Pathophysiology

Dr. Yasser Mufid

Lecture 2

Cell Injury, Cell Death & Adaptation

I. Learning objectives

1. Comprehending the concepts of adaptations: Hyperplasia, Hypertrophy ,Atrophy, Metaplasia.
2. Comprehending the concepts of Reversible cell injury.
3. Comprehending the concepts of Irreversible cell injury.
4. Classifying necrosis.
5. Compare and differentiate between apoptosis and necrosis.
6. Identify common intracellular accumulations: Fat, Hyaline ,CA++, Proteins, Glycogen , Pigments.
7. Understand aging and differentiate the concepts of preprogrammed death.

Cells normally maintain a steady state called homeostasis in which the intracellular milieu is kept within a fairly narrow range of physiologic parameters. As cells encounter physiologic stresses or pathologic stimuli, they can undergo adaptation, achieving a new steady state and preserving viability and function.

Cell injury *is the effect of a variety of stresses due to etiologic agents a cell encounters resulting in changes in its internal and external environment.*

In general, cells of the body have inbuilt mechanism to deal with changes in environment to an extent. The cellular response to stress may vary and depends upon following two variables:

i) Host factors i.e. the type of cell and tissue involved.

ii) Factors pertaining to injurious agent i.e. extent and type of cell injury.

Various forms of cellular responses to cell injury may be as follows:

1. When there is increased functional demand, the cell may adapt to the changes which are expressed morphologically, which then revert back to normal after the stress is removed.
2. When the stress is mild to moderate, the injured cell may recover (reversible cell injury), while persistent and severe form of cell injury may cause cell death (irreversible cell injury).
3. The residual effects of reversible cell injury may persist in the cell as evidence of cell injury at subcellular level (subcellular changes), or metabolites may accumulate within the cell (intracellular accumulations).

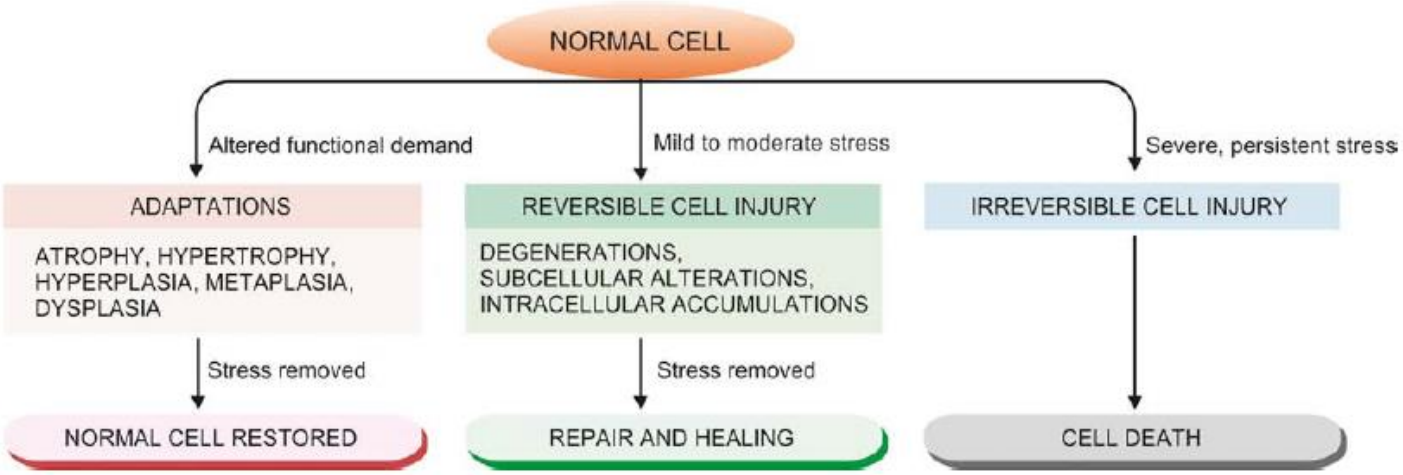

I. Adaptations

are reversible changes in the number, size, phenotype, metabolic activity, or functions of cells in response to changes in their environment.

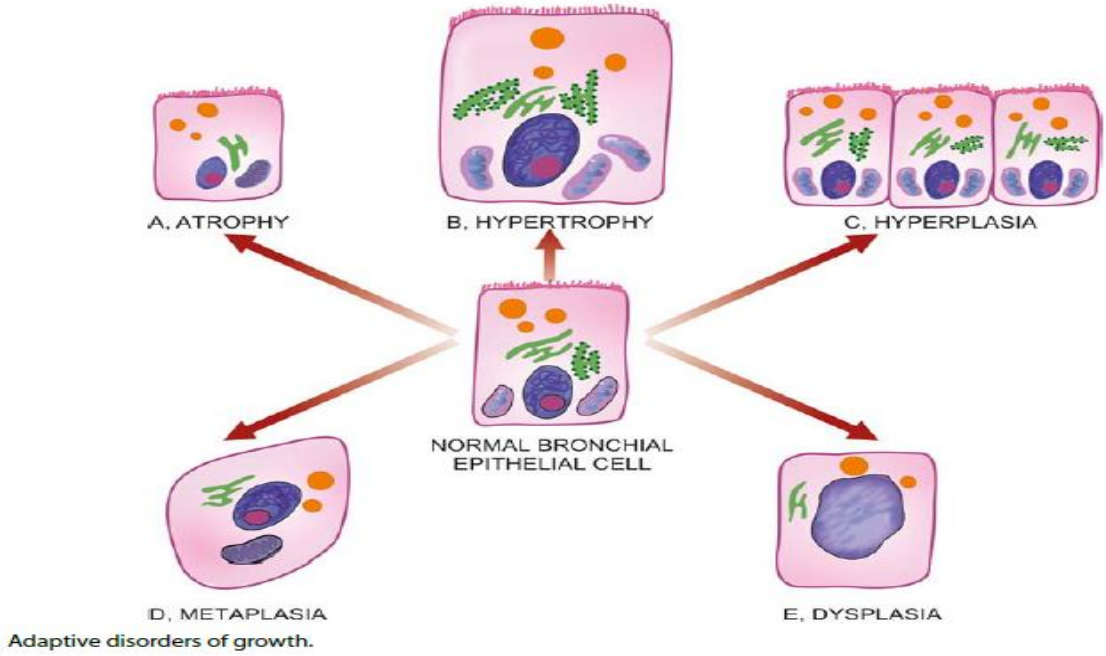

It is of two types:-

1- Physiologic adaptations usually represent responses of cells to normal stimulation by hormones or endogenous chemical mediators (e.g., the hormone-induced enlargement of the breast and uterus during pregnancy).

2- Pathologic adaptations are responses to stress that allow cells to modulate their structure and function and thus escape injury. Such adaptations can take several distinct forms.

Examples of adaptations include:

1) **Atrophy:** *A reduction of the number and size of parenchymal cells of an organ or its parts which was once normal.*

CAUSES Atrophy may occur from physiologic or pathologic causes:

A. Physiologic atrophy:

Atrophy is a normal process of ageing in some tissues, which could be due to loss of endocrine stimulation or arteriosclerosis. *For example:* Atrophy of lymphoid tissue with age, Atrophy of thymus in adult life, Atrophy of gonads after menopause, Atrophy of brain with ageing & Osteoporosis with reduction in size of bony trabeculae due to ageing.

B. Pathologic atrophy

The causes are as under:

1. Starvation atrophy In starvation.

2. Ischemic atrophy e.g.

i) Small atrophic kidney in atherosclerosis of renal artery.

ii) Atrophy of the brain in cerebral atherosclerosis.

3. Disuse atrophy Prolonged diminished functional activity is associated with disuse atrophy of the organ e.g.

i) Wasting of muscles of limb immobilized in cast.

ii) Atrophy of the pancreas in obstruction of pancreatic duct.

4. Neuropathic atrophy Interruption in nerve supply leads to wasting of muscles e.g.

i) Poliomyelitis ii) Motor neuron disease iii) Nerve section.

5. Endocrine atrophy Loss of endocrine regulatory mechanism.

6. Pressure atrophy Prolonged pressure from benign tumors or cyst or aneurysm may cause compression and atrophy of the tissues.

MORPHOLOGIC FEATURES

Irrespective of the underlying cause for atrophy, the pathologic changes are similar. The organ is small, often shrunken. The cells become smaller in size but are not dead cells. Shrinkage in cell size is due to reduction in cell organelles: mitochondria, myofilaments and endoplasmic reticulum. There is often increase in the number of autophagic vacuoles containing cell debris. These autophagic vacuoles may persist to form 'residual bodies' in the cell cytoplasm e.g. lipofuscin pigment granules in brown atrophy

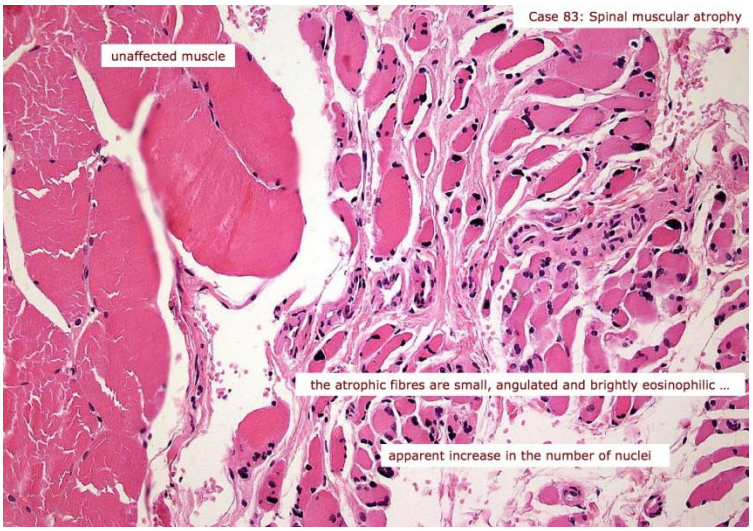

2) **Hypertrophy:** *An increase in the size of parenchymal cells resulting in enlargement of the organ or tissue, without any change in the number of cells.*

CAUSES Hypertrophy may be physiologic or pathologic. In either case, it is caused by increased functional demand or by hormonal stimulation.

A. Physiologic hypertrophy

Enlarged size of the uterus in pregnancy is an example of physiologic hypertrophy as well as hyperplasia.

B. Pathologic hypertrophy Examples of certain diseases associated with hypertrophy are as under:

1. Hypertrophy of cardiac muscle may occur in a number of cardiovascular diseases.
2. Hypertrophy of smooth muscle e.g. Cardiac achalasia (in esophagus), Pyloric stenosis (in stomach), Intestinal strictures, Muscular arteries in hypertension.
3. Hypertrophy of skeletal muscle e.g. hypertrophied muscles in athletes and manual laborers.
4. Compensatory hypertrophy may occur in an organ when the contralateral organ is removed e.g. Following nephrectomy on one side in a young patient, there is compensatory hypertrophy as well as hyperplasia of the nephrons of the other kidney.

MORPHOLOGIC FEATURES

The affected organ is enlarged and heavy. For example, a hypertrophied heart of a patient with systemic hypertension may weigh 700-800 g as compared to average normal adult weight of 350 g. There is enlargement of muscle fibers as well as of nuclei. At ultrastructural level, there is increased synthesis of DNA and RNA, increased protein synthesis and increased number of organelles such as mitochondria, endoplasmic reticulum and myofibrils.

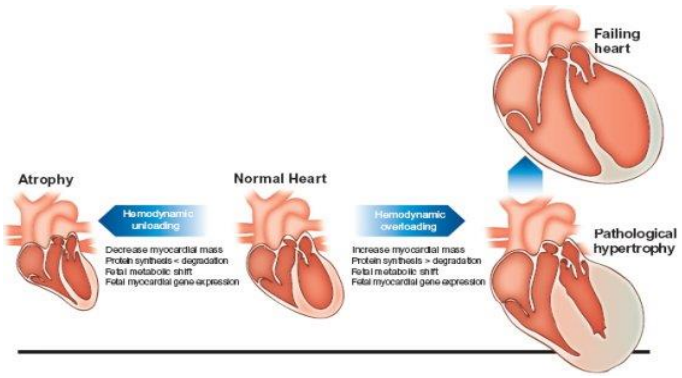

3) **Hyperplasia:** *An increase in the number of parenchymal cells resulting in enlargement of the organ or tissue.*

Both hyperplasia and hypertrophy occur together. Hyperplasia occurs due to increased recruitment of cells from G0 (resting) phase of the cell cycle to undergo mitosis, when stimulated. All body cells do not possess hyperplastic growth potential. **Labile cells** (e.g. epithelial cells of the skin and mucous membranes, cells of the bone marrow and lymph nodes) and **stable cells** (e.g. parenchymal cells of the liver, pancreas, kidney, adrenal, and thyroid) can undergo hyperplasia, while **permanent cells** (e.g. neurons, cardiac and skeletal muscle) have little or no capacity for regenerative hyperplastic growth.

CAUSES: As with other adaptive disorders of growth, hyperplasia may also be physiologic and pathologic.

A. Physiologic hyperplasia *The two most common types are hormonal and compensatory:*

1. Hormonal hyperplasia i.e. hyperplasia occurring under the influence of hormonal stimulation e.g. Hyperplasia of female breast at puberty, during pregnancy and lactation, Hyperplasia of pregnant uterus, Proliferative activity of normal endometrium after a normal menstrual cycle, Prostatic hyperplasia in old age.

2. Compensatory hyperplasia i.e. hyperplasia occurring following removal of part of an organ or in the contralateral organ in paired organ e.g. Regeneration of the liver following partial hepatectomy. Regeneration of epidermis after skin abrasion. Following nephrectomy on one side, there is hyperplasia of nephrons of the other kidney.

B. Pathologic hyperplasia Most examples of pathologic hyperplasia are due to excessive stimulation of hormones or growth factors e.g. Endometrial hyperplasia following estrogen excess. In wound healing, there is formation of granulation tissue due to proliferation of fibroblasts and endothelial cells.

MORPHOLOGIC FEATURES

There is enlargement of the affected organ or tissue and increase in the number of cells. This is due to increased rate of DNA synthesis and hence increased mitoses of the cells.

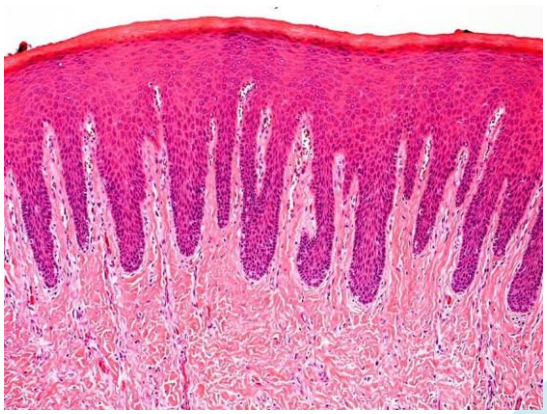

4) Metaplasia:

A reversible change of one type of epithelial or mesenchymal adult cells to another type of adult epithelial or mesenchymal cells, usually in response to abnormal stimuli, and often reverts back to normal on removal of stimulus.

If the stimulus persists for a long time, epithelial metaplasia may progress to dysplasia and further into cancer. Metaplasia is broadly divided into 2 types: epithelial and mesenchymal.

Examples include:

A. Squamous metaplasia

This is replacement of another type of epithelium by squamous epithelium. For example, the columnar epithelium of the bronchus can be replaced by squamous epithelium in cigarette smokers.

B. Osseous metaplasia

This replacement of a connective tissue by bone, for example at sites of injury.

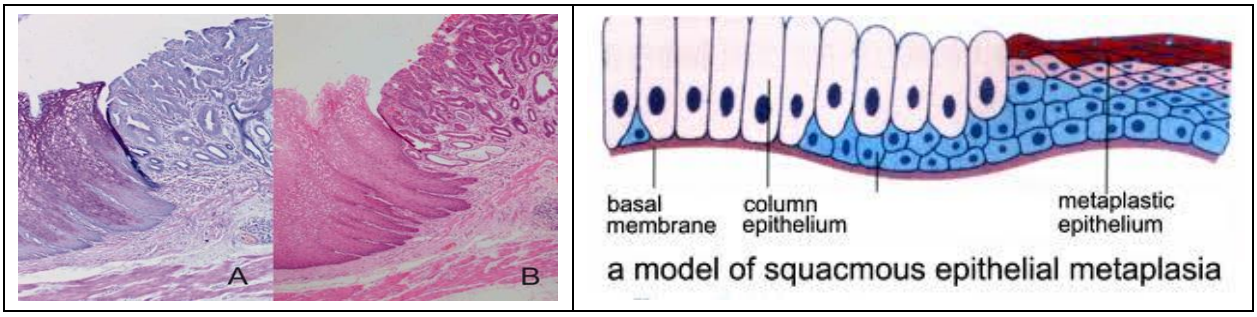

5) Dysplasia:

An alteration in cell growth resulting in cells that differ in size, shape, and appearance, often as a result of chronic irritation. There is loss in the architecture (normal cell arrangement), it could lead to ***Neoplasia.***

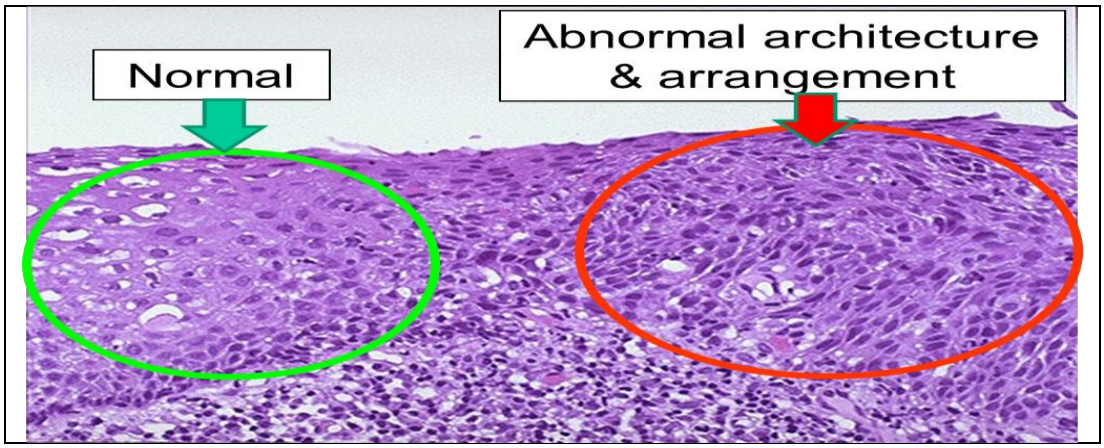

MORPHOLOGIC FEATURES

It is characterized by:

1. Increased number of layers of epithelial cells.
2. Disorderly arrangement of cells from basal layer to the surface layer.
3. Loss of basal polarity i.e. nuclei lying away from basement membrane.
4. Cellular and nuclear pleomorphic.
5. Increased nucleocytoplasmic ratio.
6. Nuclear hyperchromatism.
7. Increased mitotic activity.

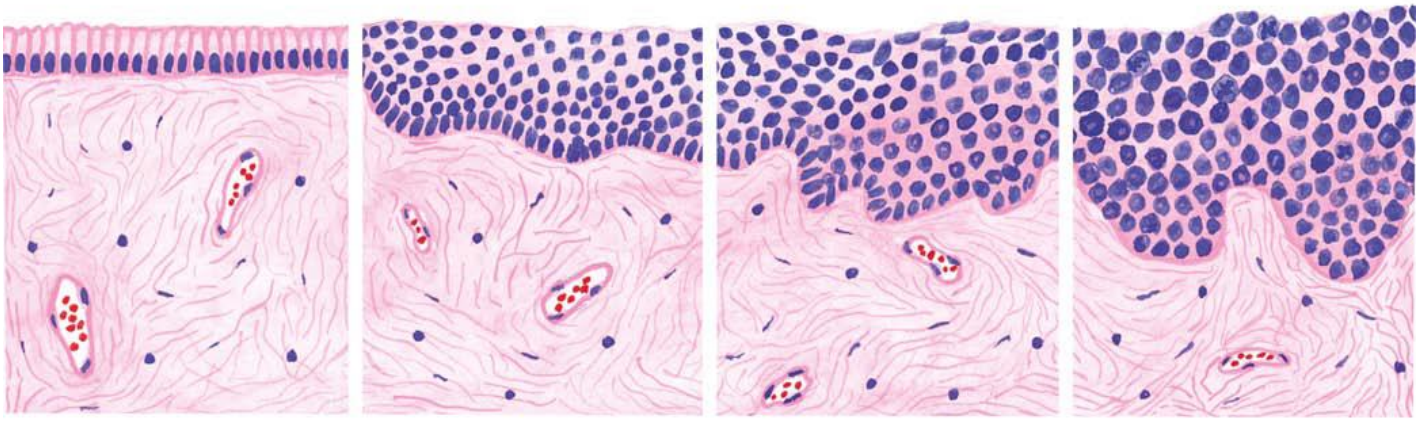

6) **Ageing:** Life expectancy of an individual depends upon certain factors: **genetic, environmental, life style and some age related diseases.**

There are several hypothesis of ageing. These are: shortening of telomere without replacement of damaged ends, persistent oxidative stress (accumulation of free radicals), hormonal decline, defective host defenses and failure to renew old cells.

Ageing causes decline in morphology and function of multiple organs: cardiovascular system, nervous system, muscles, bones, eyes, ears, immune system and skin. About 80% of cancers are seen in the age range of 50-80 years.

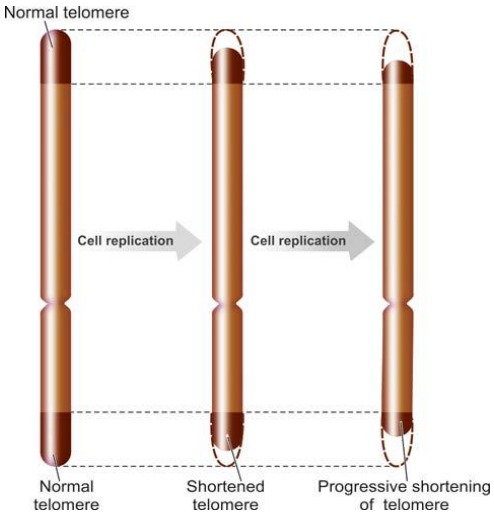

II. Reversible Cell injures & accumulations

1) Reversible Cell injures (*retrogressive changes*)

The two main morphologic correlates of reversible cell injury are:

1. Cellular swelling.
2. Fatty change.

Cellular swelling is the result of failure of **energy-dependent ion pumps** in the plasma membrane, leading to an inability to maintain ionic and fluid homeostasis.

Fatty change occurs in **hypoxic injury** and in various forms of toxic or metabolic injury and is manifested by the appearance of small or large lipid vacuoles in the cytoplasm.

Common examples of morphologic forms of reversible cell injury are as under:

1. Hydropic change.
2. Hyaline change.
3. Mucoid change.
4. Fatty change.

The most important targets of injurious agents are:

1. Mitochondria (the sites of ATP generation).
2. Cell membranes, which influence the ionic and osmotic homeostasis of the cell.
3. Protein synthesis (ribosomes).
4. The cytoskeleton (microtubules, and various filaments).
5. The genetic apparatus of the cell (nuclear DNA).

Morphology of Reversibility Cell Injury

Hydropic swelling is the earliest form of cell injury from various etiologies and its main features are cellular swelling due to cytoplasmic vacuoles.

Hyaline change is intra- and extracellular deposition of pink, proteinaceous material.

Mucoid change is deposition of mucinous material in epithelial and connective tissues in excessive amounts.

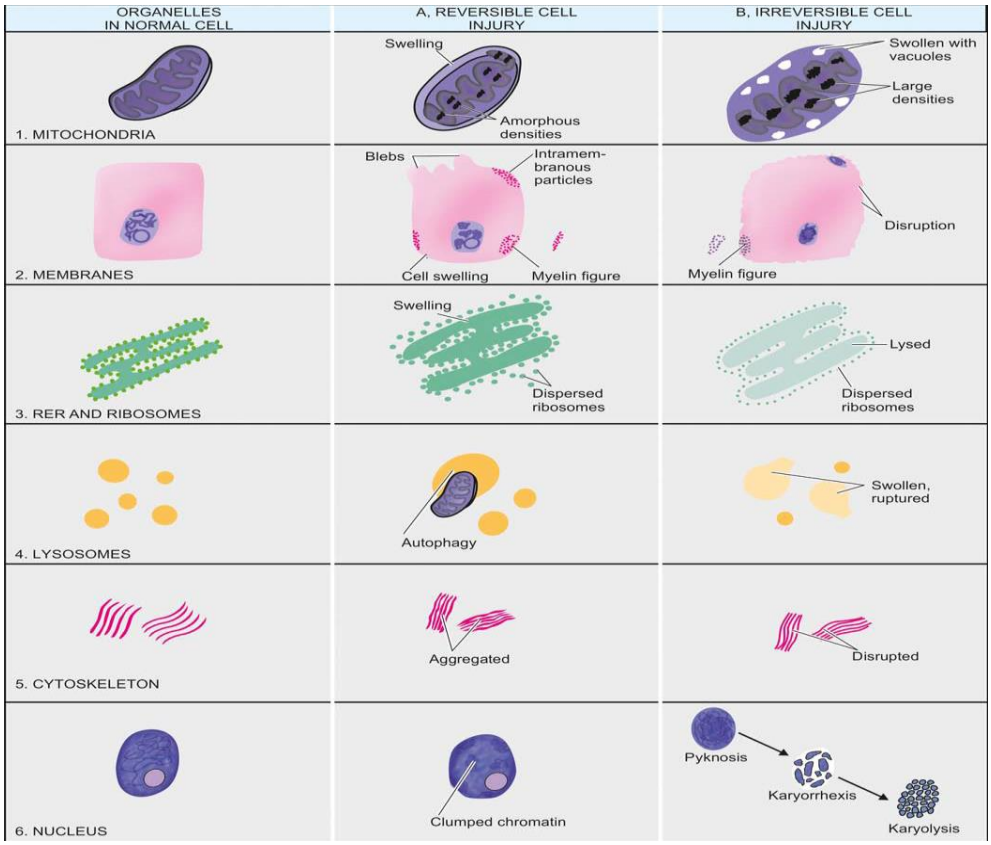

Fatty change

The accumulation of triglycerides inside parenchymal cells.

It is caused by an imbalance between the uptake, utilization, & secretion of fat. Fatty change is usually seen in the liver, heart, or kidney. Fatty liver (hepatic steatosis) may be caused by alcohol, diabetes mellitus, malnutrition, obesity, & poisonings. These etiologies cause accumulation of fat in the hepatocytes by the following mechanisms:

a. Increased uptake of triglycerides into the parenchymal cells.
b. Decreased use of fat by cells.
c. Overproduction of fat in cells.
d. Decreased secretion of fat from the cells.

MORPHOLOGIC FEATURES

Grossly, The liver in fatty change is enlarged with a tense, glistening capsule and rounded margins. The cut surface bulges slightly and is pale-yellow to yellow and is greasy to touch.

Microscopically, Characteristic feature is the presence of numerous lipid vacuoles in the cytoplasm of hepatocytes, appear as non-staining vacuoles in H & E.

2) The accumulations of pigments

Pigments can be exogenous or endogenous. These pigments can accumulate inside cells in different situations.

A. <u>ENDOGENOUS PIGMENTS</u>

1. Melanin
2. Melanin-like pigment
3. Hemoprotein-derived pigments

i) Hemosiderin
ii) Acid hematin (Haemozoin)
iii) Bilirubin
iv) Porphyrins

4. Lipofuscin (Wear and tear pigment)

B. <u>EXOGENOUS PIGMENTS</u>

1. Inhaled pigments
2. Ingested pigments
3. Injected pigments (Tattooing)

a. Melanin

Melanin is a brownish-black pigment produced by the melanocytes found in the skin. **Increased** melanin pigmentation is caused by **sun tanning** & certain diseases e.g. nevus, or malignant melanoma. **Decreased** melanin pigmentation is seen in **albinism & vitiligo**.

b. Bilirubin

Bilirubin is a yellowish pigment, mainly produced during the degradation of hemoglobin. Excess accumulation of bilirubin causes yellowish discoloration of the sclerae, mucosae, & internal organs. Such a yellowish discoloration is called **jaundice**.

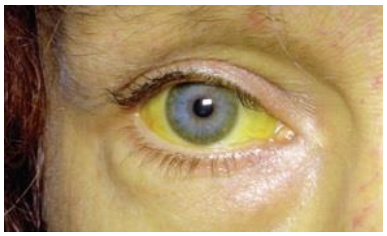

c. Hemosiderin

Hemosiderin is an iron-containing pigment derived from ferritin. It appears in tissues as golden brown amorphous aggregates & is identified by its staining reaction with the Prussian blue dye. Hemosiderin exists normally in small amounts within tissue macrophages of the bone marrow, liver, & spleen as physiologic iron stores. It accumulates in tissues in excess amounts in certain diseases.

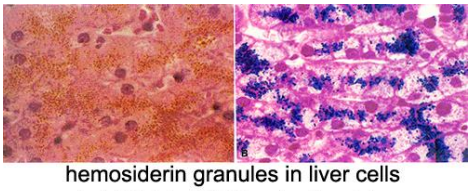

hemosiderin granules in liver cells
Left: HE stain, Right: Prussian blue stain

<u>III. Irreversible Cell Injury</u>

With continuing damage, the injury becomes irreversible, at which time the cell cannot recover and it **dies**. Cell death is a state of irreversible injury. It may occur in the living body as a local or focal change (i.e. autolysis, necrosis and apoptosis) which differ in their morphology, mechanisms, and roles in disease and physiology.

A. Autolysis (i.e. Self-digestion)

is disintegration of the cell by its own hydrolytic enzymes liberated from lysosomes. Autolysis can occur in the living body when it is surrounded by inflammatory reaction (vital reaction), but the term is generally used for postmortem change in which there is complete absence of surrounding inflammatory response.

Morphologically

Autolysis is identified by homogeneous and eosinophilic cytoplasm with loss of cellular details and remains of cell as debris.

B. NECROSIS

A localized area of death of tissue followed later by degradation of tissue by hydrolytic enzymes liberated from dead cells; it is invariably accompanied by inflammatory reaction.
Necrosis can be caused by various agents such as hypoxia, chemical and physical agents, microbial agents, immunological injury,… etc.

Morphologic features of necrosis:

These consists of cytoplasmic & nuclear changes:

1- Cytoplasmic changes: The necrotic cells show increased cytoplasmic eosinophilia i.e. it appears deep pink in color than normal cells. Myelin figures; leakage and enzymatic digestion of cellular contents.

2-Nuclear changes: These assume one of three patterns, due to breakdown of DNA and chromatin

a. Karyolysis: The basophilia of the chromatin become pale secondary to deoxyribonuclease (DNase) activity.

b. Pyknosis: Characterized by nuclear shrinkage and increased basophilia; the DNA condenses into a solid shrunken mass.

c. Karyorrhexis: The pyknotic nucleus undergoes fragmentation.

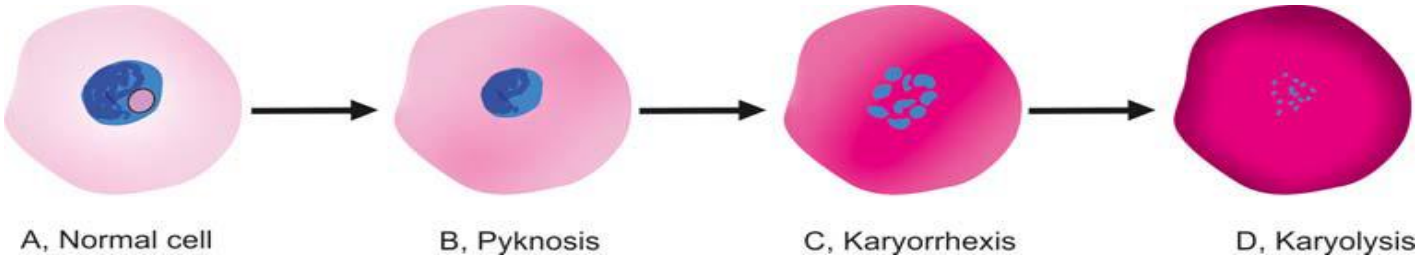

Based on etiology and morphologic appearance, there are5 types of necrosis: coagulative, liquefaction, caseous, fat, and fibrinoid necrosis.

1- Coagulative necrosis: *Is a form of tissue necrosis in which the component cells are dead but the basic tissue architecture is preserved for at least several days.*

The affected tissues take on a **firm texture**.

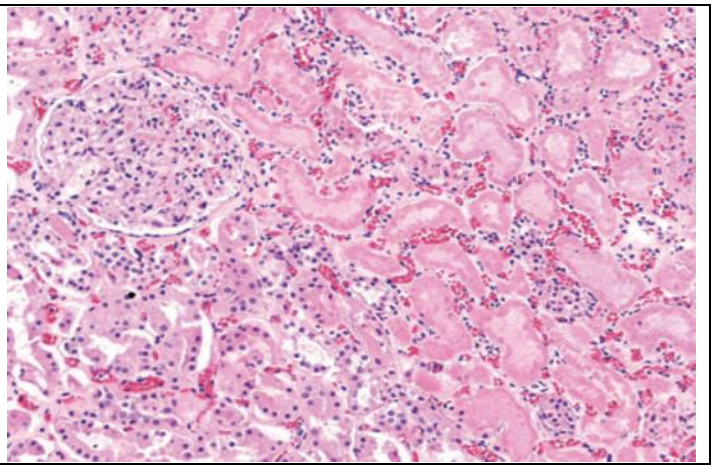

Grossly, Focus of coagulative necrosis in the early stage is pale, firm, and slightly swollen and is called **infarct**. With progression, the affected area becomes more yellowish, softer, and shrunken.

Microscopically, the hallmark of coagulative necrosis is the conversion of normal cells into their 'tomb stones' i.e. outlines of the cells are retained and the cell type can still be recognized but their cytoplasmic and nuclear details are lost. The necrotized cells are swollen and have more eosinophilic cytoplasm than the normal. These cells show nuclear changes of pyknosis, karyorrhexis and karyolysis.
However, cell digestion and liquefaction fail to occur. Eventually, the necrotized focus is infiltrated by inflammatory cells and the dead cells are phagocytosed leaving granular debris and fragments of cells.

2- Liquefactive necrosis: *Is seen in focal bacterial or, occasionally, fungal infections,* ***not ischemia*** because microbes stimulate the accumulation of inflammatory cells and the enzymes of leukocytes digest ("liquefy") the tissue. For obscure reasons, hypoxic death of cells within the central nervous system often evokes liquefactive necrosis.

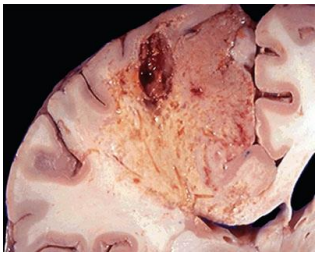

Grossly: The affected area is soft, liquefied center & containing necrotic debris. Later, a cyst wall is formed. ***Microscopically,*** The cystic space contains necrotic cell debris and macrophages filled with phagocytosed material. The cyst wall is formed by prolife rating capillaries, inflammatory cells, and gliosis (prolife rating glial cells) in the case of brain and proliferating fibroblasts in the case of abscess cavity.

3- Caseous necrosis: Caseous (caseous= cheese-like) necrosis is found in the center of foci of tuberculous infections. *It combines features of both coagulative and liquefactive necrosis.*

A

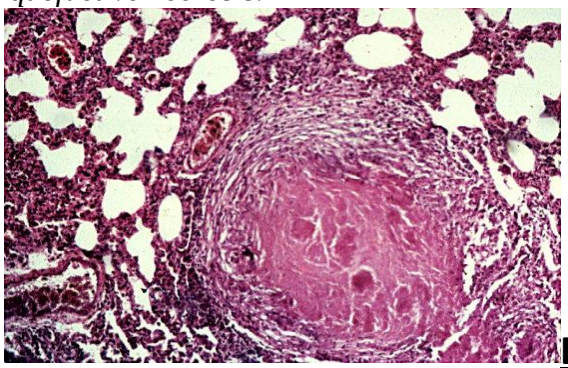

B

Grossly: Foci of caseous necrosis resemble dry cheese and are soft, granular and yellowish. ***Microscopically:*** The center of the necrotized focus contain structureless, eosinophilic material having scattered granular debris of disintegrated nuclei. The surrounding tissue shows characteristic granulomatous inflammatory reaction consisting of epithelioid cells (modified macrophages having slipper-shaped vesicular nuclei), interspersed giant cells of Langhans' and foreign body type and peripheral mantle of lymphocytes.

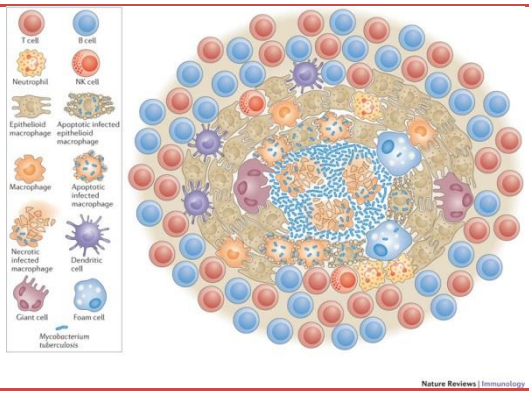

4- Fat necrosis, *Is a focal areas of fat destruction, typically resulting from release of activated pancreatic lipases into the substance of the pancreas and the peritoneal cavity. This occurs in the calamitous abdominal emergency known as acute pancreatitis.*

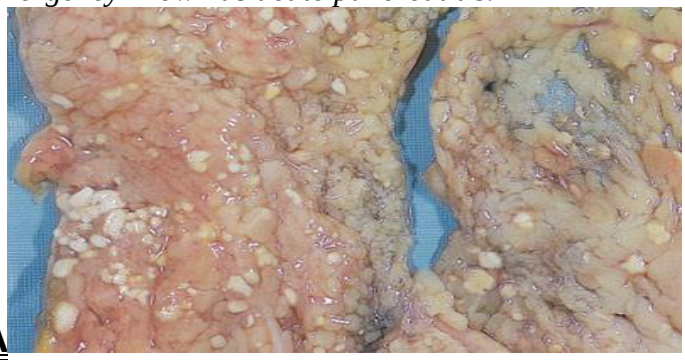

A

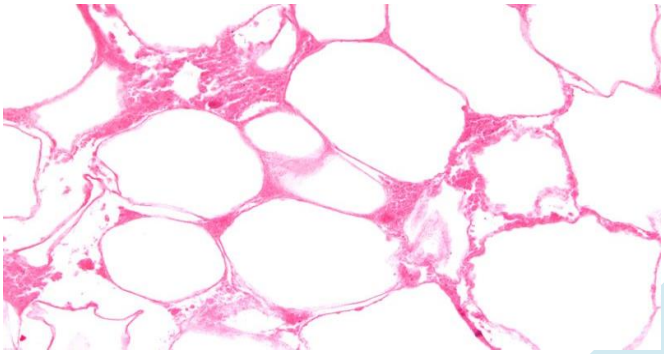

B

A. Fat necrosis in acute pancreatitis. The areas of white chalky deposits represent foci of fat necrosis with calcium soap formation (saponification) at sites of lipid breakdown in the mesentery. **B.** The cytoplasm has been pushed to the periphery with a crescent ghostly nucleus and the hall space is filled with fatty acid.

Grossly: Fat necrosis appears as yellowish-white and firm deposits. Formation of calcium soaps imparts the necrotized foci firmer and chalky white appearance.

Microscopically, the necrotized fat cells have cloudy appearance and are surrounded by an inflammatory reaction. Formation of calcium soaps is identified in the tissue sections as amorphous, granular and basophilic material.

5- Fibrinoid necrosis: *A special form of necrosis usually seen in immune reactions involving blood vessels.*

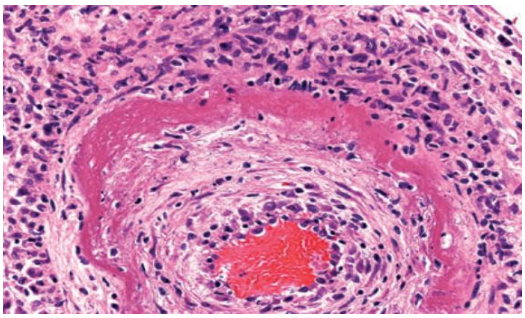

Microscopically, fibrinoid necrosis is identified by brightly eosinophilic, hyaline-like deposition in the vessel wall. Necrotic focus is surrounded by nuclear debris of neutrophils (leucocytoclasis). Local hemorrhage may occur due to rupture of the blood vessel.

6- Gangrenous necrosis

Although Gangrenous necrosis is not a distinctive pattern of cell death, the term is still commonly used in clinical practice. It is usually applied to a limb, generally the lower leg, that has lost its blood supply and has undergone coagulative necrosis involving multiple tissue layers (so called dry gangrene). When bacterial infection is superimposed, coagulative necrosis is modified by the liquefactive action of the bacteria and the attracted leukocytes (so called wet gangrene).

C. Apoptosis

A pathway of cell death that is induced by a tightly regulated suicide program in which cells destined to die activate enzymes capable of degrading the cells' own nuclear DNA and nuclear and cytoplasmic proteins. Fragments of the apoptotic cells then break off, giving the appearance that is responsible for the name (apoptosis, "falling off").

When the cell is not needed, pathway of cell death is activated ('cell suicide'). Unlike necrosis, apoptosis is not accompanied by any inflammation and collateral tissue damage.

MORPHOLOGIC FEATURES

The characteristic morphologic changes in apoptosis by light microscopy and electron microscopy are:

1. Involvement of single cells or small clusters of cells in the background of viable cells.
2. Apoptotic cells are round to oval shrunken masses of intensely eosinophilic cytoplasm (mummified cell) containing shrunken or almost-normal organelles.
3. Nuclear chromatin is condensed under the nuclear membrane i.e. pyknosis.
4. The cell membrane may show blebs or projections on the surface.
5. There may be formation of membrane-bound near spherical bodies containing condensed organelles around the cell called **apoptotic bodies**.
6. Characteristically, unlike necrosis, there is no acute inflammatory reaction around apoptosis.
7. Phagocytosis of apoptotic bodies by macrophages takes place at varying speed. The tissue shows no significant changes in the overall structure.

Apoptotic bodies in the layer of squamous mucosa (shown by arrows). The dead cell seen in singles, is shrunken, the nucleus has clumped chromatin, while the cytoplasm is intensely eosinophilic. There is no inflammation, unlike necrosis.

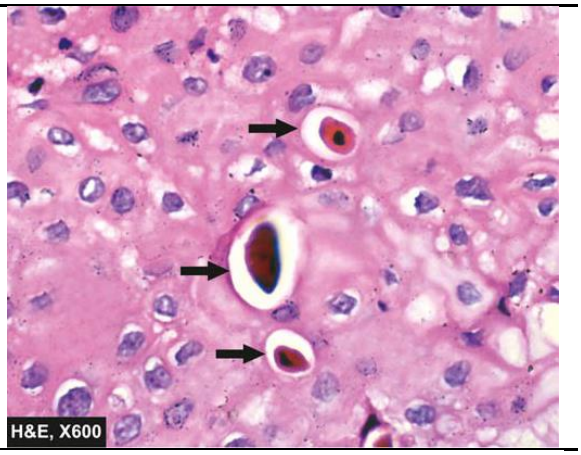

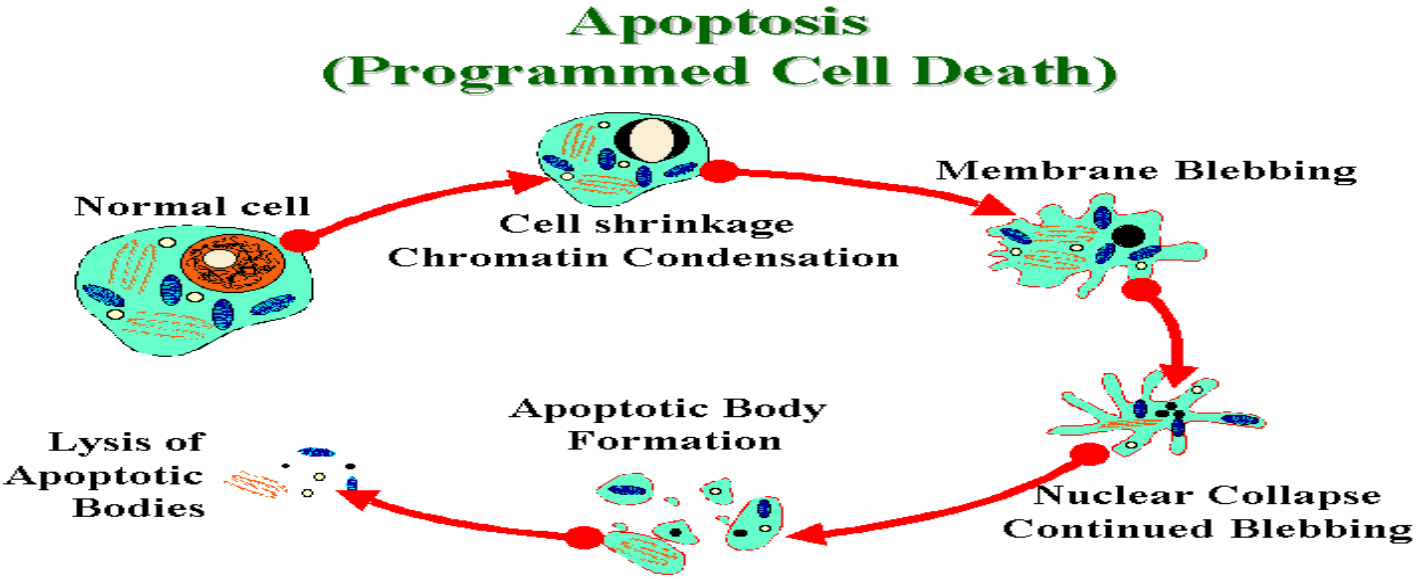

Pathophysiology

Initiation of Apoptosis:

1- **Mitochondrial (intrinsic) pathway** is triggered by:

A. Loss of survival signals.
B. DNA damage beyond repair.
C. Accumulation of misfolded proteins (Endoplasmic Reticulum stress). E.g Aging, cystic fibrosis and Neurodegenerative Diseases.

All these will lead to:

i. Leakage of pro-apoptotic proteins from mitochondrial membrane.
ii. Into the cytoplasm.
iii. Trigger Caspase activation *which is normally inhibited by anti-apoptotic members of the Bcl family, which are induced by survival signals including growth factors.*

2- **Death receptor (extrinsic) pathway** *is responsible for elimination of self-reactive lymphocytes and damage by cytotoxic T lymphocytes*.

It is initiated by engagement of death receptors(members of the Tumor necrotizing factor (TNF) receptor family by ligands on adjacent cells.

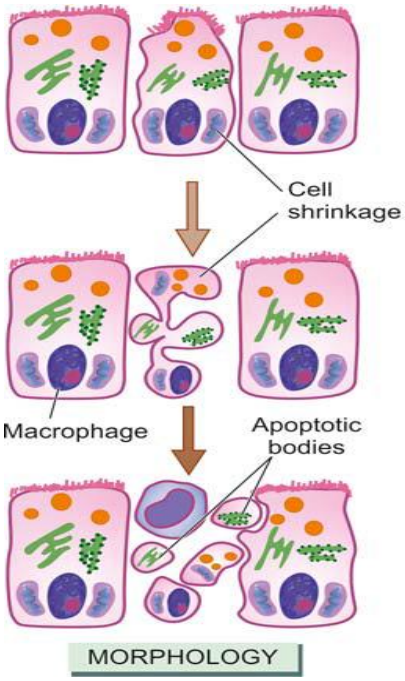

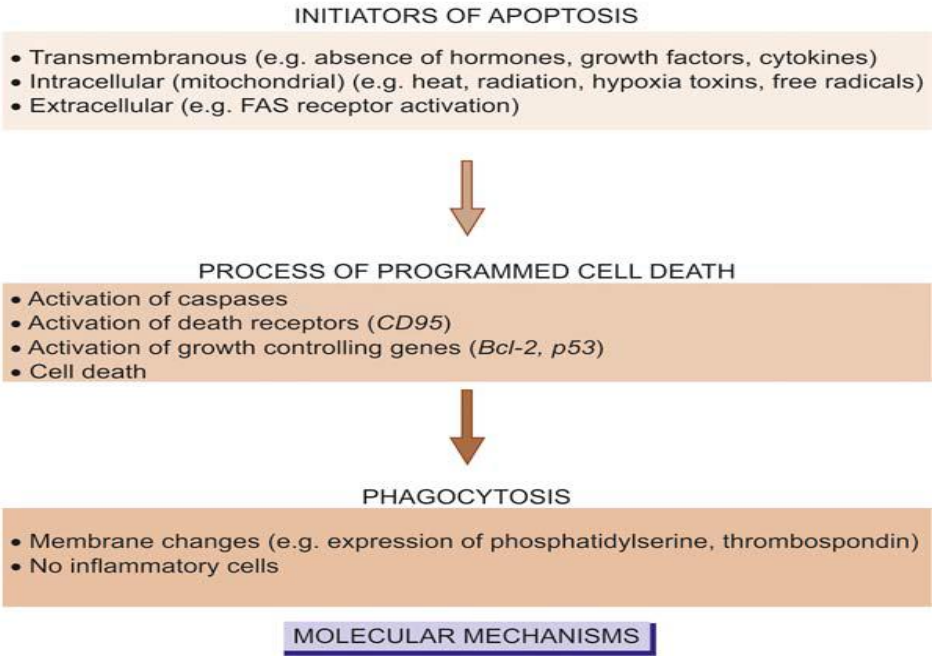

Features of Necrosis and Apoptosis

Feature	Necrosis	Apoptosis
Cell size	Enlarged (swelling)	Reduced (shrinkage)
Nucleus	Pyknosis → karyorrhexis → karyolysis	Fragmentation into nucleosome-size fragments
Plasma membrane	Disrupted	Intact; altered structure, especially orientation of lipids
Cellular contents	Enzymatic digestion; may leak out of cell.	Intact; may be released in apoptotic bodies.
Adjacent inflammation	Frequent	No
Physiologic or pathologic role	Invariably pathologic (culmination of irreversible.	Often physiologic, means of eliminating unwanted cell injury) cells; may be pathologic after some forms of cell injury, especially DNA damage.

PATHOLOGIC CALCIFICATION

The abnormal deposition of calcium salts, together with smaller amounts of iron, magnesium, and other minerals in the tissue.

Types of pathological calcification:

1- **Dystrophic calcification** *is encountered in areas of necrosis of any type. It mostly* ***indicates insignificant past cell injury****, it may also be a cause of organ dysfunction.*

For example, calcification can develop in aging or damaged heart valves, resulting in severely compromised valve motion. Dystrophic calcification of the aortic valves is an important cause of aortic stenosis in the elderly.

A

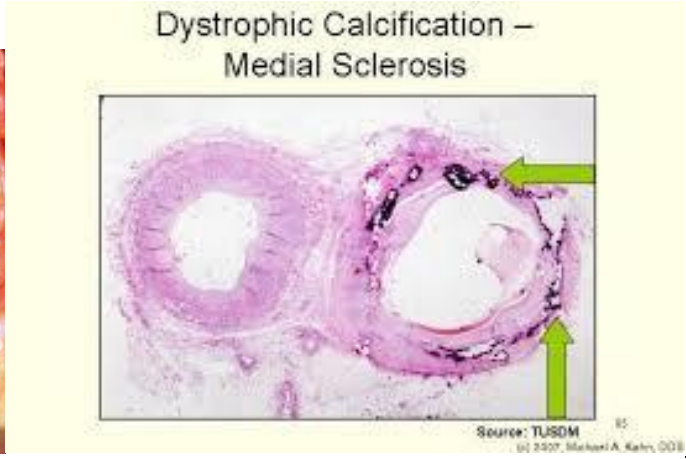

B

A. Calcification of the aortic valve. A view looking down onto the unopened aortic valve in a heart with calcific aortic stenosis. The semilunar cusps are thickened and fibrotic. Behind each cusp are large, irregular masses of dystrophic calcification that will prevent normal opening of the cusps. **B.** calcification appears as intracellular and/or extracellular basophilic deposits. ***In H&E stain.***

2- Metastatic calcification *can occur in normal tissues whenever there is hypercalcemia.*

The four major causes of hypercalcemia are:-

(1) Increased secretion of parathyroid hormone, due to either primary parathyroid tumors or production of parathyroid hormone-related protein by other malignant tumors.

(2) Destruction of bone due to the effects of accelerated turnover (e.g., Paget disease), immobilization, or tumors(increased bone catabolism associated with multiple myeloma, leukemia, or diffuse skeletal metastases).

(3) Vitamin D–related disorders including vitamin D intoxication and sarcoidosis (in which macrophages activate a vitamin D precursor).

(4) Renal failure, in which phosphate retention leads to secondary hyperparathyroidism.

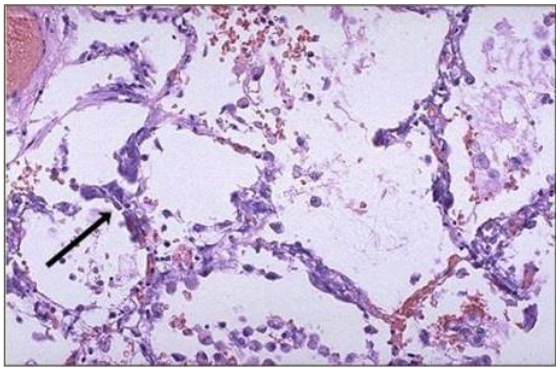

Metastatic calcification can occur widely throughout the body but principally affects the interstitial tissues of the vasculature, kidneys, lungs, and gastric mucosa. The calcium deposits morphologically resemble those described in dystrophic calcification. Although they do not generally cause clinical dysfunction, extensive calcifications in the lungs may produce remarkable radiographs and respiratory deficits, and massive deposits in the kidney (nephrocalcinosis) can cause renal damage.

Differences between dystrophic and metastatic calcification.

FEATURE	DYSTROPHIC CALCIFICATION	METASTATIC CALCIFICATION
1- Definition	Deposits of calcium salts in dead and degenerated tissues.	Deposits of calcium salts in normal tissues.
2-Calcium metabolism	Normal .	Deranged.
3-Serum calcium level	Normal.	Hypercalcemia.
4- Reversibility	Generally irreversible.	Reversible upon correction of metabolic disorder.
5- Causes	Necrosis (caseous, liquefactive, fat), infarcts, thrombi, hematomas, dead parasites, old scars, atheromas, , certain tumors, cysts, calcinosis cutis.	Hyperparathyroidism (due to adenoma, hyperplasia, CRF), bony destructive lesions (e.g. myeloma, metastatic carcinoma), prolonged immobilization, hypervitaminosis D, milk-alkali syndrome, hypercalcemia of infancy
6- Pathogenesis	Increased binding of phosphates with necrotic and degenerative tissue.	Increased precipitates of calcium phosphate due to hypercalcemia at certain sites e.g. in lungs, stomach, blood vessels and cornea.

Exercises

1. Why should you study cell injury?
2. Compare & contrast the various types of cellular adaptation.
3. Describe the various mechanisms of necrosis.
4. Mention some of the causes of each of the various types of necrosis.
5. Compare & contrast necrosis & apoptosis.
6. Contract metastatic & dystrophic calcification.
7. What are the causes of hepatic steatosis?
8. Write a five line paragraph on Myelin figures. " Internet Homework".
9. Describe Mesenteric saponification.

Select the most appropriate answer.

1- Which of the following types of necrosis is grossly opaque & chalky white:

(a) Coagulative necrosis. **(b) liquefaction necrosis.**
(c) fibrinoid necrosis. **(d) fatty necrosis.**
(e) gangrenous necrosis .

2- Which of the following types of necrosis is mostly associated with ischemia:

(a) Coagulative necrosis. **(b) liquefaction necrosis.**
(c) fibrinoid necrosis. **(d) fatty necrosis.**
(e) gangrenous necrosis .

3- Dystrophic calcification is mostly associated with:

(a) Hypercalcemia. **(b) Necrosis.**
(c) Chronic irritation. **(d) Diminished blood flow.**

4- Which of the following is a reversible change:

(a) karyorrhexis. **(b) Pyknosis.**
(c) karyolysis. **(d) swelling of the endoplasmic reticulum.**
(e) gangrenous necrosis.

5- Caseative necrosis is mostly characteristic of :

(a) Acute myocardial infarction. **(b) Tuberculosis.**
(c) Acute pancreatitis. **(d) Cerebral infarction.**

References:

1.Cotran RS, Kumar V, Collins T. Robbins basic pathology. Philadelphia, J.B. Saunders Company. 9th edition 2013.
2.Macfarlane, Reid, Callander, Illustrated Pathology, Churchill Livingstone, 5th edition, 2000.
3.Harsh Mohan MD, FAMS, FICPath, FUICC. Textbook of PATHOLOGY 7th edition, 2015.
4.James Carton. Oxford Handbook of Clinical Pathology 1st edition 2012.