Central Nervous System

- Spinal cord (Medulla Spinalis)
- Brain

–gray matter
–white matter
–no intervening conn. tissue

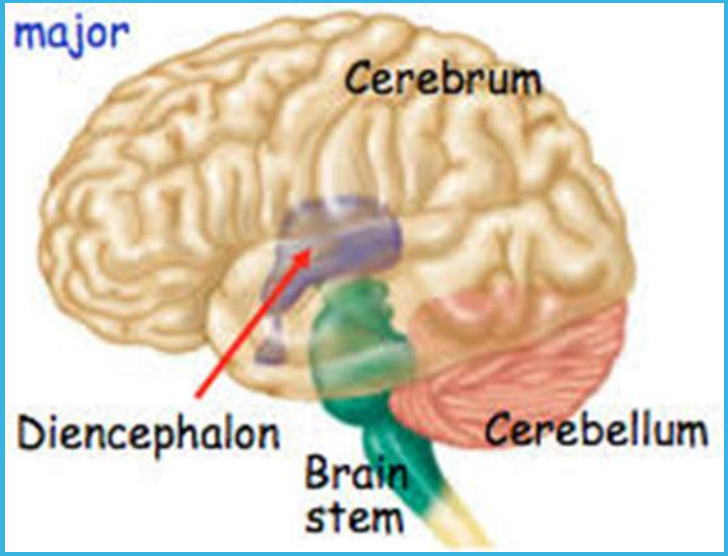

CNS

- The principal structures of the CNS are the cerebrum, cerebellum, and spinal cord.
- It has virtually no connective tissue and is therefore a relatively soft, gel-like organ.
- When sectioned ,the cerebrum ,cerebellum, and spinal cord show regions of white (white matter) and gray (gray matter), differences caused by the differential distribution of myelin

White matter;

- Myelinated/ few unmyelinated nerve fibers
- Glia
- Capillaries
- White color results from the myelin

Gray matter;

- Neuronal cell bodies
- Dendrites
- Initial unmyelinated portions of axons
- Glia
- Capillaries

Neuropil??

- network of the axons, dendrites and neuroglial processes in the gray matter

Nuclei???

- aggregations of neuron cell bodies embedded in white matter
- counterpart of ganglia

Types of Nerve Cells

1. Pyramidal cells

- **Are the most common type of neurons found in the cerebral cortex.**
- **Are pyramidal in shape.**
- **Their size ranges from 10 µm to 120 µm.**
- **The apices of the neurons give rise to dendritic processes which are directed towards the surface of the cortex, whereas the bases give origin to axons which forms projection fibers of the white matter.**
- **They are distributed in layers, 2–5, and progressively increase in size.**

2. Stellate/Granule cells

- **Small, star-shaped neurons of uniform diameter (8 µm).**
- **Have short axons terminating in nearby neurons.**

3. Fusiform cells

- **Spindle-shaped cells placed at right angles to the surface in the deep layer.**
- **Dendrites arise from each pole of the cell body and axon arises from the cell body just above the**

•Spinal Cord

•gray matter lies centrally where it forms an H shape in cross-section

•white matter is located in the periphery

•Gray matter

–the butterfly-shaped (H-shaped) area in cross-section

•White matter

•Central canal

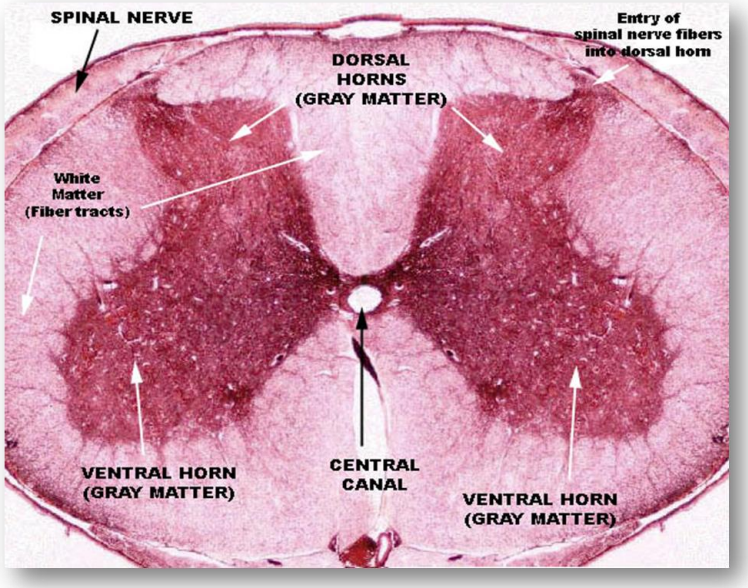

Brain

•gray matter

–periphery (cortex) of the cerebrum and cerebellum

–basal ganglia

•white matter lies deep to the cortex

•**Dorsal (posterior) horns:**

–the upper vertical bars of the H

–receive central processes of the sensory neurons whose cell bodies lie in the dorsal root ganglion

–contain cell bodies of interneurons

•**Ventral (anterior) horns:**

–the lower vertical bars of the H

–house cell bodies of large multipolar somatomotor neurons whose axons make up the ventral roots of the spinal nerves

•**Intermediary column:** visceromotor neurons

Central canal

•remnant of the lumen of the embryonic neural tube

•lies in the center of the crossbar of the H

•lined by low columnar- cuboidal cells (ependymal cells)

CEREBRAL CORTEX

1. Molecular layer **(plexiform layer)—is the most superficial, well defined layer. It consists mainly of nerve fibers and occasional *horizontal cells of Cajal.***

2. External granular layer**—contains large number of *stellate cells* and *small pyramidal cells.***

3. External pyramidal layer**—is mainly made of medium sized *pyramidal cells* and also contains few *stellate cells* and *cells of Martinotti.***

4. Internal granular layer**—is composed of closely packed *stellate cells* and horizontally oriented white fi bre band called *outer band of Baillarger.***

5. Internal pyramidal layer **(ganglionic layer)—consists mainly of *large pyramidal cells* and few *stellate cells* and *cells of Martinotti.* This layer also contains horizontally arranged fi bres that form the *inner band of Baillarger.***

6. *Multiform layer* (layer of polymorphic cells)—is the deepest layer. It contains predominantly *fusiform cell* and also few *stellate cells* and *cells of Martinotti* intermixed with many nerve fibers entering or leaving the underlying white matter.

Cerebellar Cortex

Gneral Cortex:

- **The cortex of cerebellum is highly folded. The *folds* or *folia* are separated by closely set parallel transverse fissures.**

Each folium contains a core of white matter covered superficially by grey matter or cortex

Structure:

The cerebellar cortex consists of three layers; an external molecular layer, a middle Purkinje cell layer and an internal granular layer :

1. Molecular layer

- **Is the superfi cial thick layer and is usually lightly stained with eosin.**
- **Mainly made of nerve fi bres and few cells, namely, *stellate cells* in the superfi cial part and *basket cells* in the deeper part.**
- **The axons of these cells run parallel to the long axis of the folia. The axons of basket cells form collaterals which arborize around the Purkinje cells in a 'basket-like' manner.**

2. Purkinje cell layer

***Purkinje cells* are large flask-shaped neurons (*Golgi type I*) and are arranged in a single row between *molecular* and *granular* layers.**

The dendrites of these cells pass into molecular layer and arborize profusely in a plane transverse to the folium. These dendrites synapse with axons of granular cells

The axons of Purkinje cells pass through the granular layer to end in deeper nuclei of cerebellum.

3. Granular layer

Is stained deeply with hematoxylin because it is densely packed with very *small granule neurons* . The axons of these granule cells pass into the molecular layer where they bifurcate in a T-shaped manner and run at to the dendritic processes of the Purkinje cells and synapse with them. Few *Golgi cells* (type II) are also present in the granular layer.

CEREBELLUM

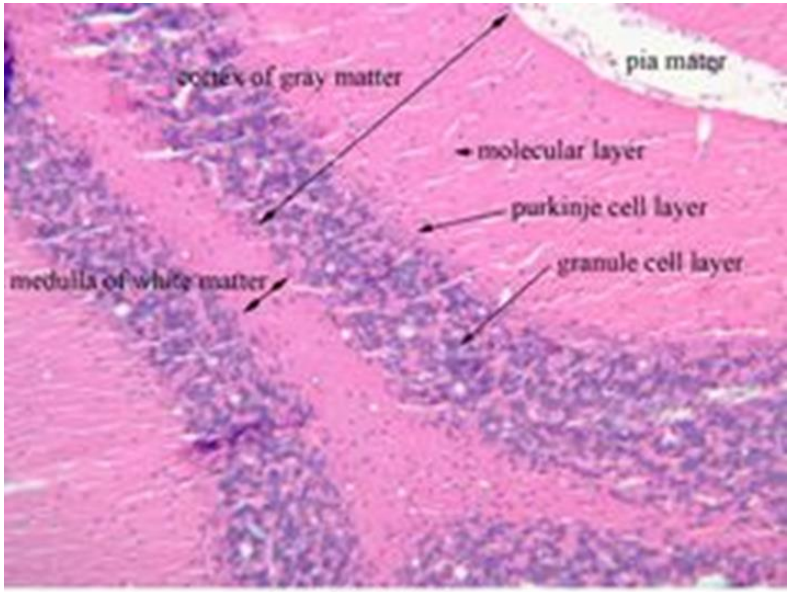

human cerebellum

cerebral cortex

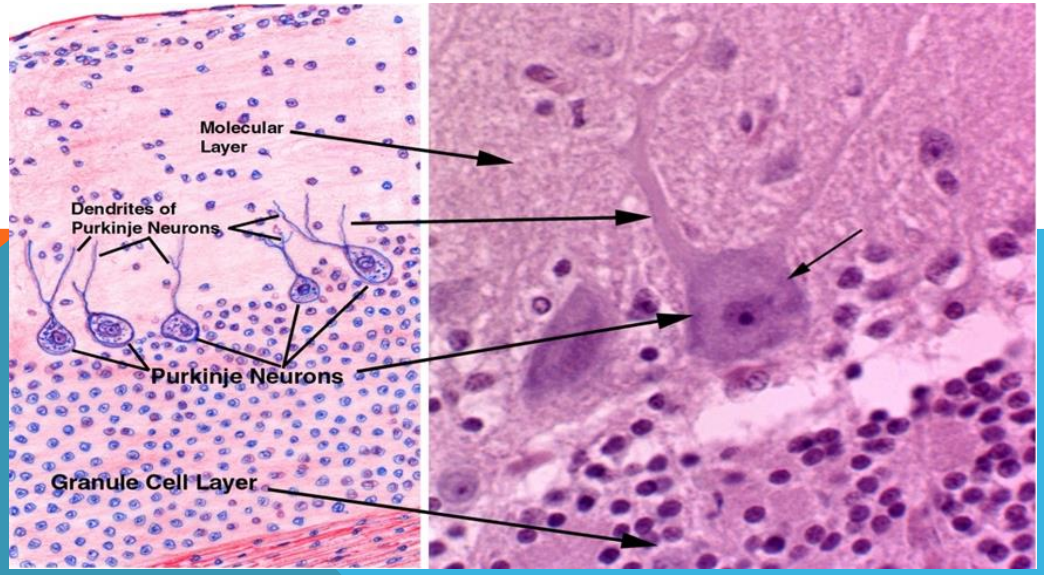

peripheral nervous system PNS

PNS

The peripheral nervous system PNS, consists of nerves, ganglia, and nerve endings. The ganglia are nodular masses of neuronal cell bodies (ganglion cells), together with their supporting peripheral neuroglia, capsule cells or satellite cells. There are two kinds of ganglia in the PNS- sensory ganglia which contain cell bodies of sensory (afferent neuron), and autonomic ganglia, which contain cell bodies of certain efferent neurons of the autonomic nervous system. The sensory ganglia include the cranial ganglia, which are associated with some of the cranial nerves, and the spinal ganglia, known as posterior (dorsal) root ganglia, which are associated with posterior root of the spinal nerves.

Peripheral nerves consist of bundles of nerve fibers (myelinated and unmyelinated). Afferent fibers and efferent fibers are both present in most nerves. Afferent nerve endings are a part of sensory receptors, and efferent nerve endings are found on muscle fibers, secretory cells of exocrine glands, and fat cells of adipose tissue

- **In the PNS, all axons are enveloped by Schwann cells which provide both structural and metabolic support.**
- **Many axons with small diameter invaginate into one Schwann cell longitudinally and are simply surrounded by the cytoplasm of Schwann cells. They are called *unmyelinated* nerve fibres.**
- **Myelination begins with the invagination of the axon into the Schwann cell. The invaginated axon is suspended from the periphery of the cell by a fold of fused plasma membrane called *mesaxon***

Peripheral Nerve:

- **Each peripheral nerve (spinal or cranial) is made of bundles (fascicles) of nerve fibres (axons) which may be myelinated and/or unmyelinated.**
- **The bundles are held together by connective tissue which provides structural support as well as nutritional support by carrying blood vessels to nerve fibres.**
- **The connective tissue framework is well appreciated in cross section of a nerve, where following structures can be observed:**
  - ***Epineurium:*** Dense connective tissue sheath surrounding the entire nerve.
  - ***Perineurium:*** A sleeve of fl attened specialised epithelial cells surrounding the bundles of nerve fibres.
  - ***Endoneurium:*** Loose connective tissue composed of reticular fibers supporting individual nerve fibers.

PERIPHERAL NERVE

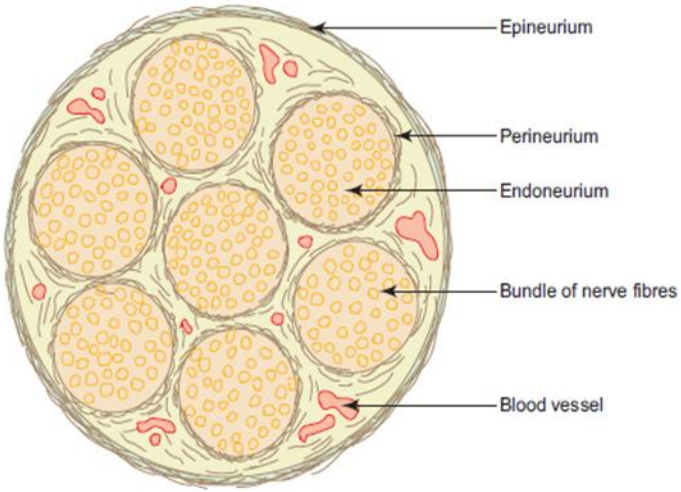

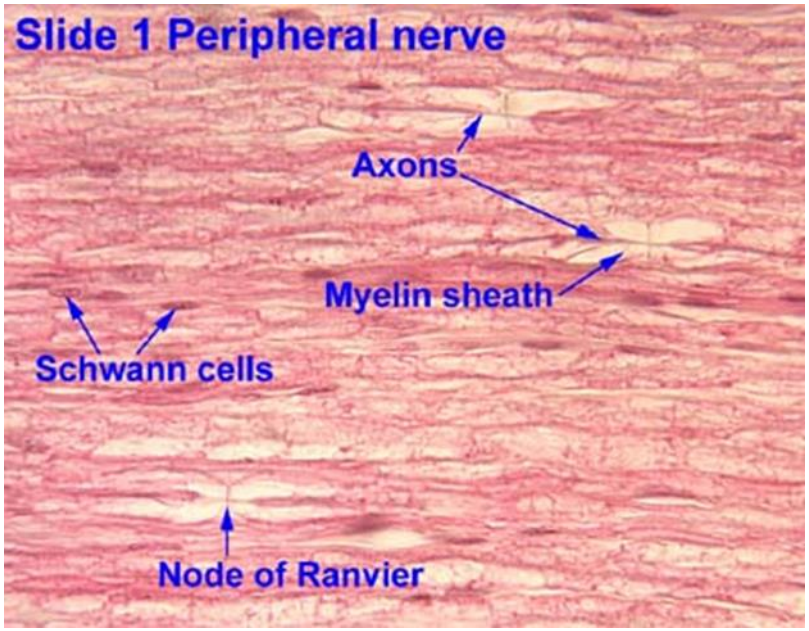

GANGLIA

Spinal ganglia

Ganglion cells have the typical features of neurons, i.e. large rounded cell body, intense cytoplasmic basophilia with fine Nissl bodies, The nucleus is large spherical pale staining with prominent nucleolus and is centrally located. Lipofuscin pigment may be present in the cytoplasm. A layer of flat capsule cells or satellite cells invest the cell body. The satellite cells are the neuroglial cells in the peripheral nervous system. The ganglion cells and the satellite cells are both derived from the neural crest and are supported by connective tissue framework and a capsule.

The ganglion cells are pseudounipolar neurons, therefore in a tissue sections they appear as rounded because the processe was not in the plane of the section.

Autonomic Ganglia

Autonimc ganglia are bulbous dilatations appear in the autonomic nerves. Some are located within certain organs, especially in the walls of the digestive tract, where they constitute the intramural ganglia. In autonomic ganglia the margins of the ganglion cells are indistinct because they are multipolar. The cytoplasm is basophilic with fine Nissl granules with eccentrically situated nucleus. The satellite cells are discontinuous unlike their counterpart of the spinal ganglia. The nucleus of the ganglion cell bodies has an eccentric position. The connective tissue capsule is not prominent

NERVE ENDINGS (RECEPTORS)

Nerve receptors are distributed throughout the body, mainly in the skin. Two types of nerve endings have been identified

- ***Free Nerve Endings***
- ***Encapsulated Nerve Endings***

Free Nerve Endings

Free nerve endings are situated in the deeper layer of the epidermis and in the papillary layer of the dermis. They are supplied with afferent nerve endings that are free of investing Schwann cells. They are *sthermoreceptor, nociceptors* and *the mechanoreceptors* that are related to the hair follicles

Encapsulated Nerve Endings

These are:

- **Pacinian Corpuscles**
- **Meissners Corpuscles**
- **Ruffini Corpuscle**
- **Krause end bulb**

NERVE ENDINGS (RECEPTORS

Meissner's corpuscles

Pacinian Corpuscles