
بسم الله الرحمن الرحيم

Introduction to Anatomy

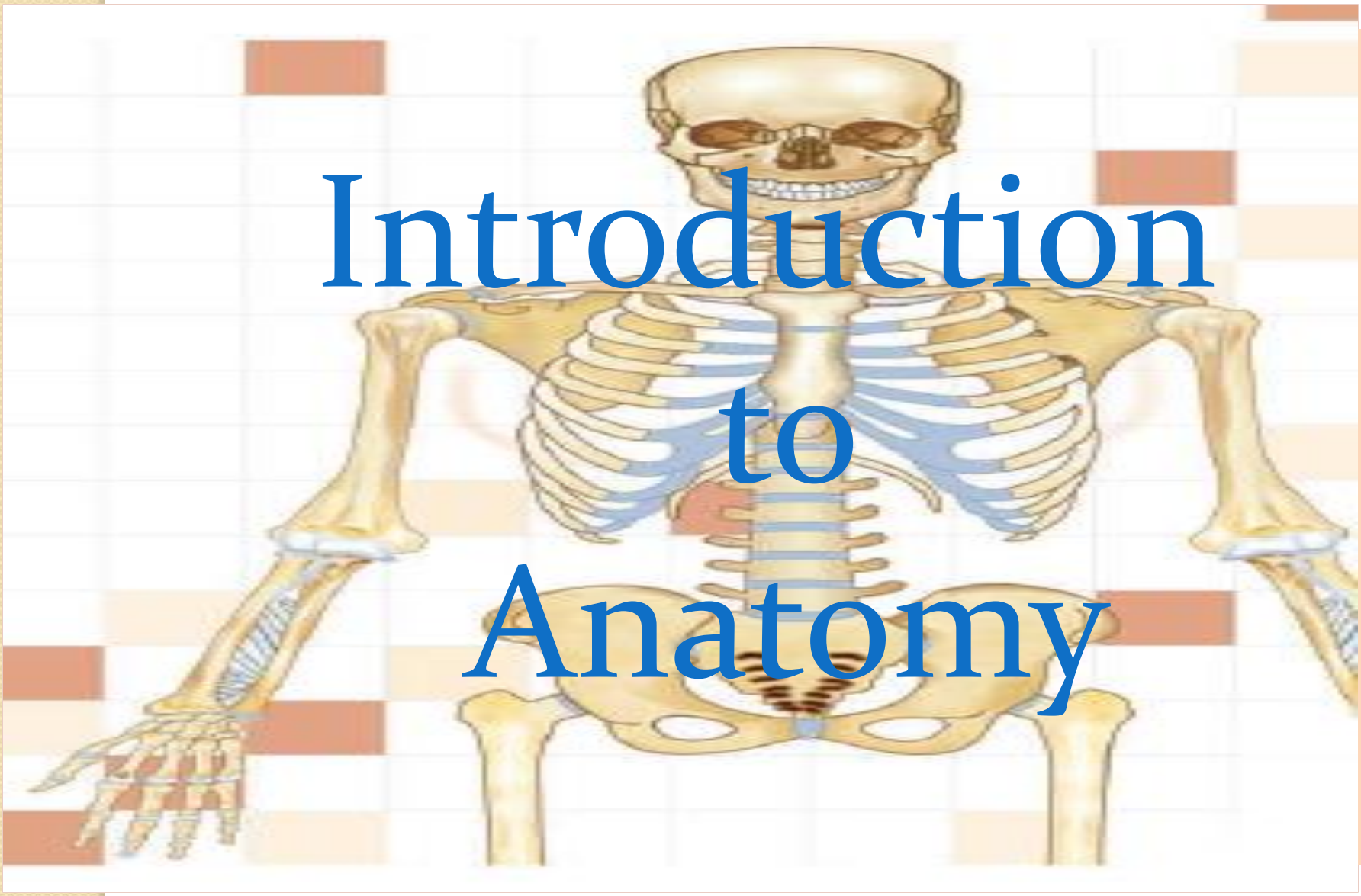

Anatomy is the science of the structure and function of the body.

- Branches of anatomy
  - Macroscopic(Gross)anatomy
    - Systemic
    - Regions
  - Microscopic anatomy
    - Cytology
    - Histology
  - Developmental anatomy
    - Embryology
  - Comparative anatomy
  - Clinical(applied) anatomy
  - Surface anatomy
  - Radiological anatomy

All descriptions in human anatomy are expressed in relation to the **anatomical position**, a convention whereby the body is erect, with the upper limbs by the side and the face and palms of the hands directed forward. It is often necessary, however, to describe the position of the viscera also in the recumbent posture, because this is a posture in which patients are frequently examined clinically.

The various parts of the body are then described in relation to certain imaginary planes.

Anatomical position with median imaginary plan

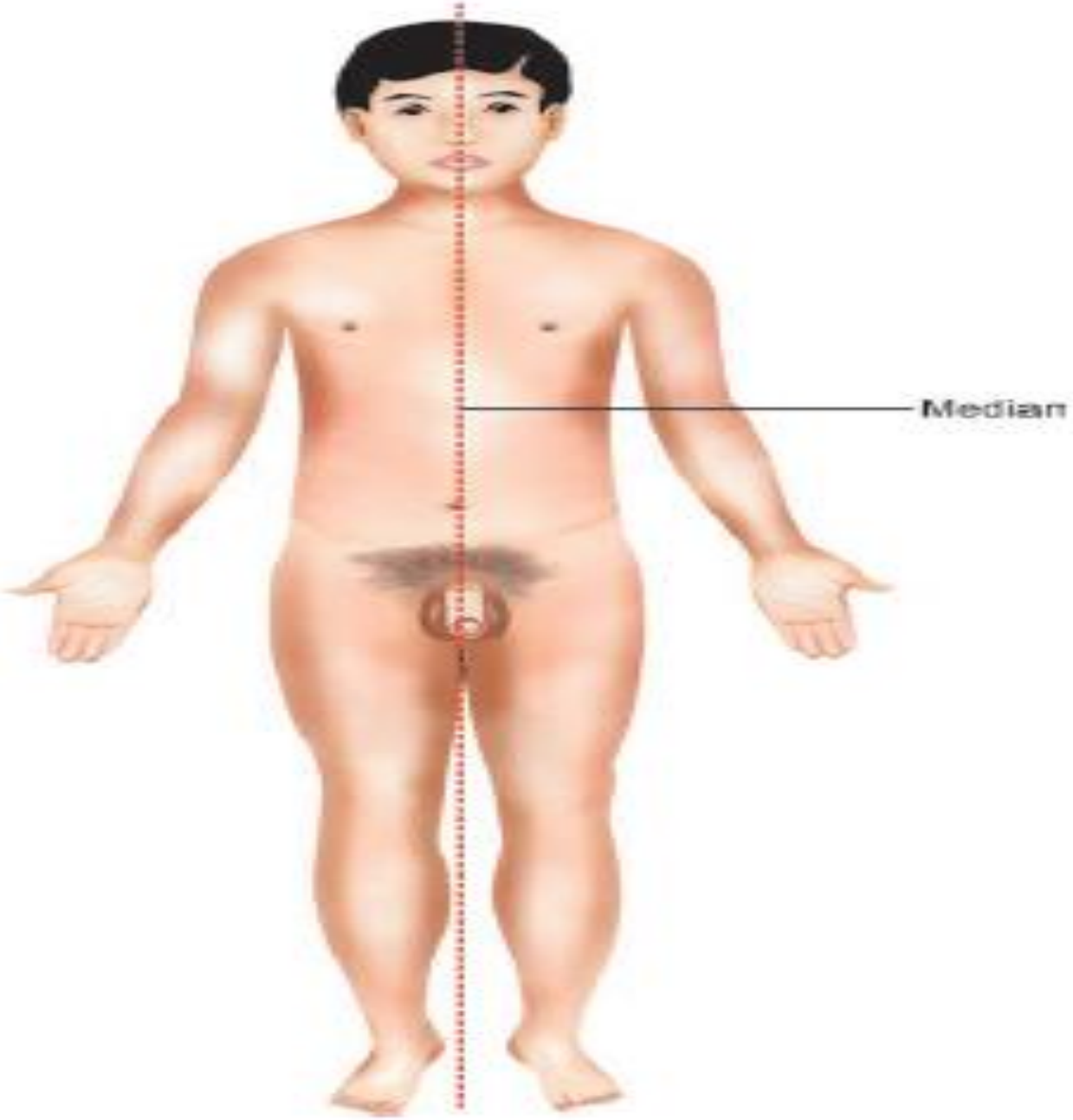

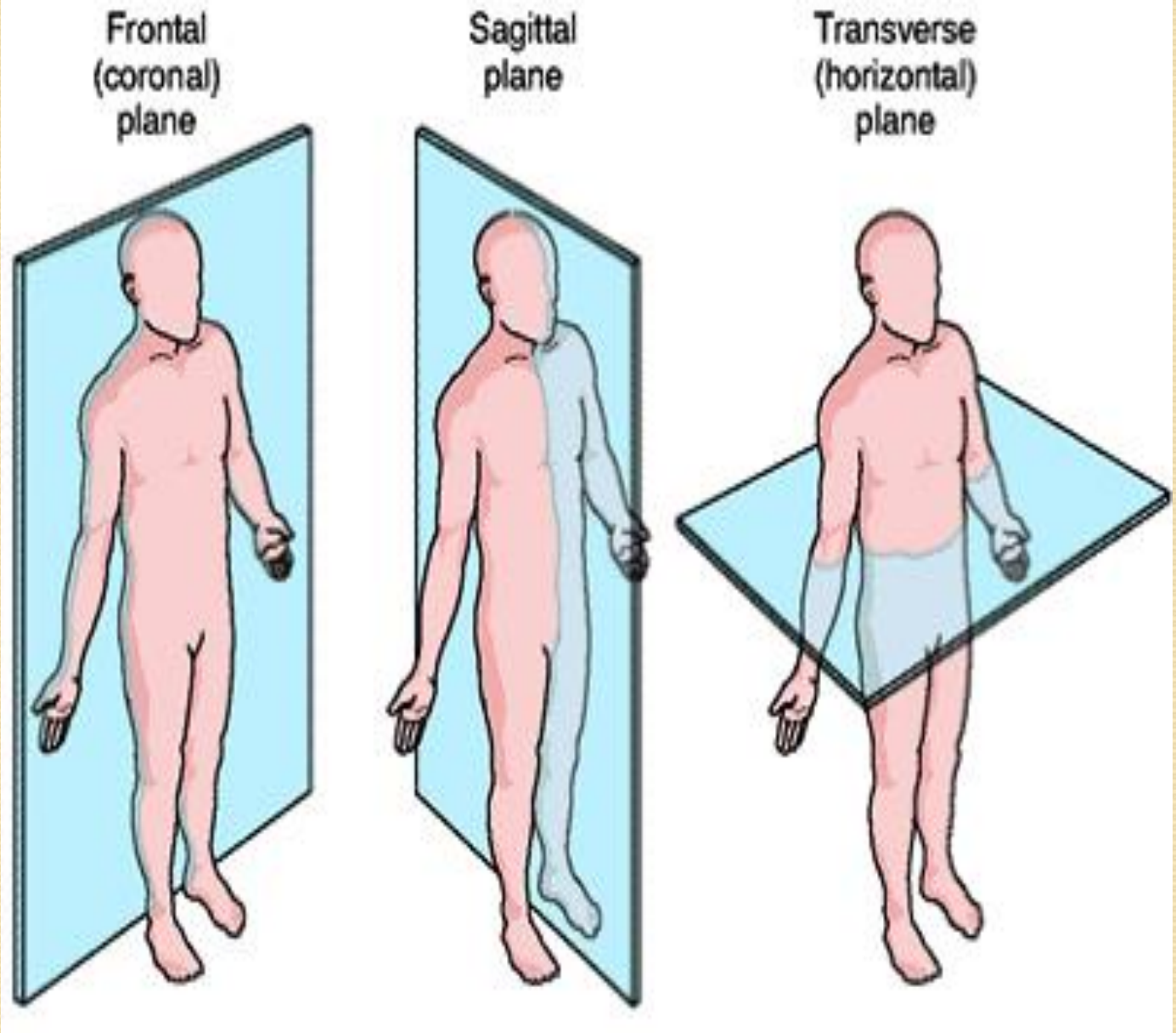
Frontal
(coronal)
plane
Sagittal
plane
Transverse
(horizontal)
plane

Anatomical terms

Superficial: Nearer to the skin, e.g. the veins are superficial to the deep fascia.
Deep: Away from the skin, e.g. the veins are deep to the skin.
Superior/cephalic: Nearer to the head, e.g. eyes are superior to the nose.
Inferior/caudal: Nearer to the tail, e.g. the diaphragm is caudal to the heart.
Anterior/ventral: Nearer to the front, e.g. the heart is anterior to the vertebrae.
Posterior/Dorsal: Towards the back, e.g. the vertebrae lie posterior to the heart.
Medial: Nearer to the midline, e.g. the trachea lies medial to the lungs.
Lateral: Away from the midline, e.g. the lungs lie lateral to the trachea.

External: Nearer to the outside, e.g. the pericardium lies external to the heart.
Internal: Nearer to the inside, e.g. the heart lies internal to the pericardium.
Proximal: Nearer to the body, e.g. the arm lies proximal to the forearm.
Distal: Away from the body, e.g. the forearm lies distal to the arm.
Palmar means towards the palm of the hand, e.g. the palmar aponeurosis lies in the palm of the hand.
Plantar means towards the sole of the foot, e.g. the plantar aponeurosis lies in the sole of the foot.

Ipsilateral: refers to the same side of the body for example, the left hand left foot are ipsilateral

Contralateral: refers to opposite sides of the body; for example, the left biceps brachii muscle and the right femoris muscle are contralateral

Supine: position of the body is lying on the back

Prone: position is lying faces downward

Terms Related to Positio

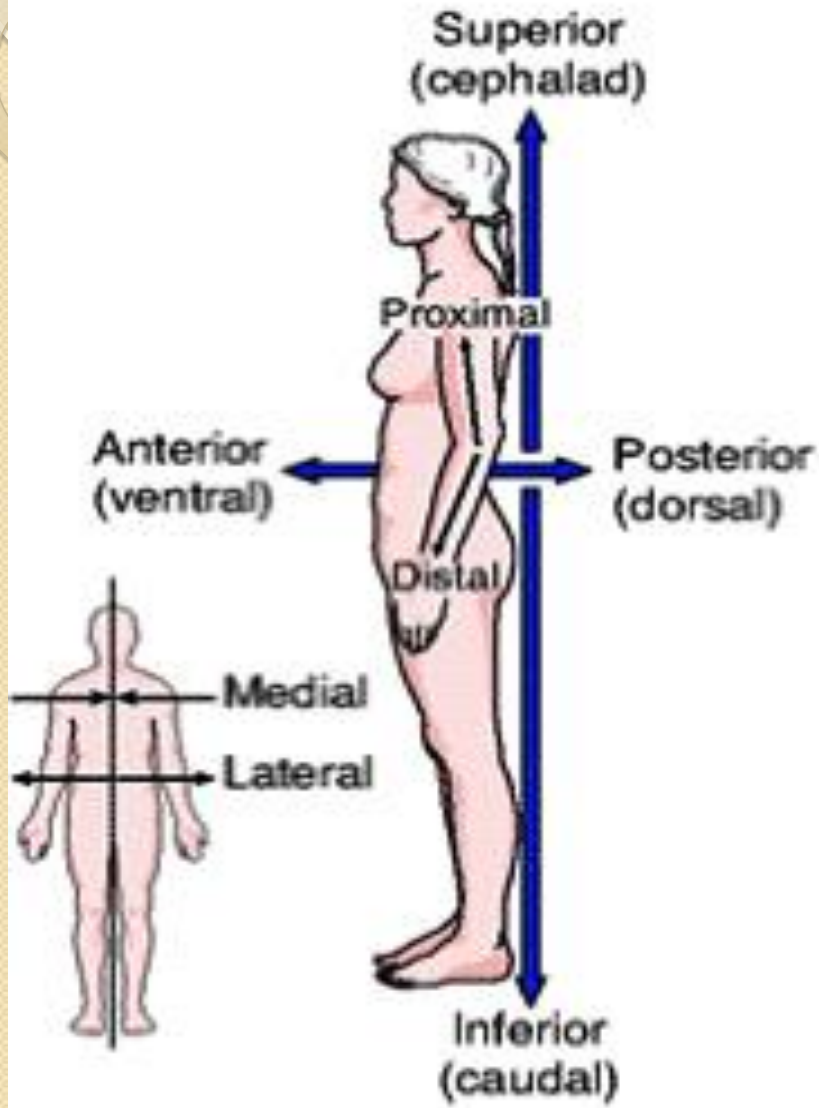

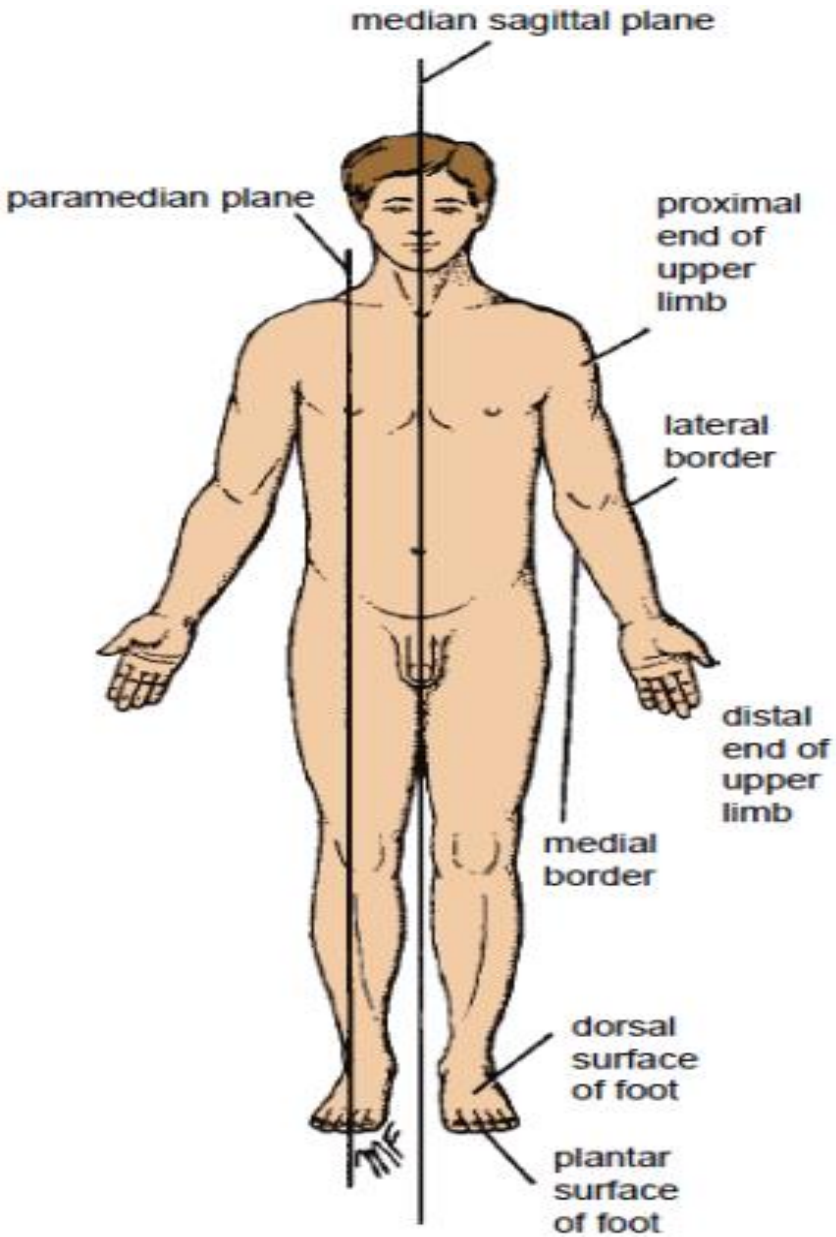

TERMS OF MOVEMENTS

Flexion : is when the ventral surfaces of forearm touching the ventral surface of the arm at the elbow joint in upper limb. In lower limb back of the leg touching the back of the thigh for example.

Extension is when two dorsal surfaces approximate or opening up of an angle, e.g. bringing arm and forearm into a straight line. In lower limb bringing the thigh and leg into straight line .

Lateral flexion: Is a movement of the trunk in the coronal plane.

Abduction is a movement of limb a way from the midline of the body in coronal plane, in relation to the movement of the fingers, the imaginary midline passes through the middle of the middle finger, move the fingers away from the middle finger. The hand moving away from the body or moving towards the radial side is called radial deviation.

Adduction bringing the part nearer to the midline, e.g. bringing the upper limb nearer to the body, move the fingers of the hand, back to touch the middle finger. When the hand moves towards the body it is called adduction or ulnar deviation.

Medial rotation—where the anterior surface of the part facing medially.

Lateral rotation is where the anterior surface of the part facing laterally.

Terms Related to Movement

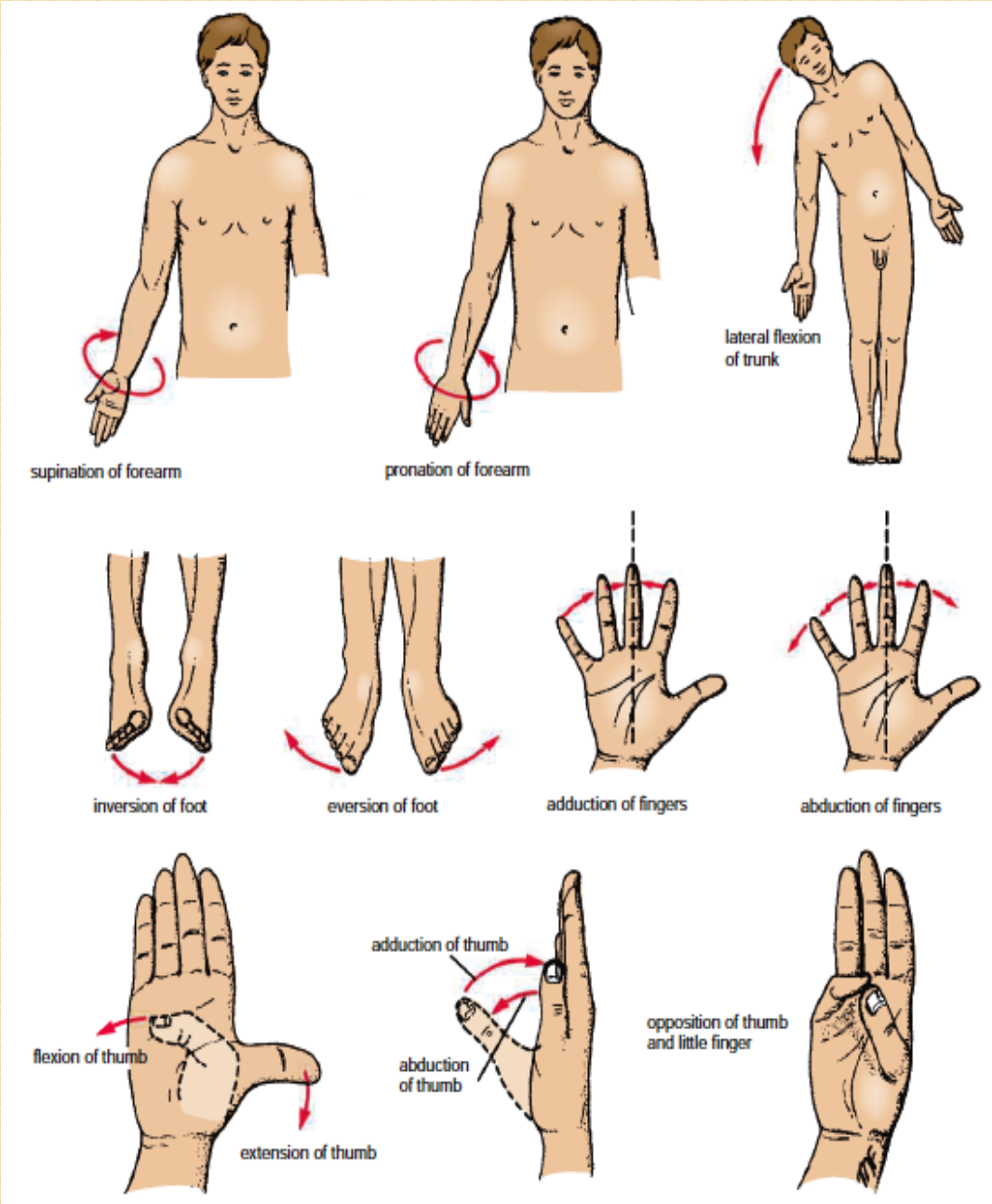

Protraction is where a part moves bodily forwards, e.g. move the shoulder forwards.

Retraction is where a part moves backwards, e.g. bracing the shoulders.

Supination of the forearm is the lateral rotation of the forearm in such manner that the palm face anteriorly. when the body is put on the table facing forwards it is said that the body is in supine position.

Pronation is where the palm faces posteriorly or where the body is put with face touching the table.

Dorsiflexion is used only in relation to foot. When the foot moves towards the front of leg it is called dorsiflexion.

Plantar flexion is when the foot is lifted off the ground with the sole facing backwards.

Circumduction is where the part moves in a circular motion , e.g. move the upper limb totally in a circular motion.(combination in sequence of the movement of flexion, extension, abduction and adduction

Opposition is a special movement of the thumb, where the thumb touches the other fingers.

Inversion: is movement of foot so that the sole faces in the medial direction

Eversion: is the opposite movement of the foot so that the sole faces in the lateral direction

Terms Related to Movement

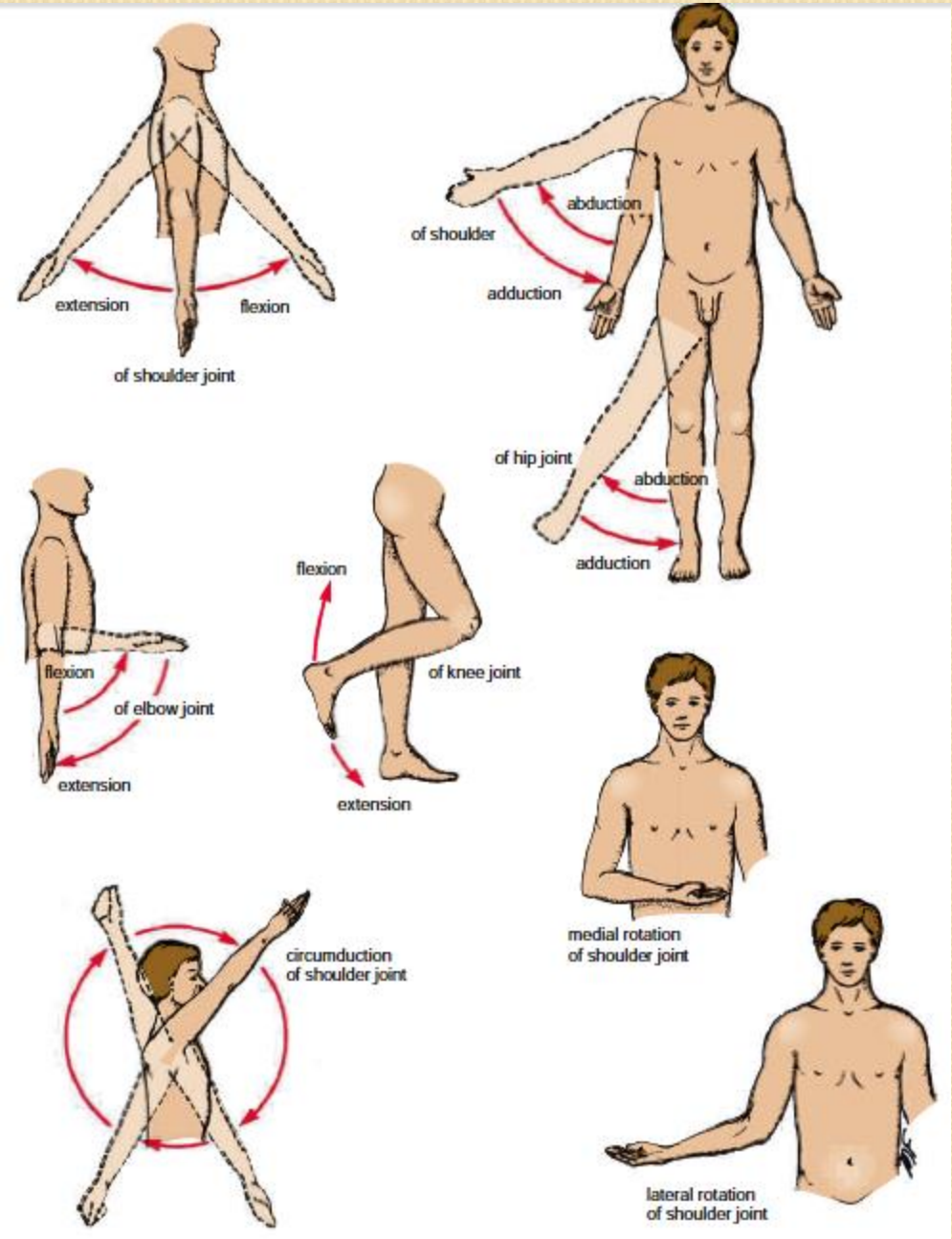

Basic structures

SKIN

- The skin is divided into two parts: the superficial part, the epidermis, and the deep part, the dermis .
- The dermis is composed of dense connective tissue containing many blood vessels, lymphatic vessels, and nerves.
- tending to be thinner on the anterior than on the posterior surface. It is thinner in women than in men.

- The skin over joints always folds in the same place, the skin creases(visible lines),also example of these lines the papillary ridges(Finger print) &wrinkles.
- Invisible line(Langer's line)or cleavage line :formed of bundles of collagen fibers in parallel rows in dermis (longitudinal in arms and circumferentially in neck and trunk. Incision along these line heal minimal scar.
- The appendages of the skin are the *nails, hair follicles, sebaceous glands, and sweat glands*.
- Hairs grow out of follicles, which are invaginations of the epidermis into the dermis .
- A band of smooth muscle, the arrector pili, connects the undersurface of the follicle to the superficial part of the dermis

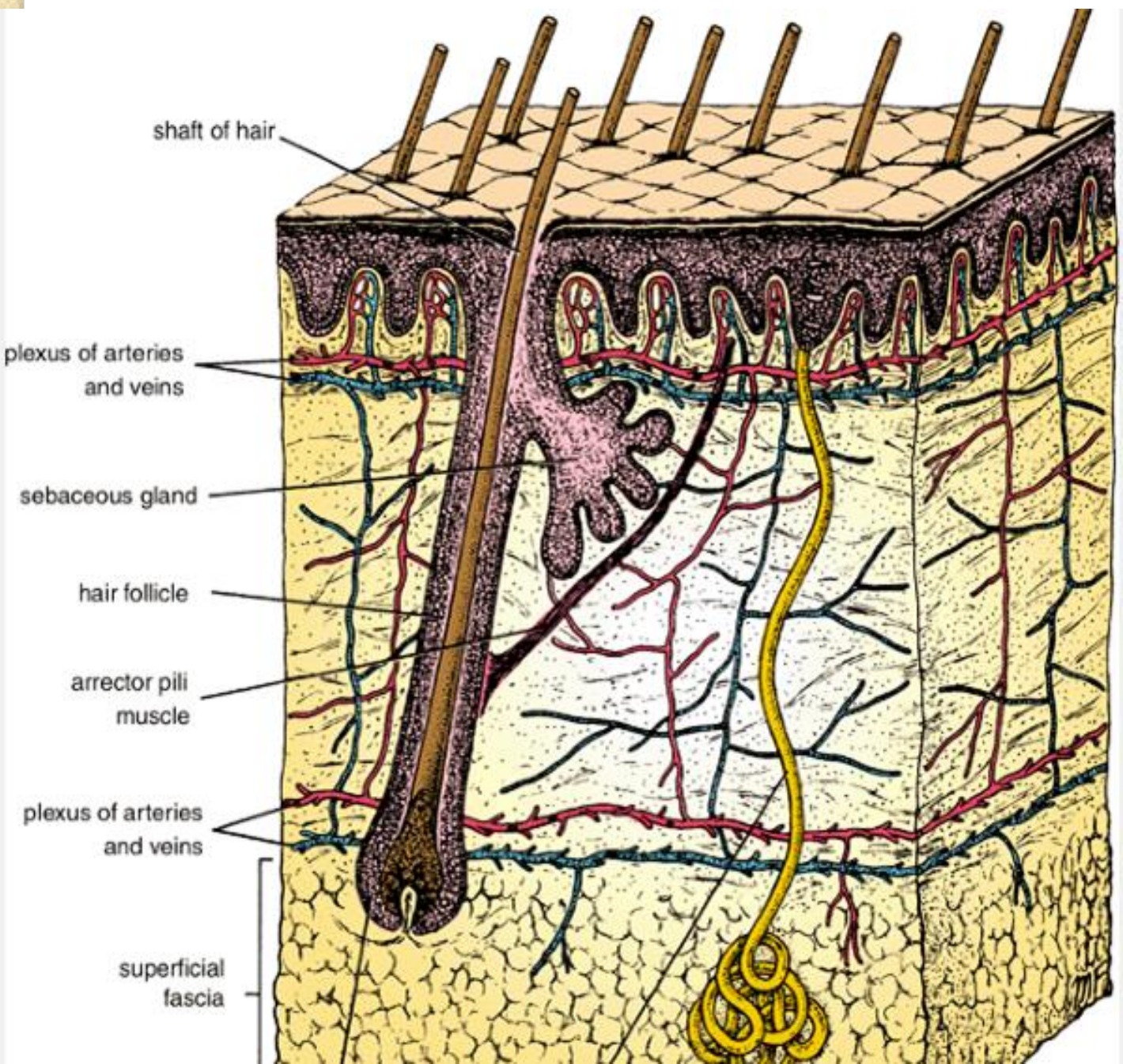
shaft of hair
plexus of arteries and veins
sebaceous gland
hair follicle
arrector pili muscle
plexus of arteries and veins
superficial fascia

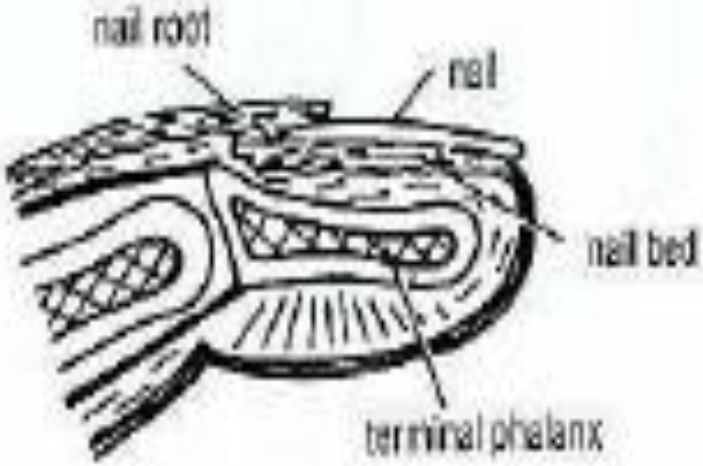

Figure 1-6 The various skin creases on the palmar surface of the hand and the anterior surface of the wrist joint. The relationship of the nail to other structures of the finger is also shown.

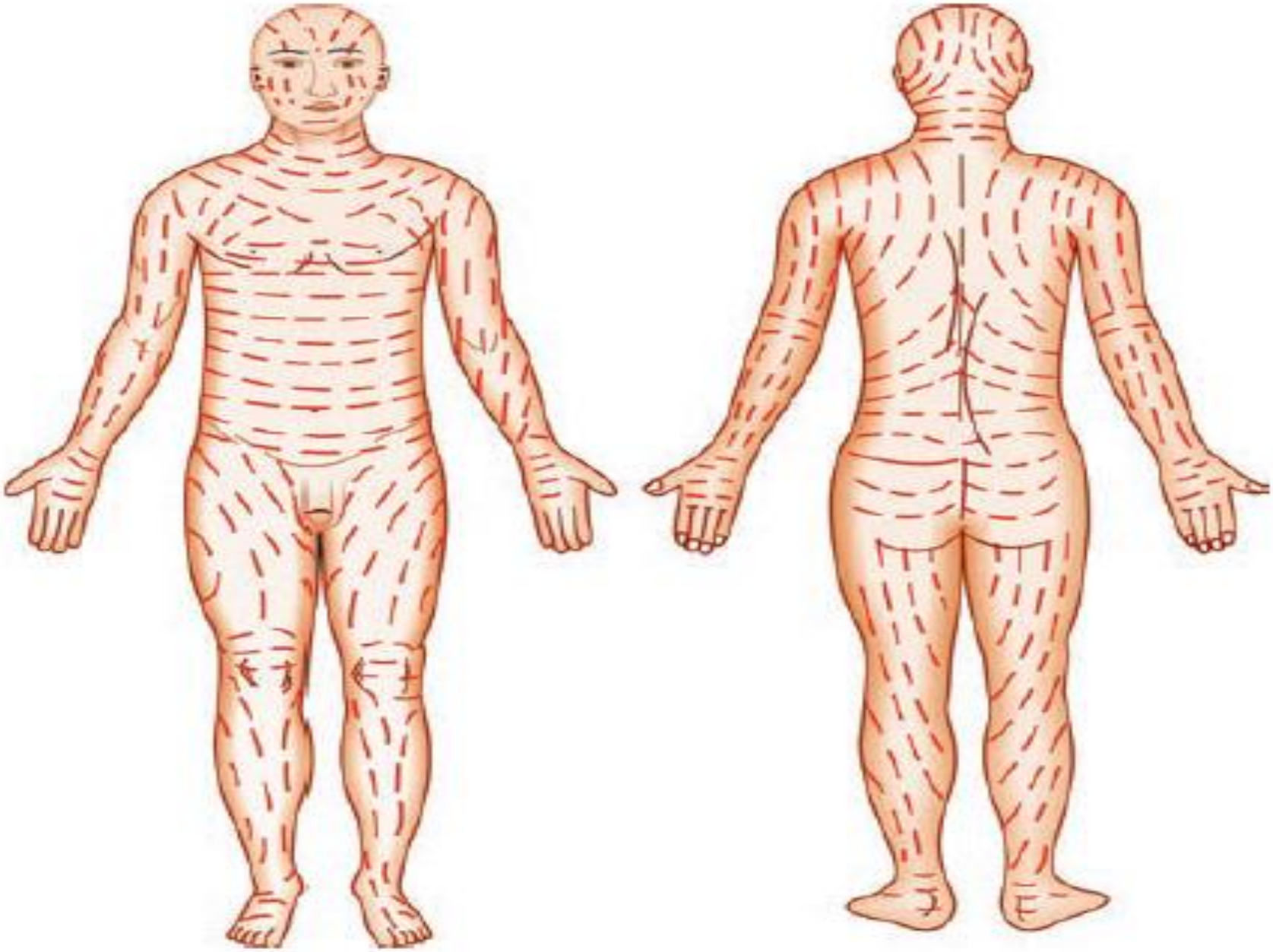

Langer's line

CLINICAL NOTES

- Skin Infections
- Paronychia.
- Boil.
- carbuncle
- Sebaceous Cyst.
- Shock
- Burns

FASCIA

- The superficial fascia, or subcutaneous tissue, is a mixture of loose areolar and adipose tissue that unites the dermis of the skin to the underlying deep fascia .
- In the eyelids, auricle of the ear, penis and scrotum, and clitoris, it is devoid of adipose tissue.
- The deep fascia is a membranous layer of connective tissue that invests the muscles and other deep structure.
- In the neck, it forms well-defined layers that may play an important role in determining the path taken by pathogenic organisms during the spread of infection.

- In thorax and abdomen it is thin areolar tissue covering the muscle and aponeuroses
- In limbs form definitive sheath surround muscles and other structure and in the interior of the limbs send fibrous septa between groups of muscle divided it to compartments
- In the region of Joint, it is thickened to form band called retinacula, holding tendon in position

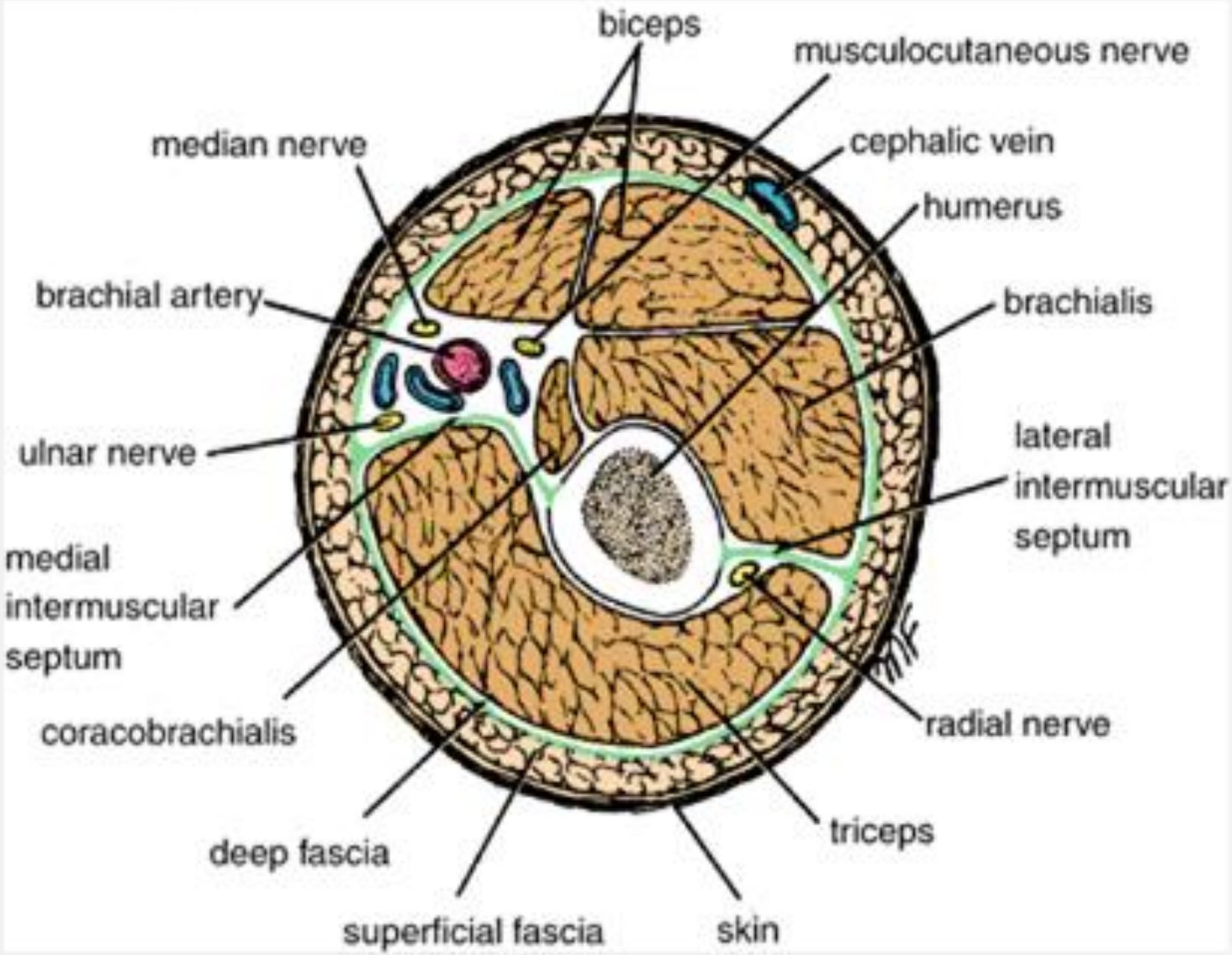
biceps
musculocutaneous nerve
median nerve
cephalic vein
humerus
brachial artery
brachialis
ulnar nerve
lateral
intermuscular
septum
medial
intermuscular
septum
coracobrachialis
radial nerve
triceps
deep fascia
superficial fascia
skin

MUSCLES

Type of muscle in the body:

- Skeletal (striated)(voluntary)(main bulk of the body 40% of body weight, total number is 620 muscles)
- Smooth (unstriated)(involuntary)
- Cardiac muscles(striated)(involuntary)

Structure of skeletal muscle

- Origin: The attachments that moves the at least(proximal, fixed attachment)
- Insertion: The attachments that moves the at most(distal, mobile attachment)
- Belly: The fleshy part of muscle
- Tendon: Is cord of fibrous tissue, binds the muscles to bone, cartilage or ligaments
- Aponeurosis: Thin strong sheath by which flattened muscles were attached.
- Raphe: is an interdigitation of the tendinous ends of fibers of flat muscles

Types of skeletal muscle according to action

1. Prime mover: Chief muscle responsible for action. e.g biceps brachii
2. Antagonist: Opposing action of prime mover.e.g.triceps
3. Fixator: Conracts isometrically to stabilize prime mover.e.g rotater cuff
4. Synergist: To prevent unwanted movement in intermediate joint. e.g carpi muscle(synergist for long flexors and extensor muscles of fingers.

Types of skeletal muscle according to shape

- Strap(parallel).e.g sartorius
- Strap with tendinous intersection.e.g rectus obdiminus
- Rhomboid.e.g rhmboid major and minor
- Quadrilateral.e.g pronator qudratus
- Traingular: e.g. deltoid
- Fusiform(spindle).e.g biceps
- Tow, three, four head. E.g biceps,triceps,quadriceps
- Pennate(feather like): it may be

  a- unipennate e.g flexor pollicis longus

  b-bipennate e.g.rectus femoris

  c-multipennate e.g deltoid(middle fibers)

  d-circumpennate e.g tibilis anterior

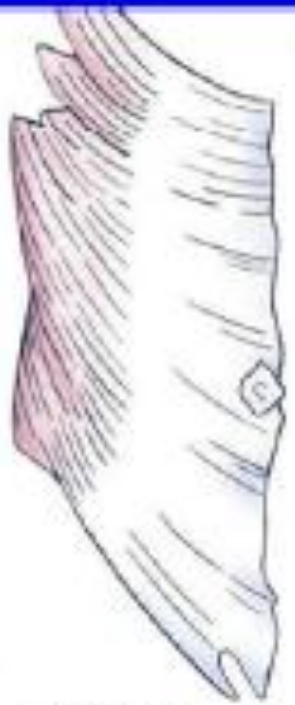

Flat muscle
with aponeurosis

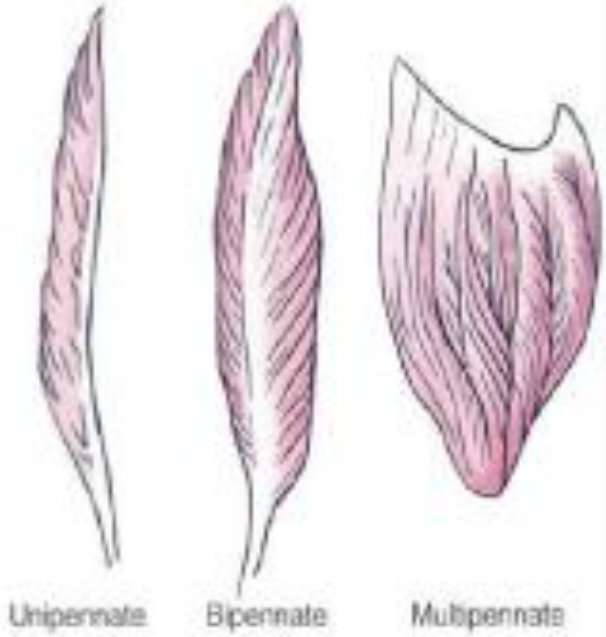

Pennate muscles

Fusiform muscle

Quadrate muscle

Circular or
sphincteral muscle

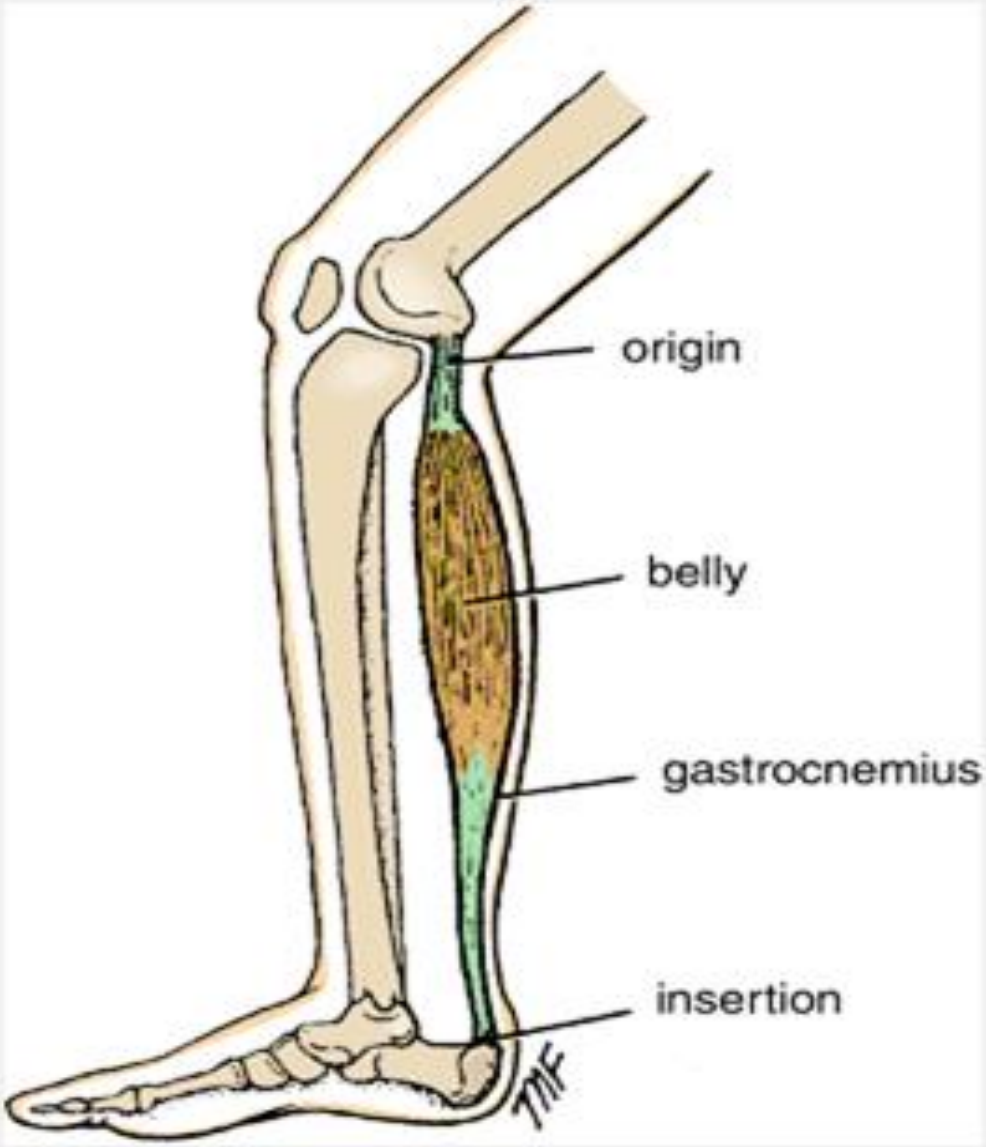
origin
belly
gastrocnemius
insertion

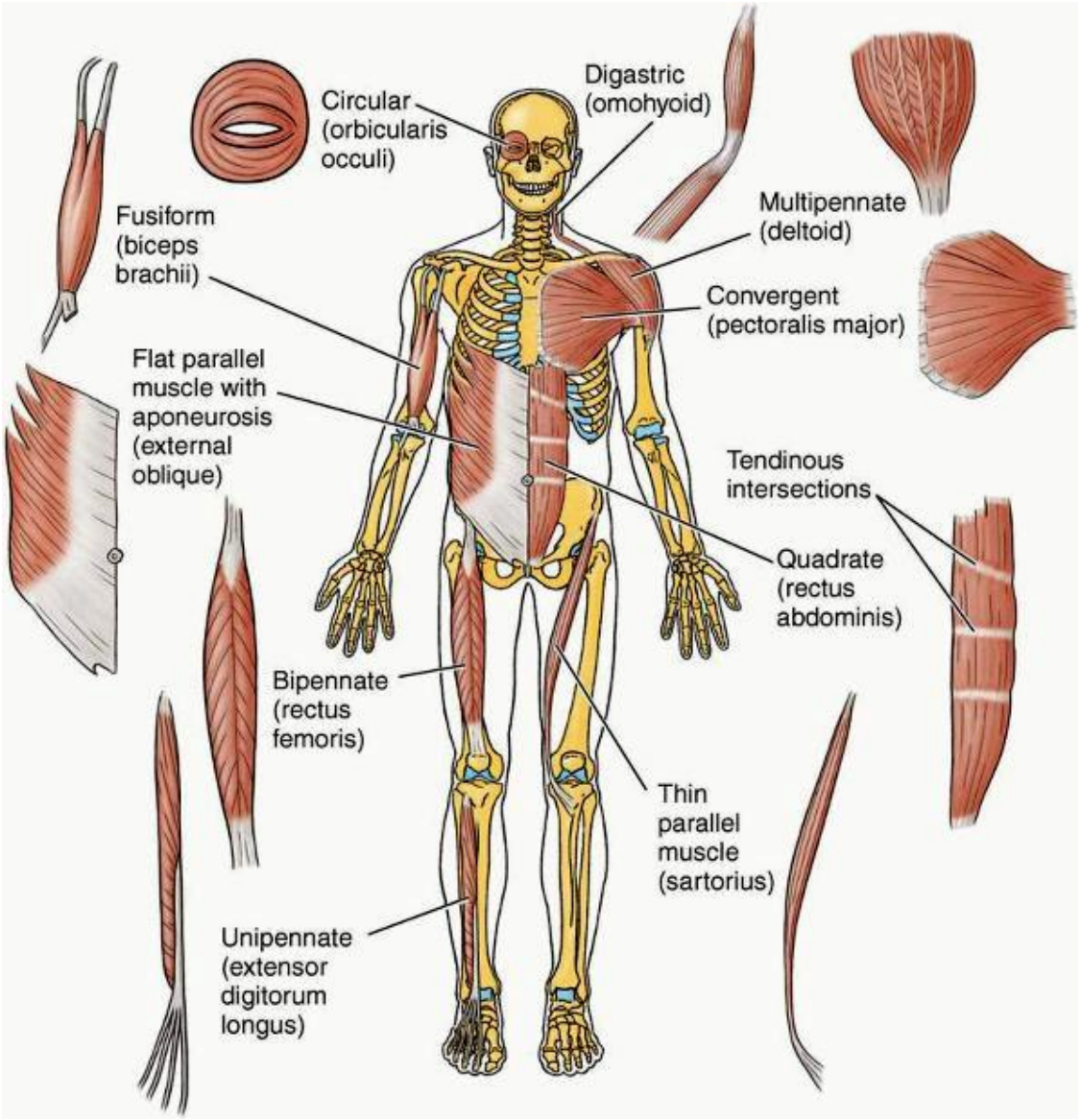
Circular
(orbicularis
occuli)
Digastric
(omohyoid)
Multipennate
(deltoid)
Fusiform
(biceps
brachii)
Convergent
(pectoralis major)
Flat parallel
muscle with
aponeurosis
(external
oblique)
Tendinous
intersections
Quadrate
(rectus
abdominis)
Bipennate
(rectus
femoris)
Thin
parallel
muscle
(sartorius)
Unipennate
(extensor
digitorum
longus)

Types of skeletal muscle according to color

- Red muscle: They contract slowly and sustain long time.e.g soleus
- White muscle: (pale):contract strongly and fatigued quickly .e.g. gastrocnemius
- Mixed muscles: Most muscles in the body are mixed

Nerve supply of skeletal muscle is mixed about 60%motor and 40% sensory with some sympathetic autonomic fibers.

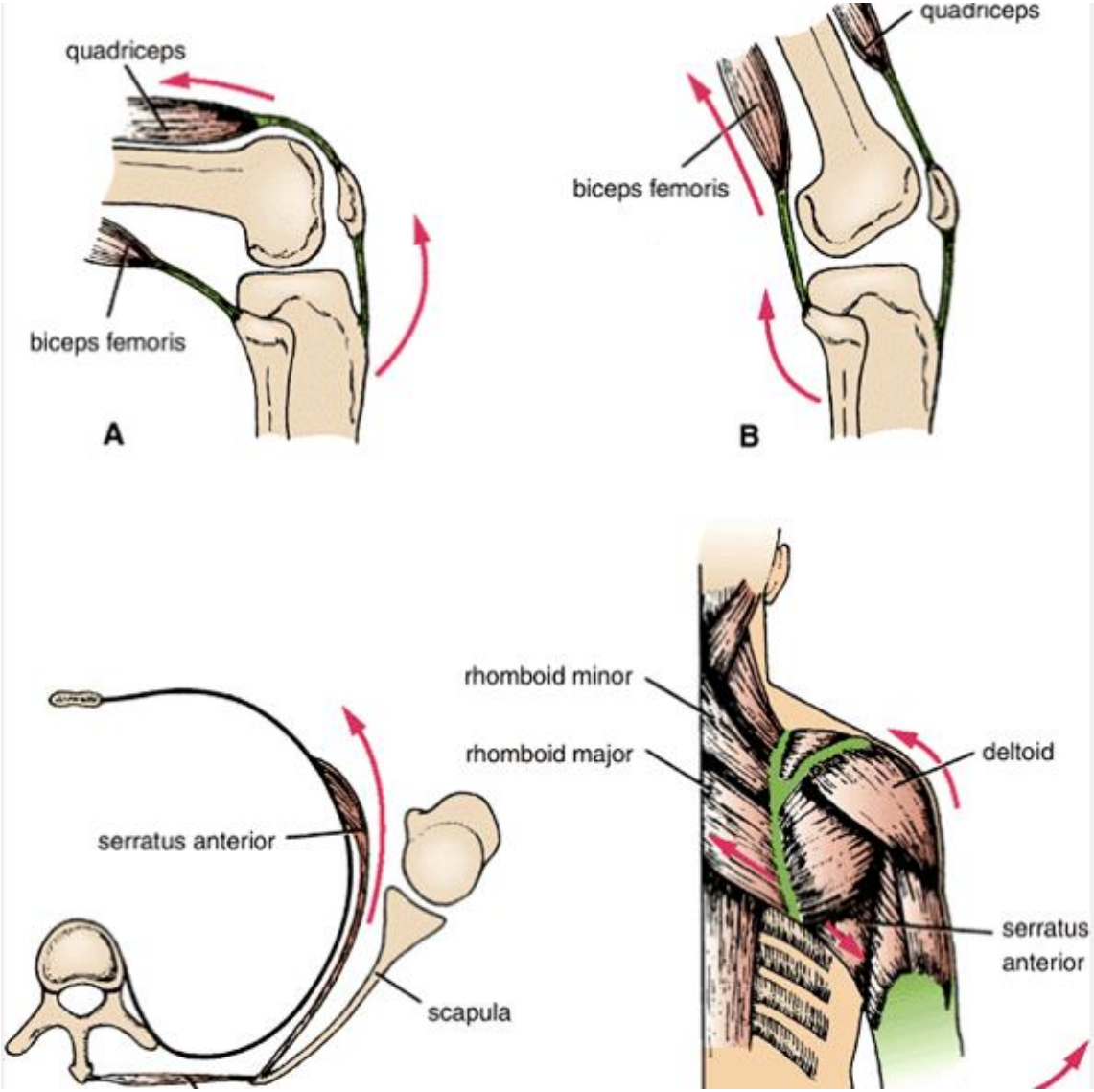
quadriceps
biceps femoris
A
quadriceps
biceps femoris
B
serratus anterior
scapula
rhomboid minor
rhomboid major
deltoid
serratus
anterior

JOINTS

- Joints are sites where two or more bones come together, whether or not movement occur between them.
- Three types according to tissues that lie between bones
- ***Fibrous joints :*** articular surface of bones joined by fibrous tissue, very little movement is possible. e.g sutures of valut of skull
- ***Cartilaginous joints***: primary C.J. the bones are united by plate of hyaline cartilage, no movement is possible(1st rib& sternum) & secondary C.J. bones are united by plate of fibrocartilage, small amount of movement is possible(vertebral bodies)
- ***Synovial joint:*** articular surface of bone are covered by a thin layer of hyaline cartilage separated by cavity which lined by synovial membrane, these membrane protected by tough fibrous membrane called capsule and articular surface are liubricated by viscous synovial fluid.

Synovia joints are classified according to arrangment of articular surfaces and the types of movement

- Plane joints: The articular surface of bones are flat. e.g. sternoclavicular j.(gliding movement)
- Hinge joint: resemble the hinge of the door. e.g. Elbow joint(flexion & extension)
- Pivot : central bony pivot surround by bony ligamentous ring and rotation movement only. e.g atlantoaxial and superior radioulnar joint
- Condyloid: two concave surface articulate with two convex surface e.g metacarpophalangeal joint.(flexion, extension, adduction, abduction and small amount rotation.
- Ellipsoid: ellipsoid concave with ellipsoid convex articular surfaces e.g. wrist joint(flexion, extension, abduction and adduction no rotation)
- Saddle: carpometacarpal joint of thumb(flexion, extension, abduction, adduction and rotation)
- Ball and socket: ball shape head of one bone fits into socket like concavity of another .e.g. shoulder joint(flexion, extension, abduction, adduction, medial & lateral rotation and circumduction)

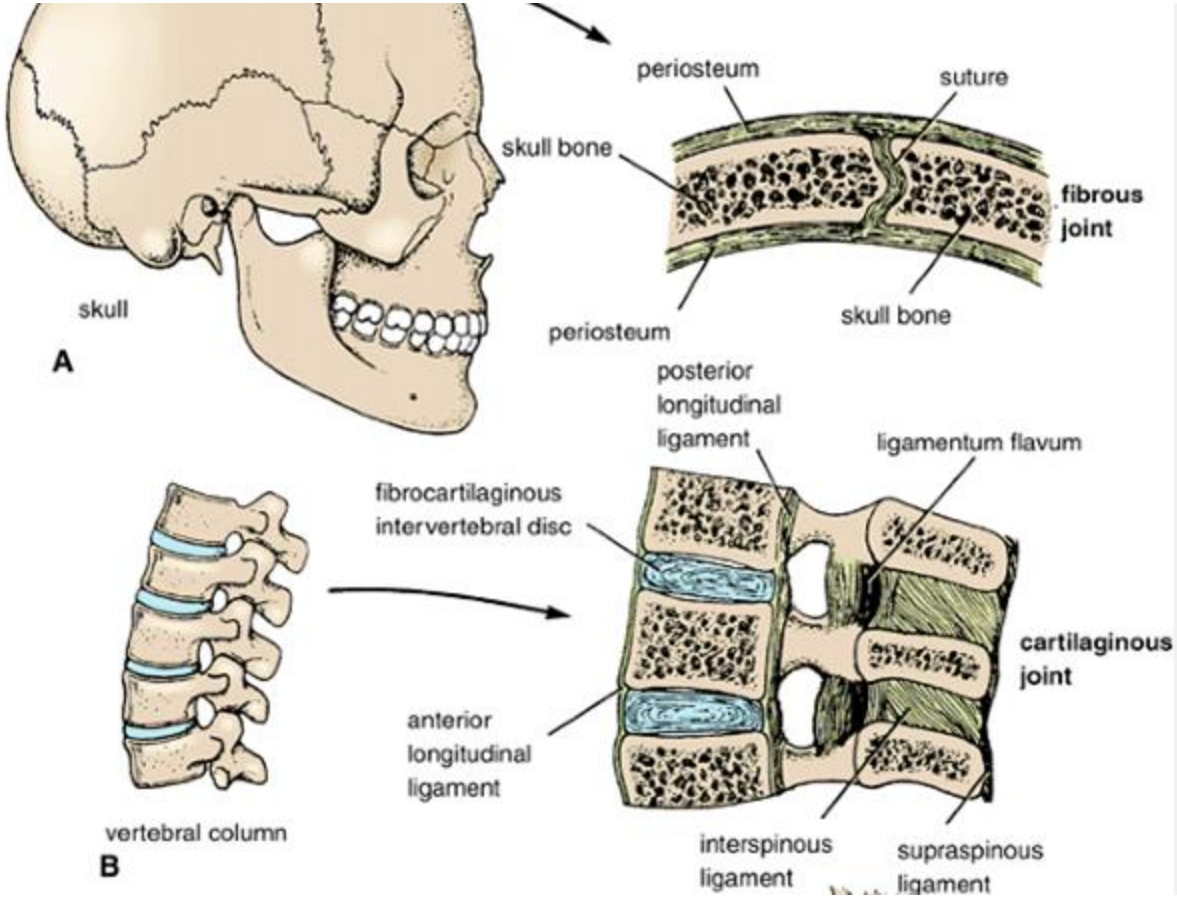
periosteum
suture
skull bone
fibrous joint
skull
periosteum
skull bone
A
posterior longitudinal ligament
ligamentum flavum
fibrocartilaginous intervertebral disc
cartilaginous joint
anterior longitudinal ligament
vertebral column
B
interspinous ligament
supraspinous ligament

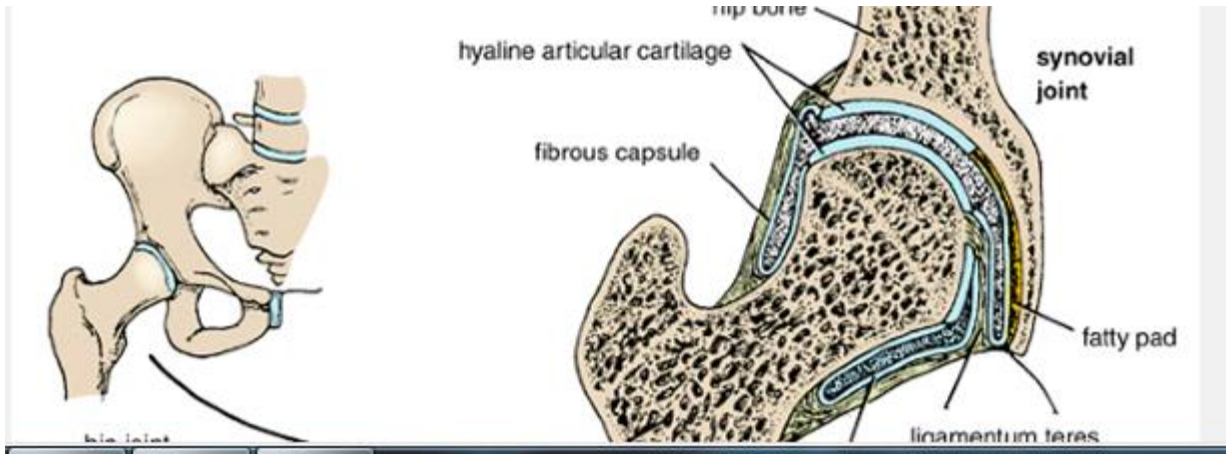
hyaline articular cartilage
synovial joint
fibrous capsule
fatty pad
ligamentum teres

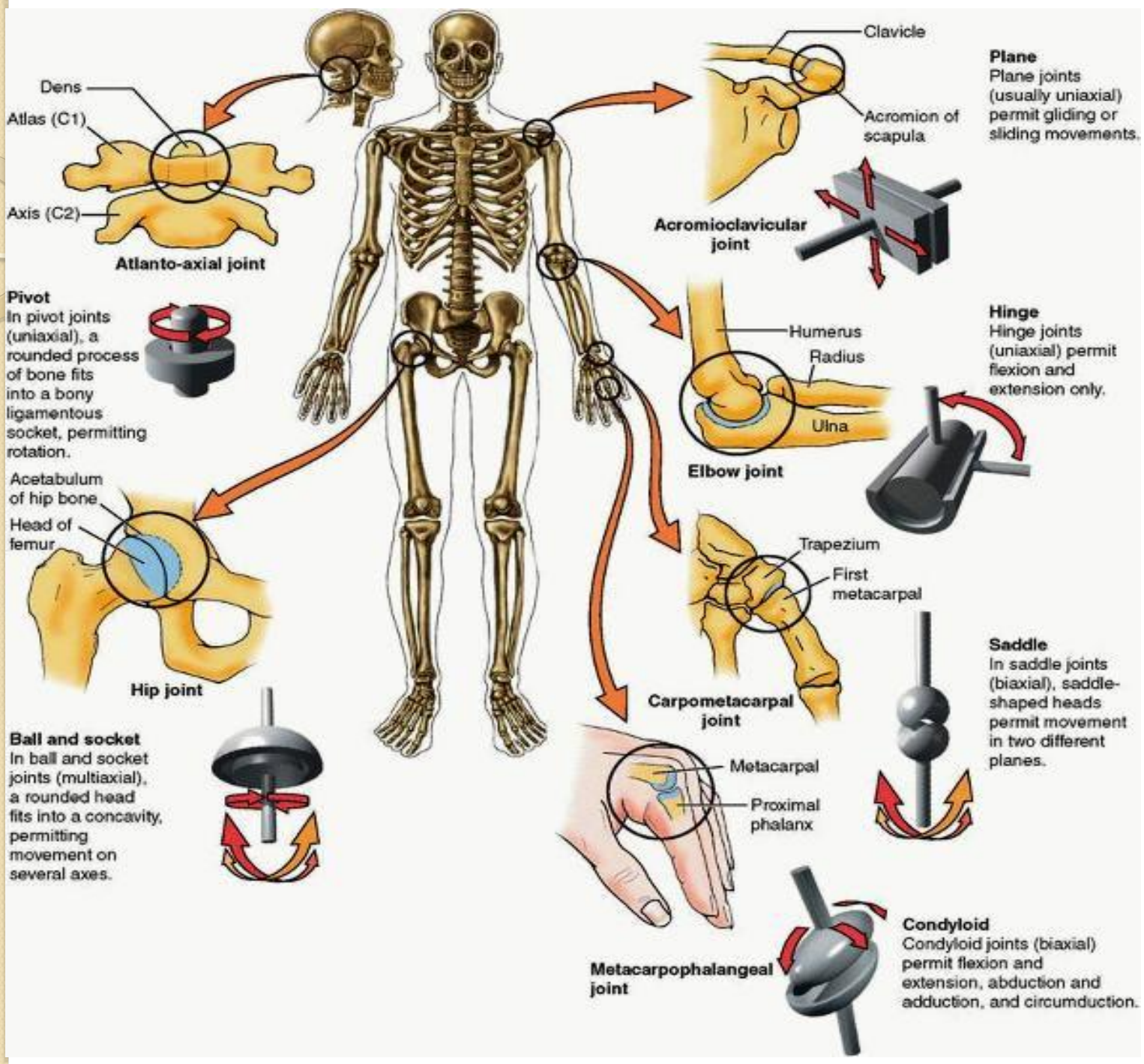
Dens
Atlas (C1)
Axis (C2)
Atlanto-axial joint
Pivot
In pivot joints (uniaxial), a rounded process of bone fits into a bony ligamentous socket, permitting rotation.
Acetabulum of hip bone
Head of femur
Hip joint
Ball and socket
In ball and socket joints (multiaxial), a rounded head fits into a concavity, permitting movement on several axes.
Clavicle
Acromion of scapula
Acromioclavicular joint
Plane
Plane joints (usually uniaxial) permit gliding or sliding movements.
Humerus
Radius
Ulna
Elbow joint
Hinge
Hinge joints (uniaxial) permit flexion and extension only.
Trapezium
First metacarpal
Carpometacarpal joint
Saddle
In saddle joints (biaxial), saddle-shaped heads permit movement in two different planes.
Metacarpal
Proximal phalanx
Metacarpophalangeal joint
Condyloid
Condyloid joints (biaxial) permit flexion and extension, abduction and adduction, and circumduction.