Advanced trauma life support (ATLS)

Causes of severe trauma

- Blunt trauma (RTA) especially of motor vehicles.
- Penetrating trauma: bullet, stab wound.
- Blast injury
- Crush injury: associated with rhabdomyolysis and acute renal failure. Prolong crushing of muscle mass causes muscle cells death and release of myoglobin and vasoactive mediators to circulation and the injuried muscle will sequestrated many liters of fluid, reducing the effective intravascular volume which result in renal vasoconstriction and ischemia.
- Thermal injury as in burn and frost bite.
- Alcohol and drug abuse

Death from trauma has a trimodal distribution.

(I) The first peak: occur within seconds or minutes of the injury. deaths are due to

- lacerations of the brain, brainstem, upper spinal cord, heart, aorta, or other large vessels. Few of these patients can be saved.

(II) The second death peak: occurs within the first few hours after injury. The period following injury has been called the "**golden hour**" because these patients may be saved with rapid assessment and management of their injuries (ATLS).

Death is usually due to airway compromise, central nervous system (CNS) injury or hemorrhage.

(III) The third death peak occurs days or weeks after the injury and is usually due to sepsis, multiple organ failure, or pulmonary embolism.

Triage

Process of determining the priority of patients treatments based on the severity of condition and facilities available.

Glasgow Coma Scale

The Glasgow Coma Scale (GCS) was developed in 1974 by Teasdale and Jennet. It was the first attempt to quantify the severity of head injury. The three variables included were best motor response, best verbal response, and eye opening.

Best motor response is a reflection of the level of CNS function, best verbal response shows the CNS's ability to integrate information, and eye opening is a function of brainstem activity. Scores range from 3 to 15. The use of the letter *T* designates that the patient was intubated at the time of the examination.

Table **Glasgow Coma Scale**

Action	*Score*
Eye opening	
Spontaneously	4
To speech	3
To pain	2
None	1
Motor response	
Obeys	6
Localizes pain	5
Withdraws from pain	4
Flexion to pain	3
Extension to pain	2
None	1
Verbal response	
Oriented	5
Confused	4
Inappropriate	3
Incomprehensible	2
None	1

Adapted from Teasdale G and Jennett B.[9]
Patient's score determines category of neurologic impairment: 15 = normal; 13 or 14 = mild injury; 9–12 = moderate injury; 3–8 = severe injury.

Stages of ATLS

- **Primary Survey: ABCDEs**
- **Secondary Assessment**
- **Tertiary survey**

Primary Survey:

During the primary survey, life-threatening conditions are identified and reversed quickly.The primary survey progresses in a logical manner based on the ABCDEs: *airway* maintenance with cervical spine control, *breathing and adequate ventilation, and circulation* with control of hemorrhage, disability, exposure

Airway Maintenance with Cervical Spine Control

Ensuring an adequate airway is the first priority in the primary survey. Patients who are conscious and have a normal voice do not require further evaluation to their airway except patients with penetrating injuries to the neck and an expanding hematoma.

Patients who have an abnormal voice or altered mental status require further airway evaluation. Means of airway maintenance are

- Oxygen supply
- Position: lateral position except if there is suspected cervical injury
- Clear of mouth from secretion and foreign bodies by using gloved finger in sweepimg motion and/or sucker.
- Jaw thrust and chin lift. The jaw thrust procedure requires the placement of both hands along the ascending ramus of the mandible at the mandibular angle. The fingers are placed behind the inferior border of the angle, and the thumbs are placed over the teeth or chin. The mandible is then gently pulled forward with the fingers at the angle and rotated inferiorly with pressure from the thumbs. The jaw thrust procedure is the safest method of jaw manipulation in a patient with a suspected cervical injury.
  The chin-lift procedure is performed by placing the thumb over the incisal edges of the mandibular anterior teeth and wrapping the fingers tightly around the symphysis or the mandible. The chin is then lifted gently anteriorly and the mouth opened, if possible.
- Glossopexy
- Disimpaction of fractured maxilla
- Oral or nasopharyngeal airway
- Endotracheal intubation
- Tracheostomy or cricothyroidotomy if previous measures fail to establish adequate airway

Cervical spine protection

With any patient sustaining injuries above the clavicle, one should assume there may be a cervical spine injury and avoid hyperextension or hyperflexion of the patient's neck during attempts to establish an airway.

Maintenance of the cervical spine in the neutral position is best achieved with the use of a backboard or collar.

Radiograph (C1-7 and T1) should be taken to rule out such injury.

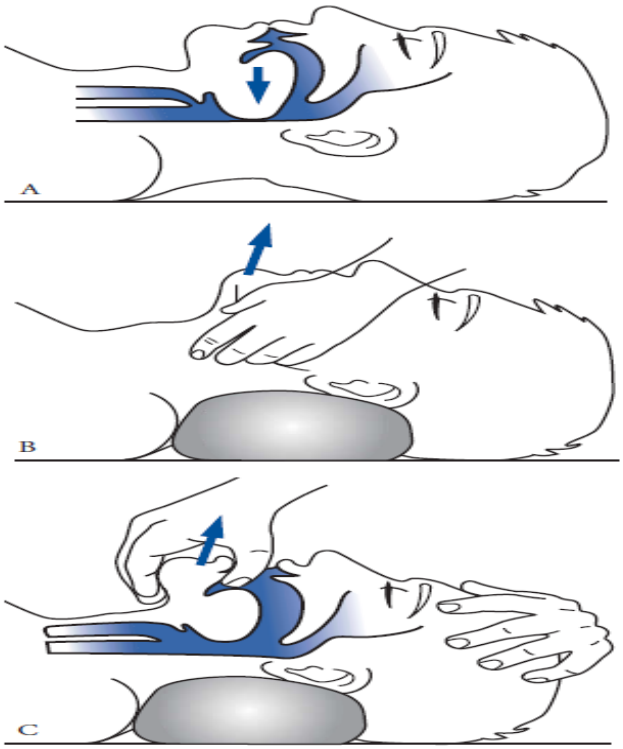

FIGURE 18-3 A, *Commonly in the unconscious patient, the tongue drops posteriorly to occlude the airway. This may be especially true in the patient with mandibular fractures because the tongue loses support. A patient with a suspected maxillofacial or head trauma must have the head stabilized at all times to prevent hyperflexion of an injured cervical spine until the possibility of injury has been ruled out.* B, *With the cervical spine stabilized, a jaw-thrust may be used.* C, *A Chin-lift procedure also may be helpful to open the airway. Adapted from Powers M.*[15]

Breathing

With establishment of an adequate airway, the pulmonary status must be evaluated. If the patient is breathing spontaneously, confirmed by feeling and listening for air movement at the nostrils and mouth— supplemental oxygen may be delivered by face mask.
If the patient is not breathing after establishment of an airway, artificial ventilation should be provided with a bag-valve mask or a bag attached to an endotracheal tube.

Chest injuries that compromise ventilation are

- Open pneumothorax due to a defect in the chest wall, allowing the air to be moved in and out of the pleural cavity with each respiration
- Tension pneumothorax develops when the injury acts as a one-way valve through the chest wall or from the lung into the pleural cavity without equilibration with the outside atmosphere
- Hemothorax is the collection of blood in the pleural cavity. When > 1.5 litre of blood with mediastinal shift, lung collapse and hypovolemic shock, all are considered surgical emergency.
- Flail chest results when there are multiple rib fractures, usually at several sites along the rib. The resulting unstable segment of chest wall moves paradoxically during respirations—inward with inspiration and outward with expiration
- Cardiac temponade is collection of blood in pericardium.

These are immediate life-threatening conditions and should be quickly identified and treated. Diagnosis of these life-threatening conditions is made on the combination of the following clinical signs and radiographical appearances

Clinical signs:

- Deviated trachea
- Absence of breath sounds in one hemithorax
- Dullness on percussion over one or both lung bases
- Muffled heart sounds

Radiographical findings

- Loss of lung markings
- Deviated trachea
- Raised hemidiaphragm
- Fluid level

Management: Require drainage with chest drain placed in 4th intercostal space anterior to midaxillary line. In case of cardiac temponade, use of spinal needle to decompress the pericardium.

Circulation

The cardiovascular system of the patient must be assessed and control of baseline circulation to the tissues must be quickly restored.

A rough first approximation of the patient's cardiovascular status is obtained by palpating peripheral pulses. External control of hemorrhage should be obtained before restoring circulating volume.

Manual compression and splints frequently control extremity hemorrhage as effectively as tourniquets. Digital control of hemorrhage for penetrating injuries of the head, neck, thoracic outlet, groin, and extremities is important. Scalp lacerations through the galea aponeurotica tend to bleed profusely; these can be controlled temporarily with Rainey clips or a full-thickness large nylon continuous stitch.

Intravenous access for fluid resuscitation is begun with two peripheral Catheters. Blood is drawn simultaneously and sent for typing and hematocrit measurement

Initial fluid resuscitation is a 2-L intravenous bolus of isotonic crystalloid in an adult or 20 mL/kg of body weight lactated Ringer's solution in a child. Effectiveness of resuscitation is assessed by improvement in patient condition and UOP. Foley catheter and nasogastric tube are used during this phase

The goal of fluid resuscitation is to reestablish tissue perfusion. Classic signs and symptoms of shock are tachycardia, hypotension, tachypnea, mental status changes, diaphoresis, and pallor. None of these signs or symptoms taken alone can predict the patient's organ perfusion status.

Skin perfusion is the most reliable indicator of poor tissue perfusion during the initial evaluation of the patient. The early physiologic compensation for volume loss is vasoconstriction of the vessels to the skin and muscles.

The location of the pulse may give some indication of the cardiac output. Generally,

if the radial pulse is palpable, the patient's systolic blood pressure is > 80 mm Hg; if the femoral pulse is palpable, the patient's systolic blood pressure is 70 mm Hg or higher; and if the carotid pulse is noted, the systolic blood pressure is > 60 mm Hg

DISABILITY

A brief neurologic evaluation is performed to establish the patient's level of consciousness and papillary size and reaction. A lack of consciousness with altered pupil reaction to light requires an immediate CT scan of the head and management with mannitol or fluid restrictions.

The Committee on Trauma of the American College of Surgeons recommends the use of the mnemonic AVPU. In this system, each letter describes a level of consciousness in relation to the patient's response to external stimuli: *a*lert, responds to *v*ocal stimuli, responds to *p*ainful stimuli, and *u*nresponsive.

A more detailed quantitative neurologic examination is part of the secondary survey of the trauma patient. The primary survey establishes a baseline.

Exposure of the Patient

The patient should be completely disrobed so that all of the body can be visualized, palpated, and examined for injuries or bleeding sites. At the same time patient must be protected from hypothermia.

Secondary survey

The secondary assessment does not begin until the primary assessment has been completed and management of life-threatening conditions has begun.

The patient is examined in a systematic fashion to identify occult injuries. The secondary assessment includes a subjective and objective evaluation of the injured patient.

A subjective assessment should include a brief history of the patient by AMPLE system (A: allergy, M: medications, P: past-medical history or pregnancy, L: last meal, E: events related to incident)

The objective assessment should involve inspection, palpation, percussion, and auscultation of the patient from head to toe. Special procedures such as peritoneal lavage, radiographic studies, and further blood studies may be done at this time.

Tertiary survey

Definitive care, review and re-examination of patient at intensive care unit to identify any missed injuries.

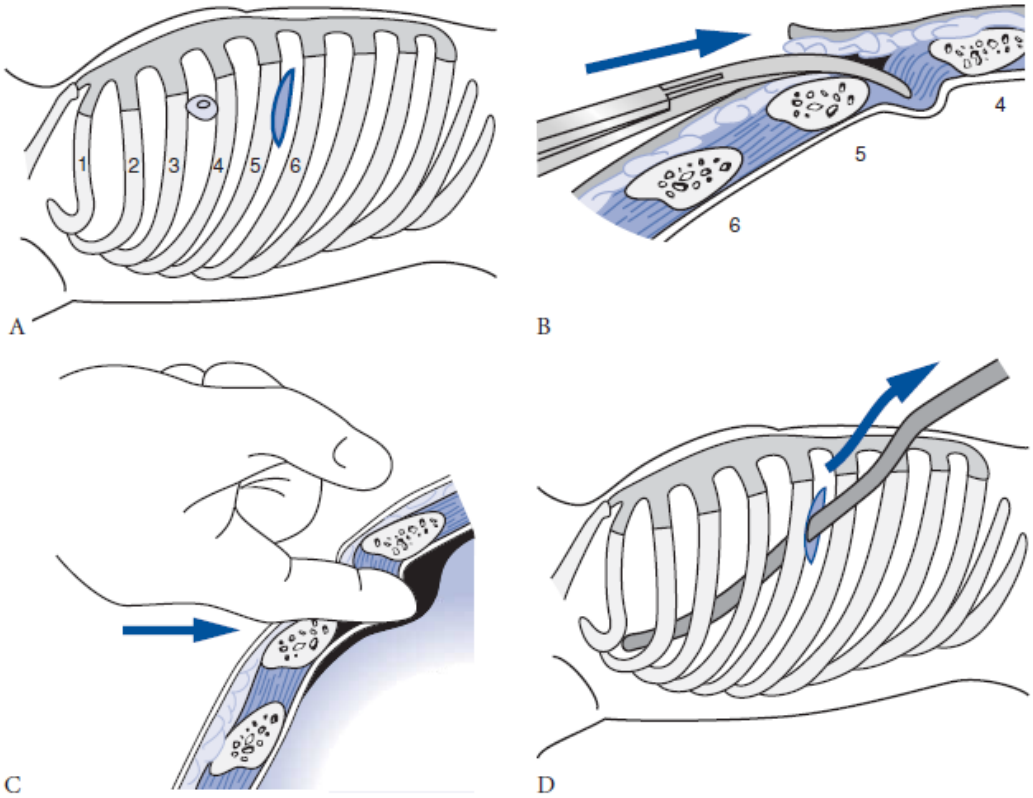

FIGURE 18-5 *Chest tube placement. The patient should be supine with the arm positioned superiorly to assist with access to the midaxillary line.* A, *An incision is made through the skin and subcutaneous tissue along the inferior aspect of the fifth rib.* B, *A large Kelly clamp is used, with the tips placed inferiorly, to bluntly dissect over the fifth rib into the intercostal space between the fourth and fifth ribs.* C, *A gloved finger should be used to enter the pleural space to avoid possible laceration of structures, within the pleural space, such as the lung, or possible disruption of abdominal contents in case of a ruptured diaphragm.* D, *The chest tube is then passed along the finger, superiorly and posteriorly within the pleural cavity. The tube should be secured to the chest with sutures, covered with an occlusive dressing, and then connected to an underwater sealed drainage, which creates suction, following verification of tube position by chest radiographs. Adapted from Powers M.*[15]

Case history and clinical examination

The art of taking accurate case history is probably the most important single step in the diagnosis of a medical or surgical condition.

A case history may be divided into:

I. The patient name, age, occupation and address
II. Chief complaint
III. History of present illness
IV. Medical, social, dental and family history.

- Cc: The nature and duration of the presenting symptoms should be considered briefly in one- or two-word summary,e.g. abdominal pain, nausea and vomiting.

- HPI: what was the first thing that he noticed wrong?
what other symptoms have occurred?
what make it better or worse?
what seems to be the main trouble now?
what treatment has he had and does it help?
what does the patient think he is suffering from?
ask about: (appetite, weight, bowl habits, sleep, dypnea, chest pain or swollen ankles).

-Medical Hx: inquire of the patient what diseases, operations or accidents he has sustained and list them in chronological order .Always give the dates and do not write 'three years ago' ….ect.

-Family Hx: Health and medical status of patient relatives should be asked.

-Social history: this part of history enables the physician to build up a picture of patient background like smoking, drinking alcohol and occupation.

Clinical examination:

After accurate case history has been taken, the clinical examination is carried out. This consists of:-

1- General physical examination of the patient using the principles of examination (inspection, palpation, percussion, auscultation).

2- Local examination of the lesion which carefully elicits all its clinical characteristics.

Clinical examination of patient with a pain

Pain anywhere should have the same features elicited. These can be summarized by the acronym SOCRATES.

- Site :where is the pain, is it localized or generalized?
- Onset : Gradual or sudden?intermittent or generalized?

- Character: Sharp, stabbing, dull, aching, sore?
- Radiation : Does it spread to other areas?(from loin to groin in ureteric pain, to jaw and neck in myocardial pain)
- Associated symptoms: Nausea, vomiting, dysuria, jaundice?
- Timing: Does it occur at any particular time?
- Exacerbating or relieving factors: relief with hot water bottles suggest deep inflammatory or infiltrative pain.
- Surgical history: Does the pain relate to surgical intervention.

- **Other common surgical symptoms:** dyspepsia, dyspnoea, dysphagia, haematemesis, haemoptysis, abdominal distension, jaundice, change in bowel habit

The examination of lump

Before carrying out a local physical examination of any lump or mass, it is essential to ascertain:-

- How long the swelling has been present?
- Whether it is getting larger?
- Whether there is any possible cause for swelling,i.e., trauma.

The features of lump that should be considered can be remembered by acronym (4 students and 3 teachers around the campfire):-

- Site: the lump may arise from skin, s.c. , muscle, tendon, BV., nerves or organ. The lump must be described with reference to the body surface landmarks,e.g. angle of mandible.
- Size
- Shape
- Surface: of the mass may be smooth, lobulated or irregular.
- Tenderness: on gentle palpation is valuable physical sign. Inflammatory lumps are tender while neoplasms are painless unless secondarily infected.
- Temperature: the site of acute inflammation is usually warmer than the adjoining areas.
- Transillumination: Whether a torch behind lump will allow light to shine through the lump. The only readily transilluminable swelling of the head and neck is the cystic hygroma .
- Consistency and color: the consistency of lump is defined surgically as Soft as in lipoma , Firm as in fibroma , Cartilage Hard as in pleomorphic adenoma, Bony hard as in osteoma, Rock hard as in malignant lymph nodes, Rubbery hard as in hodgkin lymphoma.

The color of lump may be helpful diagnostic sign like reddening msy suggest inflammatory aetiology.

- Appearance of patient: massive swellings associated with cachexia of the patient are usually indicative of malignant neoplasms.

- Mobility: Move lump in two directions, right-angled to each other. Then repeat exam when muscle contracted:

a) Bone: immobile.
b) Muscle: contraction reduces lump mobility.
c) Subcutaneous: skin can move over lump.
d) Skin: moves with skin

- Pulsation: Assess with 2 fingers on mass, there are three types of pulsation which may occur in lumps:

a) The mass may be pulsatile : aneurysm
b) Transmitted pulsation occur when the mass rests on a large artery,e.g. palatal adenoma of the palate which transmit pulsation of greater palatine artery.
c) A mass lying deep in the tissue may displace artery so that it lies superficially upon the mass.

- Fluctuation: indicate presence of fluid within the lump. It is elicited by placing the tips of two fingers on the lump. When pressure is applied to the mass with one finger, transmitted upward impulse is felt with the other finger-tip.
- Reducibility: Reducible mass reappears only on cough,e.g. hernia.
- Regional lymph nodes
- Edge: of the lump may be clearly defined or diffuse, fading into the surrounding tissues as in inflammatory lumps.

Examination of ulcer

Is a discontinuity or break in a skin or mucous membrane .

Classification:

1. Venous
2. Arterial
3. Diabetic
4. Neuropathic
5. Traumatic
6. Malignant
7. Infective

Before carrying out any local examination of an ulcer, ascertain whether : any known exciting factor + duration of ulcer.

A) Inspection: we should note

1) Size & Shape (ulcer may be round, oval, crescentic, irregular in shape)

2) Number

3) Location: many ulcers occur in characteristic sites.

- Varicose ulcer → medial aspect of lower third of the leg
- Rodent ulcer → nose
- Squamous cell carcinoma ulcer ⟶ tongue
- Tuberculous ulcer → neck

- Syphilis ⟶ junction of hard and soft palate
- Trophic ulcer → weight-bearing area (e.g. heel of the feet)
- Bedsore ulcer→ sacrum

4) Floor: is the exposed surface of the ulcer. We should note:-

- ❖ The granulation tissue (this may be red, pale), amount of sloughing (necrotic tissue not yet separated from living tissue), membrane..ect.
- ❖ Discharge: which may be
- ❑ Serous (plasma that's thin, clear and watery),
- ❑ Serosanginous (This leakage is thin and watery, and it's pink in color (it can also be a darker red),
- ❑ Sanginous (fresh blood)
- ❑ Purulent. (gray, green or yellow, and purulent drainage is most commonly thick in consistency)

5) Margin & Edge: ***Margin*** *is the border or transitional zone of skin around an ulcer*. There are three types:

-Healing margin [white (outer) – blue (central) – red (Inner)]

-Inflamed margin (red, irregular margin with inflamed surrounding skin)

-Fibrosed margin (thickened white)

Edge *is the mode of union between the floor and the margin of* ulcer. There are five types: (see figure below)

o Sloping edge → healing ulcer

o Punched edge → trophic ulcer, syphilis

o Undermined edge → tuberculous ulcer

o Everted edge→ malignant ulcer

o Raised (rolled) edge → basal cell carcinoma (rodent ulcer).

6) Surrounding skin: if ulcer is spreading and infected the surrounding skin is shiny, red, edematous due to cellulitis.

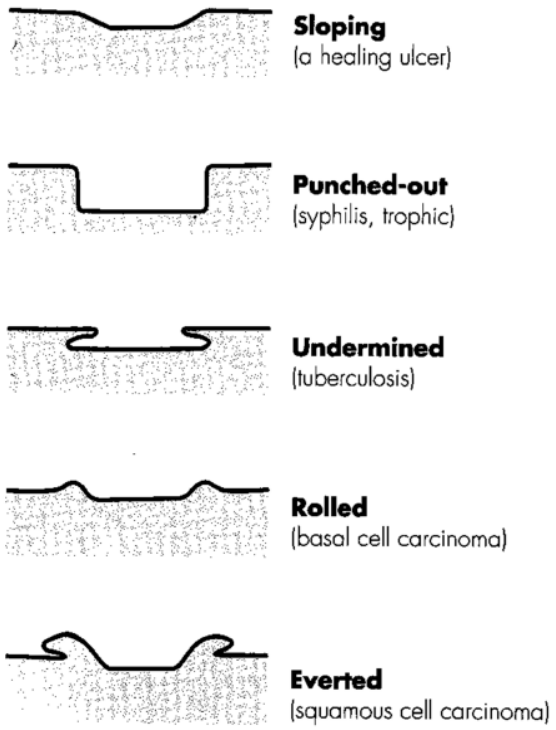

FIG 1.15 The varieties of ulcer edge.

B)Paplation

1) Surrounding skin for temperature and tenderness.
2) Ulcer: edge, base
3) Test the fixity of the ulcer to the structures in its base.

Base (tissue on which the ulcer rests): note
• Consistency (soft, indurated or fixed)
• Underlying structures (muscle, fascia or bone).

C) Focal examination

1. Regional Lymph node,e.g.
• Hard, discrete, non-tender → malignant ulcer
• Soft, tender → infective
• Non-tender, matted → tuberculous ulcer
2. State of arteries, venous circulation, nerves
3. Movement of neighboring joints

D) Systemic examination

• CVS: for CHF which delays ulcer healing
• R.S: for TB .

Wound Healing

Wound healing involves three overlapping phases :
1- Inflammation,
2- Proliferation
3- Remodelling.
This produce scar which represent trace of healing wound.

Inflammatory phase

1. Begins at the time of injury; lasts 2 to 3 days.
2. Begins with vasoconstriction to achieve hemostasis (epinephrine and thromboxane).
3. Platelet plug forms and clotting cascade is activated, resulting in fibrin deposition.
4. Platelets release platelet-derived growth factor (PDGF) and transforming growth factor β (TGF-β) from their alpha granules, attracting inflammatory cells, particularly macrophages.
5. After hemostasis is achieved, vasodilation occurs and vascular permeability increases (due to histamine, platelet-activating factor, bradykinin, prostaglandin I_2, prostaglandin E_2, and nitric oxide), aiding the infiltration of inflammatory cells into the wound.
6. Neutrophils peak at 24 hours and help with débridement.
7. Monocytes enter the wound, becoming macrophages, and peak within 2 to 3 days.
8. Limited numbers of lymphocytes arrive later, but their significance is unknown.

Proliferative phase

1. Begins around day 3, as fibroblasts arrive; lasts through week 3.
2. Fibroblasts: Attracted and activated by PDGF and TGF-β; arrive day 3, reach peak numbers by day 7.
3. Collagen synthesis (mainly type III), angiogenesis, and epithelialization occur.
4. Total collagen content increases for 3 weeks, until collagen production and breakdown become equal and the remodeling phase begins.

Remodeling phase

1. Increased collagen production and breakdown continue for 6 months to 1 year.
2. Type I collagen replaces type III until it reaches a 4:1 ratio of type I to type III (that of normal skin and mature scar tissue).
3. Wound strength increases as collagen reorganizes along lines of tension and is cross-linked.
4. Vascularity decreases.
5. Fibroblast and myofibroblasts cause wound contraction during the remodeling phase.
6- Wounds have 50% of their final strength at 6 weeks, but never reaches normal (only 80% normal).

Fetal wound healing

A. Skin (but not all fetal tissue) heals by regeneration without scarring. This is limited to the first two trimesters.

B. Many aspects of fetal tissue and the fetal environment may contribute to scarless healing.
1. The fetal environment (amniotic fluid) is sterile.
2. Amniotic fluid contains growth factors and extracellular matrix molecules.
3. The inflammatory phase is minimal, and macrophages may or may not be the main organizing cells in the healing process in the fetus.
4. The growth factor and cytokine milieu is different in the fetus, although the significance of any particular difference is unclear

TYPES OF WOUND HEALING

A. Primary Healing
Wounds are closed by reapproximation using suture or by some other mechanical means within hours of their creation.
B. Delayed primary closure (tertiary healing)
1. Wound remains open for a few days before surgical closure.
2. Decreases the risk of infection in contaminated wounds.
C. Secondary closure
1. Wound closes over time by contraction and epithelialization.
2. Appropriate for infected or contaminated wounds.
3. Allows drainage of fluid.
4. Allows debridement with dressing changes.
5. Prolonged inflammatory phase, leading to increased scarring and wound contracture.

Factors Contributing to Impaired Wound Healing
I. Local factors
A-Mechanical injury
B- Infection
C- Edema
D- Ischemia//necrotic tissue
E- Topical agents
F- Ionizing radiation
G- Low oxygen tension
H- Foreign bodies
II. Systemic factors
A- Age
B- Nutrition
C- Trauma
D- Metabolic diseases
E- Immunosuppression
F- Connective tissue disorders
G- Smoking

TREATMENT OF WOUNDS:
- *Local Care*
- *Antibiotics*
- *Dressings*
- *Skin Replacements*
- *Growth Factor Therapy*

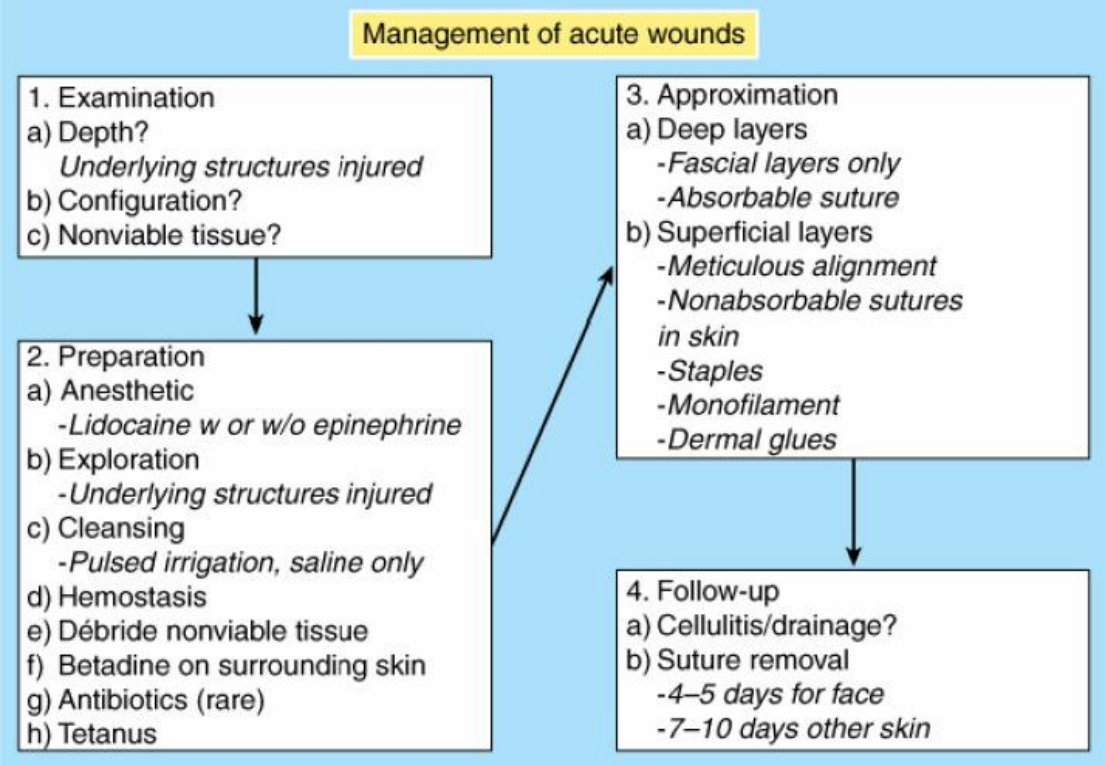

Excessive Wound Healing

I. Keloids

A. Excessive scar formation: Defined by scar tissue that extends beyond the boundaries of the incision or wound.

B. Etiology

1. Not completely understood, but growth factors certainly play a role.
2. Keloids contain elevated levels of TGF-β.

C. Demographics and natural history

1. More common in patients of African ancestry.
2. Tendency to form keloids is often inherited in an autosomal dominant pattern.
3. Common in ear lobes and areas of tension.
4. Keloids may develop months to a year after injury, and do not resolve spontaneously.

D. Histology

1. Excess collagen, and increased vascularity compared with normal scar tissue.
2. Collagen production is many times that seen in normal scar tissue, and there is a higher proportion of type III collagen.

E. Treatment

1. Excision alone is rarely successful.
2. Corticosteroid injection may cause some reduction in keloid size.
3. Excision followed by corticosteroid injection locally is more successful.
4. Excision should be followed by radiation therapy for severe cases.
5. Recurrence is common.

II. Hypertrophic scars

A. Excessive scar formation: Defined by scar tissue that does not extend beyond the boundaries of the incision or wound.

B. Etiology

1. Prolonged or increased inflammatory phase of healing.
2. Increased wound tension.

C. Demographics and natural history

1. More common in patients of African ancestry.
2. Less genetic component than keloids.
3. Tendency decreases with age, as the inflammatory phase of healing decreases.
4. More common in areas of tension, such as the presternal area.
5. Develop within weeks of wounding (during the inflammatory phase), and there is usually some degree of improvement with time.

D. Histology

1. Increased collagen with collagen nodules, hypervascularity.
2. Collagen production is increased compared with normal scar tissue, but less than in keloids.

E. Treatment

1. Corticosteroid injection, silicone sheeting, and pressure are often successful in reducing the degree of scar hypertrophy. Multiple treatments with corticosteroids may be required, and silicone sheeting and pressure garments must be applied for at least 6 months before improvement is seen.
2. Surgical excision and reclosure may be successful if nonsurgical modalities are not working, and if the wound can be closed without tension.