DISORDERS OF THE LENS

Learning objectives

Student should be able to

- ✓ ***Define cataract***
- ✓ ***Enumerate causes of cataract***
- ✓ ***Describe symptoms and signs of cataract.***
- ✓ ***Explain The reasons for undertaking cataract surgery***
- ✓ ***Discuss the principles of cataract surgery.***
- ✓ ***Enumerate the complications of cataract surgery.***
- ✓ ***Compare between adult and pediatric cataract in term of clinical features and management.***
- ✓ ***Enumerate abnormalities in shape and position of the lens.***

The lens is a biconvex and perfectly transparent organ, held in position behind the iris by the suspensory ligament (zonule), whose fibers are composed of the protein fibrillin. The zonule attaches the equator of the lens to the ciliary body.
Disease may affect structure, shape and position of the lens.

Acquired Cataract

Definition

Cataract is the name given to any light-scattering opacity within the lens wherever it is located. When it lies on the visual axis or is extensive, it gives rise to visual loss. Cataract is the commonest cause of treatable blindness in the world. The large majority of cataracts occur in older subjects, as a result of cumulative exposure to environmental and other influences.

Etiology:

1-Age related cataracts (senile cataracts)

Morphology: **Subcapsular** cataract which is either anterior or posterior, **nuclear cataract** involving the lens nucleus, **cortical cataract** involves the anterior, posterior or equatorial cortex.

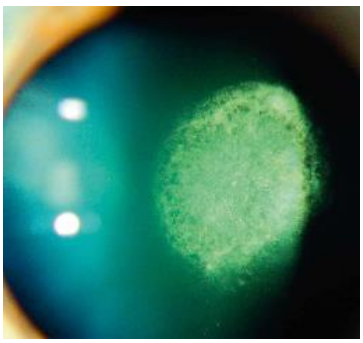

posterior subcapsular cataract

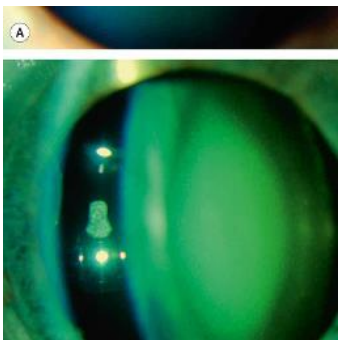

nuclear cataract

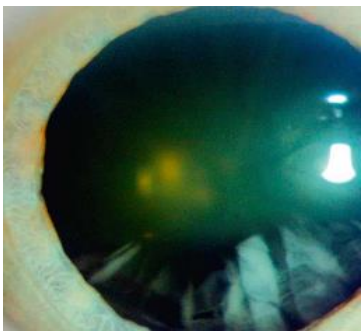

cortical cataract

Cataract maturity

a- **Immature** cataract is one in which the lens is partially opaque.
b- **Mature** cataract is one in which the lens is completely opaque
c- **Hypermature** cataract is one in which leakage of water has resulted in shrinkage of the lens capsule.

d- **Morgagnian** cataract is a hypermature cataract in which total liquefaction of the cortex has allowed the nucleus to sink inferiorly.

An intumescent cataract is a swollen cataractous lens because of fluid absorption. It may cause pupillary block with foreword displacement of the iris causing shallowing of the anterior chamber, which may result in secondary angle-closure glaucoma.

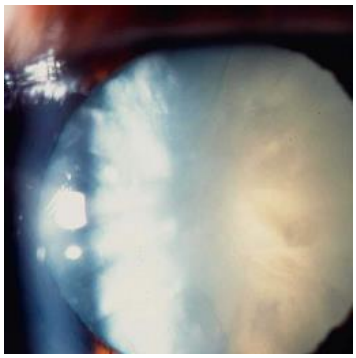

mature cataract

Hypermature cataract

morgagnian cataract

2-Cataract in systemic diseases

Cataracts may be associated with diabetes, myotonic dystrophy, atopic dermatitis and Neurofibromatosis II.

3-Traumatic cataracts

Trauma is the most common cause of unilateral cataract in young individuals. Lens opacities may be caused by direct penetrating injury, concussion, electric shock, ionizing radiation, infrared and ultraviolet radiation. Alkali injuries to the ocular surface often result in cataract, in addition to damaging the cornea, conjunctiva, and iris.

4-Toxic cataracts (drug-induced lens changes)

Steroids, both systemic and topical, are cataractogenic. Other drugs which may cause cataract are chlorpromazine, miotics, amiodarone, gold, and phenothiazines.

5-Secondary cataracts:

A secondary (complicated) cataract develops as a result of some other ocular disease. Chronic anterior uveitis is the most common cause of secondary cataract. Other causes include acute congestive angle-closure glaucoma, high myopia, hereditary fundus dystrophies such as retinitis pigmentosa.

cataract due to uveitis *cataract after acute angle-closure glaucoma*

Symptoms and Signs

The cardinal symptom of juvenile or adult cataract is a progressive, painless loss of vision. The degree of loss depends on the location and extent of the opacity. When the opacity is in the central lens nucleus (nuclear cataract), myopia develops in the early stages, so that a presbyopic patient may discover that he can read without his glasses (second sight).

Opacity beneath the posterior lens capsule (posterior subcapsular cataract) disproportionately affects vision because the opacity is located at the crossing point of the light rays from the viewed object. Such cataracts are particularly troublesome in bright light.

Rarely, the cataract swells (intumescent cataract), producing secondary glaucoma and pain.

Well-developed cataracts appear as gray or yellow-brown opacities in the lens. A cataract appears black against the red reflex when the eye is examined with a direct ophthalmoscope held about 30 cm (1 ft) away. A large cataract may obliterate the red reflex. Slit-lamp examination provides more details about the character, location, and extent of the opacity.

Management

General indications for cataract surgery

1. Visual improvement is by far the most common indication for cataract extraction.
2. Medical indications such as secondary angle closure by an intumescent lens, and diabetic retinopathy, for treatment of the fundus.
3. Cosmetic indications to restore a black pupil in an otherwise blind eye

Systemic preoperative assessment

For elective surgery, a general medical history is taken and any problems managed accordingly. Routine preoperative general medical examination, blood tests and ECG are not usually required for local anaesthesia.

Ophthalmic preoperative assessment

A detailed and pertinent ophthalmic evaluation is required. Following a past ophthalmic history, the following should be considered:

Visual acuity is usually tested using a Snellen chart.

Pupillary responses. Because a cataract never produces an afferent pupillary defect, its presence implies substantial additional pathology likely to influence the final visual outcome and requires further investigation.

Ocular adnexa. Dacryocystitis, blepharitis, chronic conjunctivitis, lagophthalmos, ectropion, entropion and tear film abnormalities may predispose to endophthalmitis and require effective preoperative resolution.

Cornea. Eyes with decreased endothelial cell counts have increased vulnerability to postoperative decompensation secondary to operative trauma. Specular microscopy and pachymetry may be helpful in assessing risk, and special precautions should be taken to protect the endothelium.

Anterior chamber. A shallow anterior chamber can render cataract surgery difficult.

Lens. Nuclear cataracts tend to be harder and may require more power for phacoemulsification, while cortical opacities tend to be softer. Black nuclear opacities are extremely dense and extracapsular cataract extraction rather than phacoemulsification may be the superior option.

Fundus examination. Pathology such as age-related macular degeneration may affect the visual outcome. Ultrasonography may be required, principally to exclude retinal detachment, in eyes with very dense opacity that precludes fundoscopy.

Biometry

Biometry facilitates calculation of the lens power likely to result in the desired postoperative refractive outcome; in its basic form this involves the measurement of two ocular parameters, keratometry and axial (anteroposterior) length.

Surgical techniques

Cataract extraction is usually performed using local anesthesia or topical anesthesia.general anesthesia may be required in certain cases.
The operation requires access to the lens substance via an opening in the anterior part of the lens capsule, removal of most of the lens fibers and epithelial cells, and insertion of an artificial lens implant of appropriate optical power. The implant is held in place within the 'capsular bag'.

Types of operations:

1- Phacoemulsification or 'phaco', using an ultrasound probe introduced through a smaller incision at the limbus. Usually no suture is required. This is now the preferred method.
2- Extracapsular cataract extraction (ECCE), through an extended incision at the limbus. Here, after opening the capsule, the bulk of the lens substance is expressed from the eye with gentle pressure and residual material is aspirated with a cannula. The incision must be sutured and the sutures removed postoperatively.

Postoperatively the patient is given a short course of steroid and antibiotic drops. New glasses, if required, can be prescribed after a few weeks, once the incision has healed. Visual rehabilitation and the prescription of new glasses is much quicker after phacoemulsification. Since the patient cannot accommodate, a spectacle correction will be required postoperatively for close work even if it is not needed for distance.

Complications of cataract surgery
Intra-operative complications

1- Rupture of posterior capsule, which may be accompanied by vitreous loss.
2- Posterior loss of lens fragments: large fragments should be removed to avoid progressive lens induced inflammation and long-term glaucoma.
3- Suprachoroidal (expulsive) haemorrhage. (intraoperative bleeding beneath the choroid causing the intraocular contents to be expulsed through the incision)

Early postoperative complications

1- Iris prolapse,
2- Striate keratopathy which is characterized by corneal oedema and folds in Descemet's membrane,
3- Acute bacterial endophthalmitis.

Late postoperative complications

1- Capsular opacification (treatable with laser).
2- Malposition of an IOL which is uncommon.
3- Corneal decompensation with bullous keratopathy.
4- Retinal detachment.
5- Cystoid macular edema.
6- Chronic endophthalmitis.

ACUTE BACTERIAL ENDOPHTHALMITIS

The *causative organisms,* in order of frequency, are Staph. epidermidis. Staph. aureus, seudomonas sp, and Proteus sp.
Prevention by: Treatment before surgery of pre-existing infections. Preoperative instillation of povidone-iodine 5% solution. Meticulous draping technique.

CLINICAL FEATURES

The clinical features depend on its severity at the time of examination. Mild or early endophthalmitis may be associated with only slight pain, and preservation of some red reflex. Severe endophthalmitis is characterized by pain, marked visual loss, corneal haze, hypopyon (pus in the anterior chamber), absent red reflex and inability to visualize the Fundus with the indirect ophthalmoscope.

MANAGEMENT

1. Identification of the causative organism from the aqueous and vitreous.
2. **Antibiotics** which cover both Gram-positive and Gram-negative organisms should be administered.
   a. **Intravitreal antibiotics** should be given after the culture specimens have been obtained. ceftazidime (2mg), and vancomycin (1 mg) are injected slowly into the vitreous cavity.
   b. **Periocular** injections consist of vancomycin 50 mg and ceftazidime 125 mg. The injections are repeated daily for 5-7 days according to the response to therapy.
   c. **Topical therapy** consists of Vancomycin 5% (50 mg/mL) or ceftazidime 5% (50 mg/mL) applied intensively may penetrate the cornea in therapeutic levels. Third or fourth generation fluoroquinolones achieve effective levels in the aqueous and vitreous, even in uninflamed eyes, and may be considered..
   d. **Systemic antibiotics** are not beneficial because of their relatively poor intraocular penetration.
3. **Steroid therapy** will not interfere with the control of the infection, provided the organisms are sensitive to the antibiotics.
   a. **Periocular injections** of betamethasone or dexamethasone 4 mg (1 ml) are given daily for 5-7 days according to response to therapy.
   b. **Systemic therapy** with oral Prednisolone 1 mg/kg daily should be started in severe cases for 10-14 days.
   c. **Topical therapy** with dexamethasone drops 0.1 % is given every 30 minutes.
4. **Vitrectomy** is beneficial only in cases with very severe infection and a visual acuity reduced to 'light perception'.

Congenital cataract

Thakir Mohammed Mohsin

Cataract in children can be:

- Isolated or part of systemic condition
- Congenital or acquired
- Inherited or sporadic
- Unilateral or bilateral
- Partial or complete
- Stable or progressive

Congenital cataracts are responsible for nearly 10% of all vision loss in children worldwide.
Congenital cataracts occur in about 3 in 10 000 live births. Two-thirds of cases are bilateral.

Causes

1. Inherited without systemic abnormality. most frequently autosomal dominant but may be autosomal recessive or X-linked
2. Metabolic causes as galactosaemia, and hypocalcaemia.
3. Intrauterine infections as Congenital rubella and toxoplasmosis.
4. Chromosomal disorders: e.g. Down and Turner syndrome.

Morphological types: include nuclear, lamellar, sutural, coronary and polar cataract. Focal blue dot opacities are very common and innocuous.

Evaluation of the patient

Since visual acuity cannot be obtained in neonates, greater reliance has to be placed on the density and morphology of the opacity. Associated ocular pathology may involve the anterior or posterior segment. Other features indicative of severe visual impairment are absence of central fixation, and the presence of nystagmus or strabismus.

The investigation of infants with bilateral cataracts should include the following:

(a) Serological tests for intrauterine infection(TORCH = toxoplasmosis, rubella, cytomegalovirus and herpes simplex).
(b) Urinalysis for reducing substance after drinking milk.
(c) Urine chromatography of amino acids for Lowe syndrome.
(d) Other investigations include fasting blood sugar, serum calcium and phosphorus, and galactokinase levels. Paediatric evaluation and chromosome analysis should be looked for.

Surgery

Timing is crucial. Visually significant cataract should be removed immediately. Lensectomy/vitrectomy is a small incision technique by which the cataract is removed using a vitreous cutting instrument.

Postoperative complications

The incidence of complications is greater than that in adult eyes. These include posterior capsular opacification, secondary membranes may form across the pupil, lens reproliferation in the equator, acute angle closure glaucoma due to pupillary block. Retinal detachment is a late complication.

Visual rehabilitation

Contact lenses provide a superior optical solution for both unilateral and bilateral aphakia. Spectacles are useful for older children with bilateral aphakia, but are not appropriate in patients with unilateral aphakia because of associated anisometropia. Intraocular lens implantation, , in young children, is still controversial. Lens implants are, however, being used with increased frequency in children.

ABNORMALITIES OF LENS SHAPE

1. *A lens coloboma* notching of the lens.
2. *Anterior or posterior lenticonus is a* projection of the anterior or posterior axial zone of the lens.
3. *Lentiglobus is a* generalized hemispherical deformity of the lens.
4. *Microphakia is* a lens with a smaller than normal diameter.

ABNORMALITIES OF LENS POSITION (ECTOPIA LENTIS)

Ectopia lentis refers to a displacement of the lens from its normal position. The lens may be completely dislocated from the pupillary space or partially displaced (subluxated).

Etiology:

1. Acquired causes include trauma, a very large eye (i.e. high myopia, buphthalmos), anterior uveal tumours and a hypermature cataract.

2. Hereditary causes as Marfan syndrome, homocystinuria and WeillMarchesani syndrome.

Management of ectopia lentis

The main complications of ectopia lentis are: decreased visual acuity, and glaucoma. The following are three treatment options:

1. Spectacle correction.
2. Surgical removal of the lens is indicated for associated cataract, lens-induced glaucoma, and endothelial touch.