The Central Nervous system

Anas Alhamed

- monosynaptic reflex arc.
- Lateral Spinothalamic Tract

- **anterior Spinothalamic Tract**

The Central Nervous system

- The CNS is formed from the brain and the spinal cord.
- In this part the structure and the function of the spinal cord and the nerve that originate from it will be studied.

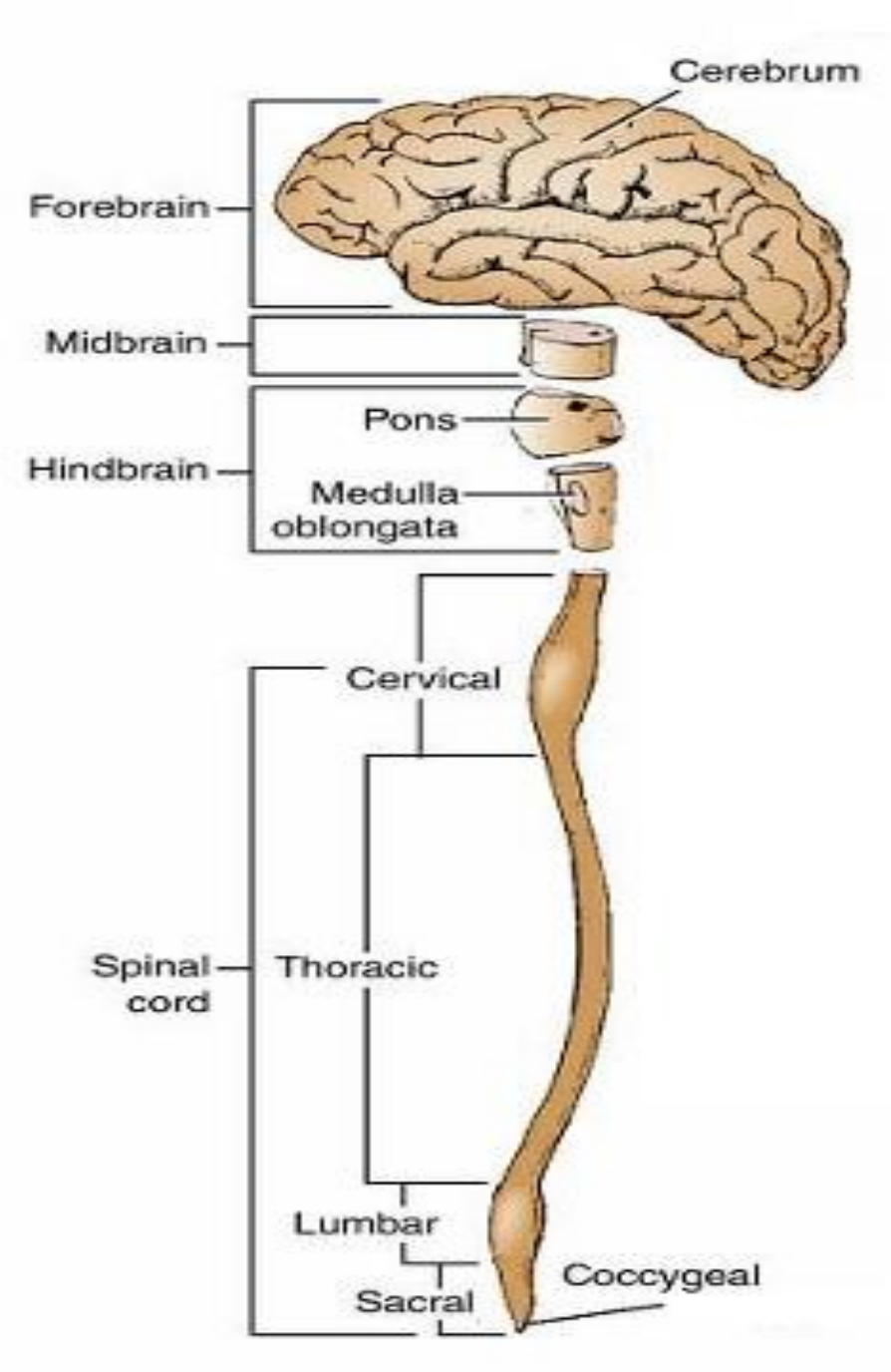

Protection and Coverings

Vertebral Canal

- The spinal cord is located in the vertebral canal of the vertebral column.
- The canal is formed by the vertebral foramina of all the vertebrae arranged on top of each other.
- Since the wall of the vertebral canal is essentially a ring of bone surrounding the spinal cord, the cord is well protected.
- A certain degree of protection is also provided by the meninges, cerebrospinal fluid, and the vertebral ligaments.

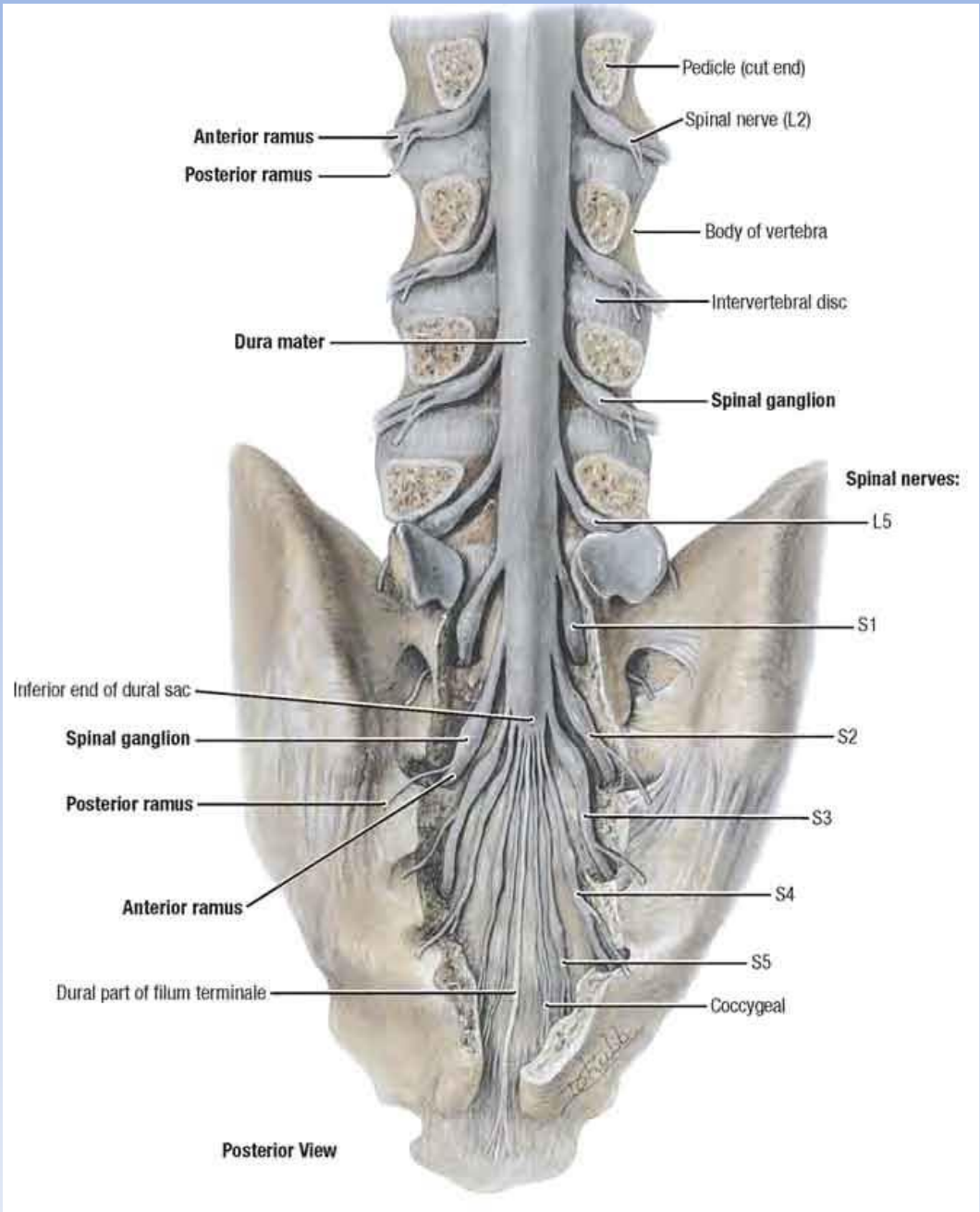

Meninges of the Spinal Cord

Dura Mater

- The dura mater is a dense, strong, fibrous membrane encloses the spinal cord and the cauda equina.
- It is continuous through the foramen magnum with the meningeal layer of the dural covering the brain.
- Inferiorly, it ends on the filum terminale at the level of the lower border of the second sacral vertebra.
- It is separated from the wall of the vertebral canal by the extradural space (epidural space).
- This contains loose areolar tissue and the internal vertebral venous plexus.
- The dura mater extends along each nerve root and becomes continuous with connective tissue surrounding each spinal nerve (epineurium) at the intervertebral foramen.
- The inner surface of the dura mater is separated from the arachnoid mater by the potential subdural space.

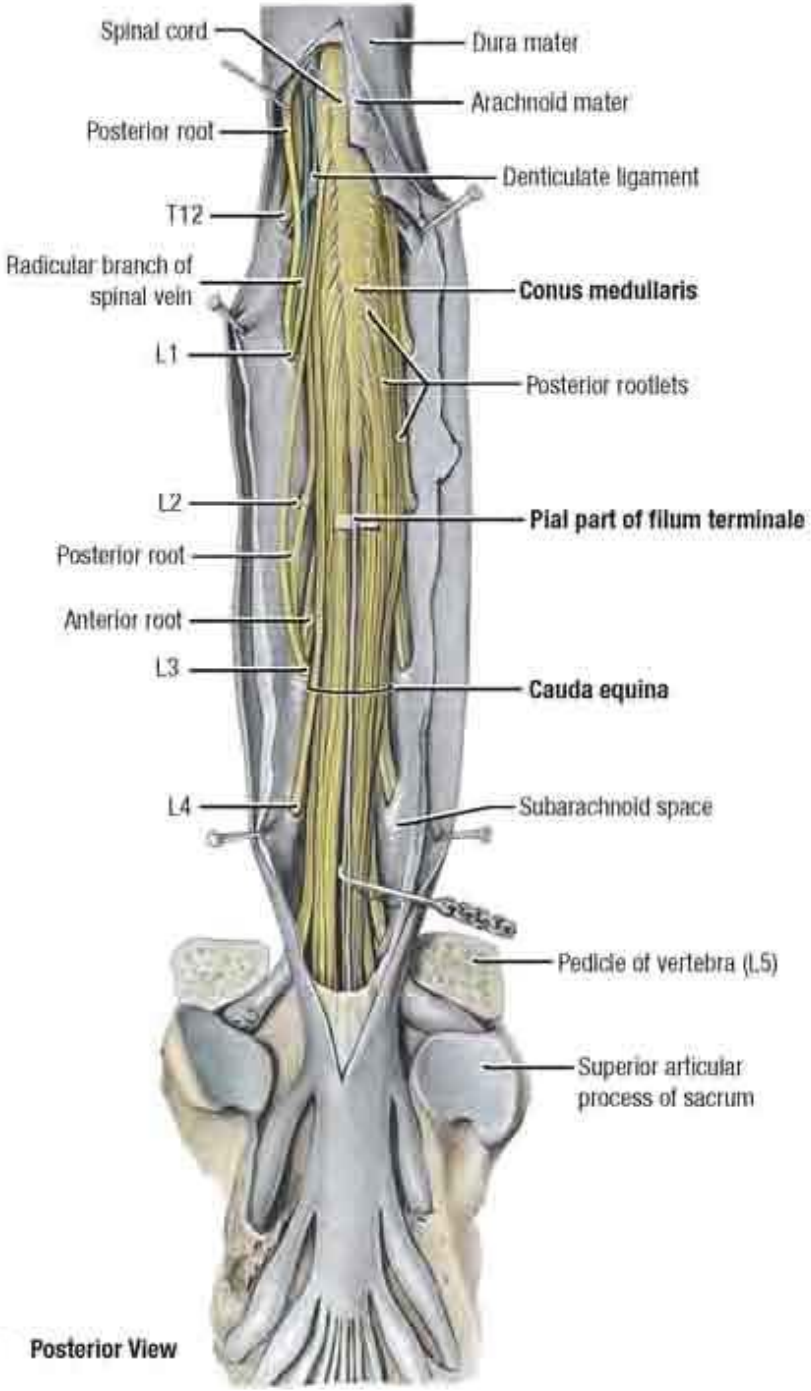

Meninges of the Spinal Cord

Arachnoid Mater

- The arachnoid mater is a delicate, impermeable membrane that covers the spinal cord and lies between the pia mater internally and the dura mater externally.
- It is separated from the pia mater by a wide space, the subarachnoid space, which is filled with the cerebrospinal fluid.
- The arachnoid mater is continuous above through the foramen magnum with the arachnoid covering of the brain.
- Inferiorly, it ends on the filum terminale at the level of the lower border of the second sacral vertebra.
- Between the levels of the conus medullaris and the lower end of the subarachnoid space lie the nerve roots of the cauda equina bathed in cerebrospinal fluid.

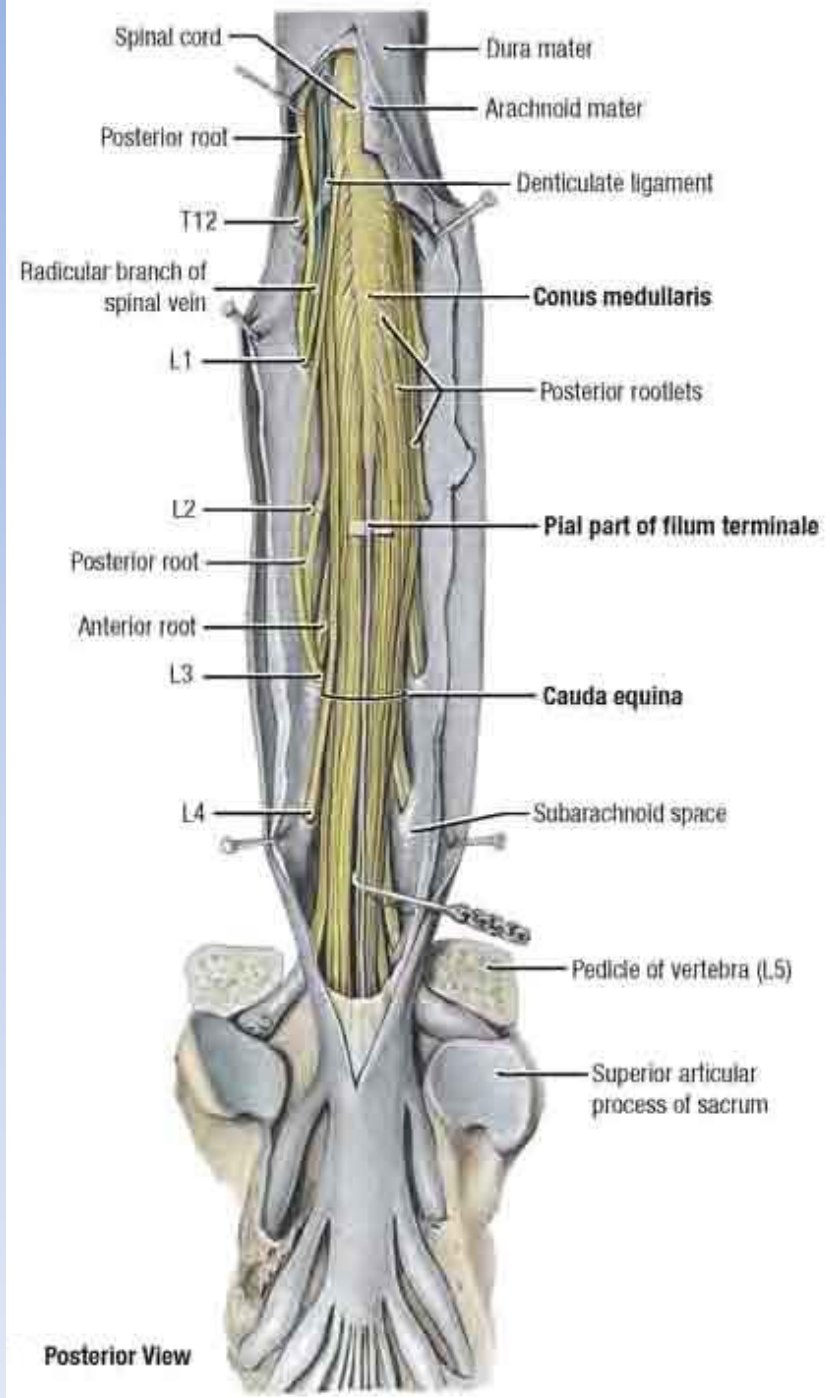

Meninges of the Spinal Cord

Pia Mater

- The pia mater, a vascular membrane that closely covers the spinal cord, is thickened on either side between the nerve roots to form denticulate ligament, which passes laterally to adhere to the arachnoid and dura.
- The ligaments protect the spinal cord against shock and sudden displacement.
- Essentially, the spinal cord is fixed in its position in the vertebral canal, since it is anchored to the coccyx inferiorly by the filum terminale, laterally to the dura mater by the denticulate ligaments, and superiorly to the brain.

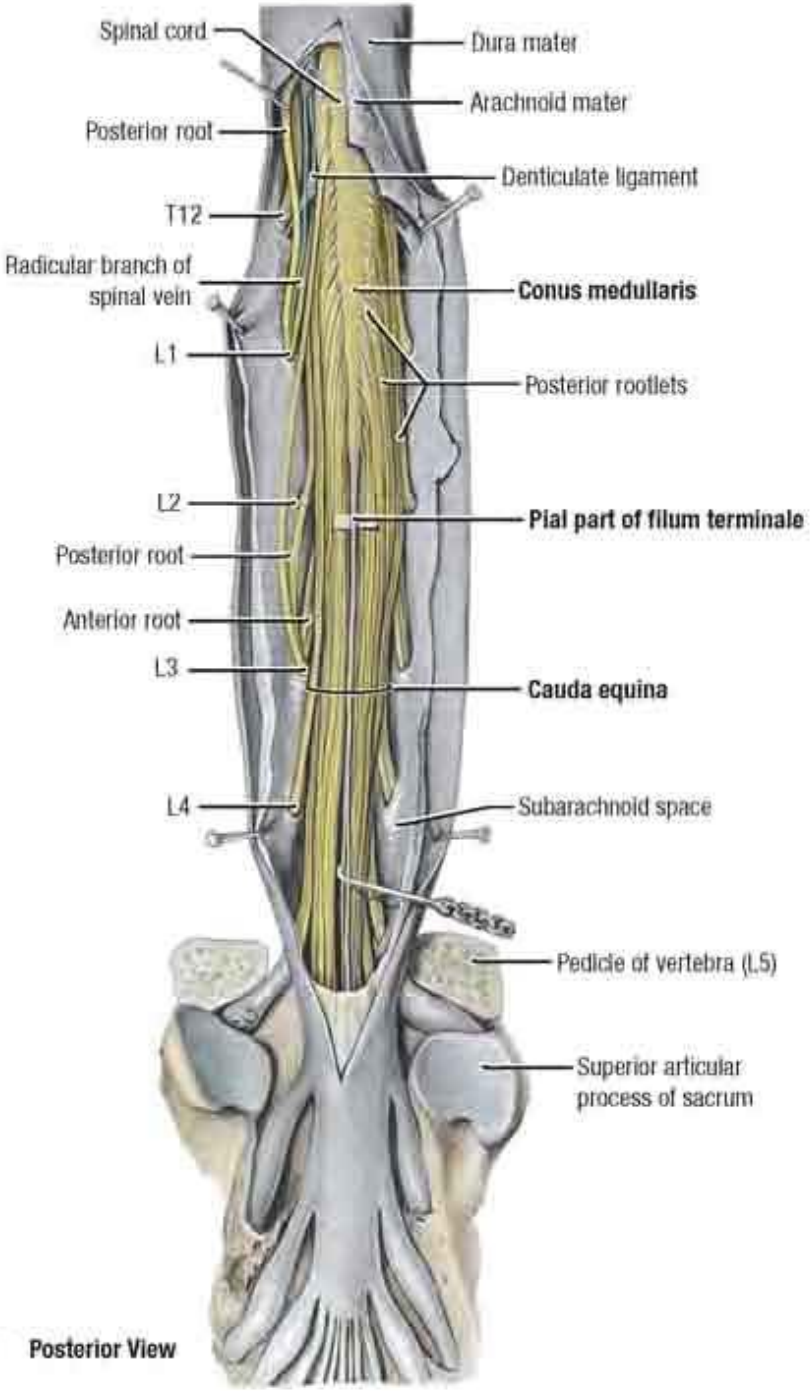

cerebrospinal fluid (CSF)

- The cerebrospinal fluid (CSF) is removed from the subarachnoid space in the inferior lumbar region of the spinal cord by a *lumbar puncture*.
- The procedure is normally performed between the third and fourth or fourth and fifth lumbar vertebrae.
- The spinal process of the fourth lumbar vertebra is easily located; a line drawn across the highest points of the iliac crest will pass through the spinous process.
- The needle pierces the skin, superficial fascia, supraspinous ligament, interspinous ligament, epidural space, and arachnoid, to enter the subarachnoid space.

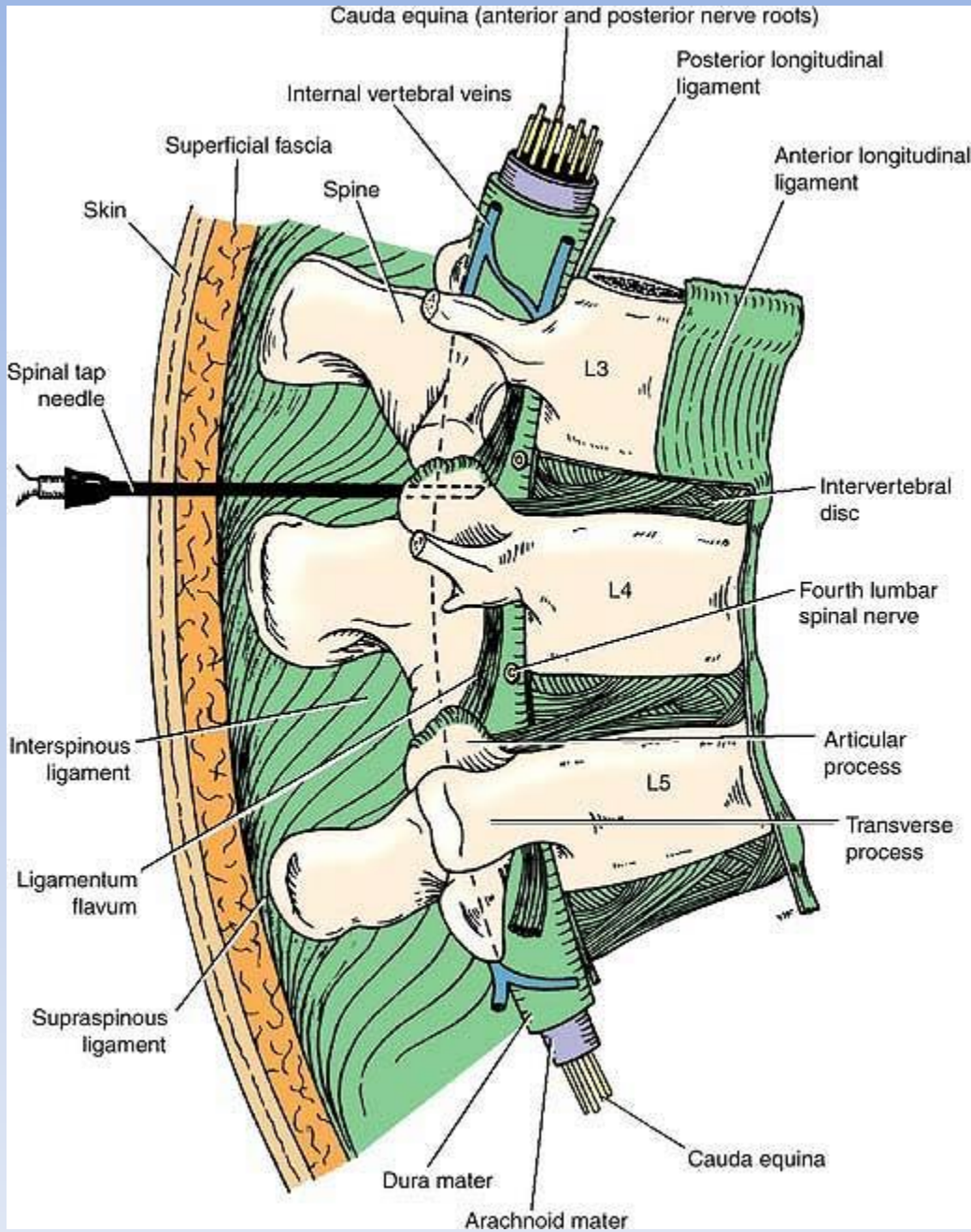

Ligaments

- The anterior and posterior longitudinal ligaments run as continuous bands down the anterior and posterior surfaces of the vertebral column from the skull to the sacrum.
- Supraspinous ligament: This runs between the tips of adjacent spines.
- Interspinous ligament: This connects adjacent spines.
- Intertransverse ligaments: These run between adjacent transverse processes.
- Ligamentum flavum: This connects the laminae of adjacent vertebrae.
- In the cervical region, the supraspinous and interspinous ligaments are greatly thickened to form the strong ligamentum nuchae.

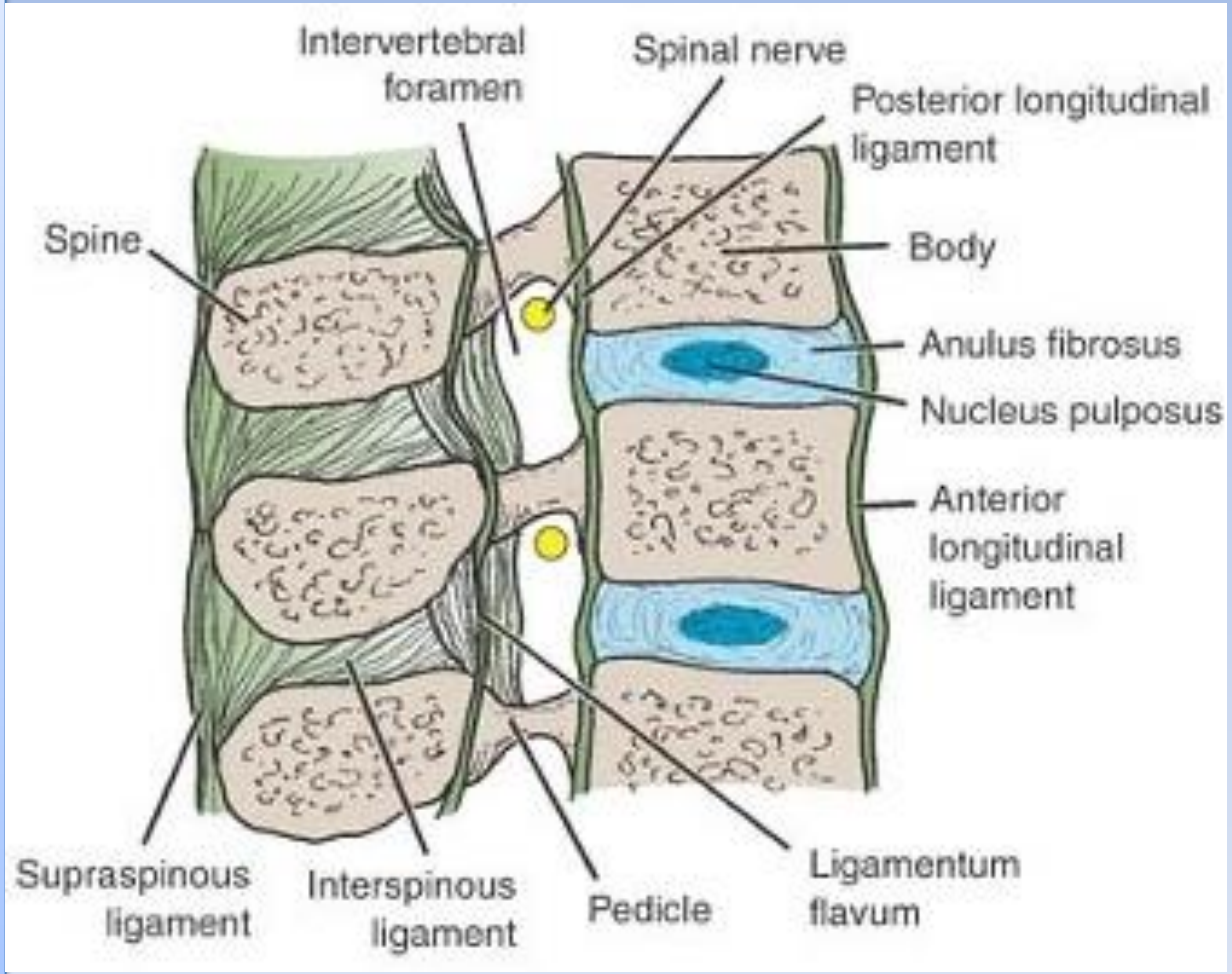

Intervertebral Discs

- The intervertebral discs are thickest in the cervical and lumbar regions, where the movements of the vertebral column are greatest.
- They serve as shock absorbers when the load on the vertebral column is suddenly increased.
- Each disc consists of a peripheral part, the anulus fibrosus, and a central part, the nucleus pulposus.
- The peripheral part is composed of fibrocartilage, which is strongly attached to the vertebral bodies and the anterior and posterior longitudinal ligaments of the vertebral column.
- The central part in the young is an ovoid mass of gelatinous material.
- The upper and lower surfaces of the bodies of adjacent vertebrae that abut onto the disc are covered with thin plates of hyaline cartilage.
- The semifluid nature of the nucleus pulposus allows it to change shape and permits one vertebra to rock forward or backward on another
- In old age, the discs are thin and less elastic, and it is no longer possible to distinguish the nucleus from the anulus.

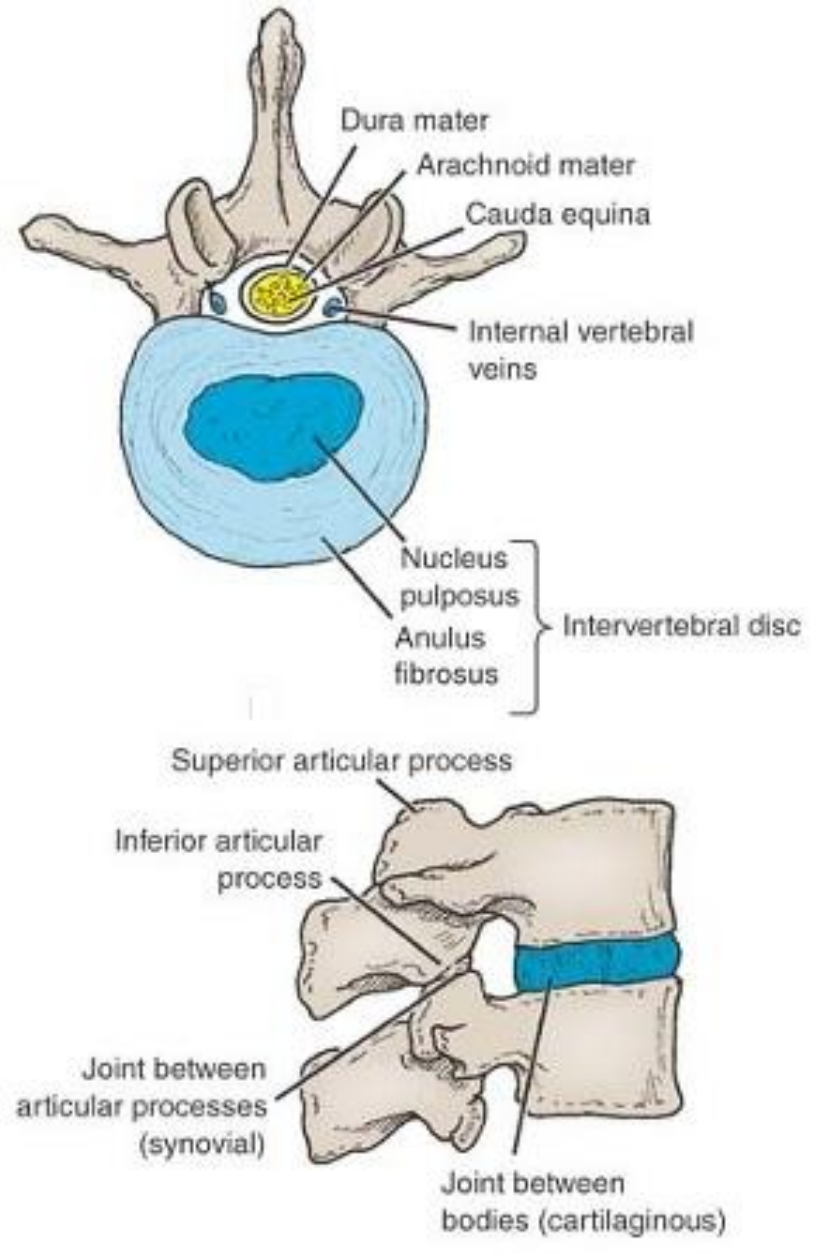

Gross Appearance of the Spinal Cord

- The spinal cord is roughly cylindrical in shape.
- It begins superiorly at the foramen magnum in the skull, where it is continuous with the medulla oblongata of the brain, and it terminates inferiorly in the adult at the level of the lower border of the first lumbar vertebra.
- In the young child, it is relatively longer and usually ends at the upper border of the third lumbar vertebra.
- Thus it occupies the upper two thirds of the vertebral canal of the vertebral column and is surrounded by the three meninges, the dura mater, the arachnoid mater, and the pia mater.

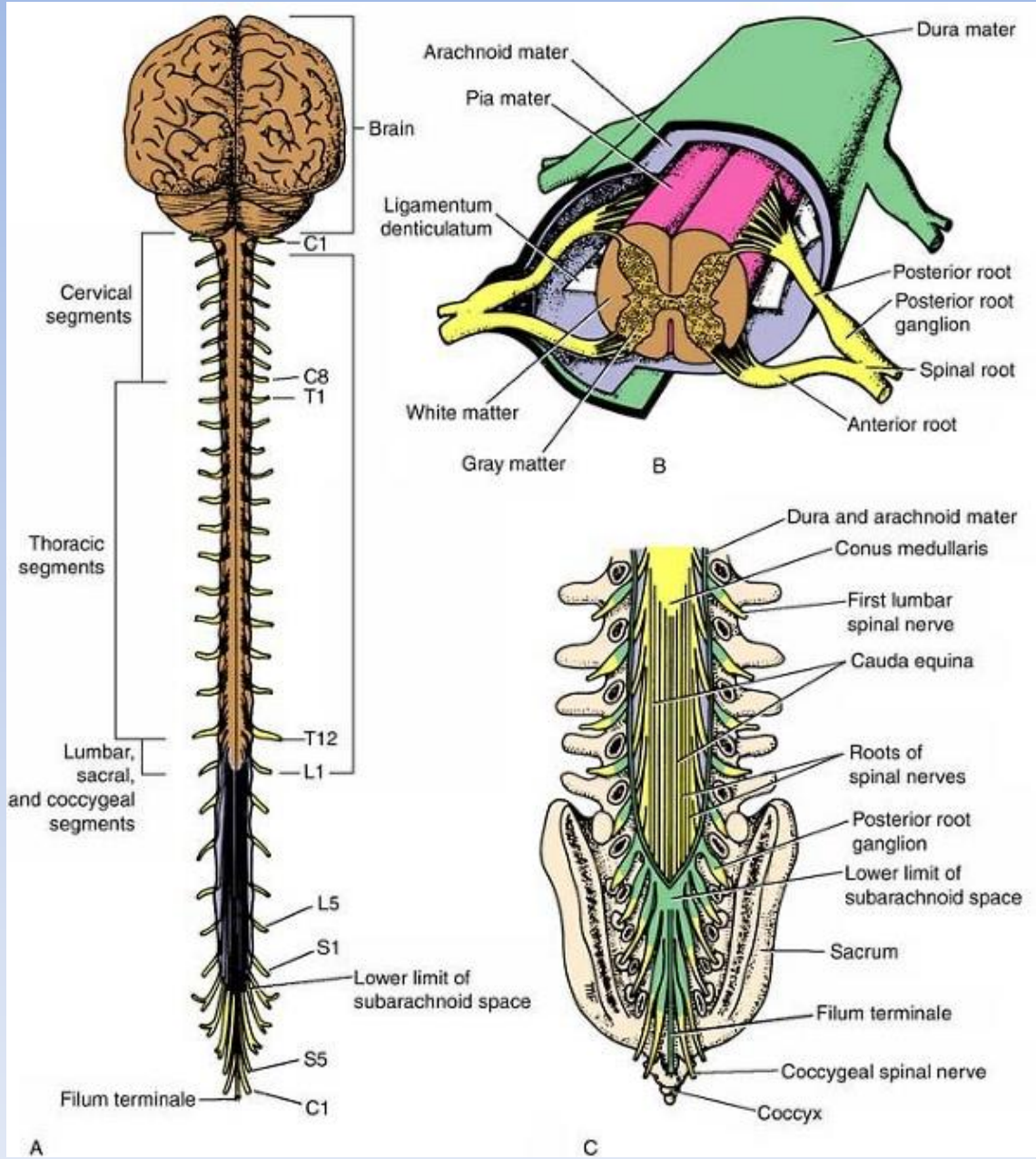

Gross Appearance of the Spinal Cord

- In the cervical region, where it gives origin to the brachial plexus, and in the lower thoracic and lumbar regions, where it gives origin to the lumbosacral plexus, the spinal cord is fusiformly enlarged; the enlargements are referred to as the cervical and lumbar enlargements.
- Inferiorly the spinal cord tapers off into the conus medullaris, from the apex of which a prolongation of the pia mater, the filum terminale, descends to be attached to the posterior surface of the coccyx.
- The cord possess in the midline anteriorly a deep longitudinal fissure called the anterior median fissure and, on the posterior surface, a shallow furrow called the posterior median sulus.

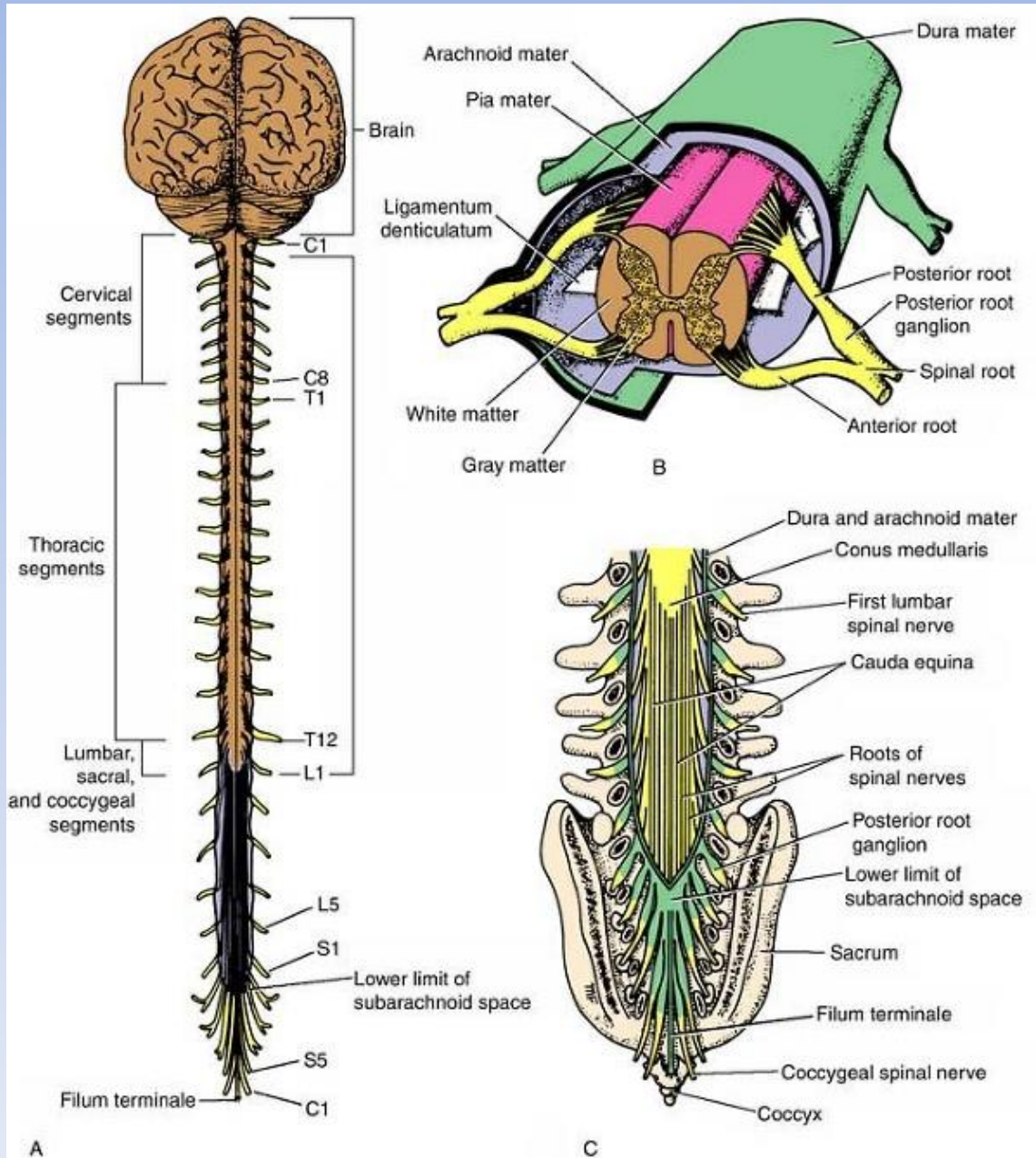

cauda equina

- During fetal life, the spinal cord and the vertebral column grow at different rate, the cord is growing slower and terminates near the level of the first or second lumbar vertebrae.
- As a result, the spinal segments do not lie opposite to their corresponding vertebrae, thus the roots of the lower spinal nerves descend more and more to enter their corresponding intervertebral foramina.
- This structure constitute the *cauda equina*, meaning horse's tail.

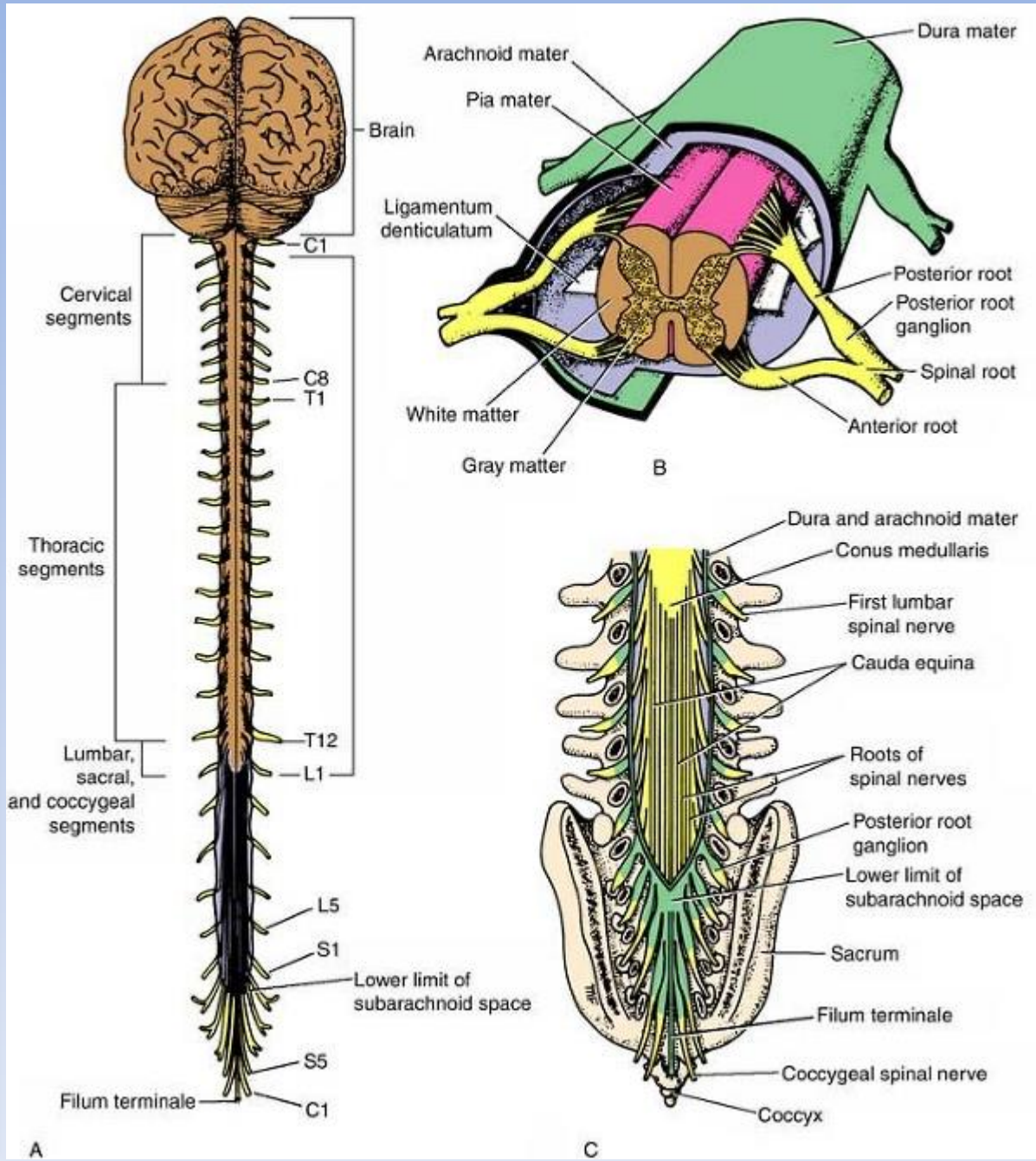

Spinal Nerve Roots

- Along the entire length of the spinal cord are attached 31 pairs of spinal nerves by the anterior or motor roots and the posterior or sensory roots.
- Each root is attached to the cord by a series of rootlets, which extend the whole length of the corresponding segment of the cord.
- Each posterior nerve root possesses a posterior root ganglion.
- The cells of the posterior root ganglion give rise to peripheral and central nerve fibers.

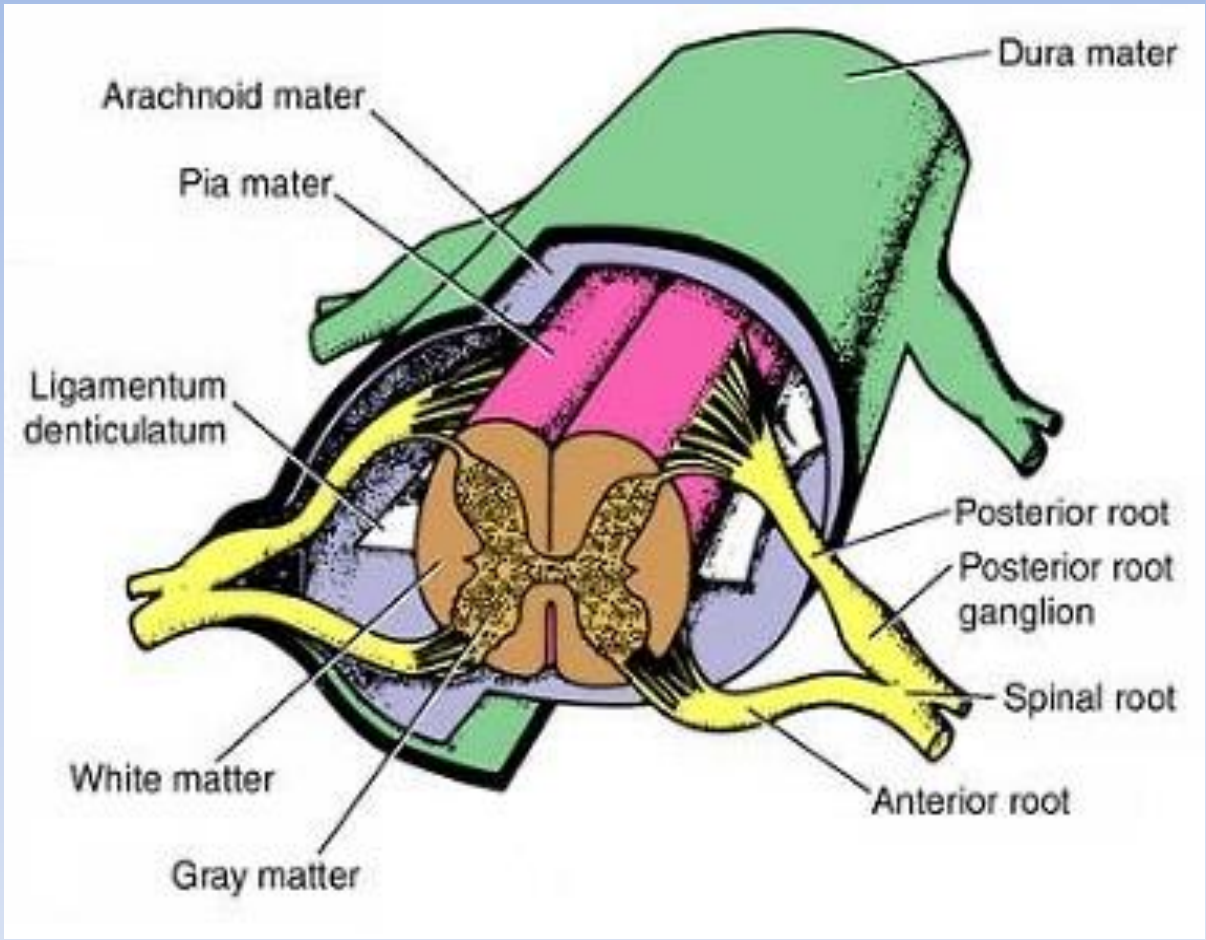

Structure of the Spinal Cord

- The spinal cord is composed of an inner core of gray matter, which is surrounded by an outer covering of white matter.
- On cross section, the gray matter is seen as an H-shaped pillar with anterior and posterior gray columns, or horns, united by a thin gray commissure containing the small central canal.
- A small lateral gray column, or horn is present in the thoracic and upper lumbar segments of the cord.
- The amount of the gray matter at any given level of the spinal cord is related to the amount of the muscle innervated at that level.
- Thus, its size is greatest within the cervical and lumbosacral segments of the cord, which innervate the muscles of the upper and lower limbs respectively

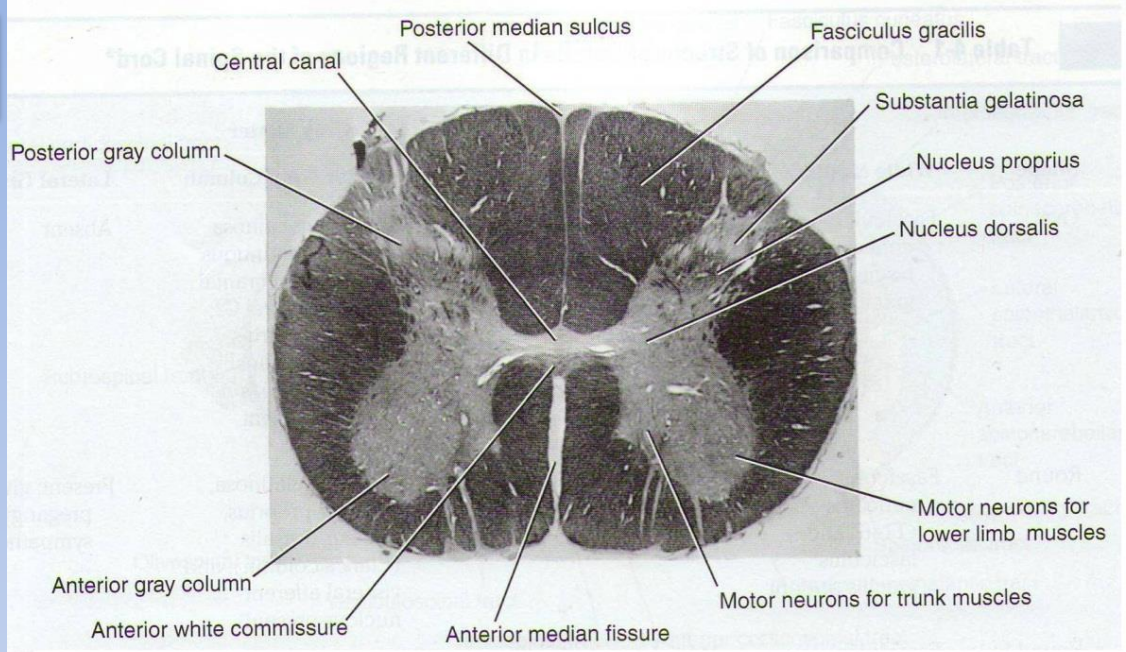

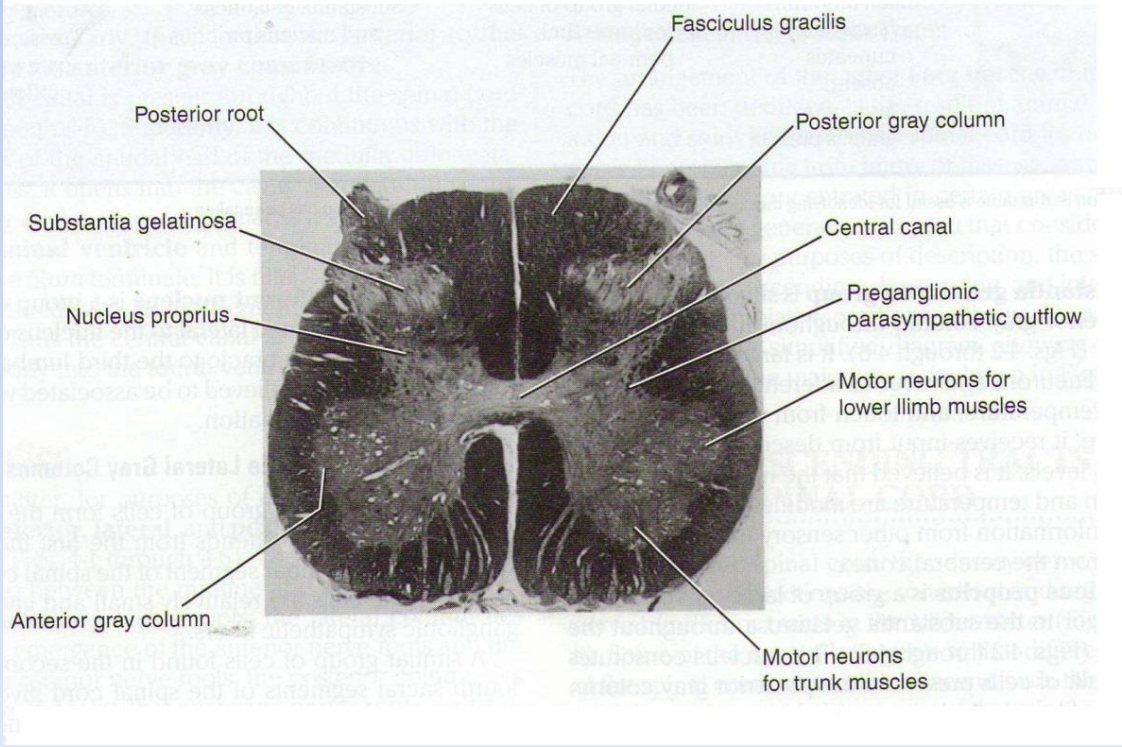

Structure of the Gray Matter

- The gray matter of the spinal cord consists of a mixture of nerve cells and their processes, neuroglia, and blood vessels.
- The nerve cells are multipolar, and the neuroglia forms an complicated network around the nerve cell bodies and their neurites.

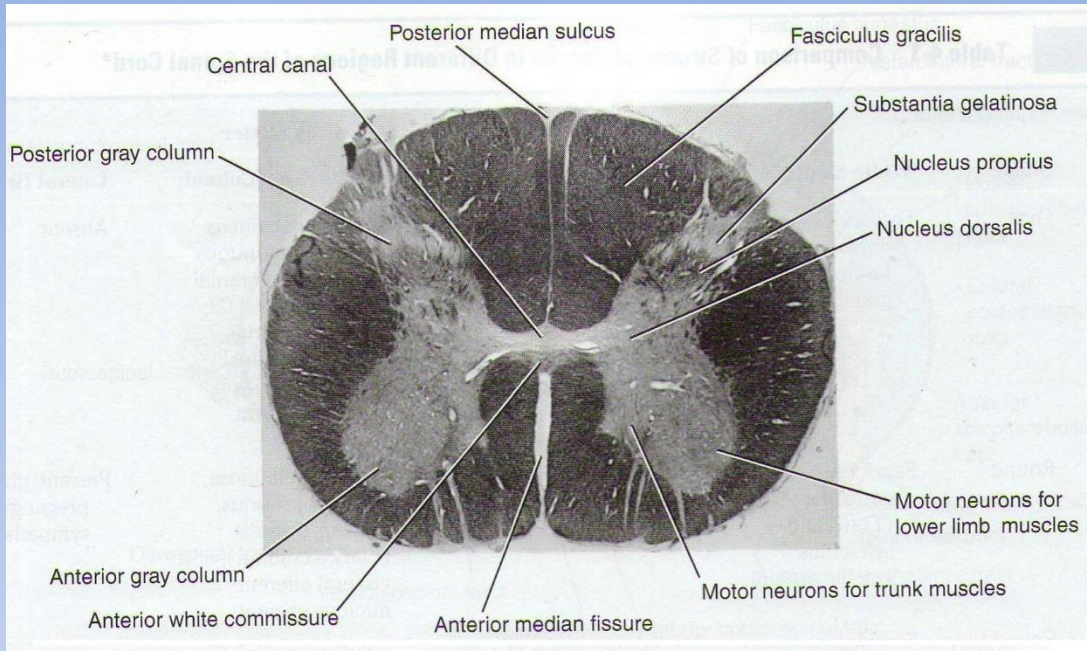

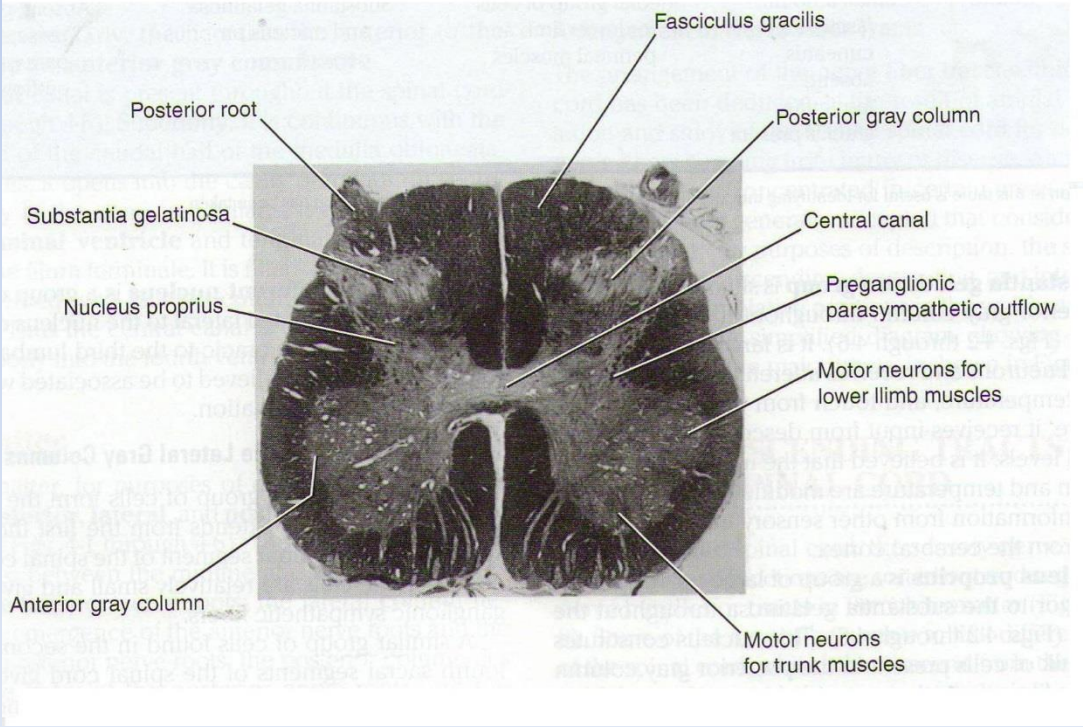

Nerve Cell Groups

Anterior Gray Columns

- For the practical purpose, the nerve cells of the anterior gray column may be divided into three basic groups or columns: medial, central and lateral.

Medial Cell Group of Anterior Gray Column

- It is present in most segments of the spinal cord and is responsible for innervating the skeletal muscles of the neck and trunk, including the intercostal and abdominal musculature.

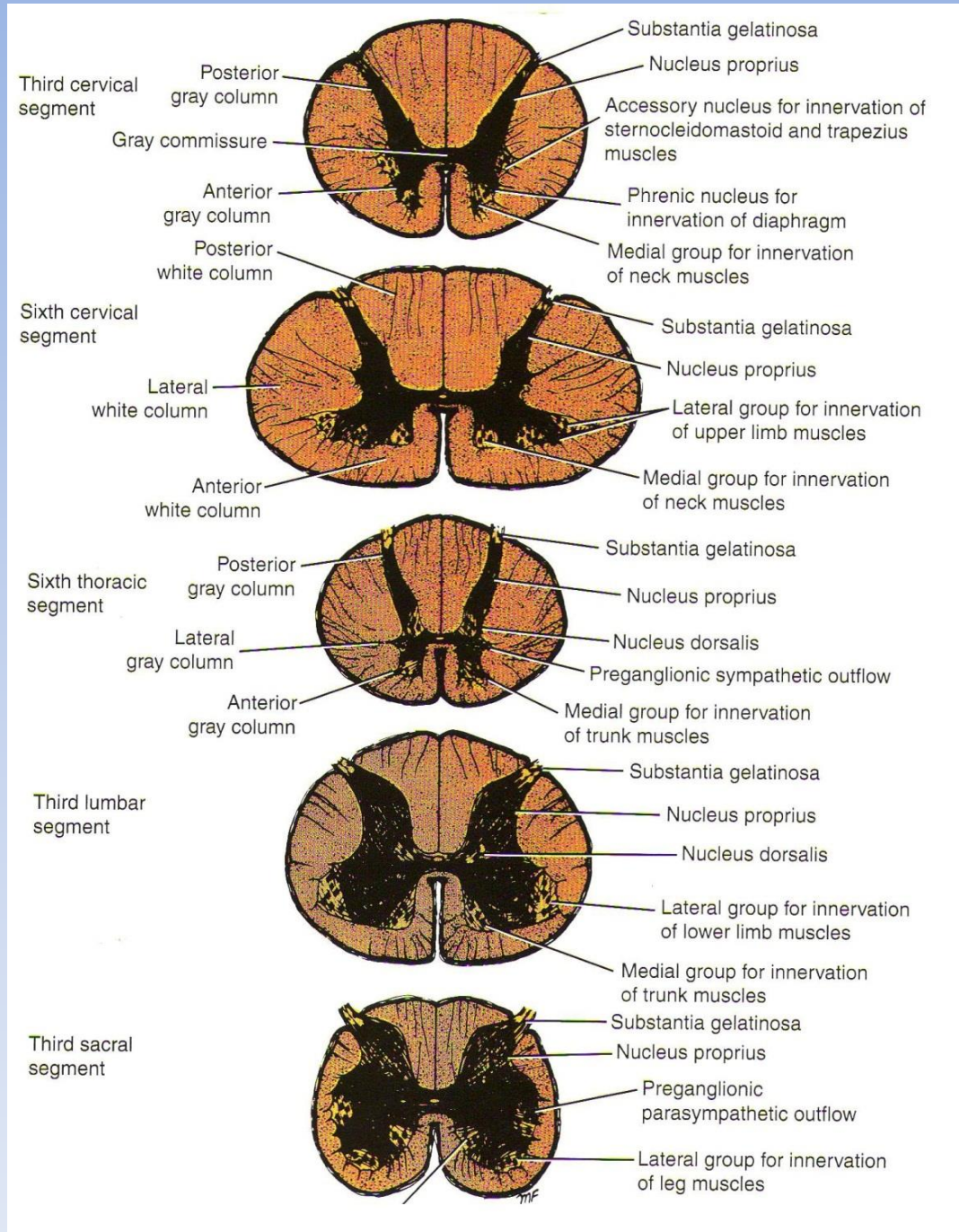

The Central Cell Group of the Anterior Gray Column

- The central cell group is the smallest and is present in some cervical and lumbosacral segments.
- In the cervical part of the cord, some of these nerve cells (segments C3, 4 and 5) specially innervate the diaphragm and are collectively referred to as the phrenic nucleus.
- In the upper five or six cervical segments, some of these nerve cells innervate the sternocleidomastoid and trapezius muscles and are referred to as accessory nucleus. The axons of these cells form the spinal part of the accessory nerve.
- The lumbosacral nucleus present in the second lumbar down to the first sacral segment of the cord is made up of nerve cells whose axons have an unknown distribution.

The Lateral Cell Group of the Anterior Gray Column

- The lateral group is present in the cervical and lumbosacral segments of the cord and is responsible for innervating the skeletal muscle of the limbs.

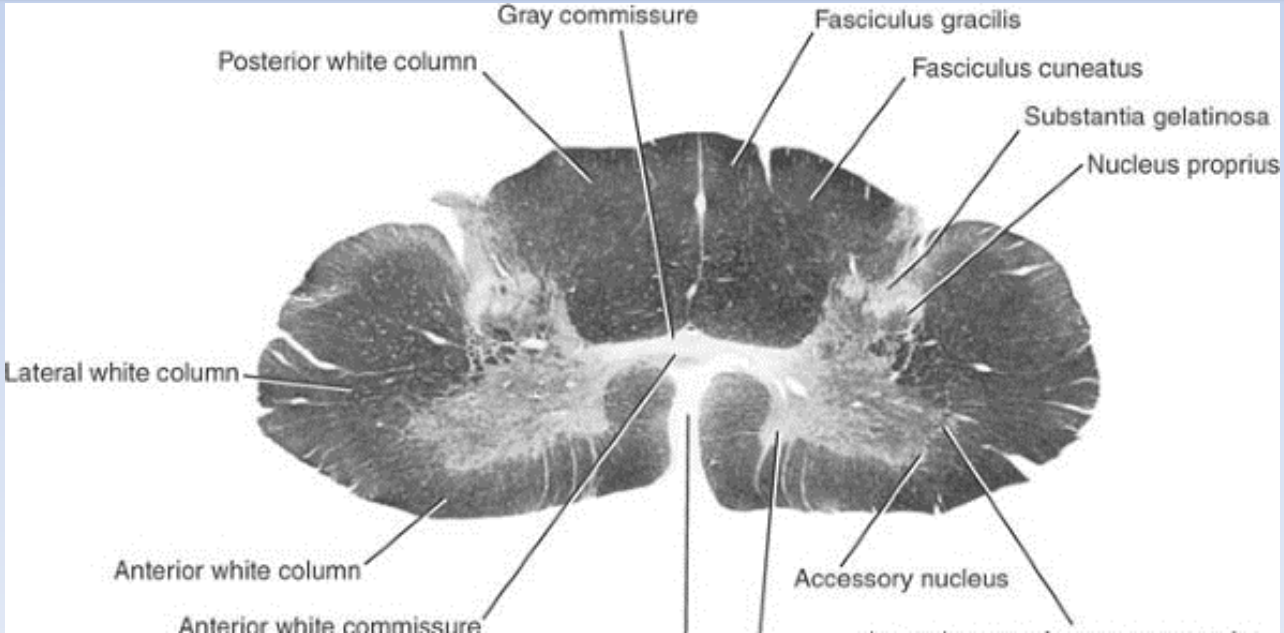

Nerve Cell Groups in the Posterior Gray Columns

- There are four nerve cell groups of the posterior gray column, two that extends throughout the length of the cord and two that are restricted to the thoracic and lumbar segments.

The substantia gelatinosa group

- is situated at the apex of the posterior gray column throughout the length of the spinal cords.
- It receives afferent fibers concerned with pain, temperature, and touch from the posterior root.

The nucleus proprius

- is a group of large nerve cells situated anterior to the substantia gelatinosa throughout the spinal cord.
- It forms the main bulk of cells present in the posterior gray column and receives fibers from the posterior white column that are associated with the senses of position and movement (proprioception), two-points discrimination and vibration.

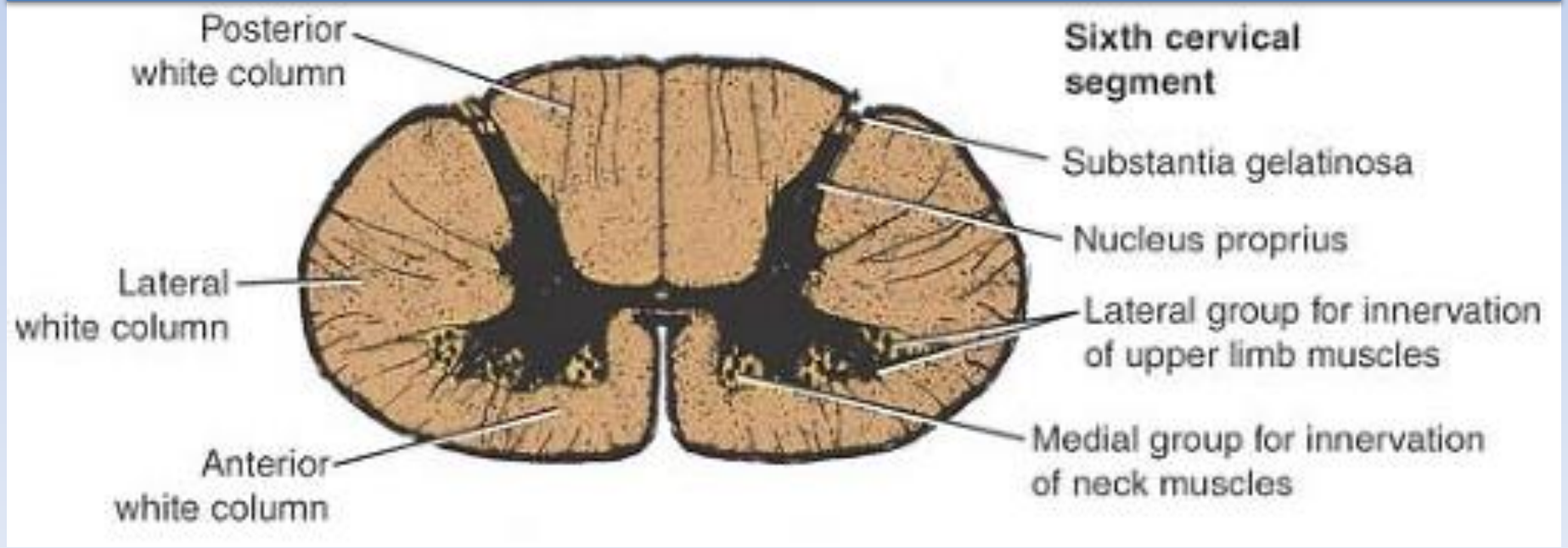

The nucleus dorsalis (Clark's column)

- is a group of nerve cells situated at the base of the posterior gray column and extending from the eighth cervical segment caudally to the third or fourth lumbar segment.
- Most of the cells are comparatively large and are associated with proprioceptive endings (neuromuscular spindles and tendon spindles).

The visceral afferent nucleus

- is a group of nerve cells of medium size situated lateral to the nucleus dorsalis; it extend from the first thoracic to the third lumbar segment of the spinal cord.
- It is believed to be associated with receiving visceral afferent information.

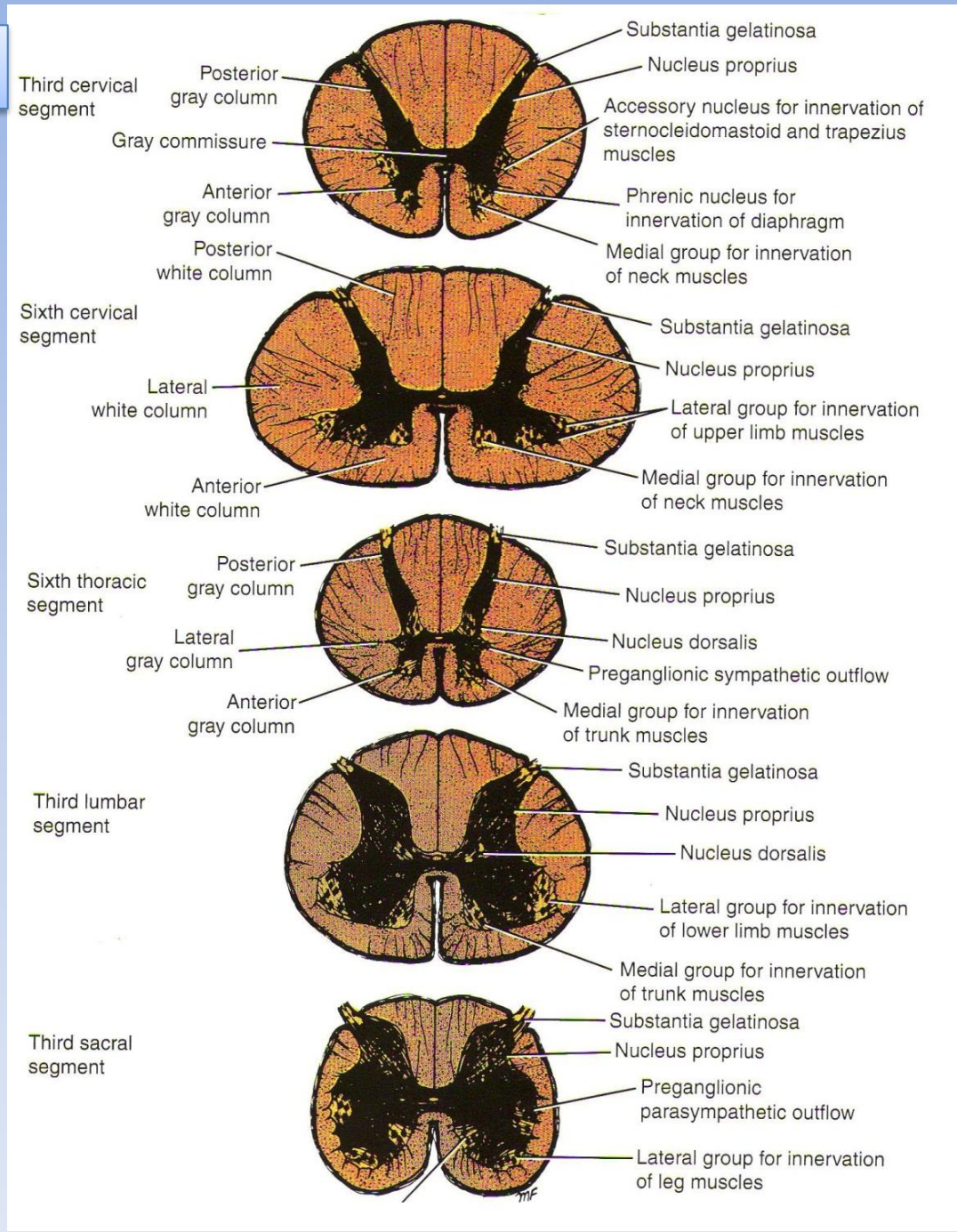

Nerve Cell Groups in the Lateral Gray Columns

- This group of cells form the small lateral gray column, which extends from the first thoracic to the second or third lumbar segment of the spinal cord.
- The cells are relatively small and give rise to preganglionic sympathetic fibers.
- A similar group of cells found in the second, third, and fourth sacral segments of the spinal cord give rise to preganglionic parasympathetic fibers

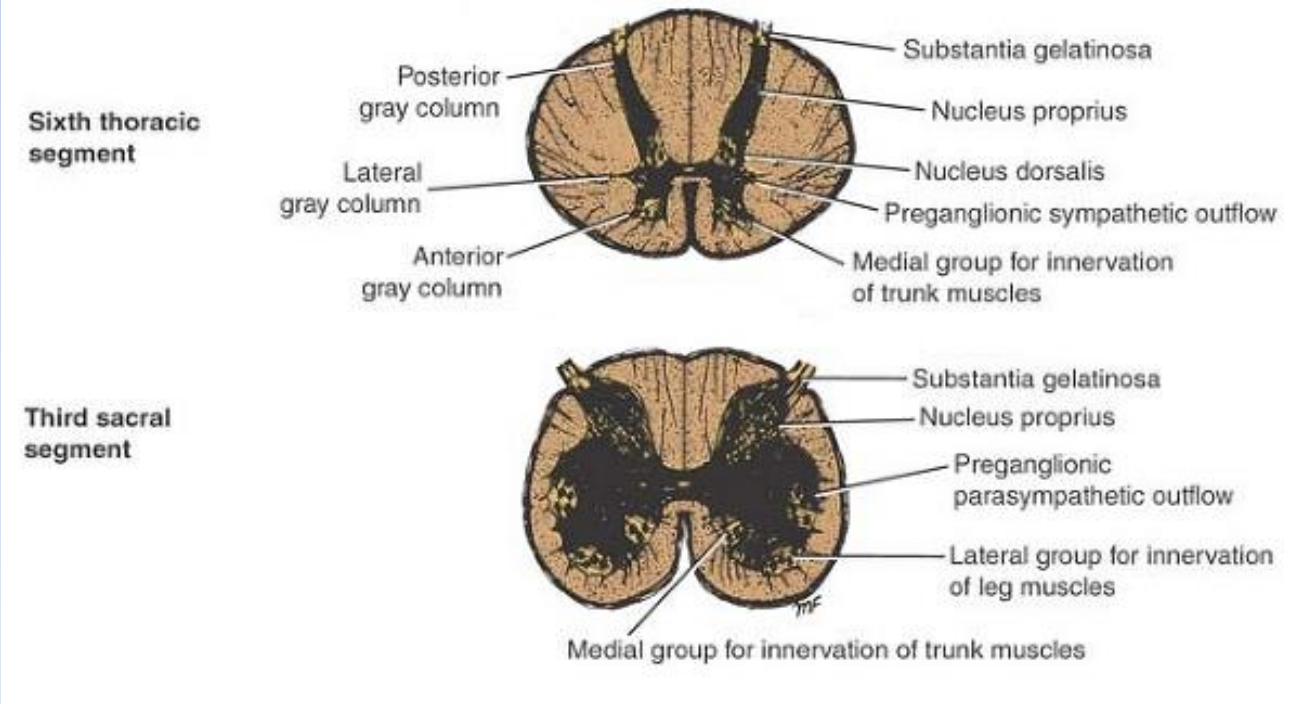

The Gray Commissure and Central Canal

- In transverse sections of the spinal cord, the anterior and posterior gray columns on each side are connected by a transverse gray commissure, so that the gray matter resembles the letter H.
- in the center of the gray commissure is situated the central canal.
- The part of the gray commissure that is situated posterior to the central canal is often referred to as the posterior gray commissure; similarly, the part that lies anterior to the canal is called the anterior gray commissure.

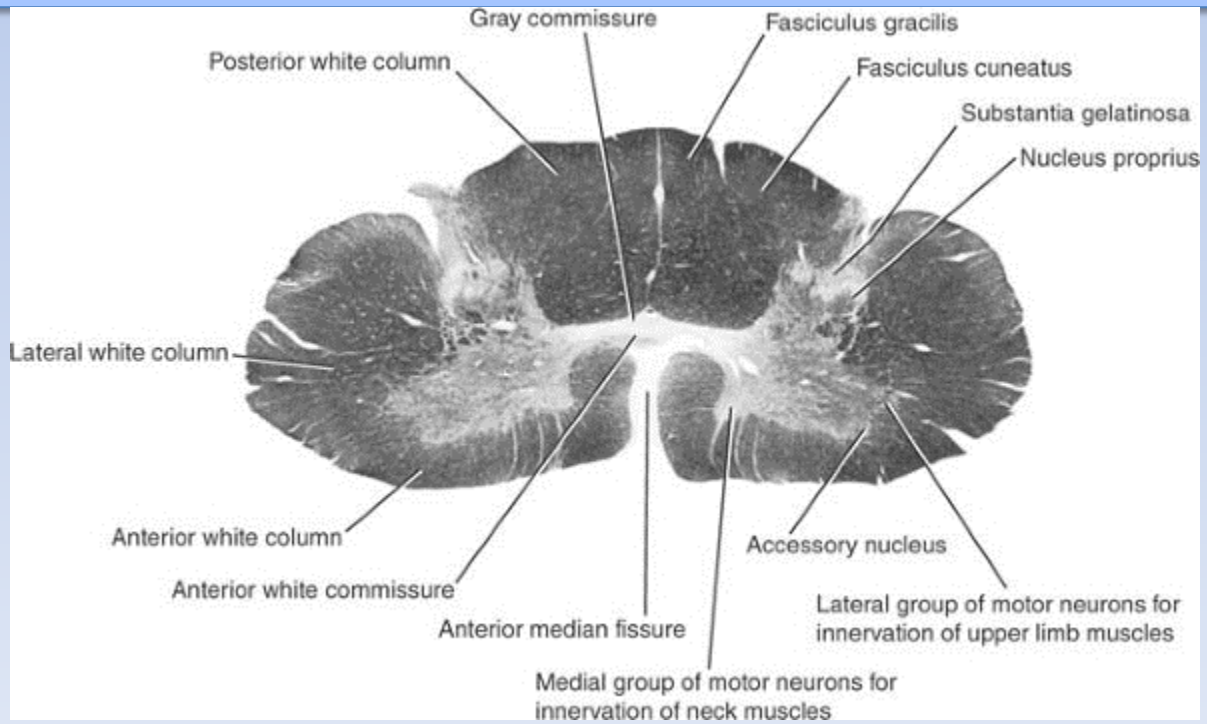

Central Canal

- The central canal is present throughout the spinal cord.
- Superiorly, it is continuous with the central canal of the caudal half of the medulla oblongata, and above this, it opens into the cavity of the fourth ventricle.
- Inferiorly in the conus medullaris, it expands into the fusiform terminal ventricle and terminates below within the root of the filum terminal.
- It is filled with cerebrospinal fluid and is lined with ciliated columnar epithelium, the ependyma.
- Thus the central canal is closed inferiorly and opens superiorly into the fourth ventricle.

White Matter

- The white matter may be divided into **anterior**, **lateral**, and **posterior white columns** or **funiculi**.
- The anterior column on each side lies between the midline and the point of emergence of the anterior nerve roots; the lateral column lies between the emergence of the anterior nerve roots and the entry of the posterior nerve roots; the posterior column lies between the entry of the posterior nerve roots and the midline.

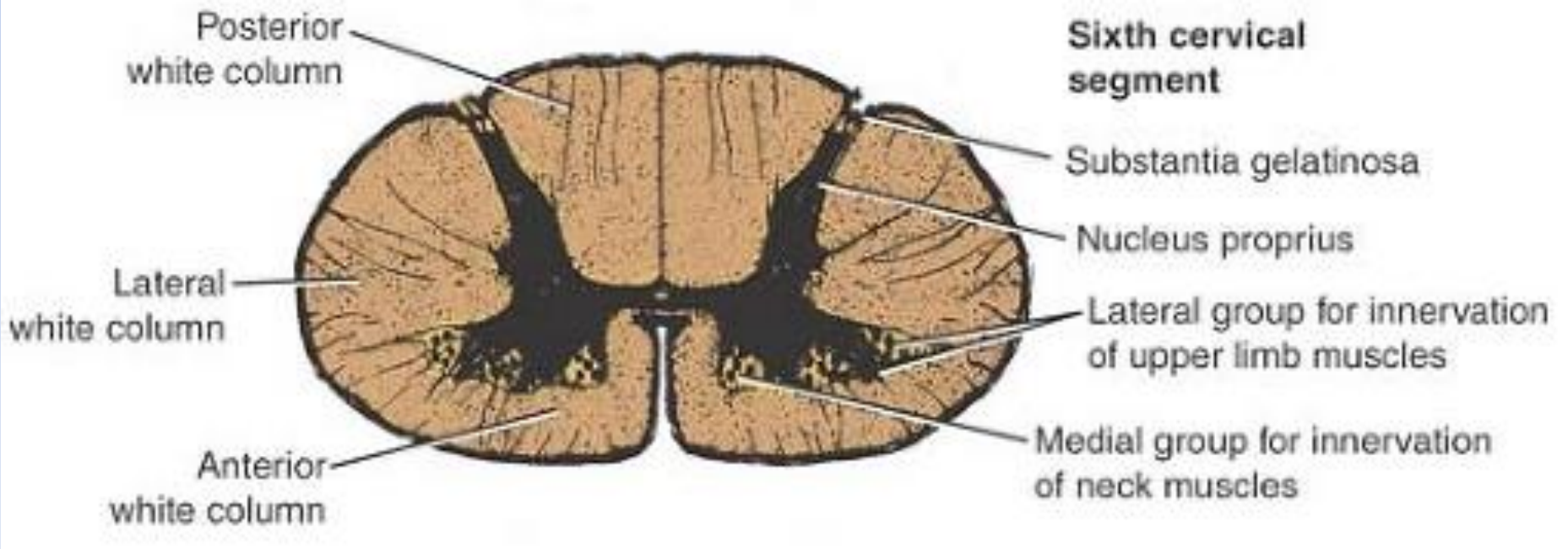

The Structure of the White matter

- As in other regions of the central nervous system, the white matter of the spinal cord consists of a mixture of nerve fibers, neuroglia, and blood vessels.
- It surrounds the gray matter, and its white color is due to the high proportion of myelinated nerve fibers.
- For purposes of description, the spinal tracts are divided into ascending, descending, and intersegmental tracts, and their relative position in the white matter are described below.

The Ascending Tracts of the Spinal Cord

- On entering the spinal cord, the sensory nerve fibers of different size and functions are sorted out and segregated into nerve bundles or tracts in the white matter.
- The nerve fiber bundles ascend from the spinal cord to higher centers connecting the spinal cord with the brain and is referred to as the ascending tracts.
- The ascending tracts conduct afferent information, which may be divided into two main groups: (1) exteroceptive information, which originates from the outside the body, such as pain, temperature, and touch, and (2) proprioceptive information, which originates from inside the body, for example, from muscles and joints.

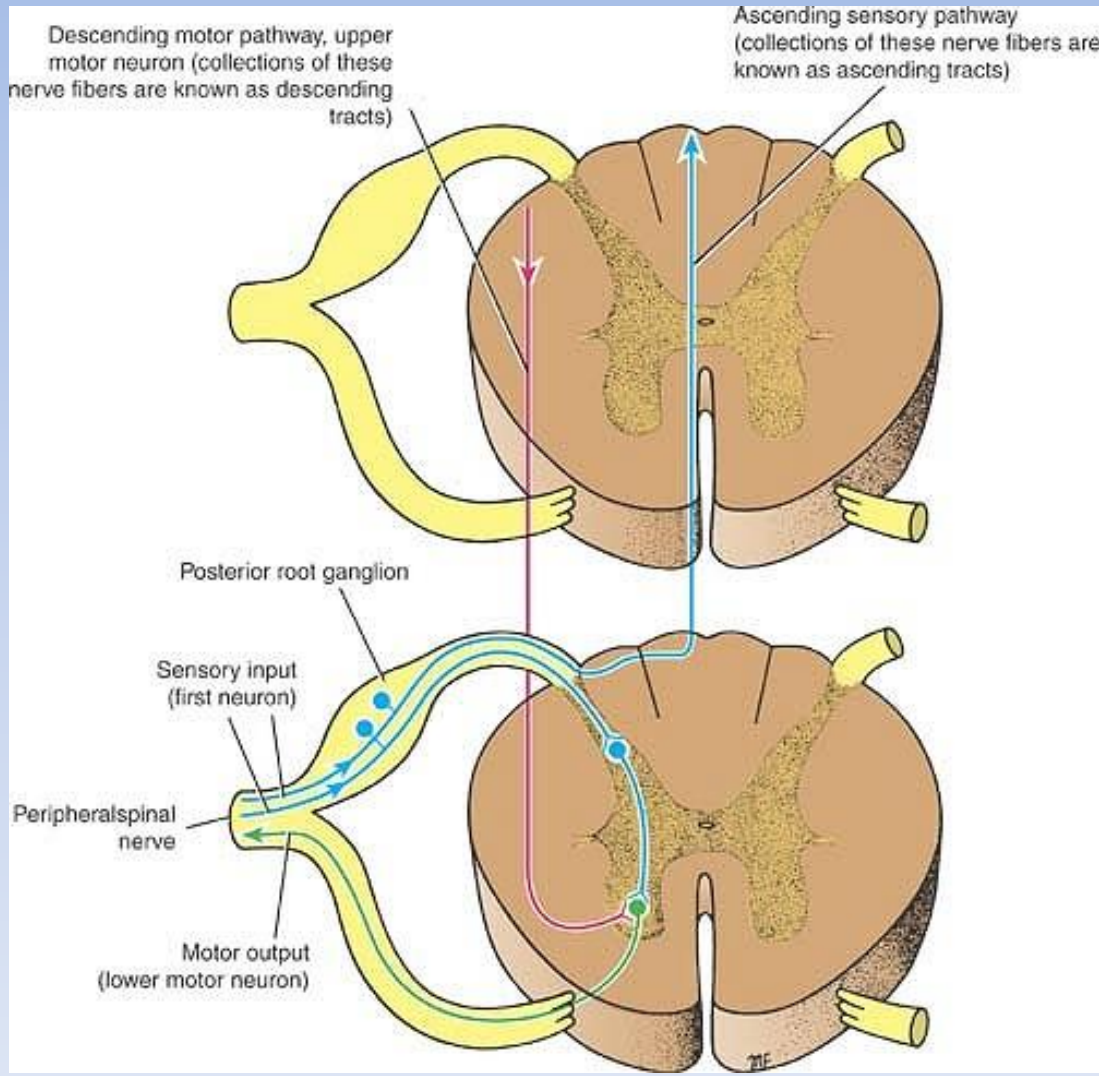

Anatomical Organization

- General information from the peripheral sensory endings is conducted through the nervous system by a series of neurons.
- In its simplest form, the ascending pathway to consciousness consists of three neurons.
- The first neuron, the first order-neuron, has its cell body in the posterior root ganglion of the spinal nerve.
- A peripheral process connects with a sensory receptor ending, whereas a central process enters the spinal cord through the posterior root to synapse on the second-order neuron.
- The second-order neuron gives rise to an axon that decussate (crosses to the opposite side) and ascend to the higher level of the central nervous system, where it synapses with the third-order neuron.
- The third-order neuron is usually in the thalamus and gives rise to projection fibers that passes to the sensory region of the cerebral cortex.

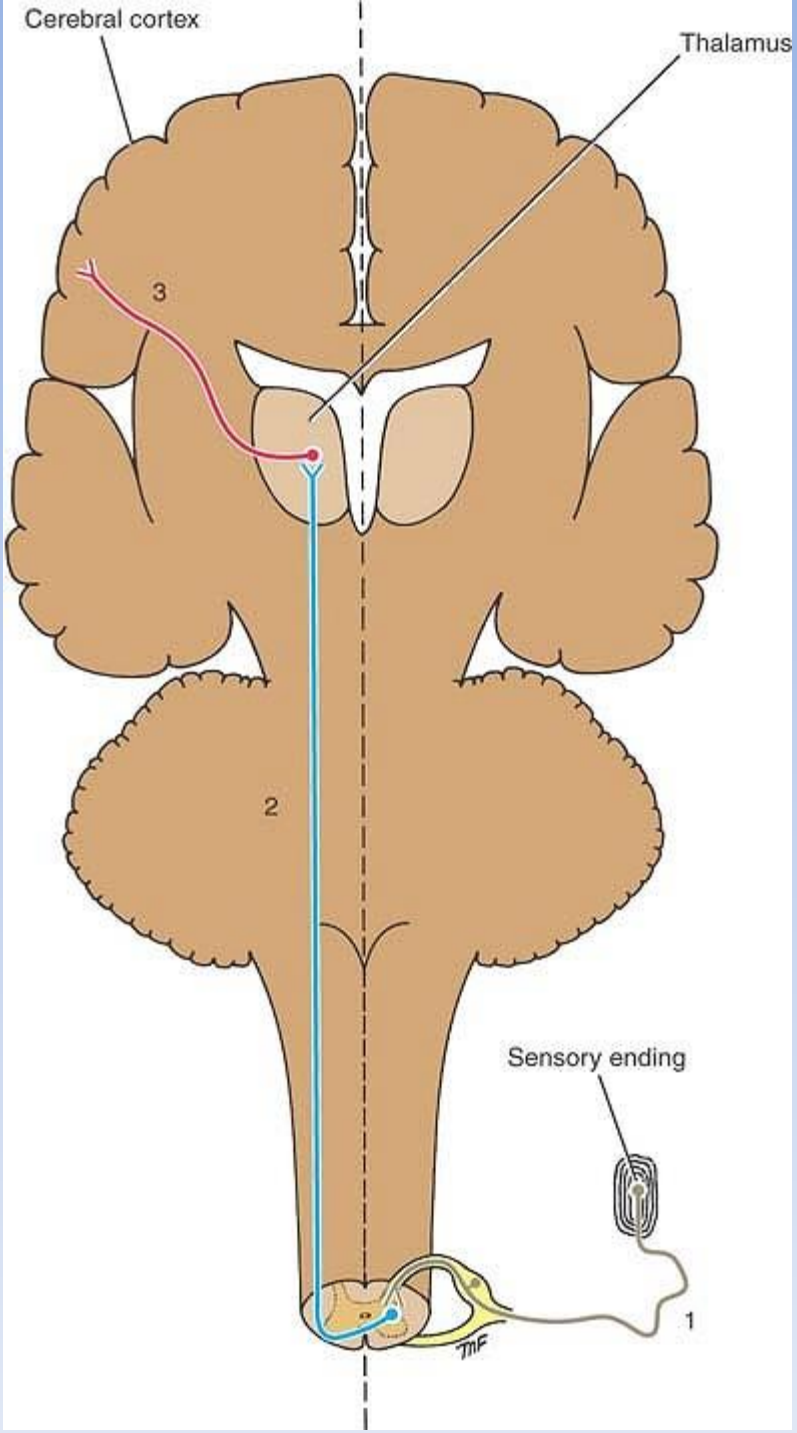

Pain and Temperature Pathways

Lateral Spinothalamic Tract

- The pain and thermal receptors in the skin and other tissues are free nerve endings.
- The axons entering the spinal cord from the posterior root ganglion (first-order neuron) proceed to the tip of the posterior gray column and divide into ascending and descending branches.
- These branches travel for a distance of one or two segments of the spinal cord and form the posterolateral tract.
- These fibers of the first-order neuron terminate by synapsing with cells in the posterior gray column, including cells in the substantia gelatinosa (second-order neuron).

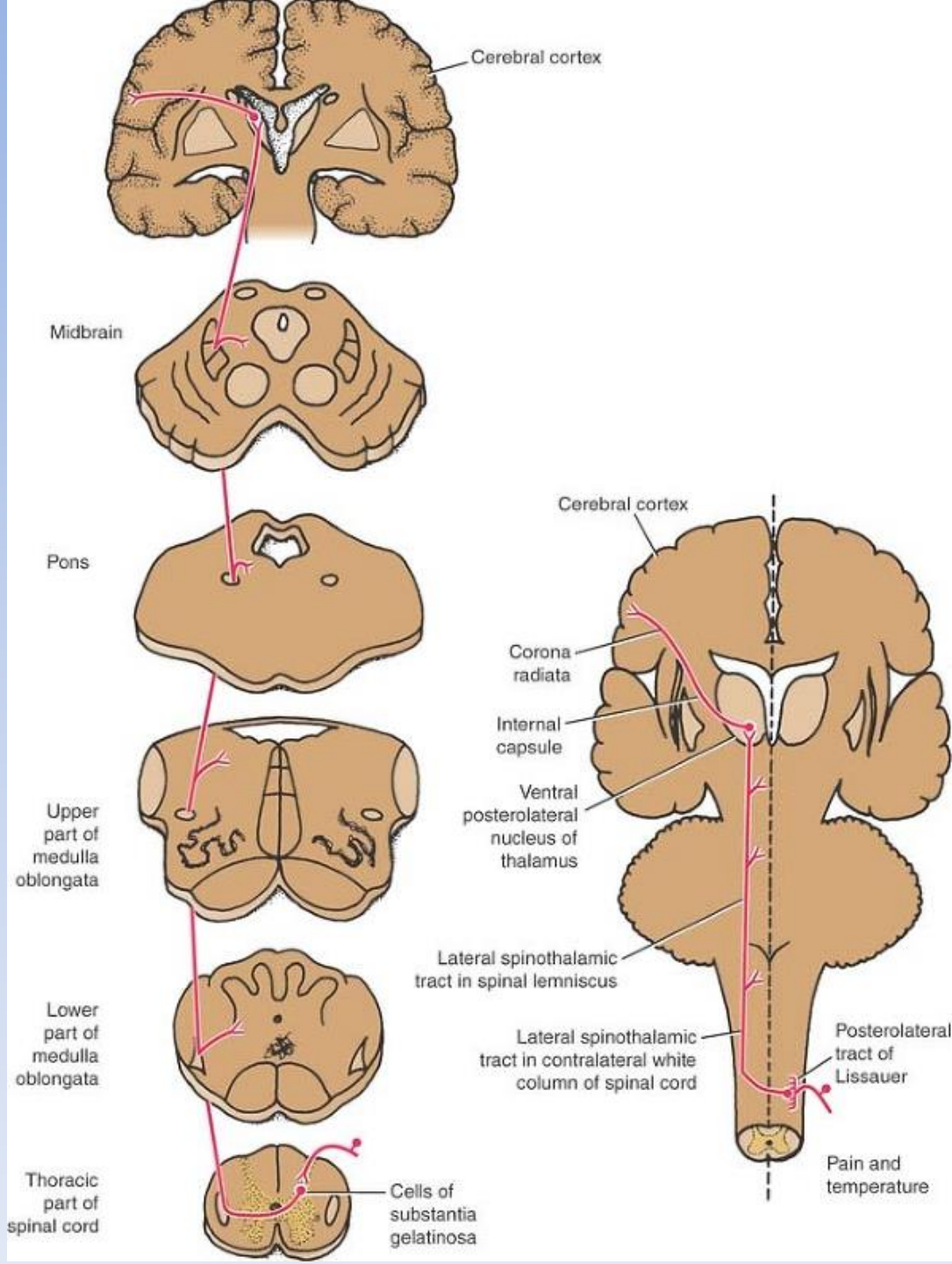

Lateral Spinothalamic Tract

- The axons of the second-order neurons now cross obliquely to the opposite side within one spinal segment of the cord, ascending in the contralateral white column as the lateral spinothalamic tract.
- It is now accompanied by the anterior spinothalamic tract and spinotectal tract; together they form the spinal lemniscus.

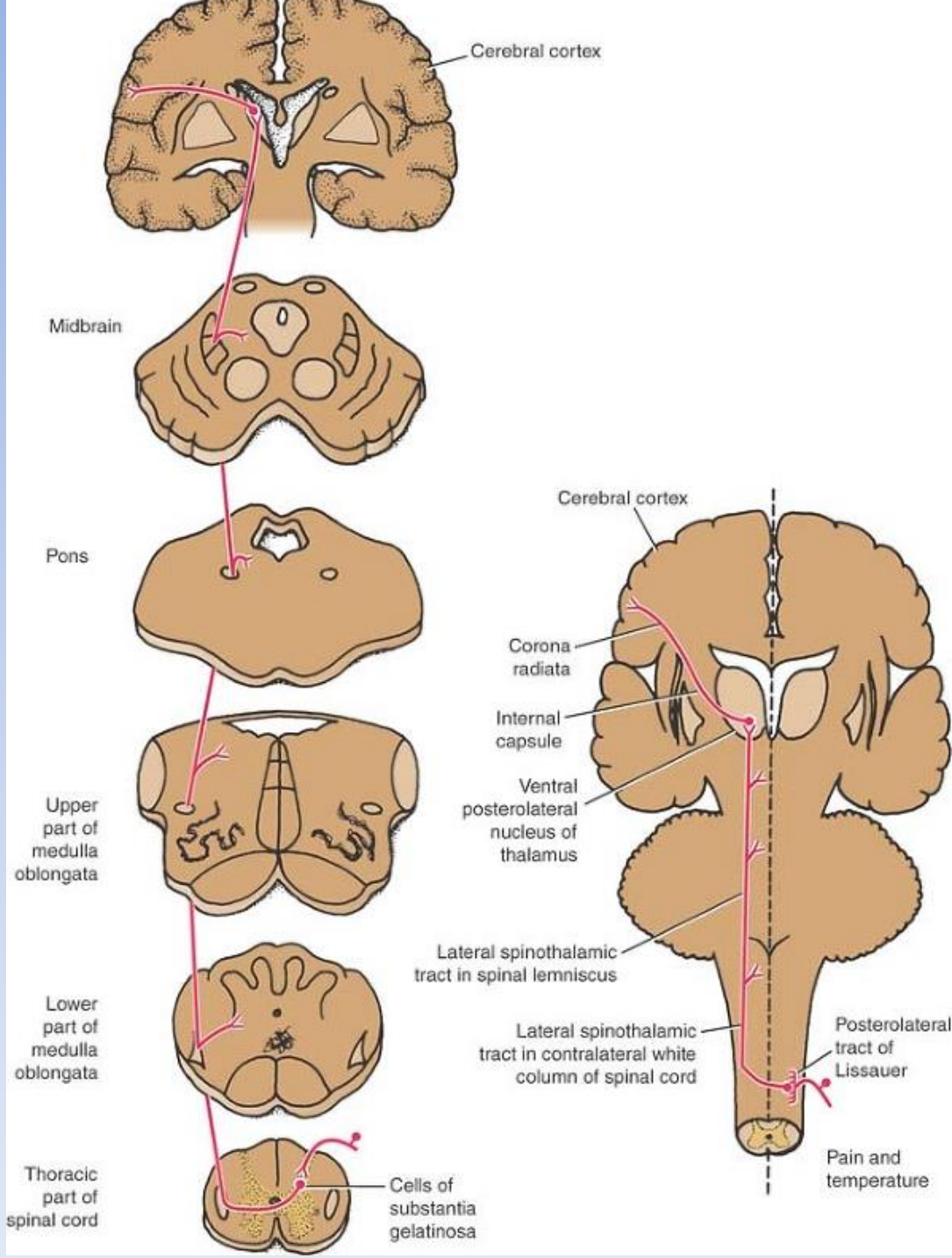

Lateral Spinothalamic Tract

- Many of the fibers of the lateral spinothalamic tract end by synapsing with the third-order neuron in the ventral posterolateral nucleus of the thalamus (third-order neuron).
- It is believed that here crude pain and temperature sensations are appreciated and emotional reactions are initiated.
- The axons of the third-order neurons in the ventral posterolateral nucleus of the thalamus now pass through the posterior limb of the internal capsule and the corona radiata to reach the somesthetic area in the postcentral gyrus of the cerebral cortex.

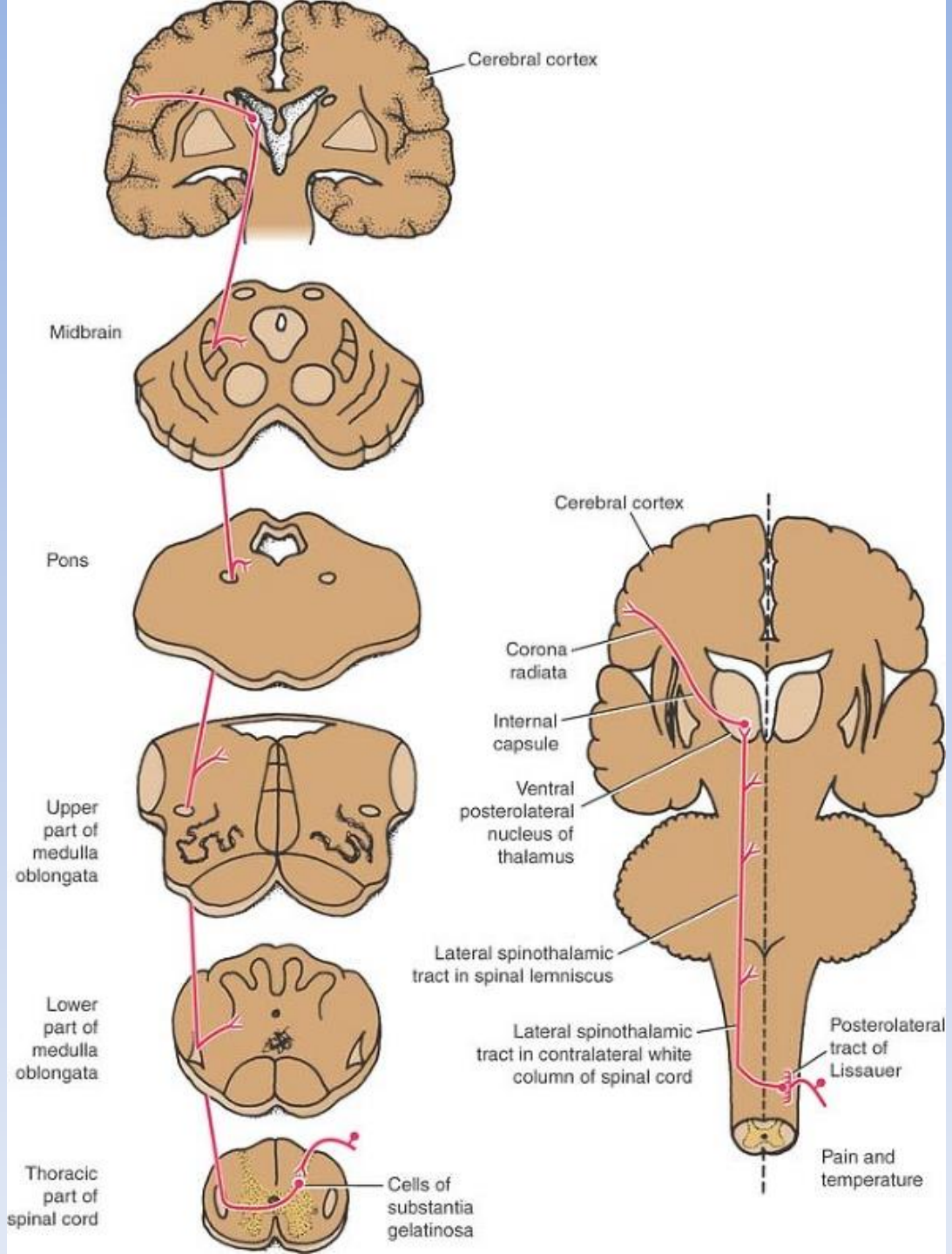

Light Touch and Pressure Pathways

Anterior Spinothalamic Tract

- The axons entering the spinal cord from the posterior root ganglion proceed to the tip of the posterior gray column, where they divide into ascending and descending branches.
- These branches travel for a distance of one or two segments of the spinal cord, contributing to the posterolateral tract.
- It is believed that these fibers of the first-order neuron terminate by synapsing with the cells of the substantia gelatinosa group in the posterior gray column.
- The axon of the second-order neuron now cross very obliquely to the opposite side within several spinal segments, and ascend in the opposite anterolateral white column as the anterior spinothalamic tract.

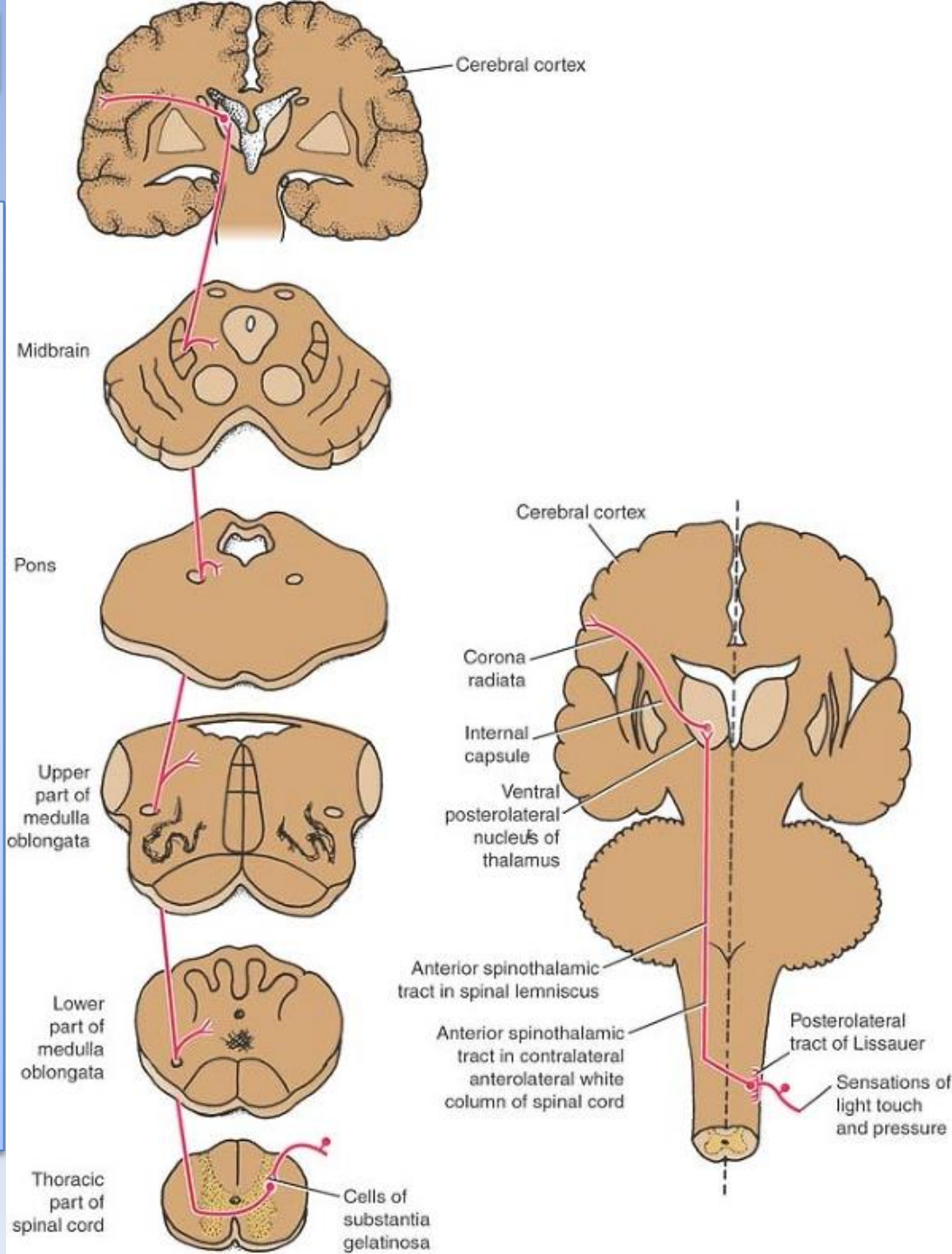

Anterior Spinothalamic Tract

- As the anterior spinothalamic tract ascends through the medulla oblongata, it accompanies the lateral spinothalamic tract and the spinotectal tract, all of which form the spinal lemniscus.
- The spinal lemniscus continues to ascend through the posterior part of the pons, and the tegmentum of the midbrain and the fibers of the anterior spinothalamic tract terminate by synapsing with the third-order neuron in the ventral posterolateral necleus of the thalamus.
- Crude awareness of touch and pressure is believed to be appreciated here.

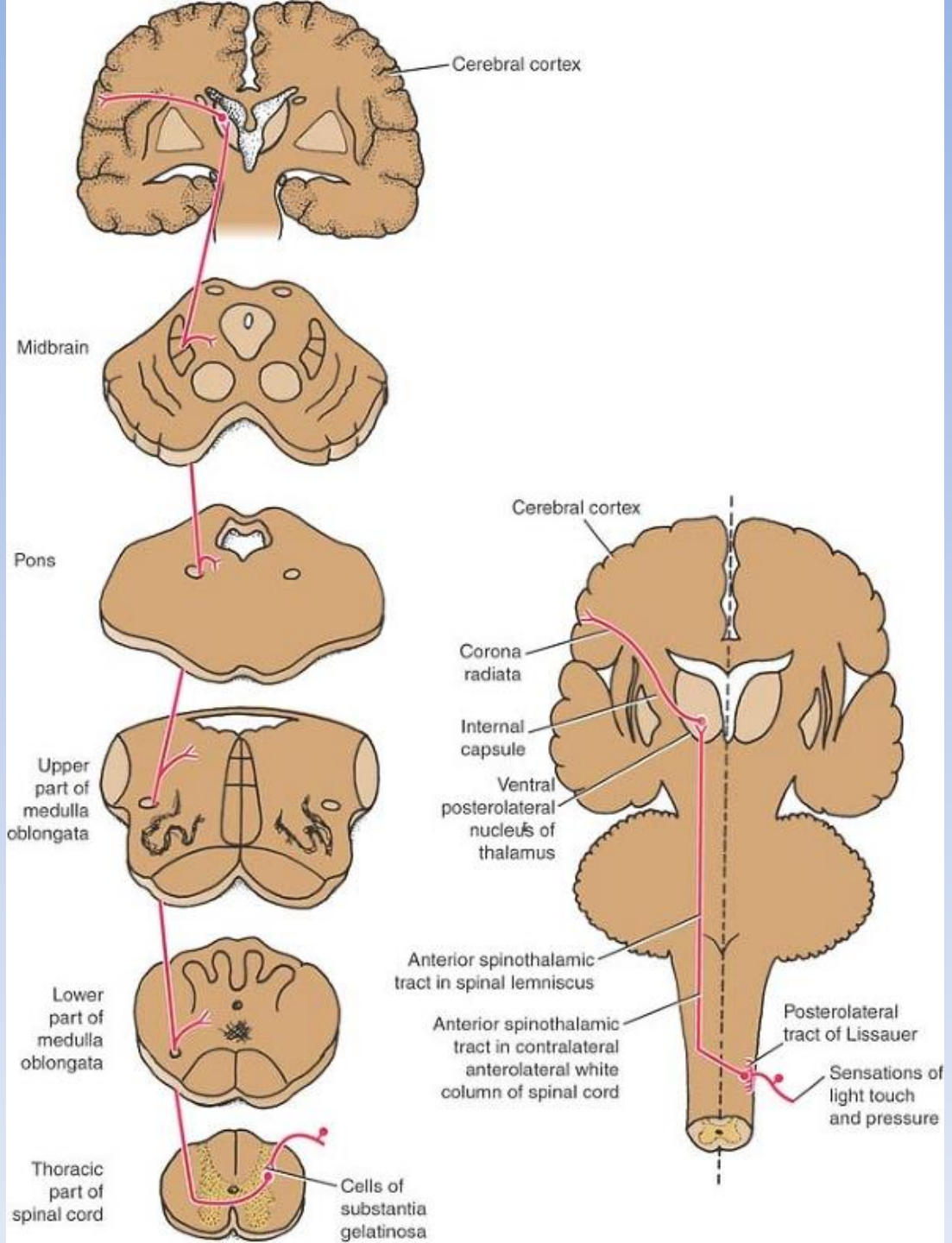

Anterior Spinothalamic Tract

- The axons of third-order neurons in the ventral posterolateral neuron of the thalamus pass through the posterior limb of the internal capsule and the corona radiata to reach the somesthetic area in the postcentral gyrus of the cerebral cortex.
- The contralateral half of the body is represented inverted, with the hand and mouth situated inferiorly.

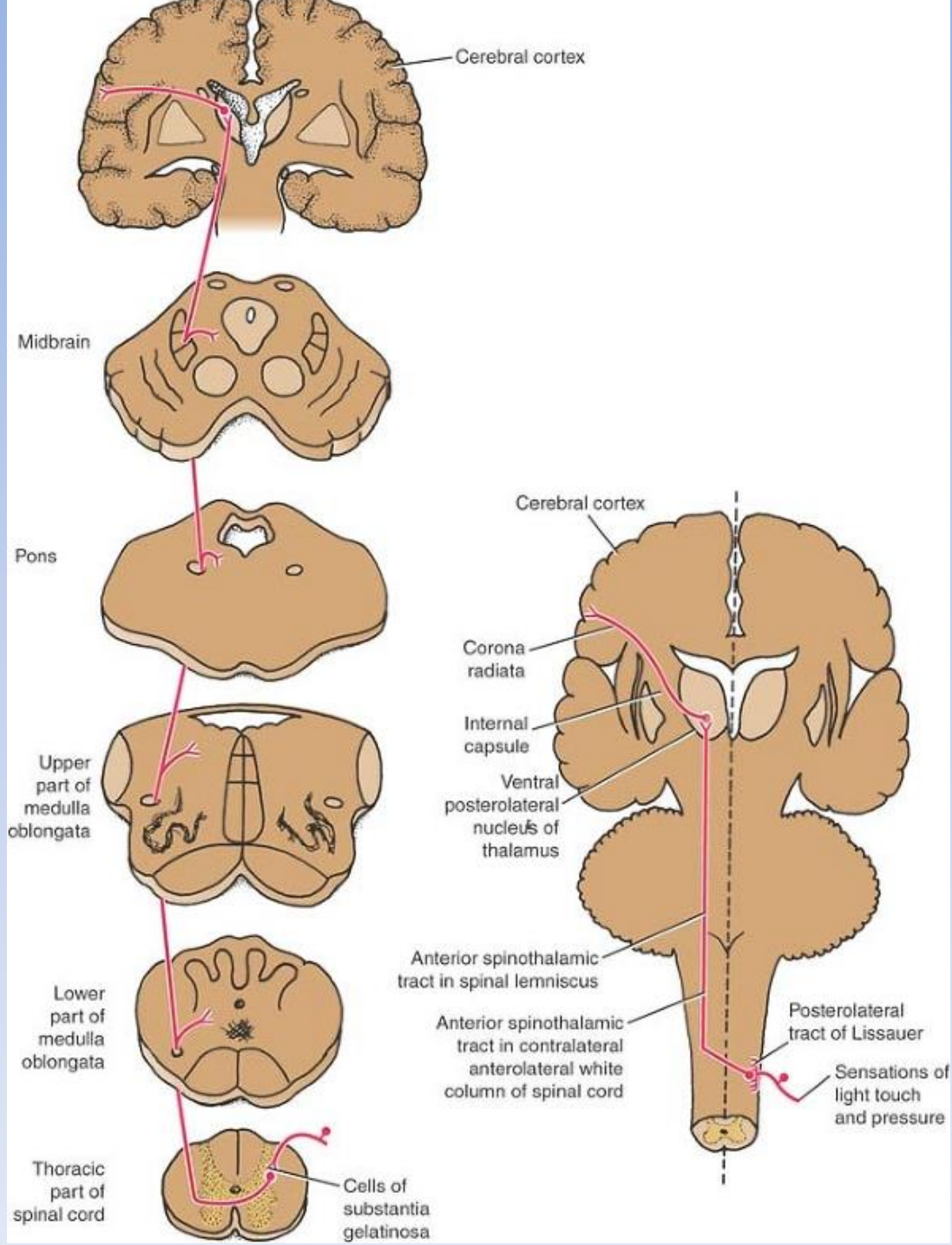

Discriminative Touch, Vibratory Sense, and Conscious Muscle Joint Sense

Posterior White Column: Fasciculus Gracilis and Fasciculus Cuneatus

- The axons enter the spinal cord from the posterior root ganglion and pass directly to the posterior white column of the same side.
- Here the fibers divide into long ascending and short descending branches.
- The short descending branches pass down a variable number of segments, giving off collateral branches that synapse with the cells in the posterior gray horn, with internuncial neurons, and with anterior horn cells.
- It is clear that these short descending fibers are involved with intersegmental reflexes.

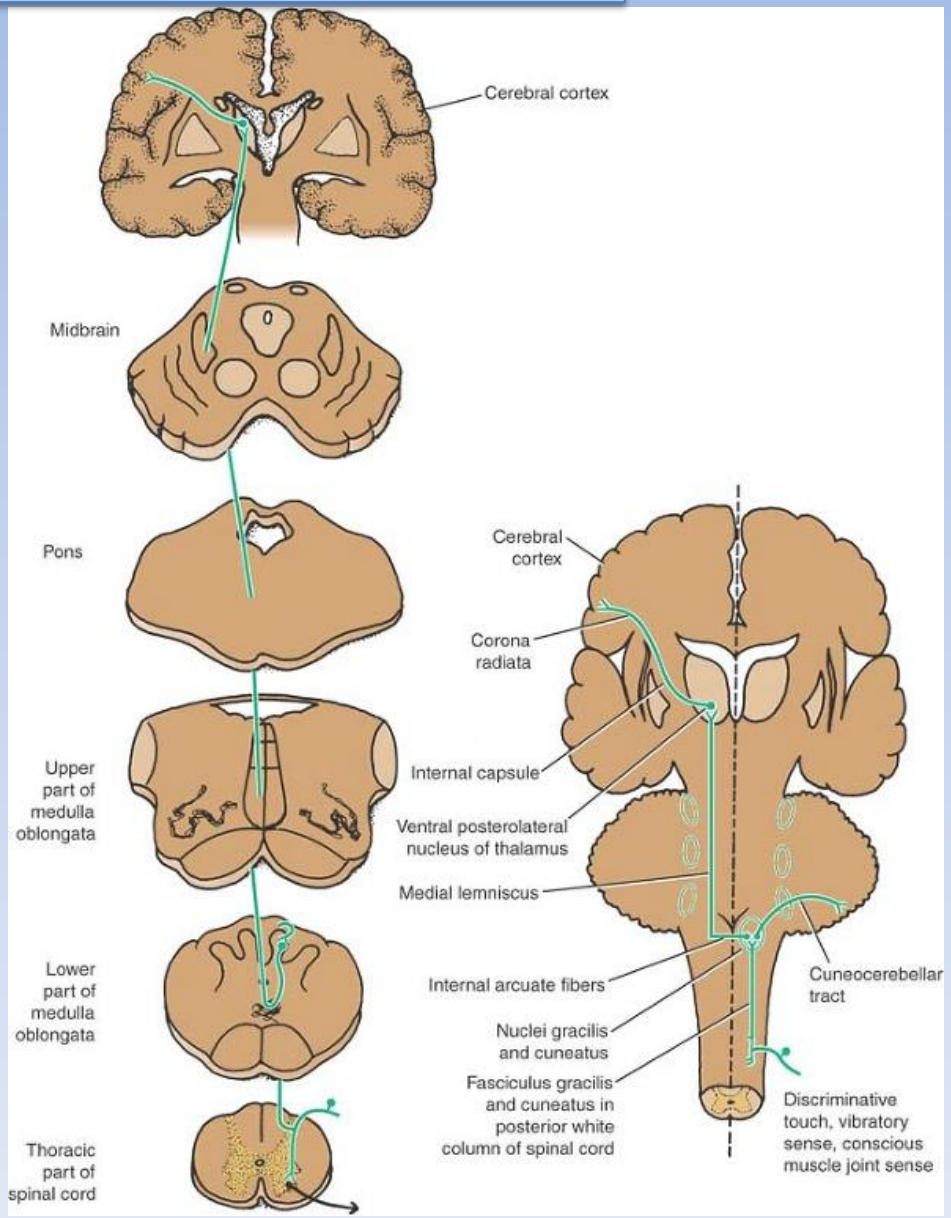

Fasciculus Gracilis and Fasciculus Cuneatus

- The long ascending fibers may also end by synapsing with cells in the posterior gray horn, with internuncial neurons, and with the anterior horn cells.
- The distribution may extend over numerous segments of the spinal cord and are involved with intersegmental reflexes.
- Many of the long ascending fibers travel upward in the posterior white column as the fasciculus gracilis and fasciculus cuneatus.
- The fibers of the fasciculus gracilis and fasciculus cuneatus ascend ipsilaterally and terminate by synapsing on the second-order neuron in the neuclei gracilis and cuneatus of the medulla oblongata.
- The axons of the second-order neurons called (internal arcate fibers) cross the median plane, decussating with the corresponding fibers of the opposite side in the sensory decussation.

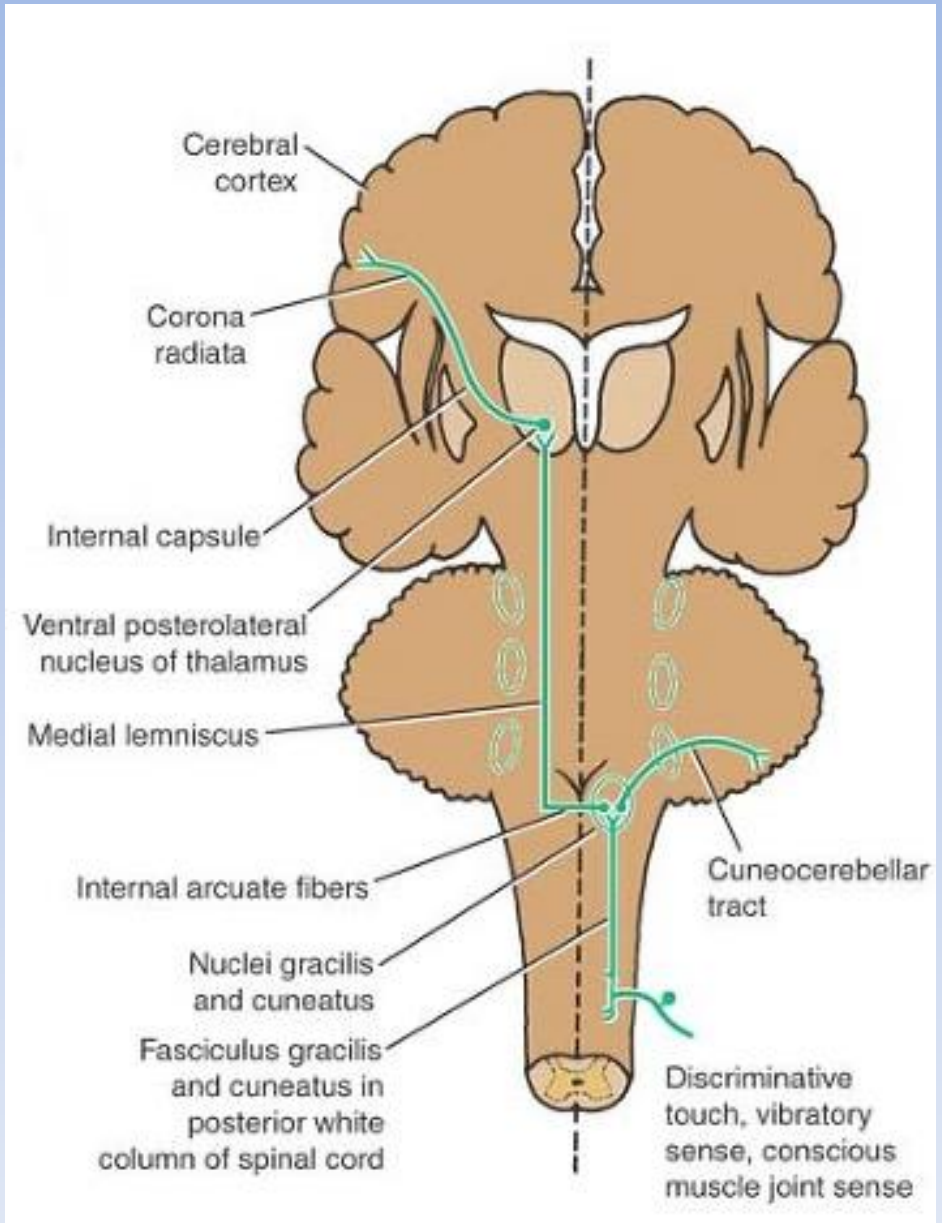

Fasciculus Gracilis and Fasciculus Cuneatus

- The fibers then ascend as a single compact bundle, the medial lemniscus, through the medulla oblongata, pons and midbrain.
- The fibers terminate by synapsing on the third-order neurons in the ventral posterolateral nucleus of the thalamus.
- The axons of the third-order neuron leave and pass through the posterior limb of the internal capsule and corona radiata to reach the somesthetic area in the postcentral gyrus of the cerebral cortex.
- The contralateral half of the body is represented inverted, with the hand and mouth inferiorly.

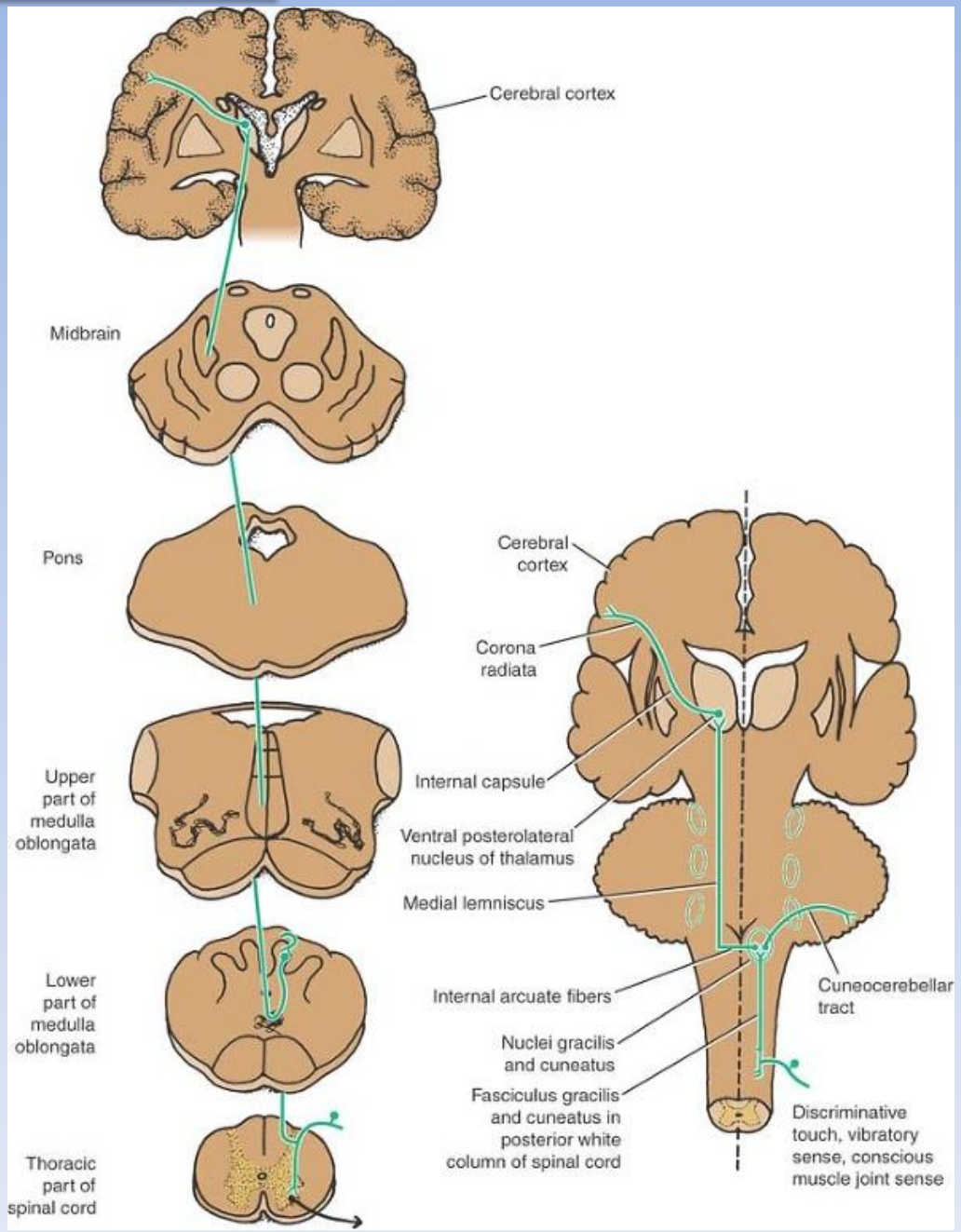

Fasciculus Gracilis and Fasciculus Cuneatus

- The impression of touch, exact localization, and two-point discrimination can be appreciated. Vibratory sense and the position of the different parts of the body can be continuously recognized.
- Many fibers in the fasciculus cuneatus from cervical and upper thoracic segments, having terminated on the second order neuron of the nucleus cuneatus, are relayed and travel as the axons of the second order neuron to enter the cerebellum through the inferior cerebellar peduncle of the same side.
- This pathway is referred to as the cuneocerebellar tract, and the fibers are known as the posterior external arcuate fibers. The function of these fibers is to convey information of muscle joint sense to the cerebellum.

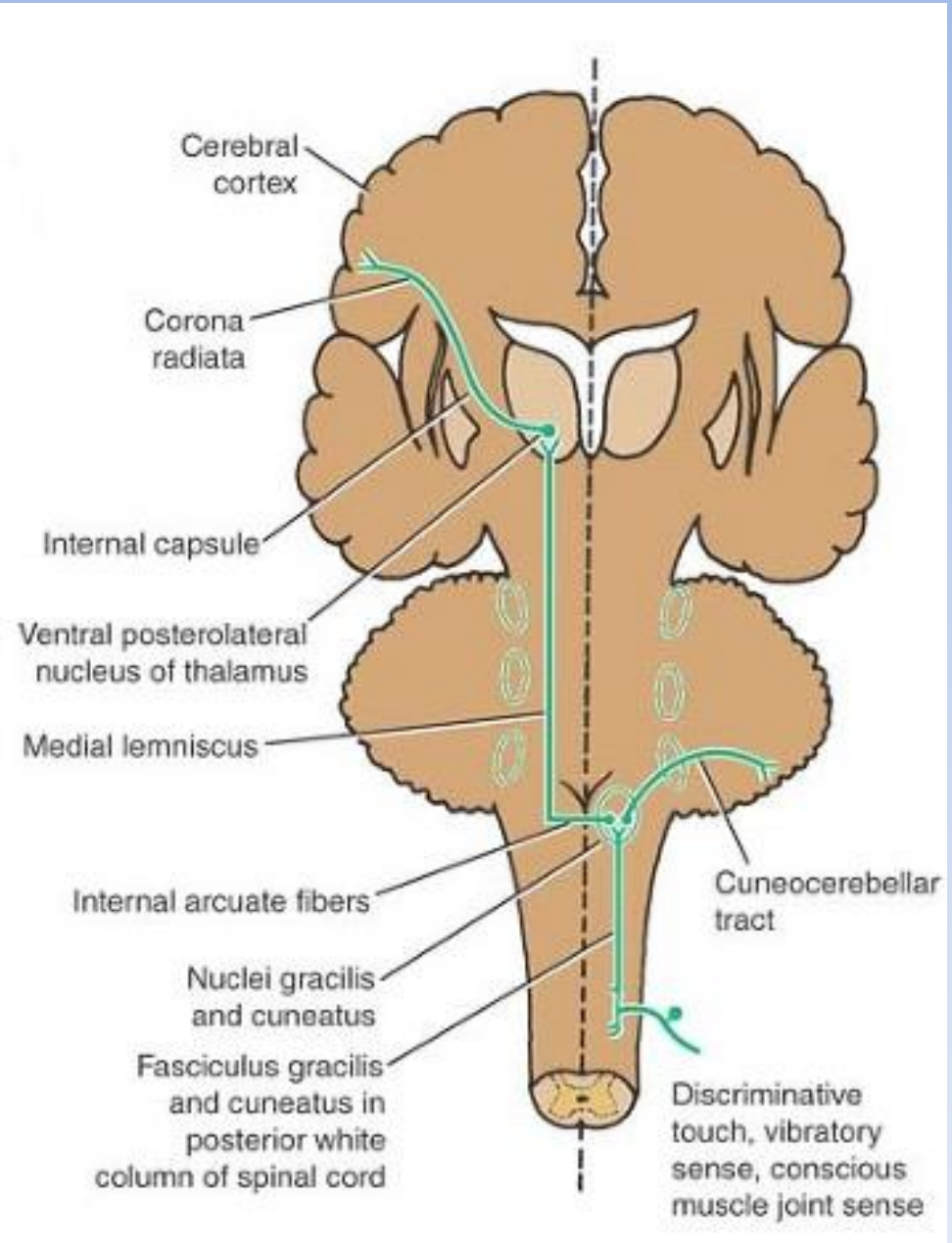

The Main Somatosensory Pathways to Consciousness

Sensation	Receptor	First-Order Neuron	Second-Order Neuron	Third-Order Neuron	Pathways	Destination
Pain and temperature	Free nerve endings	Posterior root ganglion	Substantia gelatinosa	Ventral posterolateral nucleus of thalamus	Lateral spinothalamic, spinal lemniscus	Posterior central gyrus
Light touch and pressure	Free nerve endings	Posterior root ganglion	Substantia gelatinosa	Ventral posterolateral nucleus of thalamus	Anterior spinothalamic, spinal lemniscus	Posterior central gyrus
Discriminative touch, vibratory sense, conscious muscle joint sense	Meissner's corpuscles, pacinian corpuscles, muscle spindles, tendon organs	Posterior root ganglion	Nuclei gracilis and cuneatus	Ventral posterolateral nucleus of thalamus	Fasciculi gracilis and cuneatus, medial lemniscus	Posterior central gyrus

Muscle joint Sense Pathways to the Cerebellum

Posterior Spinocerebellar Tract

- The axons entering the spinal cord from the posterior root ganglion enter the posterior gray horn and terminate by synapsing on the second-order neurons at the base of the posterior gray horn.
- These neurons are known collectively as the nucleus dorsalis (Clark's column).
- Axons of the second-order neurons enter the posterolateral part of the lateral white column on the same side and ascend as the posterior spinocerebellar tract to the medulla oblongata.
- Here the tract join the inferior cerebellar peduncle and terminate in the cerebellar cortex.

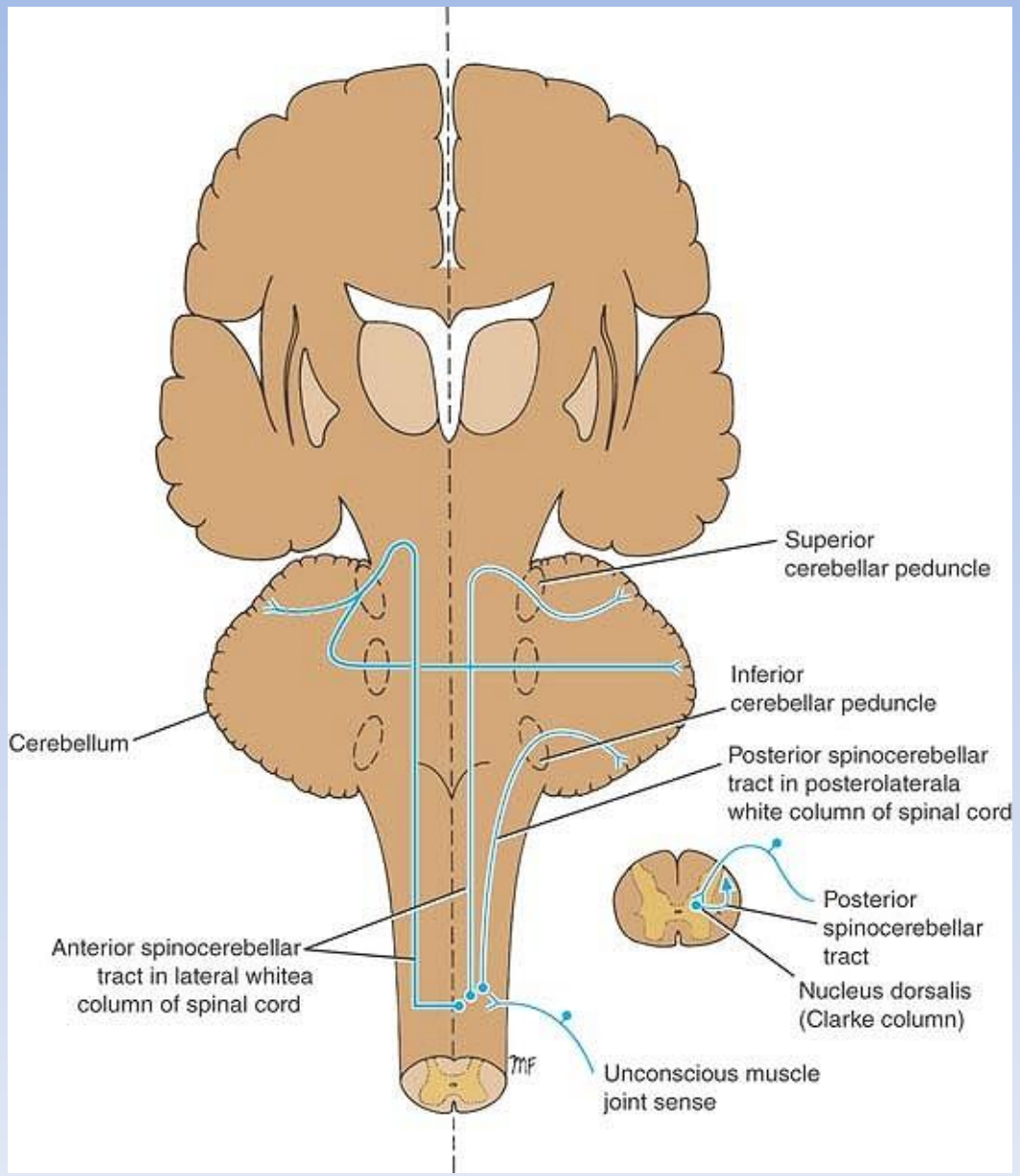

Posterior Spinocerebellar Tract

- The posterior spinocerebellar fibers receive muscle joint information from the muscle spindles, tendon organs, and joint receptors of the trunk and lower limbs.
- This information concerning tension of muscle tendons and the movements of muscles and joint is used by the cerebellum in the coordination of limb movements and maintenance of posture.

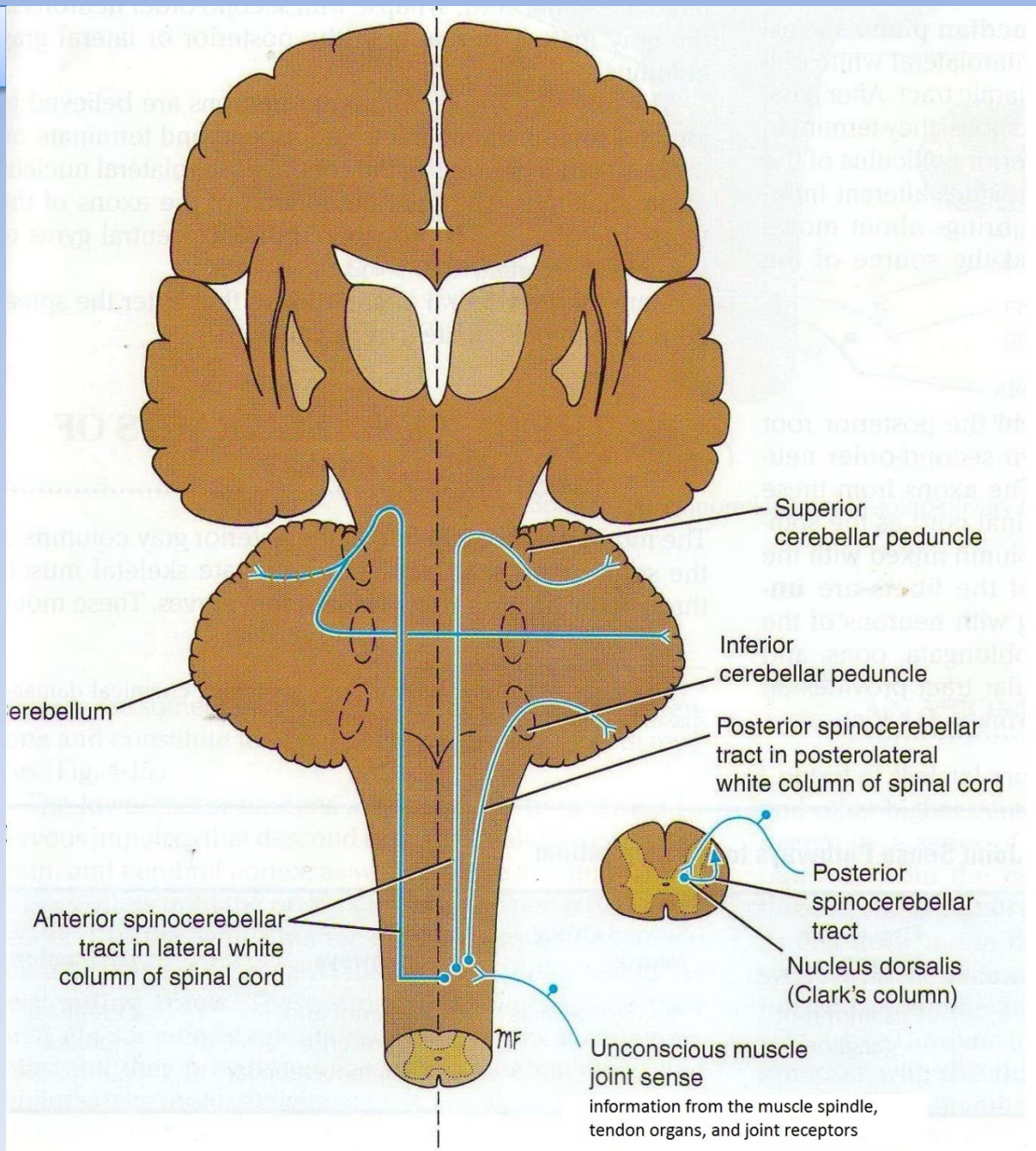

Anterior spinocerebellar Tract

- The axons entering the spinal cord from the posterior root ganglion terminate by synapsing with the second-order neuron in the nucleus dorsalis.
- The majority of the axons of the second-order neurons cross to the opposite side and ascend as the anterior spinocerebellar tract in the contralateral white column; the minority of the axons ascend as the anterior spinocerebellar tract in the lateral white column of the same side.
- The fibers, having ascended through the medulla oblongata and pons, enter the cerebellum through the superior cerebellar peduncle and terminate in the cerebellar cortex.
- The anterior spinocerebellar tract conveys muscle joint information from the muscle spindle, tendon organs, and joint receptors of the trunk and the upper and lower limbs.
- It is also believed that the cerebellum receives information from the skin and superficial fascia by this tract.

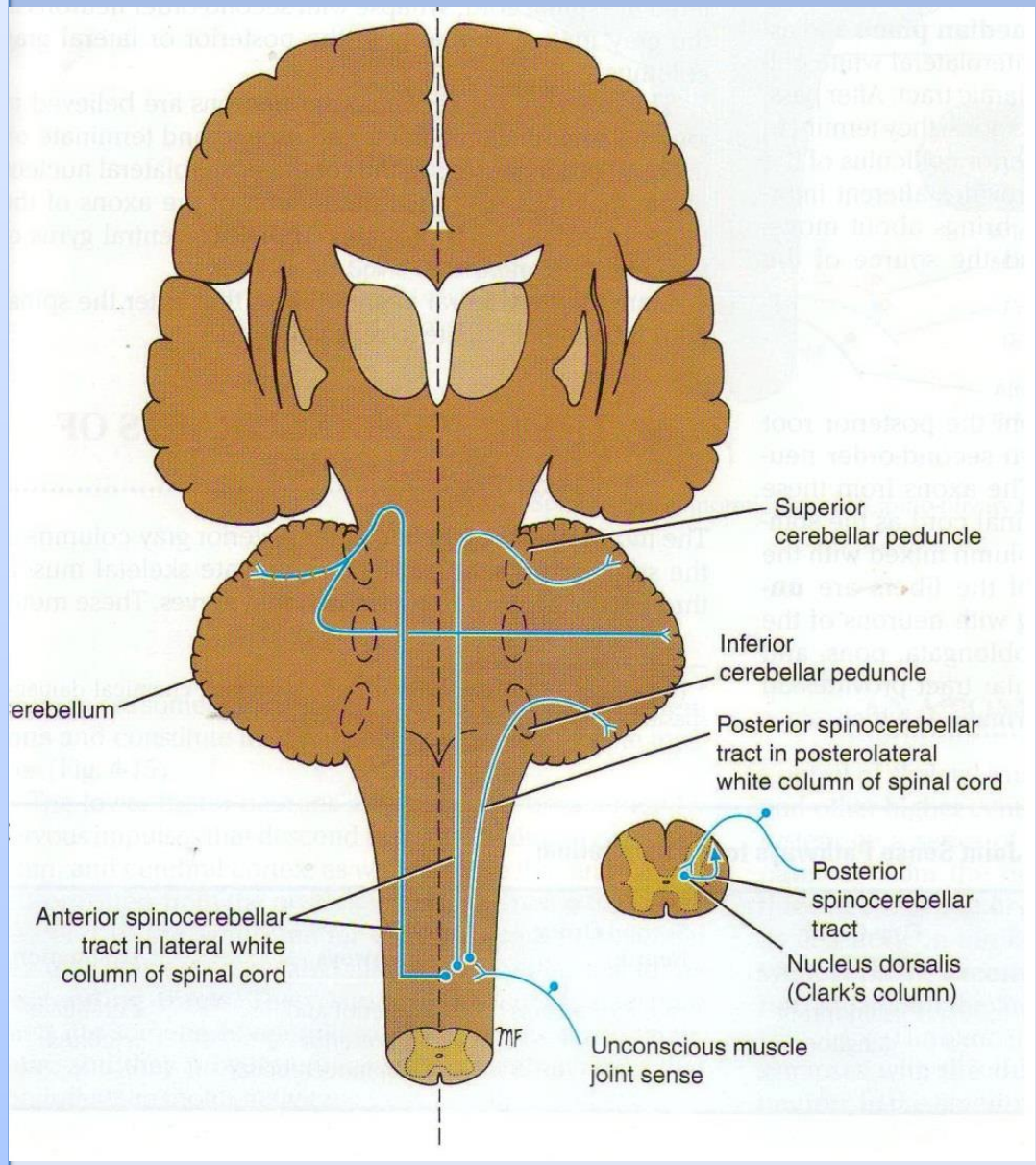

Muscle Joint Sense Pathways to the Cerebellum

Sensation	Receptor	First-Order Neuron	Second-Order Neuron	Pathways	Destination
Unconscious muscle joint sense	Muscle spindles, tendon organs, joint receptors	Posterior root ganglion	Nucleus dorsalis	Anterior and posterior spinocere-bellar	Cerebellar cortex

Other Ascending Pathways

Spinotectal Tract

- This pathway provides afferent information for spinovisual reflexes and brings about movements of the eye and head toward the source of the stimulation.

Spinoreticular Tract

- The spinoreticular tract provides an afferent pathway for the reticular formation, which plays an important role in influencing levels of the consciousness.

Spino-olivary Tract

- The spino-olivary tract conveys information to the cerebellum from the cutaneous and proprioceptive organs.

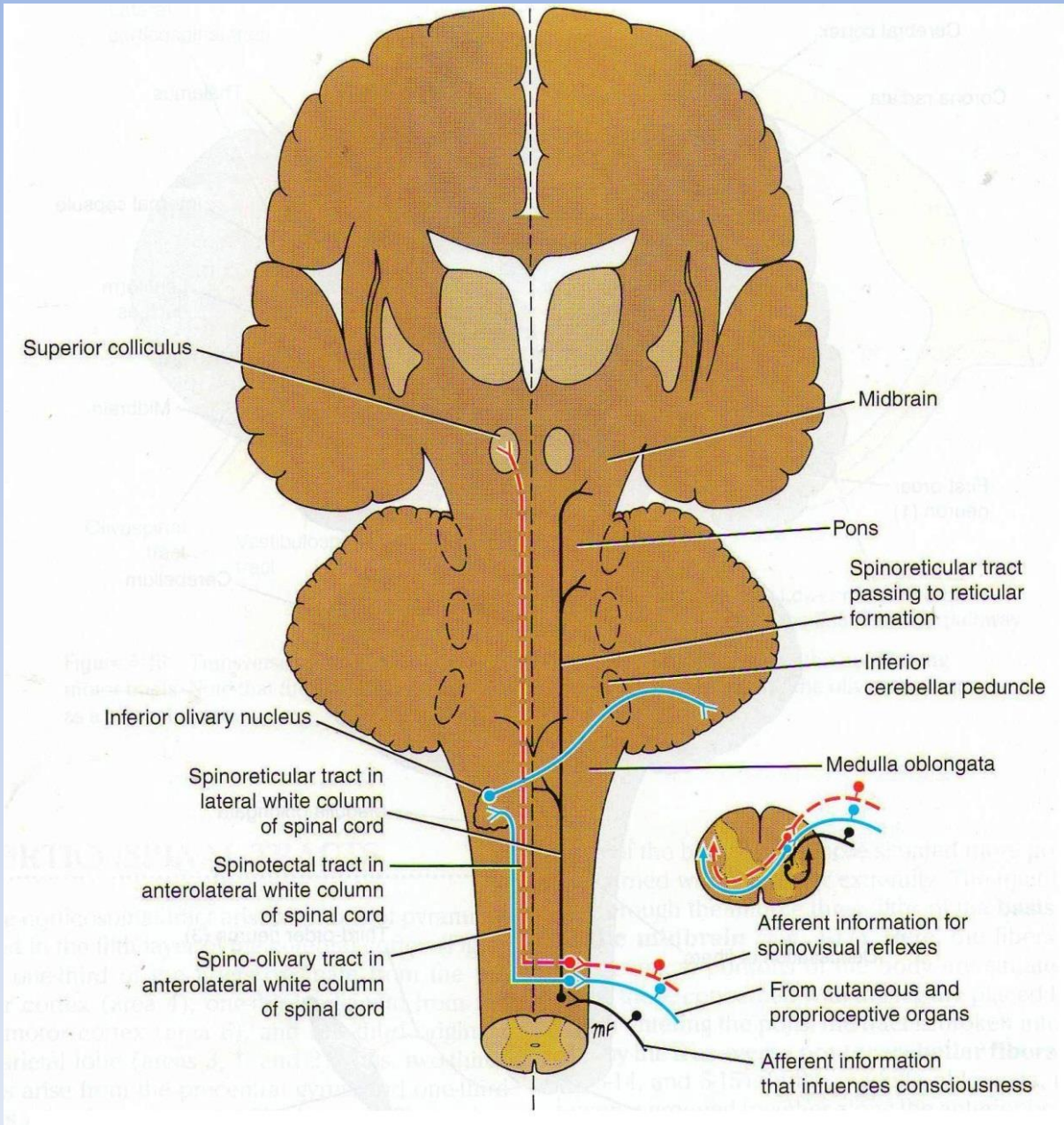

THE DESCENDING TRACTS OF THE SPINAL CORD

- The motor neurons situated in the anterior gray columns of the spinal cord send axons to innervate skeletal muscle through the anterior roots of the spinal nerves.
- These motor neurons are sometimes referred to as the lower motor neurons and constitute the final common pathway to the muscles.
- The nerve fibers that descend in the white matter from different supraspinal nerve centers (from the medulla oblongata, pons, midbrain, and cerebral cortex) are segregated into nerve bundles called descending tracts.

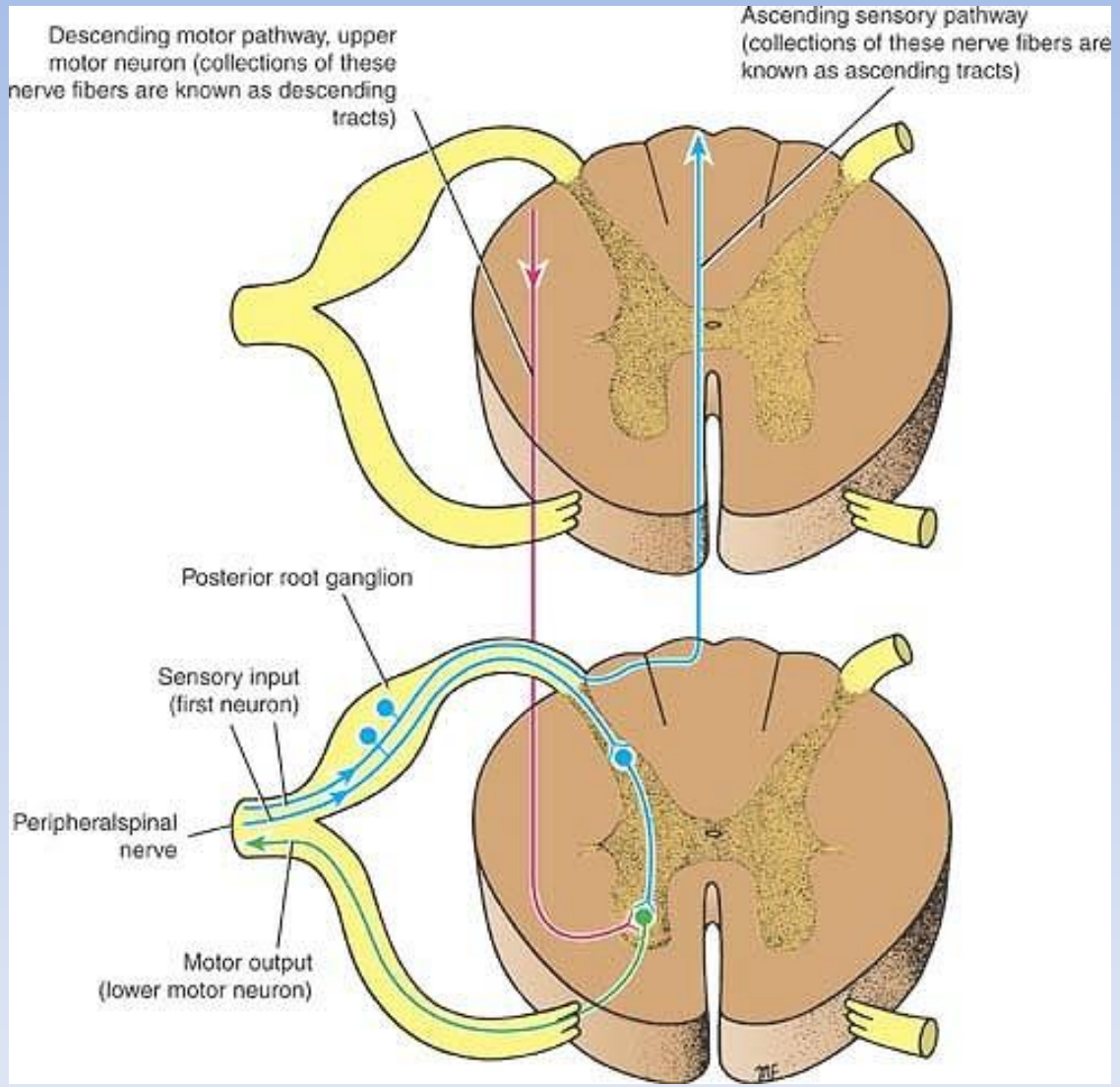

Corticospinal Tract

- Fibers of the corticospinal tract arise as axons of pyramidal cells situated in the fifth layer of the cerebral cortex. Two-thirds of the fibers arise from the precentral gyrus, and one-third of the fibers arise from the postcentral gyrus.
- Stimulation of different parts of the precentral gyrus produces movements of different parts of the opposite side of the body.
- The region controlling the face is situated inferiorly and the region controlling the lower limb is situated superiorly and on the medial side.
- The descending fibers converge in the corona radiata and then pass through the posterior limb of the internal capsule. The tract then continues through the basis peduncli of the midbrain.

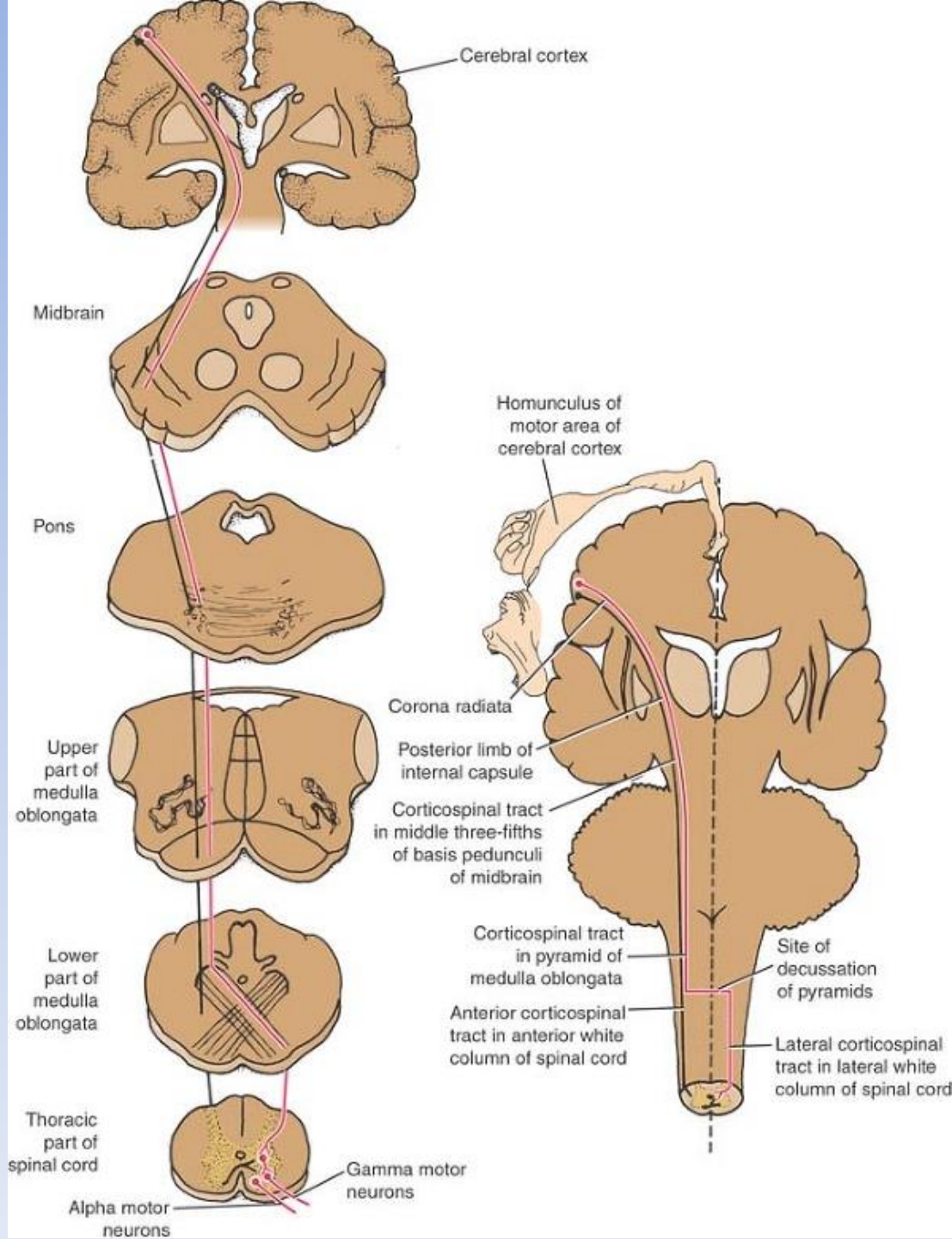

Anatomical Organization

- Control of skeletal muscle activity from the cerebral cortex and other higher centers is conducted through the nervous system by a series of neurons.
- The descending pathway from the cerebral cortex is often made up of three neurons. The first neuron, the first-order neuron, has its cell body in the cerebral cortex. Its axons descend to synapse on the second -order neuron, an internuncial neuron, situated in the anterior gray column of the spinal cord.
- The axon of the second-order neuron is short and synapses with third-order neuron, the lower motor neuron, in the anterior gray column.
- The axon of the third-order neuron innervates the skeletal muscle through the anterior root and spinal nerve. In some instances, the axon of the first-order neuron terminates directly on the third order neuron as in reflex arcs.

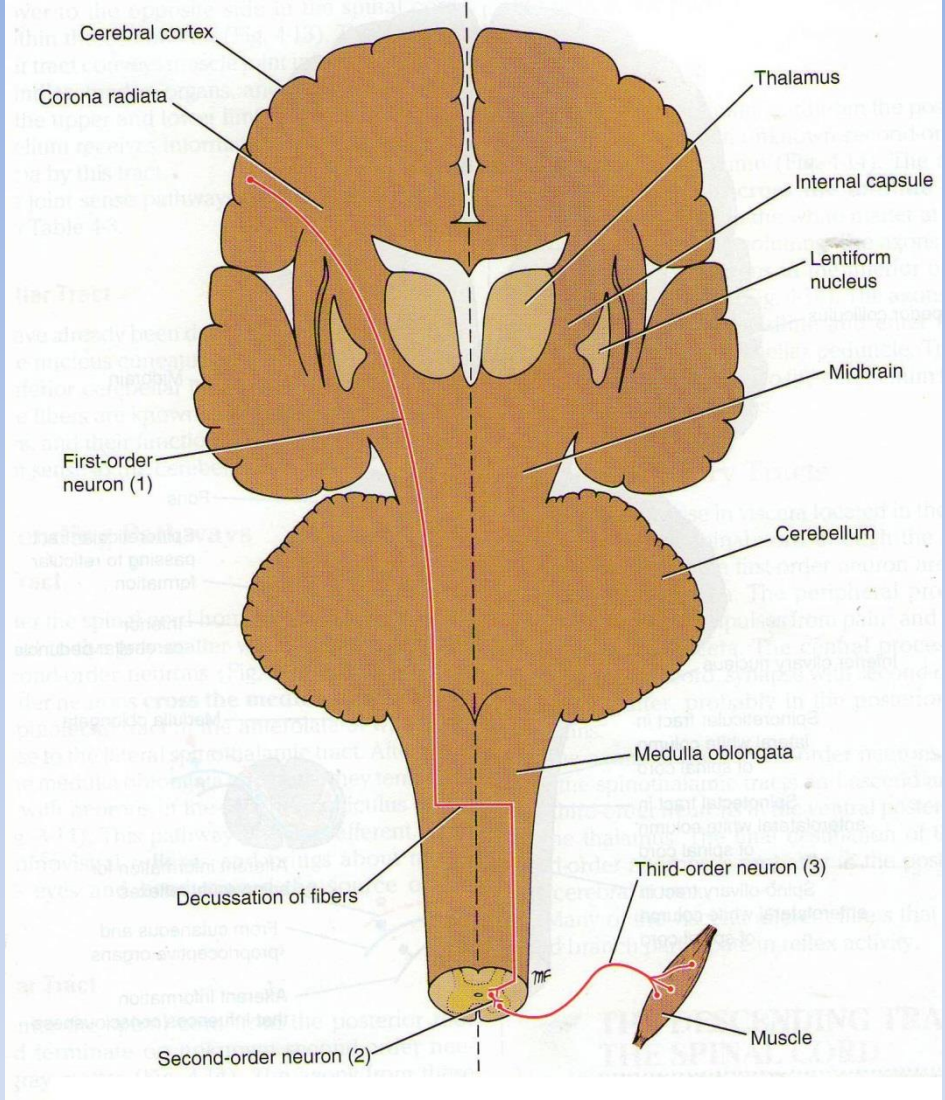

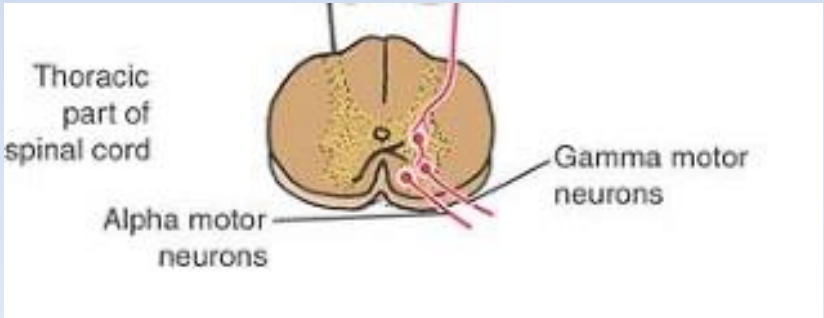

THE DESCENDING TRACTS OF THE SPINAL CORD

Pathway	Function	Origin	Site of Crossover	Destination	Branches to
Corticospinal tracts	Rapid, skilled, voluntary movements, especially distal ends of limbs	Primary motor cortex (area 4), secondary motor cortex (area 6), parietal lobe (areas 3, 1,&2)	Most cross at decussation of pyramids and descend as lateral corticospinal tracts; some continue as anterior corticospinal tracts and cross over at level of destination	Internuncial neurons or alpha motor neurons	Cerebral cortex, basal nuclei, red nucleus, olivary nuclei, reticular formation
Reticulospinal tracts	Inhibit or facilitate voluntary movement; hypothalamus controls sympathetic, para-sympathetic outflows	Reticular formation	Some cross at various levels	Alpha and gamma motor neurons	Multiple branches as they descend
Tectospinal tract	Reflex postural movements concerning sight	Superior colliculus	Soon after origin	Alpha and gamma motor neurons	?
Rubrospinal tract	Facilitates activity of flexor muscles and inhibits activity of extensor muscles	Red nucleus	Immediately	Alpha and gamma motor neurons	?
Vestibulospinal tract	Facilitates activity of extensor inhibits flexor muscles	Vestibular nuclei	Uncrossed	Alpha and gamma motor neurons	?
Olivospinal tract	Influence activity of the motor neurons	Inferior olivary nuclei	Cross in brainstem	? Alpha and gamma motor neurons	—

Intersegmental Tracts

- Short ascending and descending tracts that originate and end within the spinal cord exist in the anterior, lateral, and posterior white columns.
- The function of these pathways is to interconnect the neurons of different segmental levels, and the pathways are particularly important in intersegmental spinal reflexes.

Reflex Arc

- A reflex may be defined as an involuntary response to a stimulus. It depends on the integrity of the reflex arc.
- In its simplest form, a reflex arc consists of the following anatomical structures: (1) a receptor organ, (2) an afferent neurone, (3) an effector neuron, and (4) an effector organ.
- A reflex arc involving only one synapse is referred to as a monosynaptic reflex arc.
- In the spinal cord, reflex arc plays an important role in maintaining muscle tone, which is the basis for body posture.
- The receptor organ is situated in the skin, muscle, or tendon. The cell body of the afferent neuron is located in the posterior root ganglion, and the central axon of this first-order neuron terminates by synapsing on the effector neuron.
- Since the afferent fibers are of large diameter and are rapidly conducting and because of the presence of only one synapse, a very quick response is possible.

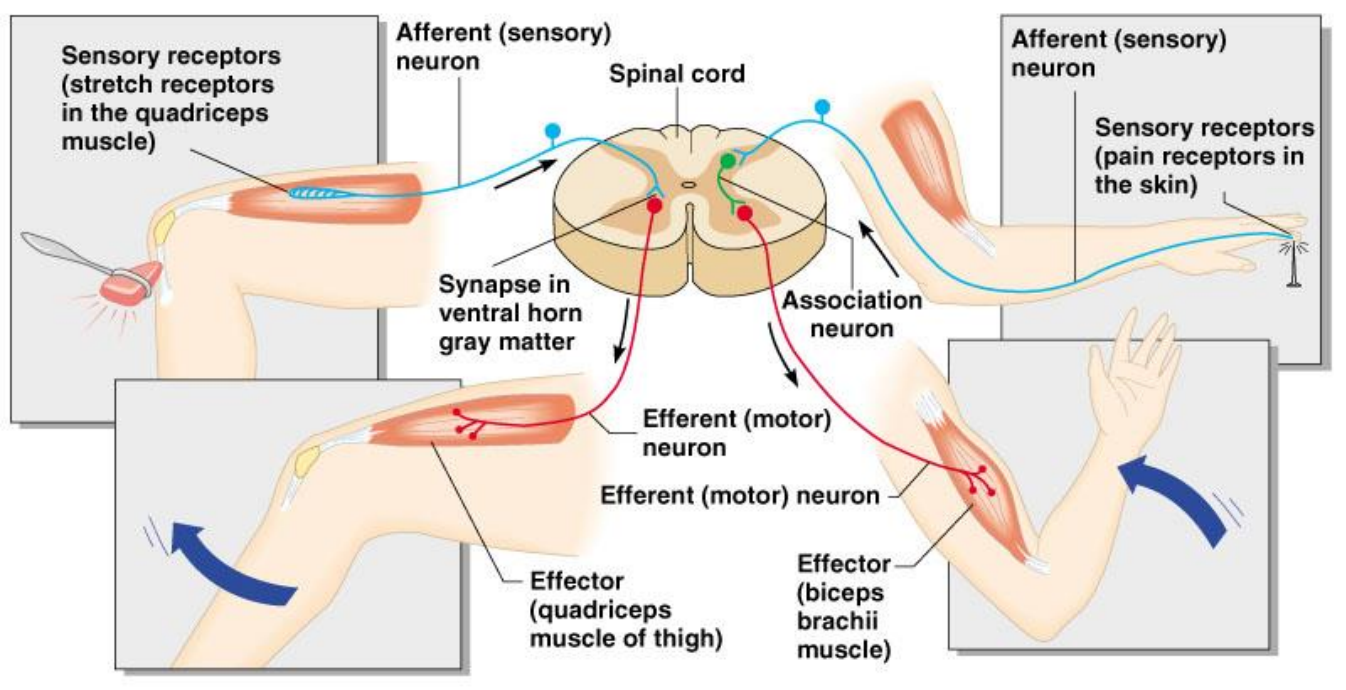

Dermatomes

- The skin over the entire body is supplied segmentally by the spinal nerves.
- This means that the spinal nerves innervate specific, constant segments of the skin.
- All spinal nerves except C1 supply branches to the skin. The skin segment supplied by the dorsal root of a spinal nerve is a dermatome.
- In the neck and trunk, the dermatomes form consecutive bands of skin. In the trunk, there is an overlap of adjacent dermatome nerve supply.
- Thus, there is a little loss of sensation if only a single nerve supply to a dermatome is interrupted.
- Since physicians know which spinal nerves are associated with each dermatome, it is possible to determine which segment of the spinal cord or spinal nerve is malfunctioning.

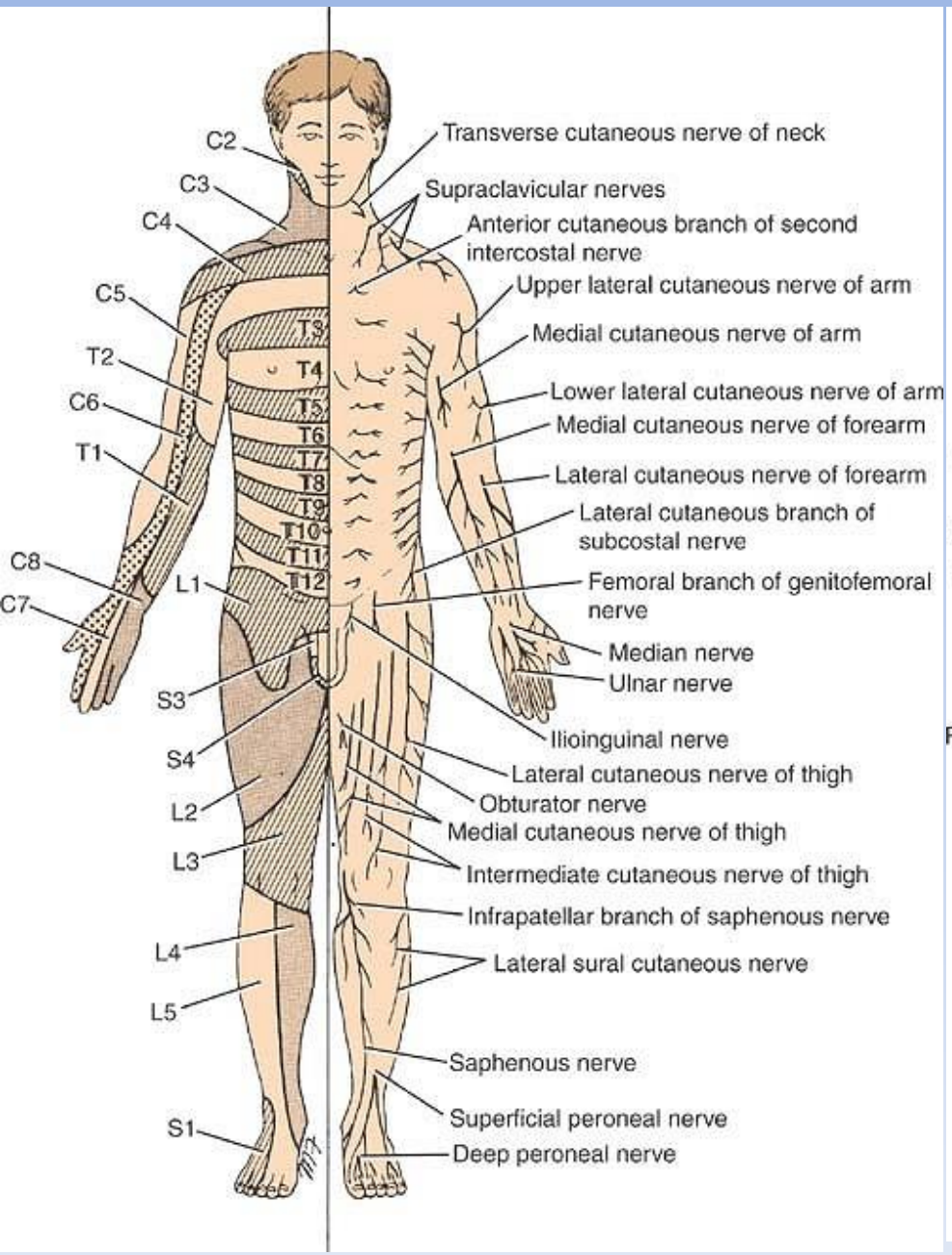
C2
C3
C4
C5
T2
C6
T1
C8
C7
L1
S3
S4
L2
L3
L4
L5
S1
T3
T4
T5
T6
T7
T8
T9
T10
T11
T12
Transverse cutaneous nerve of neck
Supraclavicular nerves
Anterior cutaneous branch of second intercostal nerve
Upper lateral cutaneous nerve of arm
Medial cutaneous nerve of arm
Lower lateral cutaneous nerve of arm
Medial cutaneous nerve of forearm
Lateral cutaneous nerve of forearm
Lateral cutaneous branch of subcostal nerve
Femoral branch of genitofemoral nerve
Median nerve
Ulnar nerve
Ilioinguinal nerve
Lateral cutaneous nerve of thigh
Obturator nerve
Medial cutaneous nerve of thigh
Intermediate cutaneous nerve of thigh
Infrapatellar branch of saphenous nerve
Lateral sural cutaneous nerve
Saphenous nerve
Superficial peroneal nerve
Deep peroneal nerve

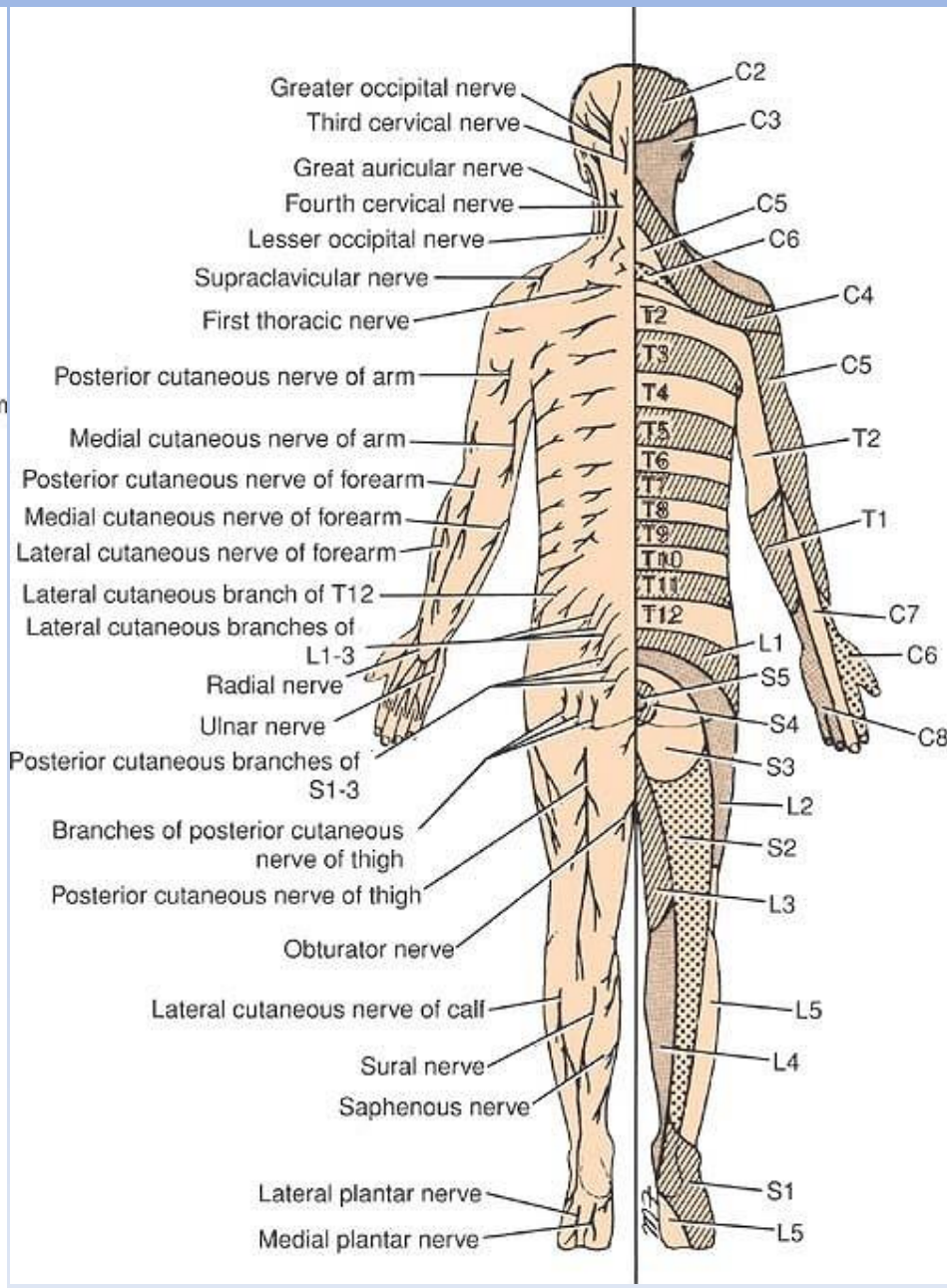
Greater occipital nerve
Third cervical nerve
Great auricular nerve
Fourth cervical nerve
Lesser occipital nerve
Supraclavicular nerve
First thoracic nerve
Posterior cutaneous nerve of arm
Medial cutaneous nerve of arm
Posterior cutaneous nerve of forearm
Medial cutaneous nerve of forearm
Lateral cutaneous nerve of forearm
Lateral cutaneous branch of T12
Lateral cutaneous branches of L1-3
Radial nerve
Ulnar nerve
Posterior cutaneous branches of S1-3
Branches of posterior cutaneous nerve of thigh
Posterior cutaneous nerve of thigh
Obturator nerve
Lateral cutaneous nerve of calf
Sural nerve
Saphenous nerve
Lateral plantar nerve
Medial plantar nerve
C2
C3
C5
C6
C4
C5
T2
T1
C7
C6
C8
T2
T3
T4
T5
T6
T7
T8
T9
T10
T11
T12
L1
S5
S4
S3
L2
S2
L3
L5
L4
S1
L5

Blood Supply of the Spinal Cord

- The spinal cord receives its arterial supply from three small, longitudinally running arteries. The two posterior spinal arteries and one anterior spinal artery.
- The posterior spinal arteries, which arise either directly or indirectly from the vertebral arteries, run down the side of the spinal cord, close to the attachments of the posterior spinal nerve roots.
- The anterior spinal arteries, which arise from the vertebral arteries, unite to form a single artery, which runs down within the anterior median fissure.
- The posterior and the anterior spinal arteries are reinforced by radicular arteries, which enter the vertebral canal through the intervertebral foramina.
- The veins of the spinal cord drain into the internal vertebral venous plexus.

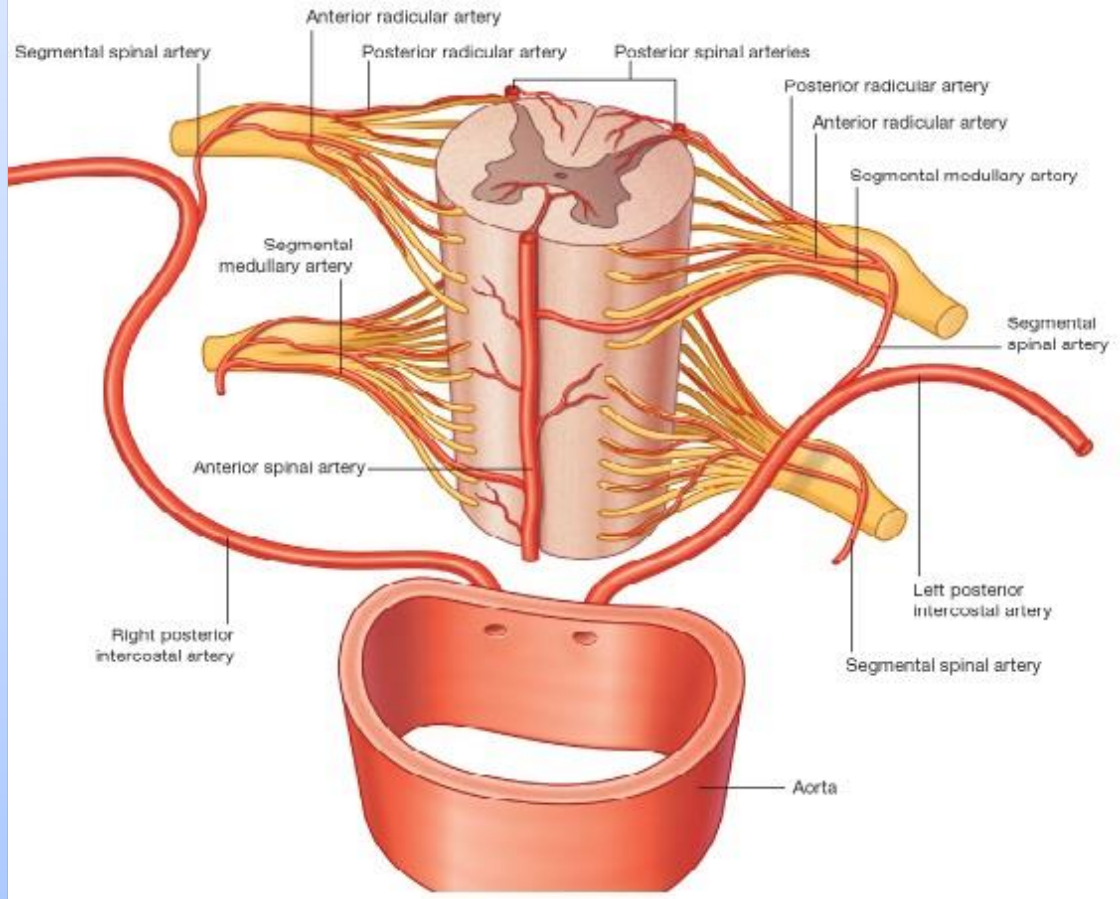

Spinal Nerves

- The 31 pairs of spinal nerves are named and numbered according to the region and level of the spinal cord from which they emerge.
- The first cervical pair emerges between the atlas and the occipital bone.
- All other spinal nerves leave the vertebral column from the intervertebral foramina between the adjoining vertebrae.
- There are 8 pairs of cervical nerves, 12 pairs of thoracic nerves, 5 pairs of lumbar nerves, 5 pairs of sacral nerves, and 1 pair of coccygeal nerves.
- During fetal life, the spinal cord and the vertebral column grow at different rates, the cord growing slowly. Thus, not all the spinal cord segments are in line with their corresponding vertebrae.
- Remember that the spinal cord terminates near the level of the first or second lumbar vertebra.
- Thus, the lower lumbar, sacral, and coccygeal nerves must descend more and more to reach their foramina before emerging from the vertebral column. This arrangement constitutes the cauda equine.

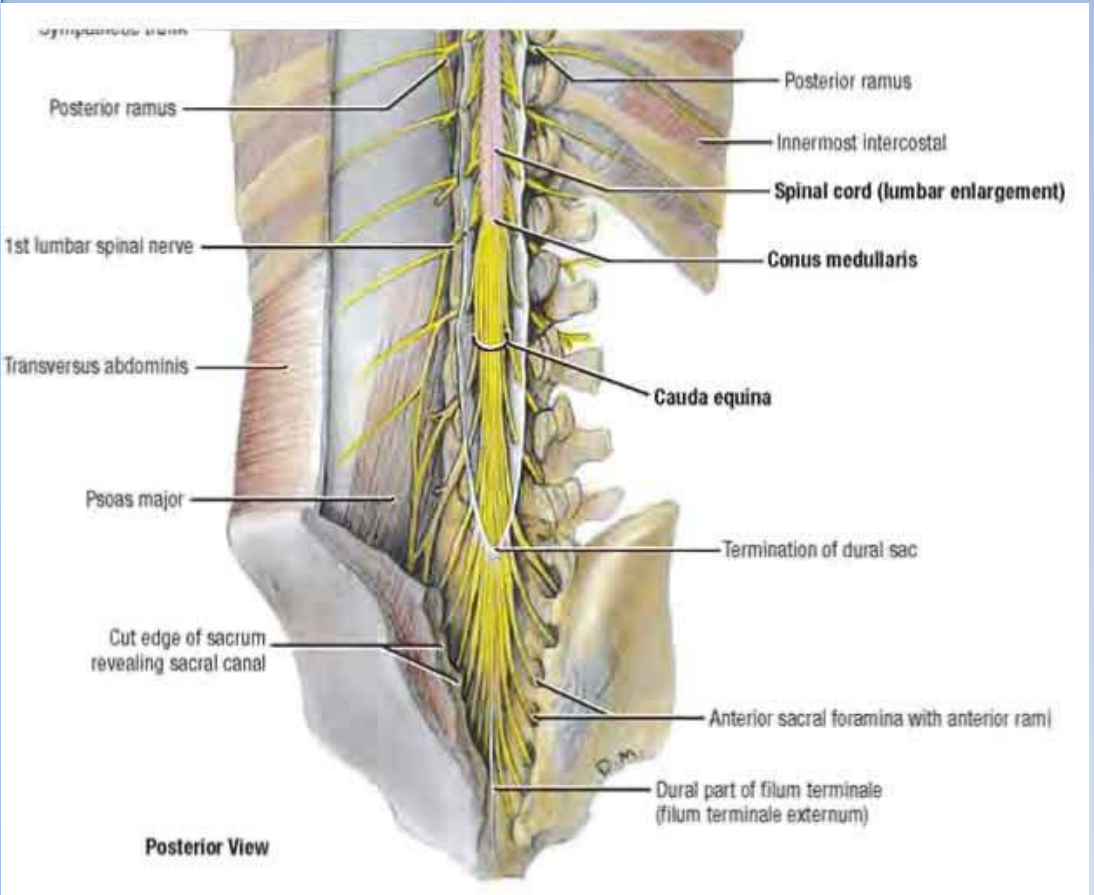

Composition and Coverings

- A spinal nerve has two points of attachment to the cord: a posterior root and an anterior root.
- The posterior and anterior roots unite to form a spinal nerve at the intervertebral foramen.
- Since the posterior root contains sensory fibers and the anterior root contains motor fibers, a spinal nerve is a mixed nerve.
- The posterior (dorsal) root ganglion contains cell bodies of sensory neurons.
- The spinal nerve contains many fibers surrounded by different coverings.
- The individual fibers, whether myelinated or unmyelinated, are wrapped in a connective tissue called endoneurium.
- Groups of fibers with their endoneurium are arranged in bundles called fascicles, and each bundle is wrapped in a connective tissue called the perineurium.
- The outer most covering around the entire nerve is the epineurium.
- The spinal meninges fuse with epineurium as the nerve exits from the vertebral canal.