THORACIC SURGERY

Introduction

Bony landmarks

- **The 1st rib is difficult to palpate as it lies under the clavicle. The 2nd**

rib articulates with the manubrium, just above the sternal angle

The costal margin is formed by lower borders of ribs 7–10, and ends of 11 and 12

Thoracic Surface Anatomy

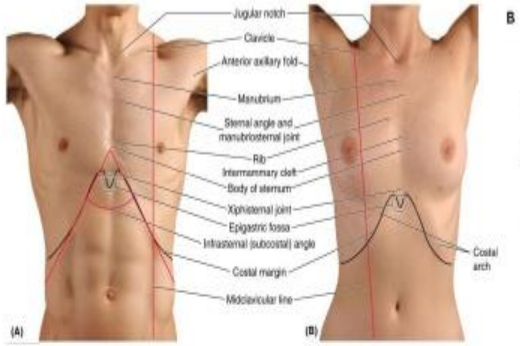

F1.25 Clinically Oriented Anatomy; Moore & Dalley, 6e, 2010, LWW

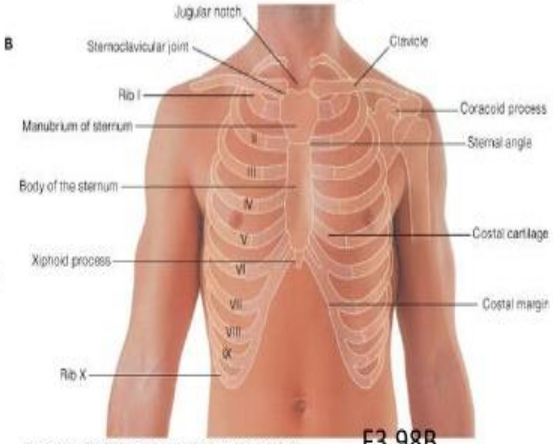

F3.98B

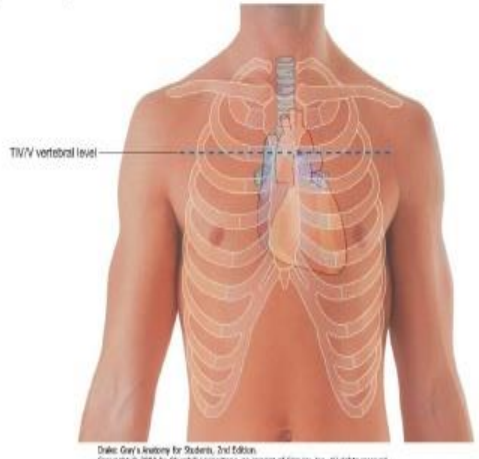

F3.100

Surface markings of thoracic structures

Trachea

This commences at the lower border of the cricoid cartilage (C6), descending in the midline to end slightly to the right, bifurcating at the level of the sternal angle (T4/5) into left and right bronchi.

Lungs and pleurae

The apex of the pleura curves 2.5cm above the medial 1/3 of the clavicle. Lines of pleural reflection pass behind sternoclavicular joints meeting in the midline at the sternal angle. The right pleura passes down behind the 6th costal cartilage whereas the left, displaced by the heart

Heart

The heart is bounded by the 2nd left costal cartilage, the 3rd right costal cartilage, the 6th right costal cartilage, and the 5th left costal cartilage.

Vessels

The internal thoracic arteries descend behind the costal cartilages, 1cm lateral to the sternal edge. The aortic arch arches anteroposteriorly behind the manubrium, the innominate, and left common carotid ascend posterior to the manubrium. The innominate veins are formed by the confluence of the internal jugular and subclavian veins posterior to the sternoclavicular joints. The SVC arises from the left and right innominate veins behind the 2nd and 3rd right costal cartilages.

Diaphragm

The highest part of the right hemidiaphragm reaches the upper border of the 5th rib in the miclavicular line in mid inspiration .The left dome reaches the lower border of the 5th rib .

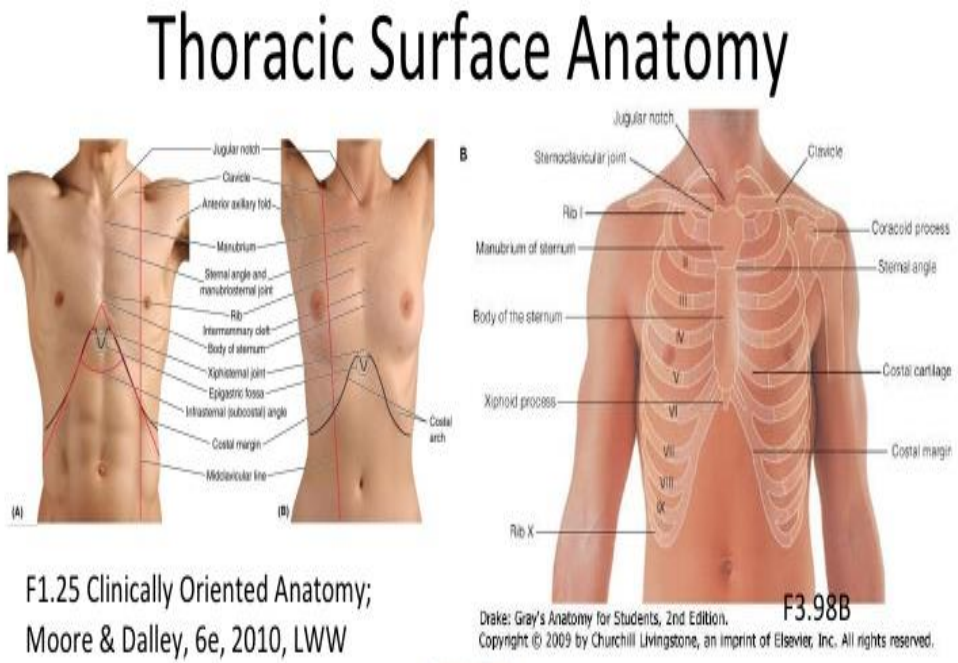

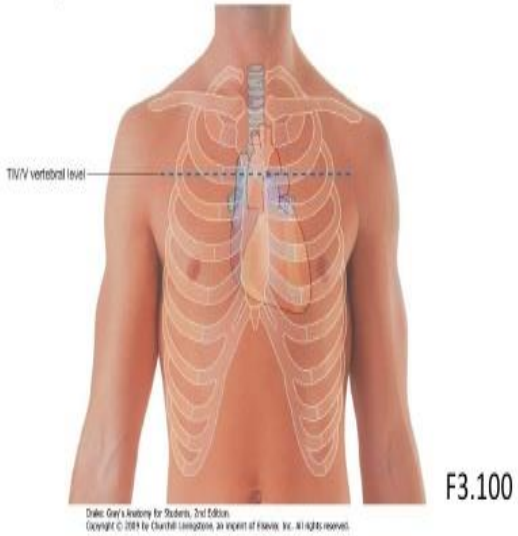

Thoracic bony cage

The thoracic cage

This is formed by the sternum and costal cartilages anteriorly, the vertebral

column posteriorly, and the ribs and intercostal spaces laterally. It is

separated from the abdominal cavity by the diaphragm and communicates

superiorly with the root of the neck via the *thoracic inlet*.

Ribs

There are 12 pairs of ribs:

- 7 pairs of true ribs which articulate with the sternum via costal

cartilages and the vertebrae.

- The false ribs whose cartilage articulates with that of the rib above.

- The false floating ribs 11 and 12.

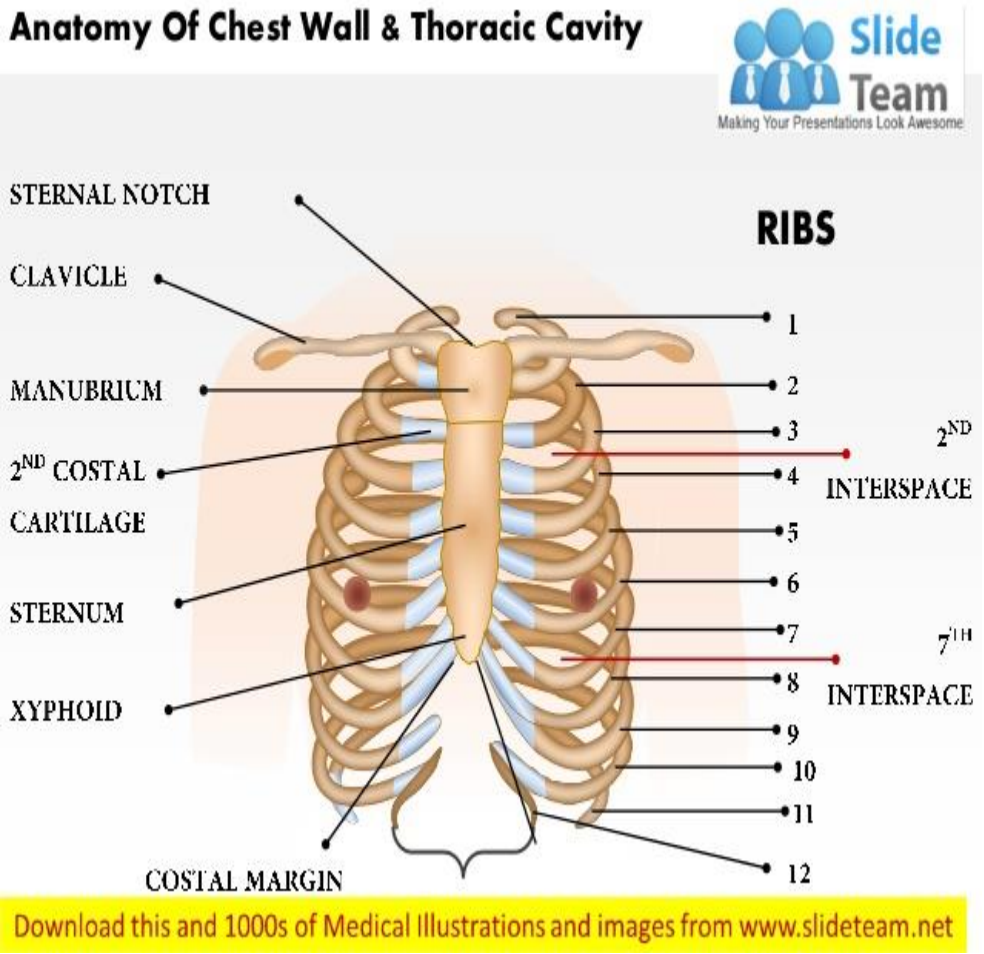

Intercostal nerves and arteries

The intercostal nerves are the anterior primary rami of the thoracic

nerves.. Posterior intercostal arteries are branches of the thoracic aorta, except for the first two which are arise

from the costocervical trunk. The six anterior intercostals are branches of

the internal mammary artery (IMA).

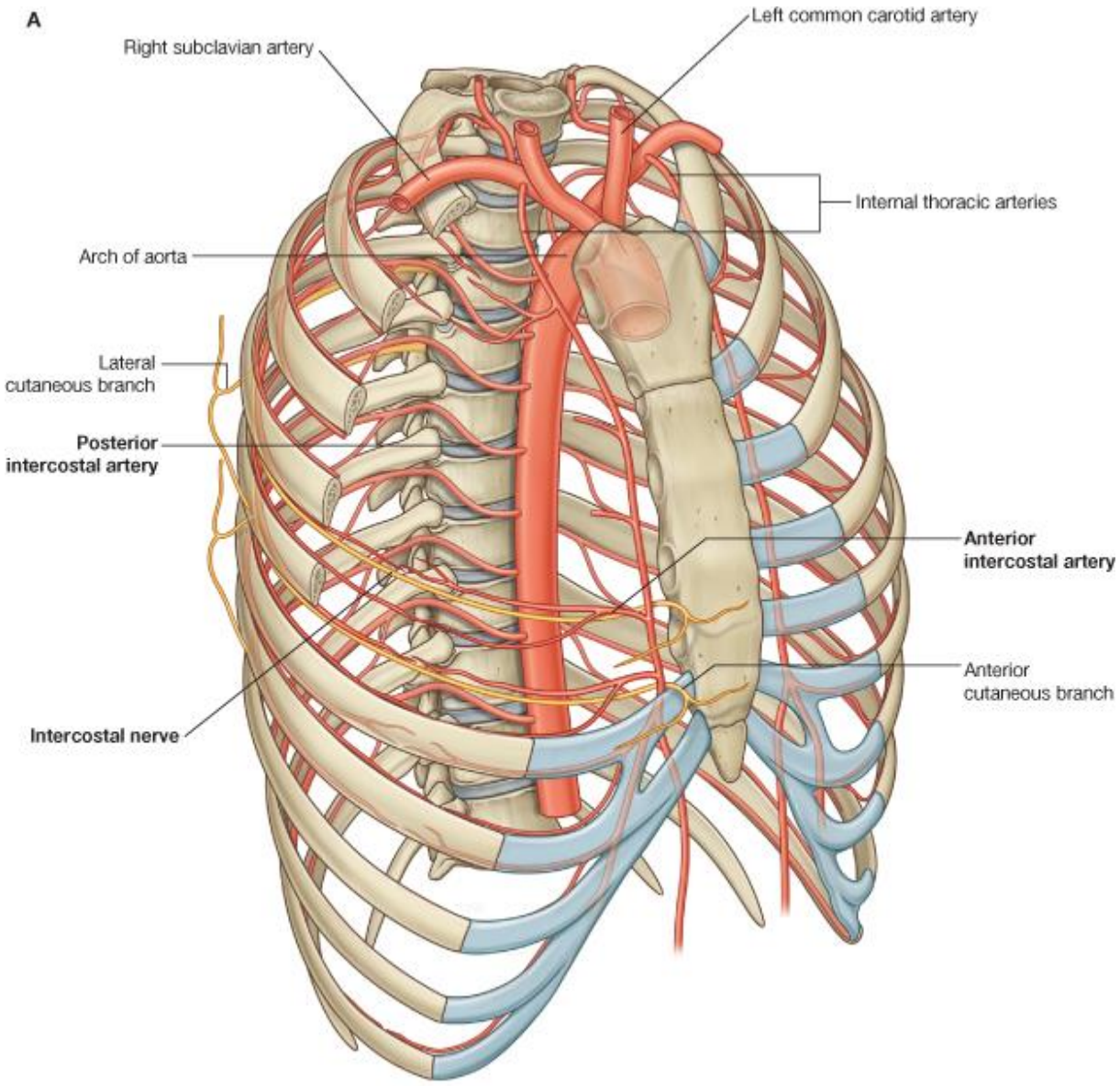

Thoracic incisions

The chest may be entered via anterior, lateral, or posterior approaches.

Anterior incisions

- ***Median sternotomy***
- ***Transverse cervical or collar incision***
- ***Left anterior to sternocleidomastoid incision***
- ***Anterior mediastinotomy:***
- ***Anterior thoracotomy***

Lateral and posterior incisions

- ***Axillary thoracotomy***
- ***Lateral 'muscle-sparing' thoracotomy***
- ***Lateral thoracotomy***
- ***Posterolateral thoracotomy***
- ***Thoracoabdominal incision***

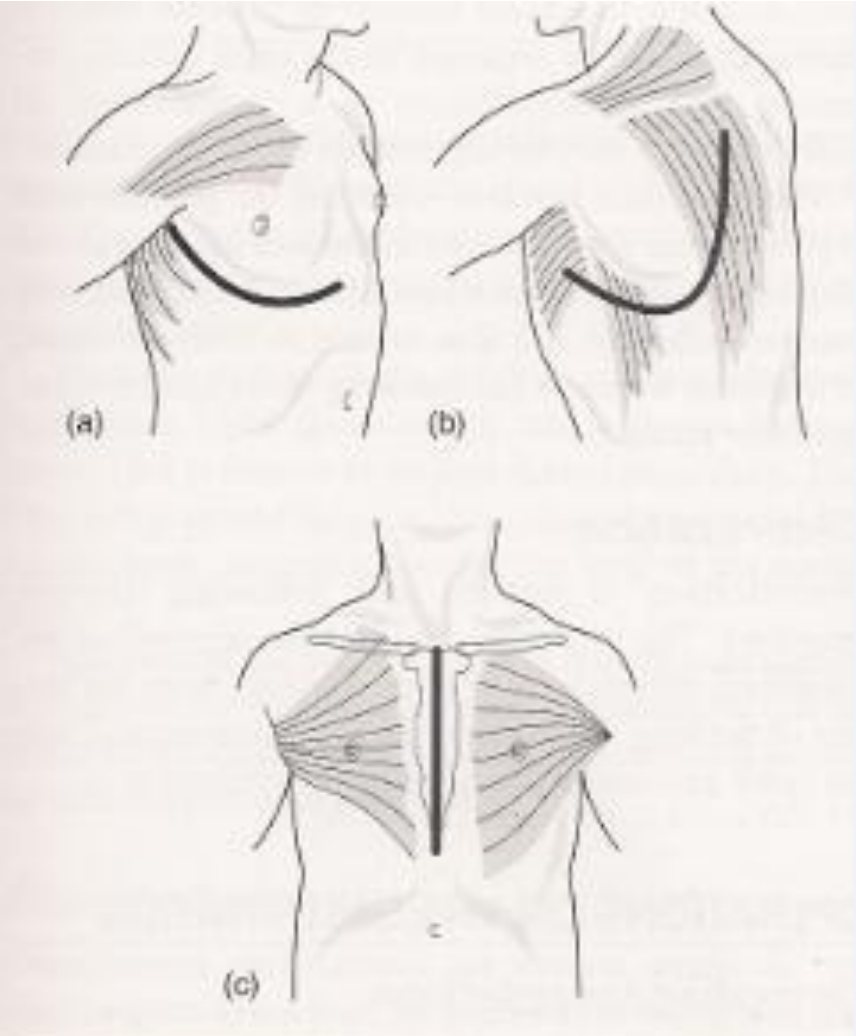

Figure 16.4 Sternotomy. Common incisions. (a) Anterolateral thoracotomy; (b) posterolateral thoracotomy; (c) median sternotomy.

Operative positions

- ***Lateral decubitus position*** **(side up**
- ***Prone*** **(face down)**
- ***Supine*** **(face up)**

Mediastinum

- **The mediastinum is the space between the pleural sacs.**
- **It is divided by a line drawn horizontally from the sternal angle to the lower border of T4, into *superior* (bounded by the thoracic inlet above) and *inferior mediastinum* (bounded by the diaphragm below).**
- **The inferior mediastinum is further divided by the pericardial sac into anterior, middle, and posterior.**

Contents of the mediastinum

- ***Superior mediastinum:* great vessels, trachea, esophagus, phrenic nerve and vagus nerve, thoracic duct.**
- ***Anterior mediastinum:* sternopericardial ligaments, thymus, lymph nodes.**
- ***Middle mediastinum:* pericardial cavity, heart, great vessels, phrenic nerve.**
- ***Posterior mediastinum:* esophagus, descending aorta, azygos veins, thoracic duct, lymph nodes.**

Subdivisions of the mediastinum.

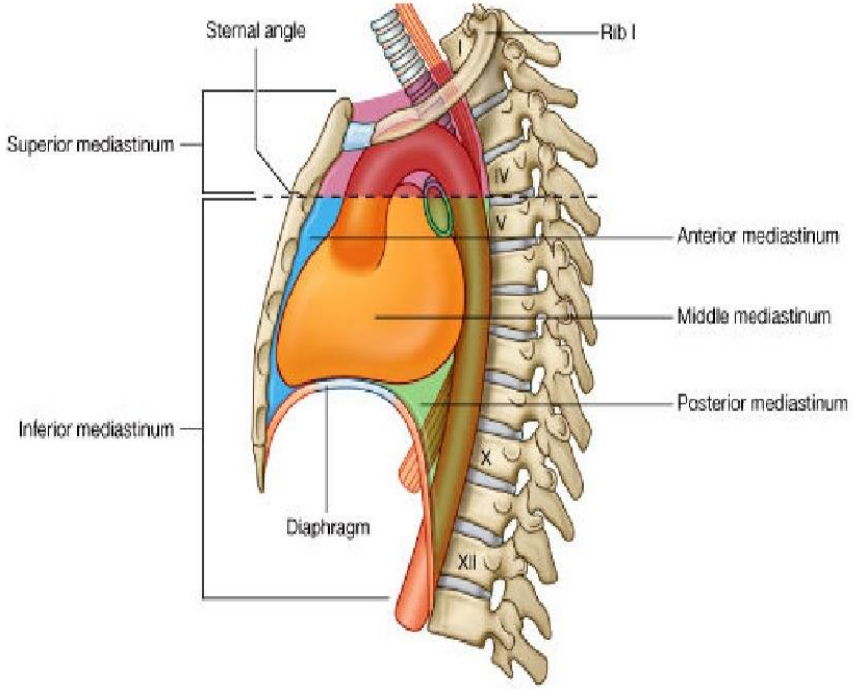

Relationships of the heart

- ***Anteriorly:*** **sternum, costal cartilages of ribs 3–5, anterior lungs.**
- ***Laterally:*** **lungs and hila.**
- ***Posteriorly:*** **esophagus, tracheal bifurcation, main bronchi, descending**

aorta, and vertebrae T5–T8.

- ***Inferiorly:*** **diaphragm and liver.**
- ***Superiorly:*** **great vessels.**

Pericardium

The pericardium has three layers: one fibrous and two internal serous

(parietal and visceral) separated by pericardial fluid. The heart and

Vagus nerve

The vagus nerve contains visceral afferent fibres from the heart, lower respiratory tract and gut, and efferent pre-ganglionic parasympathetic motor fibres to the pharynx, larynx, heart, and smooth muscles of the bronchi and gut.

On the right side the recurrent laryngeal branch arises as the vagus crosses the subclavian artery. The vagus descends through the superior mediastinum passing behind the hilum of the right lung to the pulmonary plexus and then the esophageal plexus. The left vagus crosses the arch of the aorta giving off the recurrent laryngeal nerve

Phrenic nerve

The phrenic nerve contains visceral afferents from the heart and diaphragm, as well as motor efferents from the dorsal rami of C3–5.

Thoracic sympathetic plexus

This lies lateral to the posterior mediastinum behind the parietal pleurae

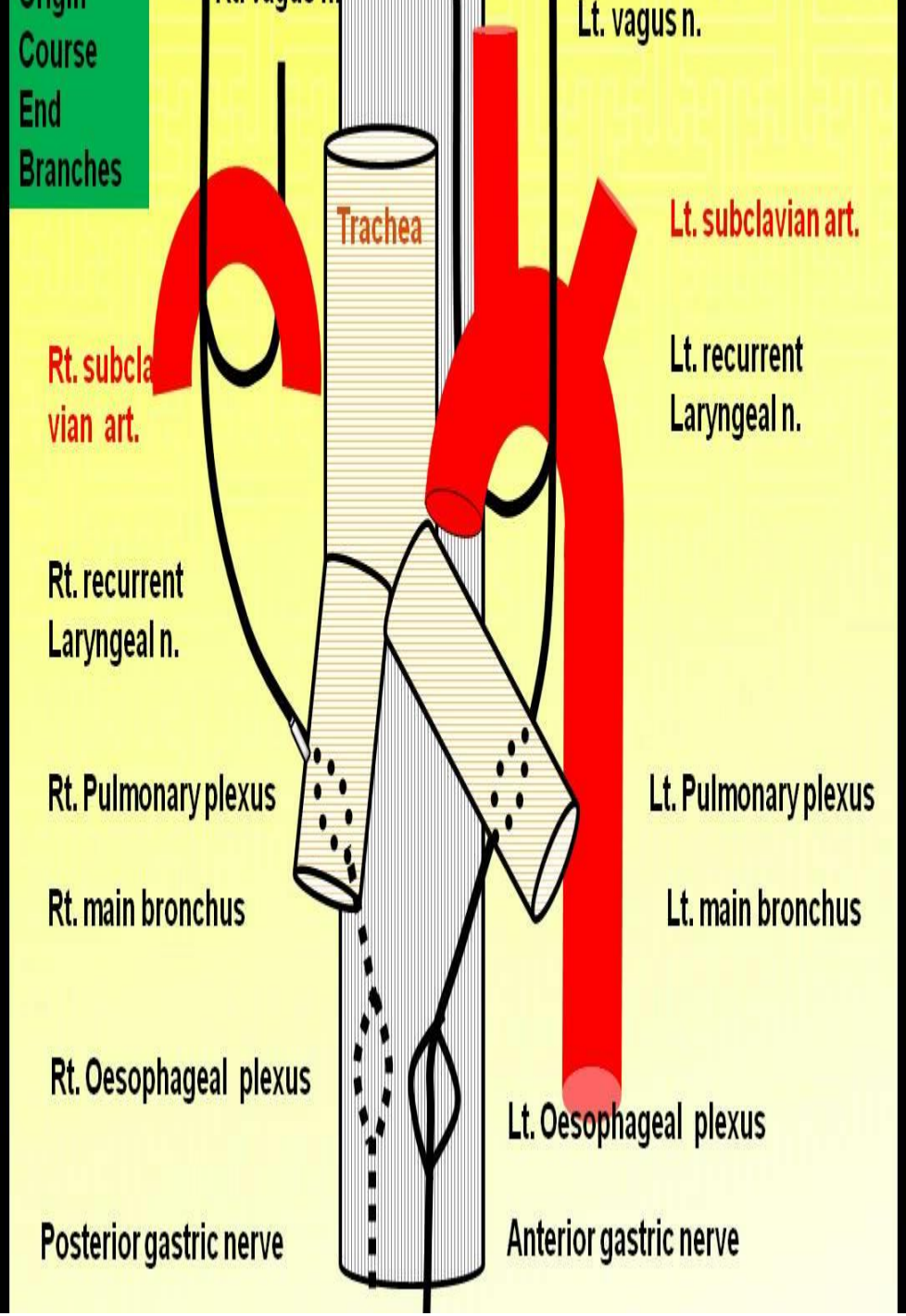

Lung anatomy

Lobes

- **The right lung has three lobes: an upper, a middle, and a lower lobe.**

- **The smaller left lung has two lobes: an upper, and a lower lobe.**

The lingular segment of the left upper lobe corresponds to the right middle

lobe.

Fissures

- **The right lung has two fissures: an oblique and a transverse fissure.**

- **The left lung has one fissure: the oblique fissur.**

The oblique fissure separates the upper lobe (and middle lobe on the

right) from the lower lobe on each side. The transverse fissure separates

the upper lobe from the middle lobe on the right. It is often incomplete.

Bronchopulmonary segments

- **A bronchopulmonary segment is a portion of lung which functions as**

an individual unit, having its own artery and bronchus. There are 18.

- **The right lung is divided into 10 bronchopulmonary segments**

- **The left lung is divided into 8 bronchopulmonary segments**

Tracheobronchial anatomy

The trachea commences at the lower border of the cricoid cartilage (C6)

and terminates at the carina dividing into right and left main bronchi.

- **Right main bronchus is 1.2cm long.**

- **The left main bronchus is 4–6cm long.**

Tracheal anatomy

- **The average adult male trachea is 10–13cm in length, measured from the lower edge of the cricoid ring to the carina.**
- **1/3 of the adult trachea is above the sternal notch, with the balance an intrathoracic structure.**
- **In the absence of congenital tracheal stenosis, the only complete tracheal ring is the cricoid cartilage; all other rings are incomplete ring of cartilage with a posterior membranous wall.**
- **There are 18–22 D-shaped partial rings. The cartilaginous rings are softer in the pediatric population, and can become calcifi ed with age.**
- **The arterial supply of the trachea is segmental, or entering via lateral pedicles. Dissection of the trachea should be limited to anterior and posterior planes. In the absence of tracheal resection, circumferential dissection should be limited to 1–2cm to avoid ischemic necrosis.**

Upper half of trachea

- **Tracheoesophageal branches of the inferior thyroid artery.**

Middle to lower trachea and carina

- **Branches from the supreme intercostal artery, subclavian artery, right internal mammary artery, innominate artery.**
- **Branches from the bronchial arteries.**

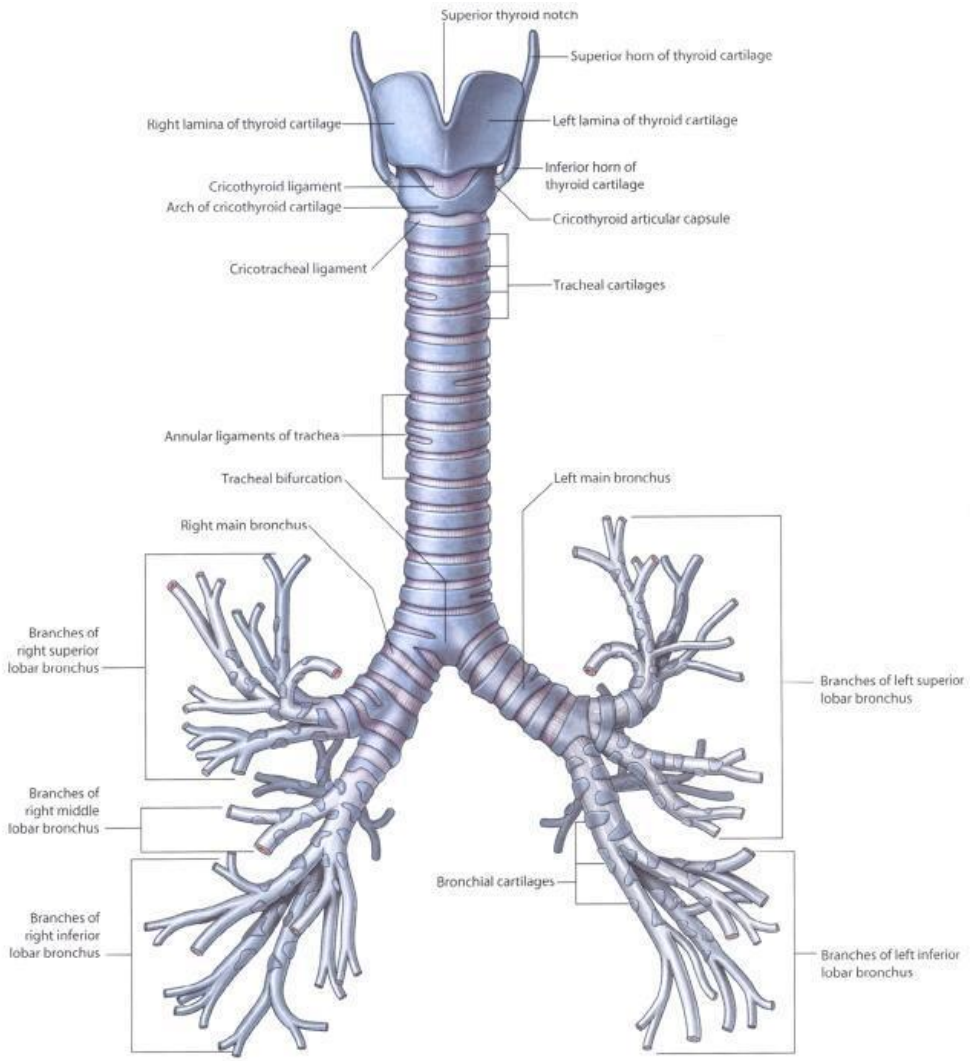

Pulmonary vessels

Pulmonary trunk

- This arises intrapericardially from the infundibulum of the RV

Right pulmonary artery

- Passes posterior to aorta and SVC.

Left pulmonary artery

Pulmonary veins

- There are two pulmonary veins on each side, a superior and an inferior.

The veins drain into the LA.

Bronchial arterial system

- This arises from systemic circulation, from various arterial origins. Drainage is into the pulmonary venous system, azygos, and hemiazygos veins.

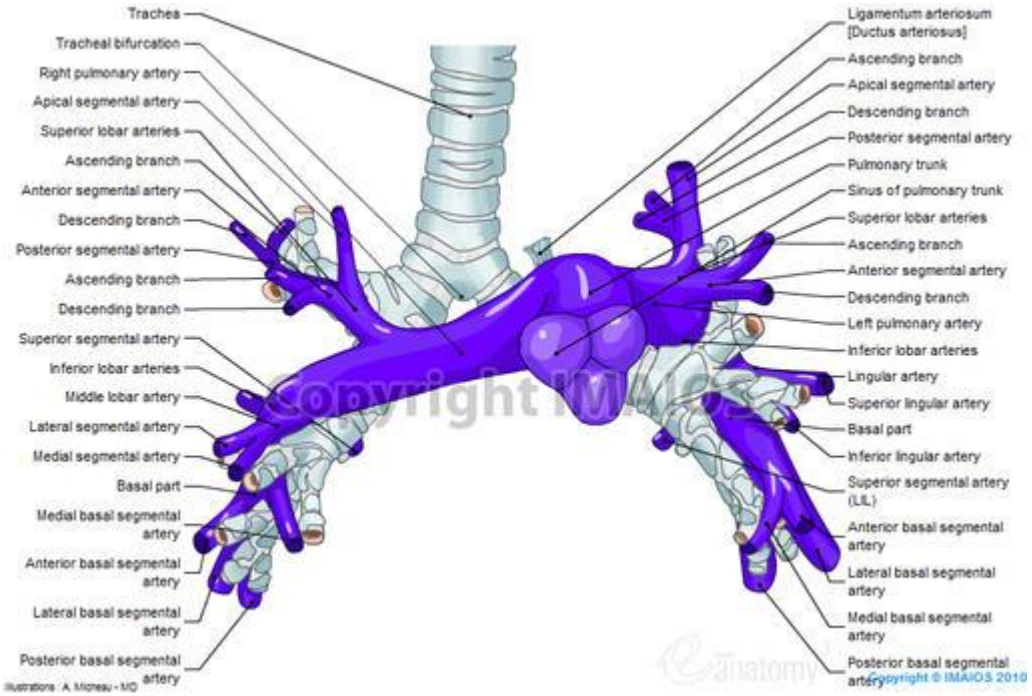

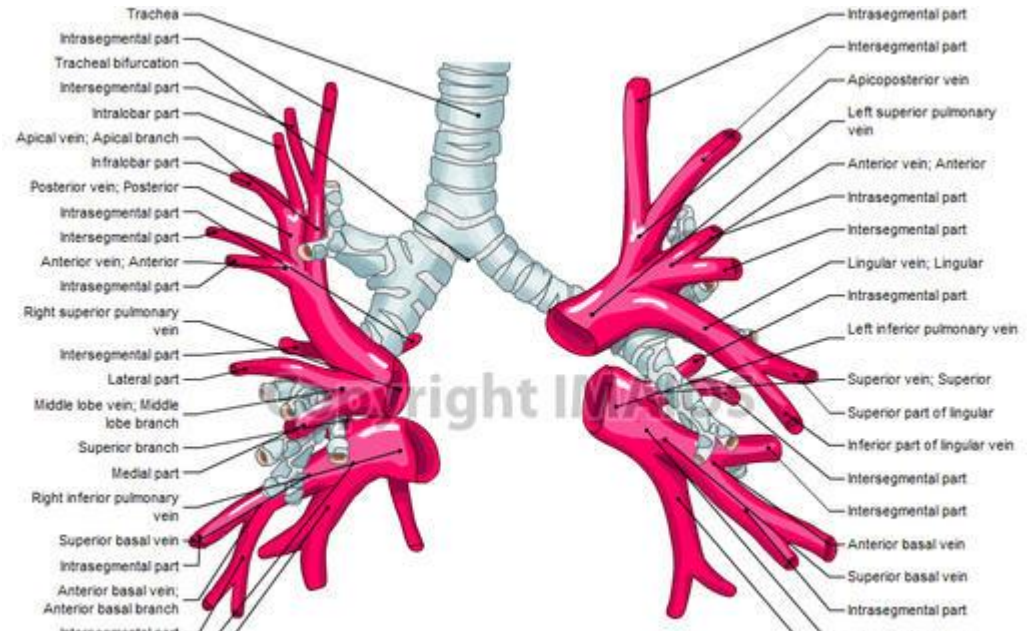

Thoracic vessels

Ascending aorta

The ascending aorta lies in the middle mediastinum, beginning at the base of the LV.

Arch of aorta

The whole of the aortic arch lies in the superior mediastinum. The aortic arch begins behind the right half of the manubrium, at the 2nd right costal cartilage.

Branches

Brachiocephalic artery, left common carotid artery, left subclavian artery

Descending thoracic aorta

The descending aorta lies in the posterior mediastinum. It begins at the level of the 4th thoracic vertebra, ending at the 12th thoracic vertebral border, where it passes through the diaphragm to become the abdominal aorta. It goes from being to the left of the vertebral column superiorly, to being directly anterior to it at the level of the diaphragm.

Branches

Pericardial branches, right and left bronchial arteries, which run posteriorly on the bronchi, four or fi ve esophageal arteries, mediastinal and phrenic branches, nine paired posterior intercostal arteries (see also b p36), paired subcostal arteries.

Inferior vena cava

Conveys blood to the RA from all structures below diaphragm.

Superior vena cava

Returns blood from upper half of the body. Formed by junction of the brachiocephalic veins, and receives azygos vein before entering the pericardium. It is valveless.

Azygos vein

Anesthetic considerations

- Specific anesthetic considerations in thoracic surgery include the need for accurate assessment of the airway, need for lung isolation and bronchoscopy prior to procedure, increased use of epidural anesthesia, and greater need for invasive monitoring, particularly arterial blood gases and pressures, with location depending on procedure.
- Bronchoscopy is routinely performed after intubation, and may impact on conduct of anesthesia in several ways.
- Tracheal reconstruction has several unique anesthesia issues.

Anesthetic considerations for key procedures

Flexible bronchoscopy

- Most flexible bronchoscopy can be performed with topical analgesia with 2–4% lidocaine sprayed onto the vocal cords.
- Conscious sedation can be used with benzodiazepines and narcotics.
- Most common complication of flexible bronchoscopy is *hypoxia* from excessive suction aspiration; therefore 100% oxygen should be used.

Rigid bronchoscopy

- General anesthesia required: hypoxia and hypercapnia may complicate procedure.
- Most rigid scopes have a sidearm to allow positive pressure ventilation.
- While anesthesiologists are accustomed to this mode of ventilation, it has to be suspended while the surgeon is working.

Single-lung ventilation

- **Many thoracic surgical procedures require the surgical lung to be nonventilated,**

with selective ventilation of the non-operative lung, with a

double lumen endotracheal tube (DLT).

- **A *bronchial blocker* is an alternative for lung isolation when placement**

of a DLT would be too diffi cult, in a patient that is already intubated

with a single lumen ET tube or a tracheostomy.

Double lumen endotracheal tubes

- **Double lumen tubes are fitted to either the right main stem bronchus**

(right-sided DLT) or the left main stem bronchus (left-sided DLT).

Bronchial blocker

- **Involves placement of a Fogarty type balloon through a single lumen**

ET tube to selectively occlude an airway.

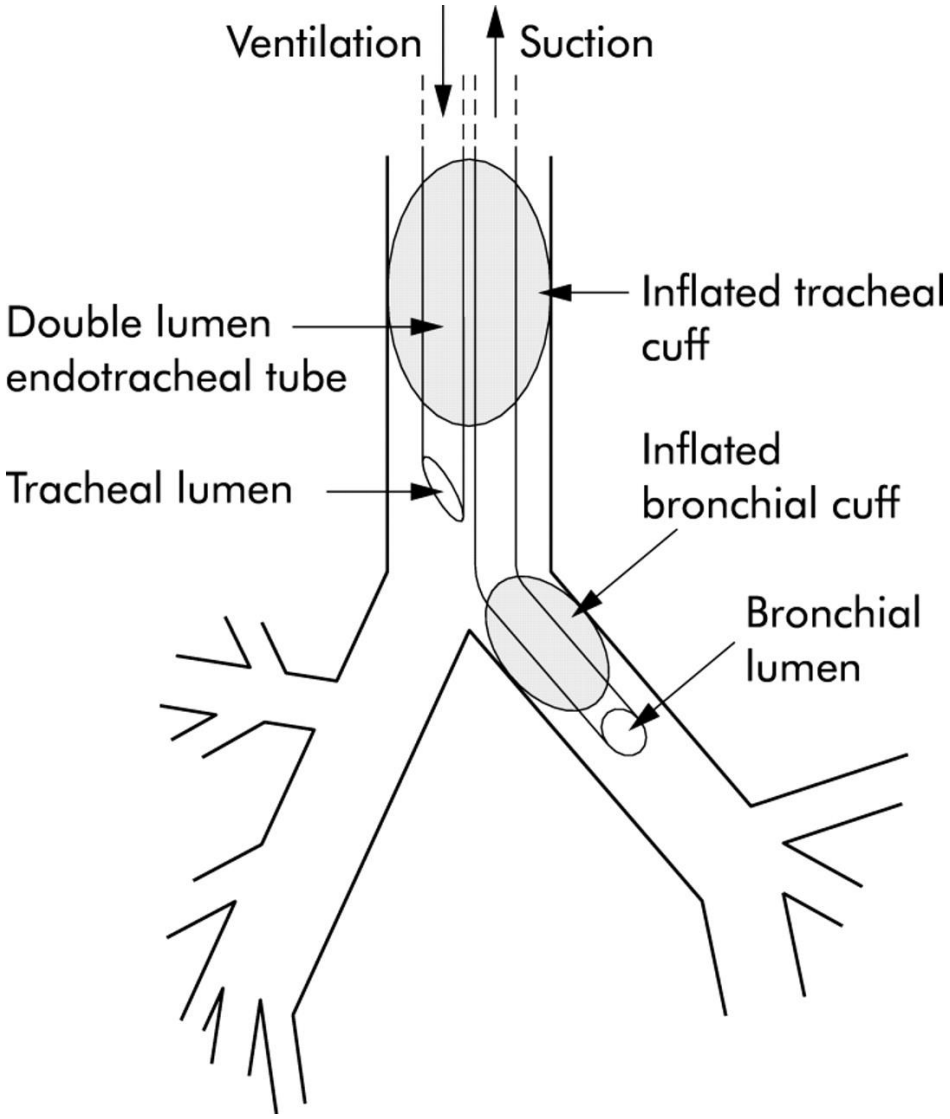

Major predictors of postoperative complications

- **Extent of resection, increased age, pre-existing cardiovascular disease,**

emergency procedure, immunocompromised patient, current or

recent smoker, multiple comorbidities.

- **Vital capacity decreases by 25% following a thoracotomy without lung**

Assessment of cardiovascular risk

- **In patients at risk for coronary artery disease (CAD), a small subpopulation of patients with heart failure, exercise-induced arrhythmia, or myocardial ischemia may be identified by non-invasive testing.**
- **In patients with no cardiac history, risk of perioperative MI is 0.07–0.13%.**
- **In patients with prior history of MI, risk of a perioperative MI is 2.8–17%.**

Initial history and examination

- **Includes physical exam, baseline EKG, determine cardiac risk factors by identifying history of CAD, valvular disease, heart failure, arrhythmia.**
- **Minor risk factors:**
- **Diminished activities of daily living such as inability to climb a fl ight of stairs.**
- **Age.**
- **Abnormal EKG.**
- **AF or other abnormal rhythms that are controlled.**
- **Hypertension.**
- **History of stroke.**

- *Intermediate risk factors*:
  - **Canadian class I or II angina.**
  - **Compensated CHF.**
  - **Chronic renal insufficiency.**
  - **Diabetes mellitus.**
  - **Prior MI.**
- *Major risk factors:*
  - **MI within 30 days.**
  - **Unstable or Canadian class III or IV angina.**
  - **Decompensated CHF.**
  - **Significant arrhythmias, including AF with rapid ventricular response, AV block.**
  - **Severe valvular disease.**

SPIROMETRY

- MEASURES EXPIRATORY AIRFL OW VOLUME OVER TIME.
- 'NORMAL' REFERENCE VALUES ARE BASED ON AGE, GENDER, AND HEIGHT.

Pulmonary function tests (marked variation with age, height, and sex)

FVC = Forced vital capacit

FEV1 = Forced

expiratory volume

in 1 second >2.0L

FEV1 / FVC 70–80%

PEFR = Peak expiratory

fl ow rate 450–600l/min

DLCO = Diffusing lung cap

Table 13.1 Pulmonary disorders

Obstructive disorders	Restrictive disorders
Asthma	Sarcoidosis
Chronic bronchitis	Congestive heart failure
Emphysema	Pulmonary fibrosis
Cystic fibrosis	Fibrosing alveolitis
Bronchiolitis obliterans	Thoracic deformities
Eosinophilic granulosa	Interstitial pneumonitis
Lymphangiomyomatosis	

Gas exchange

- **Gas exchange tests measure alveolar oxygen exchange.**

Cardiopulmonary exercise testing (CPET)

- **CPET records the exercise EKG, heart rate response, minute ventilation, and maximal oxygen consumption (VO2max).**

FLEXIBLE BRONCHOSCOPY

- Flexible bronchoscopy is the evaluation of the bronchial airways, for diagnostic or therapeutic purposes, using a flexible bronchoscope equipped with fi beroptic bundles, or with new-generation scopes, a charge coupled device at the end of the scope for improved optics.
- Flexible bronchoscopy can be readily accomplished with topical analgesia (awake patient) and therefore allows assessment of vocal cords and laryngeal function, and tracheomalacia , in addition to tracheobronchial toilet and biopsy.
- The most common complication of bronchoscopy is hypoxia from excessive suction aspiration.

DIAGNOSTIC APPLICATIONS

- ***Brushing*:**
- ***Bronchoalveolar lavage*:**
- ***Endobronchial biopsy*:**
- ***Transbronchial biopsy*:**

Therapeutic applications

Aspiration of secretions, laser treatment, photodynamic therapy (PDT), argon plasma coagulation (APC), cryotherapy, stent placement, foreign body retrieval, and Wang needle transbronchial needle aspiration (TBNA).

Complications

- **The most common complication during fl exible bronchoscopy is hypoxia from suction aspiration.**
- **Other complications are rare, and include bleeding, pneumothorax, and respiratory failure (70.1–0.2% each)**
- **The incidence of pneumothorax is 74% in transbronchial biopsy.**
- **Self-limiting fever is not uncommon after BAL.**

RIGID BRONCHOSCOPY

- Rigid bronchoscopy involves a stainless steel tube equipped with a removable lens that can allow for direct visualization, or insertion of a
- Rigid bronchoscopy is best performed with general anesthesia.
- The rigid bronchoscope is useful for diagnostic and therapeutic interventions. As a flexible bronchoscope can be inserted down a rigid bronchoscope, all the therapeutic and diagnostic manoeuvres of a flexible bronchoscope can be performed through a rigid bronchoscope.
- Endobronchial ultrasound transbronchial needle aspiration (EBUS-TBNA) is an adjunct to mediastinoscopy, although cervical mediastinoscopy is the gold standard for evaluation of nodal tissue and other pathology of the superior and middle mediastinum.

Complications

- Injury to oropharyngeal structures.
- Hypoxia.
- Hypercapnia.
- Airway injury.
- Pneumothorax.
- Bleeding.

Endobronchial ultrasound

- **EBUS-TBNA offers a minimally invasive approach to biopsying mediastinal nodal tissue and other pathology adjacent to the airways.**

MEDIASTINOSCOPY

- Mediastinoscopy is the gold standard for staging mediastinal paratracheal lymph nodes in the setting of lung cancer.
- It is also key in evaluating other pathology of the middle mediastinum.
- Mediastinotomy or Chamberlain procedure is useful for biopsying large anterior mediastinal masses.
- Aortic-pulmonary (AP) artery window lymph nodes can be evaluated by mediastinotomy or now more commonly by left VATS.

Indications

- Pre-lung resection staging for primary lung cancer.
- Biopsy of mediastinal masses and lymph nodes for histological tissue diagnosis (e.g., sarcoid, lymphoma, mediastinal tumours, tuberculosis).

MEDIANSTINOTOMY

- **Also known as the *Chamberlain procedure*, left anterior mediastinotomy was first described in 1966.**
- **This procedure may be performed in conjunction with a cervical mediastinoscopy allowing digital palpation and assessment of the AP lymph nodes. Also very useful for the incisional biopsy of large anterior mediastinal masses.**

Complications of mediastinoscopy and mediastinotomy

Complications can be catastrophic.

- **Tracheal injury, hemorrhage, wound infection, pneumothorax, recurrent laryngeal nerve injury (most common on left), esophageal injury (very rare).**
- **Azygos vein injury:**
- **Innominate artery, pulmonary artery, aortic or SVC injury:**
- **Esophageal injury.**

INVESTIGATION FOR THORACIC SURGERY

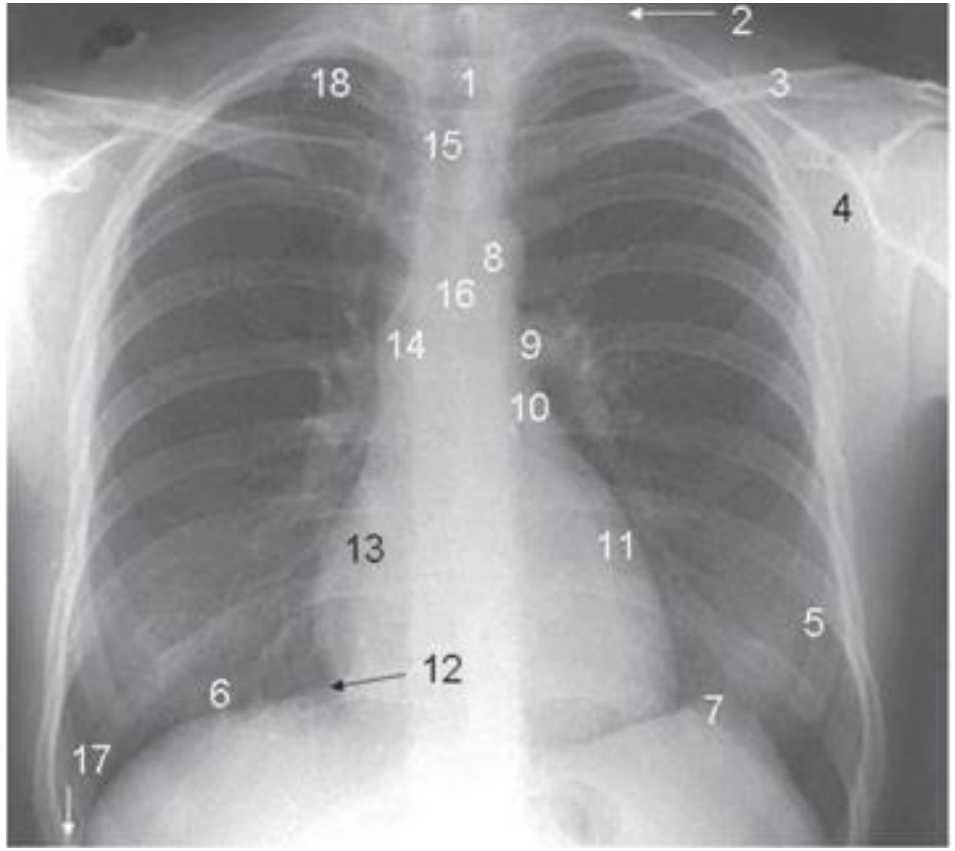

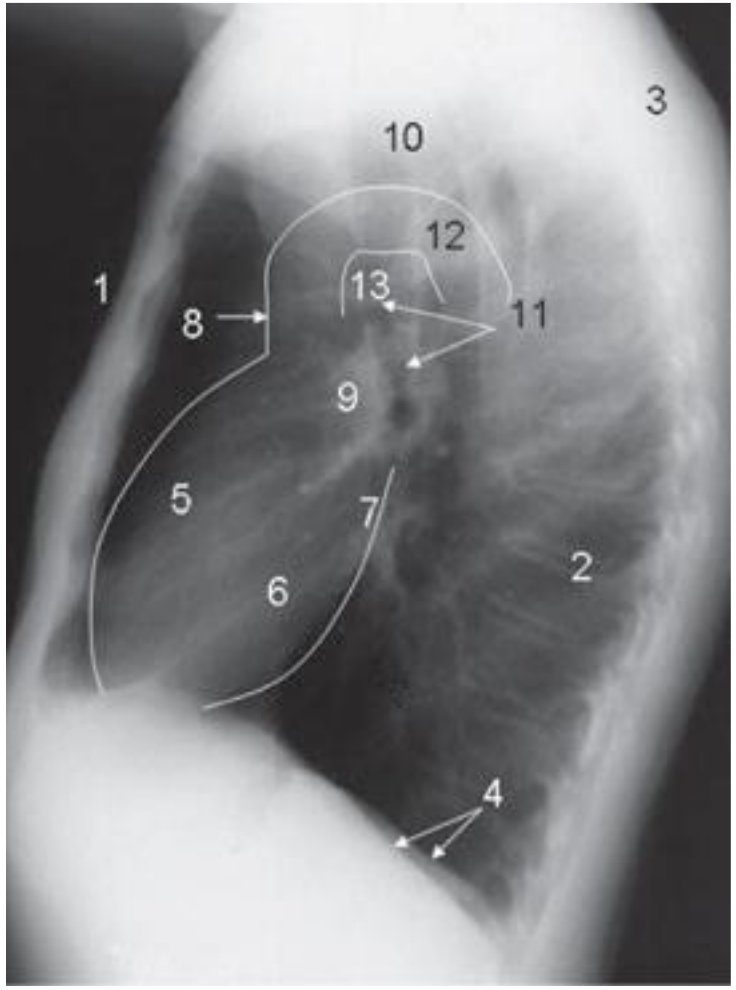

MEDIASTINOSCOPE

A **mediastinoscope** is a thin, tube-like instrument used to examine the tissues and lymph nodes in the area between the lungs (mediastinum) in a procedure known as mediastinoscopy. These tissues include the heart and its large blood vessels, trachea, esophagus, and bronchi. The mediastinoscope has a light and a lens for viewing and may also have a tool to remove tissue. It is inserted into the chest through a cut above the sternum.

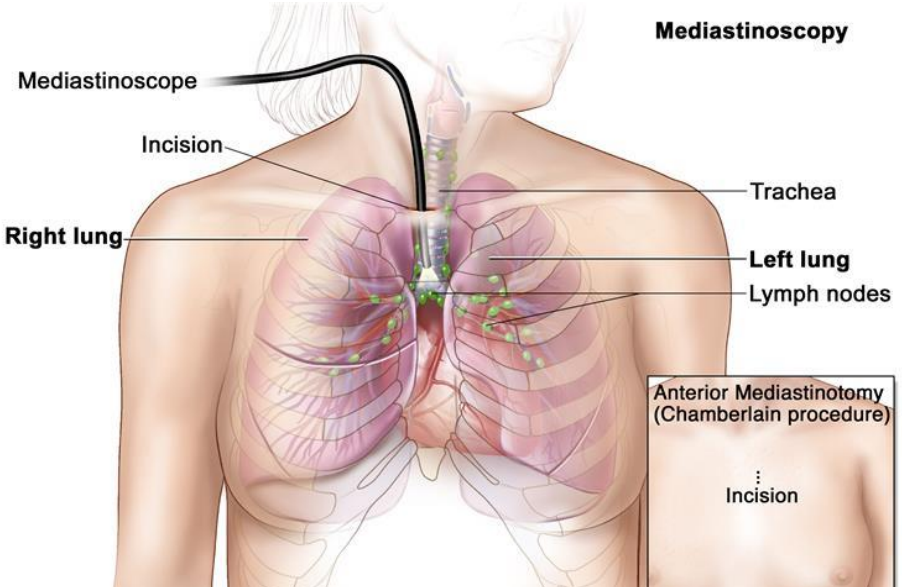

THORACOSCOPY
VIDEO-ASSISTED THORACOSCOPIC SURGERY

Thoracoscopy is a medical procedure involving internal examination, biopsy, and/or resection of disease or masses within the pleural cavity and thoracic cavity.[1] Thoracoscopy may be performed either under general anaesthesia or undersedation with local anaesthetic.

Video-assisted thoracoscopic surgery (VATS) is a surgical operation involving thoracoscopy, usually performed by a thoracic surgeon using general or local/regional anaesthesia with additional sedation as necessary. It has historically also been referred to as pleuroscopy. A wide variety of diagnostic and therapeutic procedures may be performed with this technique which has become very popular and increasingly so since the early 1990s. Prior to this, limited diagnostic procedures were done using variations on the cystoscope since 1910.

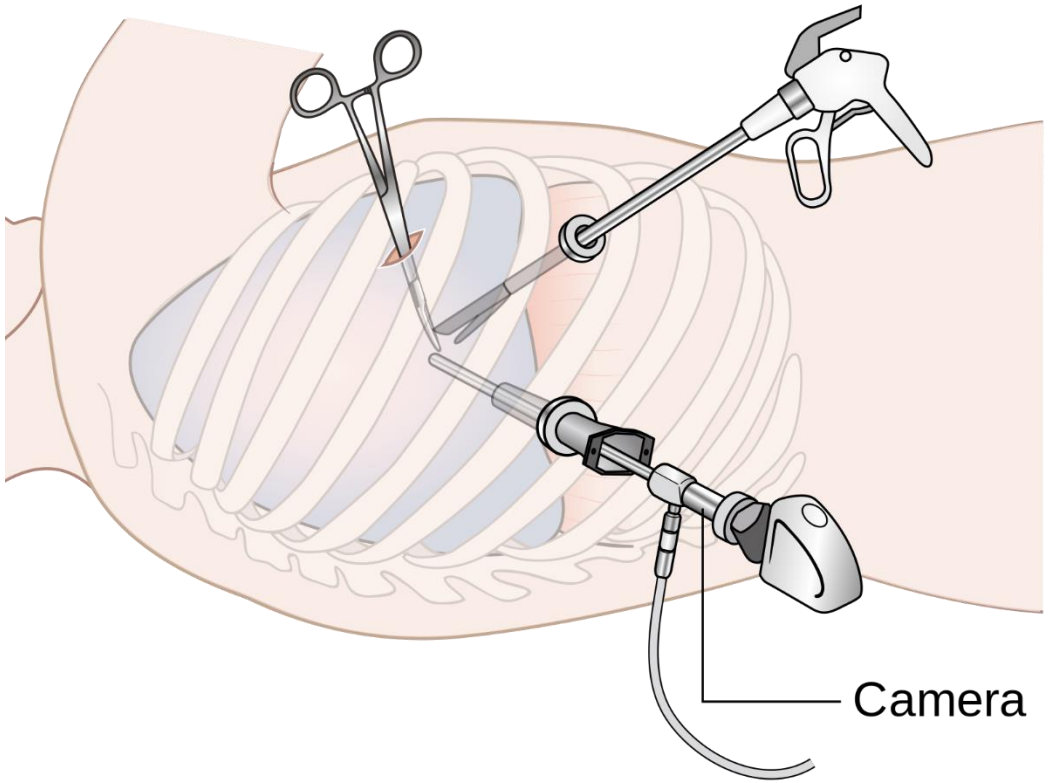
Camera

EMPYEMA

- Defined as *pus in the pleural space*: often from the lung parenchyma or translocated through the chest wall, mediastinum, or abdomen.
- An empyema may grow organisms or it may be sterile (1/3 of cases), depending how long the patient has been on antibiotics.
- The aim of treatment is to drain and sterilize the space, and re-expand the lung which can done using VATS with limited decortication in early stage empyemas, but in recurrent empyema bronchopleural fistula may require a chest wall window for chronic debridement.

PATHOLOGY

- A *parapneumonic pleural effusion* is common. The majority resolve with antibiotic therapy. *Postpneumonic empyema* forms when bacteria infect the pleural fluid or pleural space. It is the commonest cause of an empyema.
- *Postsurgical empyema* accounts for 20% of cases of empyema and can follow surgery to the mediastinum, esophagus, and lungs, most commonly following pneumonectomy. It can also follow surgery or injury to the abdomen. Presentation is usually in the early postoperative period, but it may develop several years after surgery.
- Empyema may also follow rupture of a lung abscess or infected pleural bleb, inhaled foreign bodies or bronchopleural fistula.
- Empyema may also result form thoracic trauma, ruptured esophagus, pericarditis, abdominal processes such as cholangitis and diverticulitis with translocation of bacteria across the diaphragm, mediastinitis, chest wall or spine osteomyelitis, rupture of lung abscess or infected pleural bleb, and inhaled foreign body.

Stage I: acute exudative phase

- Typically occurs 2–5 days after a pneumonia.
- Accumulation of fluid with low cellular content and viscosity.
- Characterized by low WBC, LDH, glucose, and a normal pH.
- Can be successfully treated with antibiotics only.

Stage II: fibrinopurulent phase

- Typically occurs 5–14 days after a pneumonia.
- Turbid or purulent fluid with heavy fibrin deposits.
- Appearance of simple loculations and septations.
- May have bacterial invasions, and high numbers of polymorphonuclear leukocytes (PMNs) and lymphocytes.
- Characterized by low pH, glucose, and increased LDH.
- Antibiotics and chest tube drainage is required, 9 VATS decortication.

Stage III: chronic organizing phase

- Lung trapping by collagen, visceral and parietal pleural peel with ingrowth of fi broblast and capillaries.
- Antibiotics and aggressive decortications, generally by thoracotomy.
- Bacteriology.
- Includes staphylococcus, *Haemophilus infl uenza*, Gram –ve bacilli, *Streptococcus pneumonia*, *Streptococcus pyogens*, *Mycoplasma*.
- Empyema that has been present for >2 weeks has a higher risk of conversion from VATS to open for decortication.

Presentation

Patients may complain of fever, productive cough, dyspnea, chest wall pain, malaise, fatigue. Physical examination may reveal decreased ipsilateral chest wall expansion, egophony, dullness to percussion, chest wall tenderness. Complications include *empyema necessitans* (discharge of empyema through the chest wall), pulmonary fibrosis, chest wall contractures, osteomyelitis, pericarditis, subphrenic, or mediastinal abscesses.

Investigation

- CXR, PA and lateral, and/or decubitus films to determine loculation .
- Chest CT: provides anatomy, and helps planning for chest tube placement of surgery, as well as showing thickened pleural peel, and presence of calcifications in the peel which help determine if thoracotomy rather than VATS necessary.
- Thoracentesis: Gram's stain and culture, *Light's criteria* distinguishes transudative effusion from exudative:
- Exudative if specific gravity is >1.02, protein content >2.0 g/dL, and at least one of the following: ratio of pleural fluid protein to serum >0.5, ratio of pleural fluid LDH and serum >0.6, total pleural fluid LDH >2/3 upper limit of normal, ratio of pleural fluid albumin and blood <1.

MANAGEMENT

Stage I
• Sensitivity-appropriate antibiotics.
Stage II
• Chest tube drainage (small or large bore).
• Thrombolytics most likely to be effective during early stage empyema, and should be reserved for patients who are poor surgical candidates.
Stage III and failure of stage II to resolve
• If pleural space drainage is ineffective, or the effusion has loculated appearance on imaging, a *VATS decortication* should be performed
without delay
• If complete lung expansion is not achieved by VATS, then should convert to open thoracotomy: in processes that have been going
>14 days, or in patients who have chest wall tenderness, need for conversion for open thoracotomy is higher.
• *Open decortication* indicated for late stage II, stage III, and incomplete lung expansion with VATS.
• *Chest wall window* (Eloesser flap) may be required if lung cannot expand and empyema chronically reaccumulates, or in the case
of a BPF that cannot be closed.

DECORTICATION

- This is a major undertaking usually performed through a posterolateral thoracotomy attempting to completely remove what is usually densely adherent of visceral peel off the lung to allow it to completely re-expand.
- It is indicated for treatment of stage III empyemas : early stage II decortications are difficult because there is less of a plane between the lung and the peel than in later stage III empyemas .

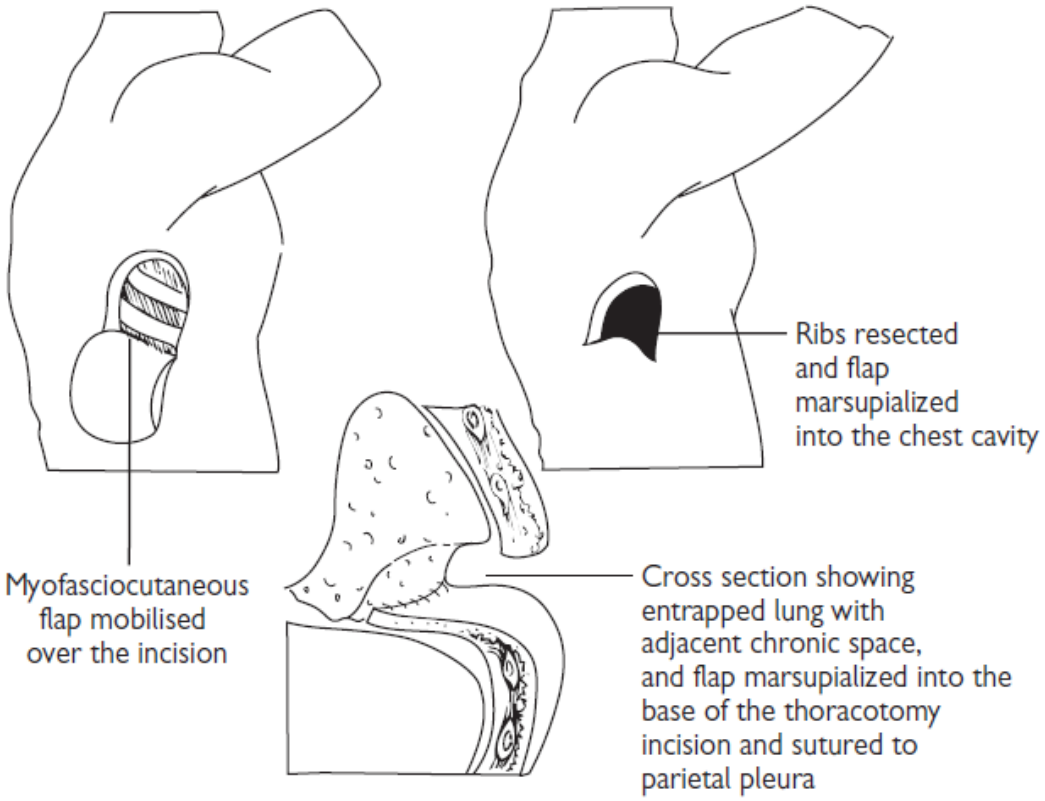
Ribs resected
and flap
marsupialized
into the chest cavity
Myofasciocutaneous
flap mobilised
over the incision
Cross section showing
entrapped lung with
adjacent chronic space,
and flap marsupialized into the
base of the thoracotomy
incision and sutured to
parietal pleura

[redacted]' 2/9/09 Condition