
بسم الله الرحمن الرحيم

Heart

- The heart is a hollow **muscular** organ that is somewhat **pyramid** shaped and lies within the pericardium in the mediastinum.
- It is **connected** at its base to the great blood vessels but otherwise lies **free** within the pericardium.

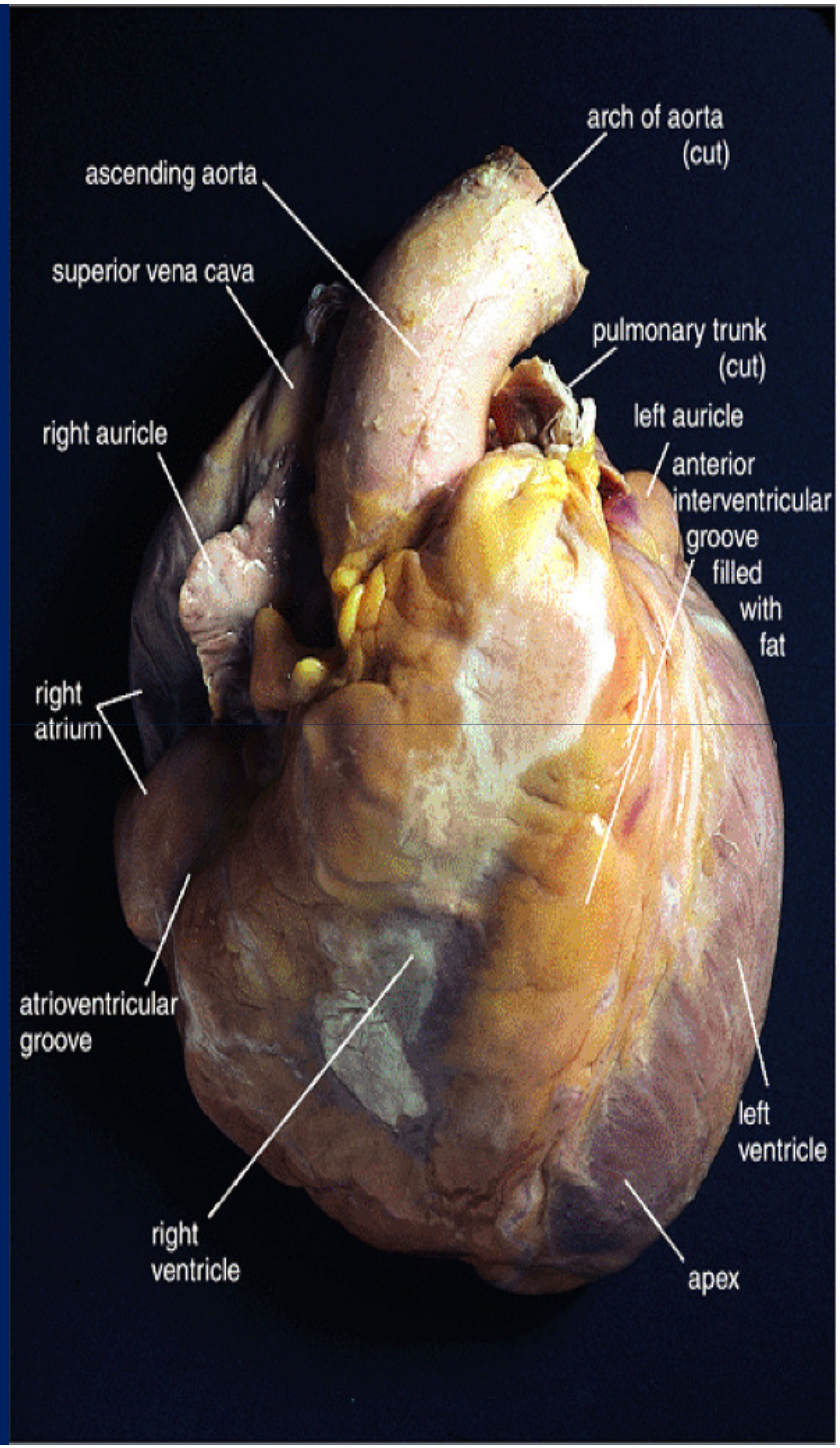

Surfaces of the Heart

- The heart has three surfaces: sternocostal (**anterior**), diaphragmatic (**inferior**), and a base (**posterior**). It also has an **apex**, which is directed downward, forward to the left.
- The **sternocostal surface** is formed mainly by the right atrium and the right ventricle, which are separated from each other by the vertical **atrioventricular** groove.
- The **diaphragmatic surface** of the heart is formed mainly by the right and left ventricles separated by the **posterior interventricular** groove. The inferior surface of the right atrium, into which the inferior vena cava opens, also forms part of this surface.
- The **base of the heart**, or the **posterior surface**, is formed mainly by the left atrium, into which open the four pulmonary veins.
- The **apex of the heart**, formed by the left ventricle, is directed downward, forward, and to the left. It lies at the level of the fifth left intercostal space.
- The **right border** is formed by the right atrium; The right ventricle is separated from the left ventricle by the **anterior interventricular** groove.
- **Left border is formed** by left auricle &below by left ventricle
- **Lower border** is formed mainly by right ventricle & atrium.

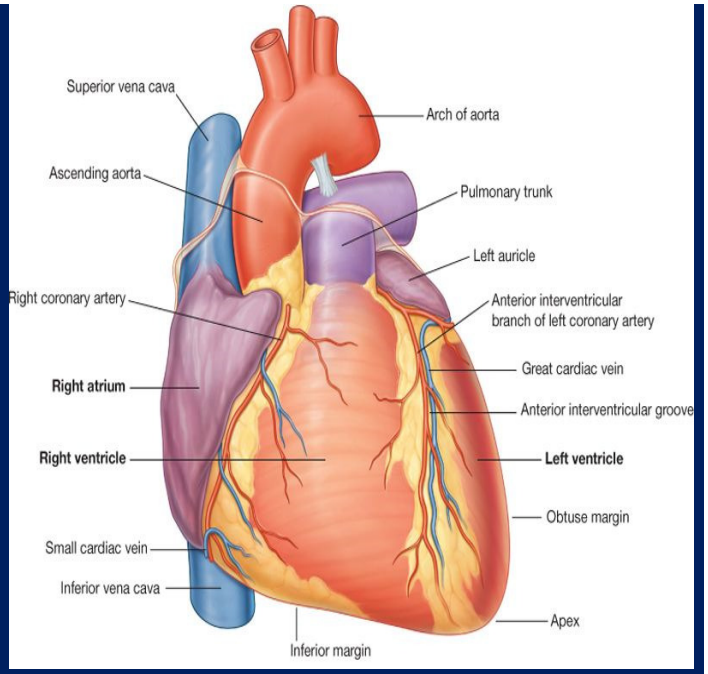

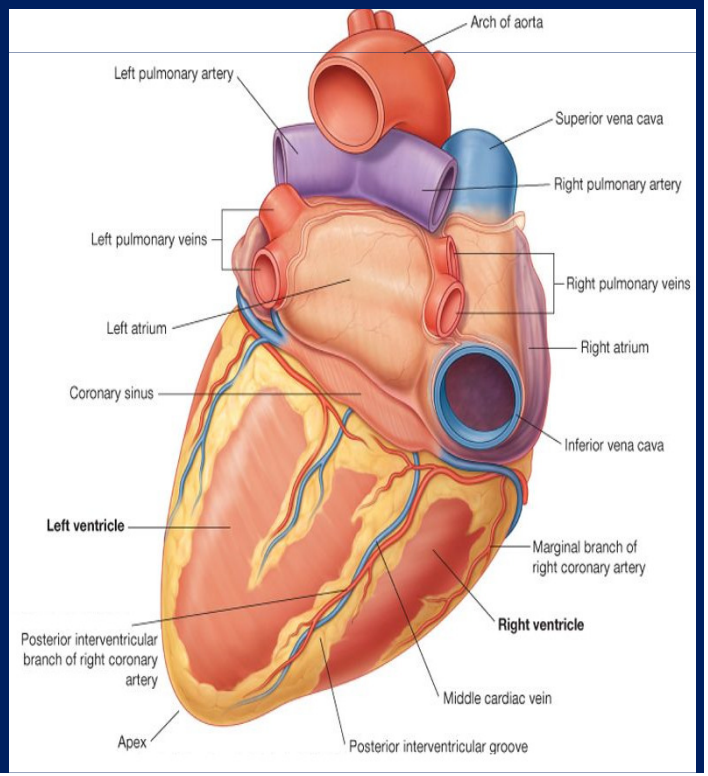

Chambers of the Heart

- The heart is divided by vertical septa into four chambers: the **right** and **left atria** and the **right** and **left ventricles**.
- The **right atrium** lies anterior to the left atrium, and the **right ventricle** lies anterior to the left ventricle.
- The **walls** of the heart are composed of cardiac muscle, the myocardium; covered externally with serous pericardium, the epicardium; and lined internally with a layer of endothelium, the endocardium.

Right Atrium

- The **right atrium** consists of a main cavity and a small outpouching, the **auricle**.
- On the outside of the heart at the junction between the right atrium and the right auricle is a vertical groove, the **sulcus terminalis**, which on the inside forms a ridge, the **crista terminalis**.
- The main part of the atrium that lies posterior to the ridge is smooth walled and the part of the atrium in front of the ridge is roughened or trabeculated by bundles of muscle fibers, the **musculi pectinati**, which run from the crista terminalis to the auricle.

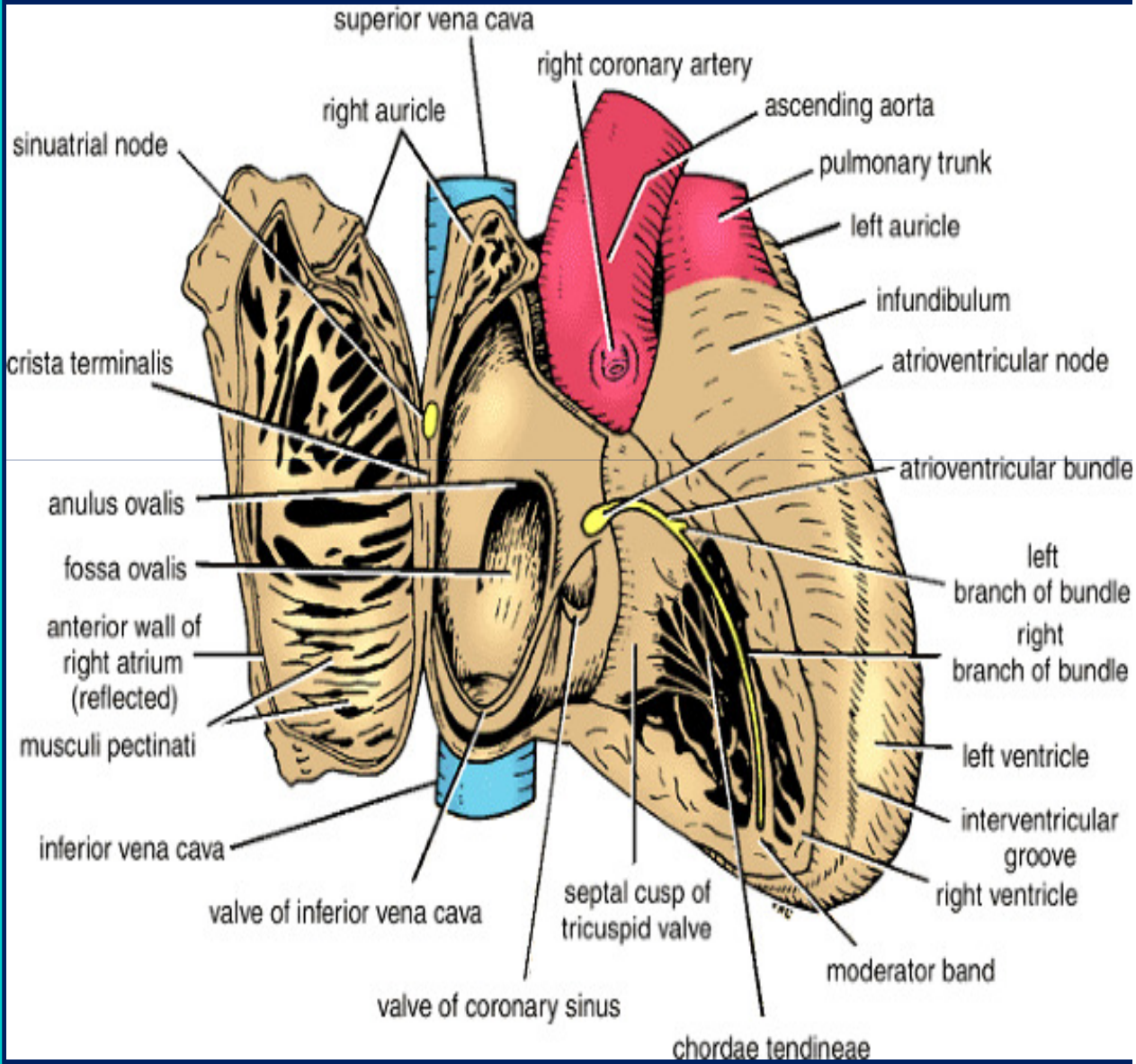

Openings into the Right Atrium

- The **superior vena cava** opens into the upper part of the right atrium; it has no valve. It returns the blood to the heart from upper half of body.
- The **inferior vena cava** (larger than the superior vena cava) opens into the lower part of the right atrium; it is guarded by a rudimentary, nonfunctioning valve. It returns the blood to the heart from lower half of the body.
- The **coronary sinus**, which drains most of blood from heart wall opens into the right atrium between the inferior vena cava &atrioventricular orifice. It is guarded by rudimentary, nonfunctioning valve.
- The **right atrioventricular** orifice lies anterior to the inferior vena caval opening and is guarded by the tricuspid valve.

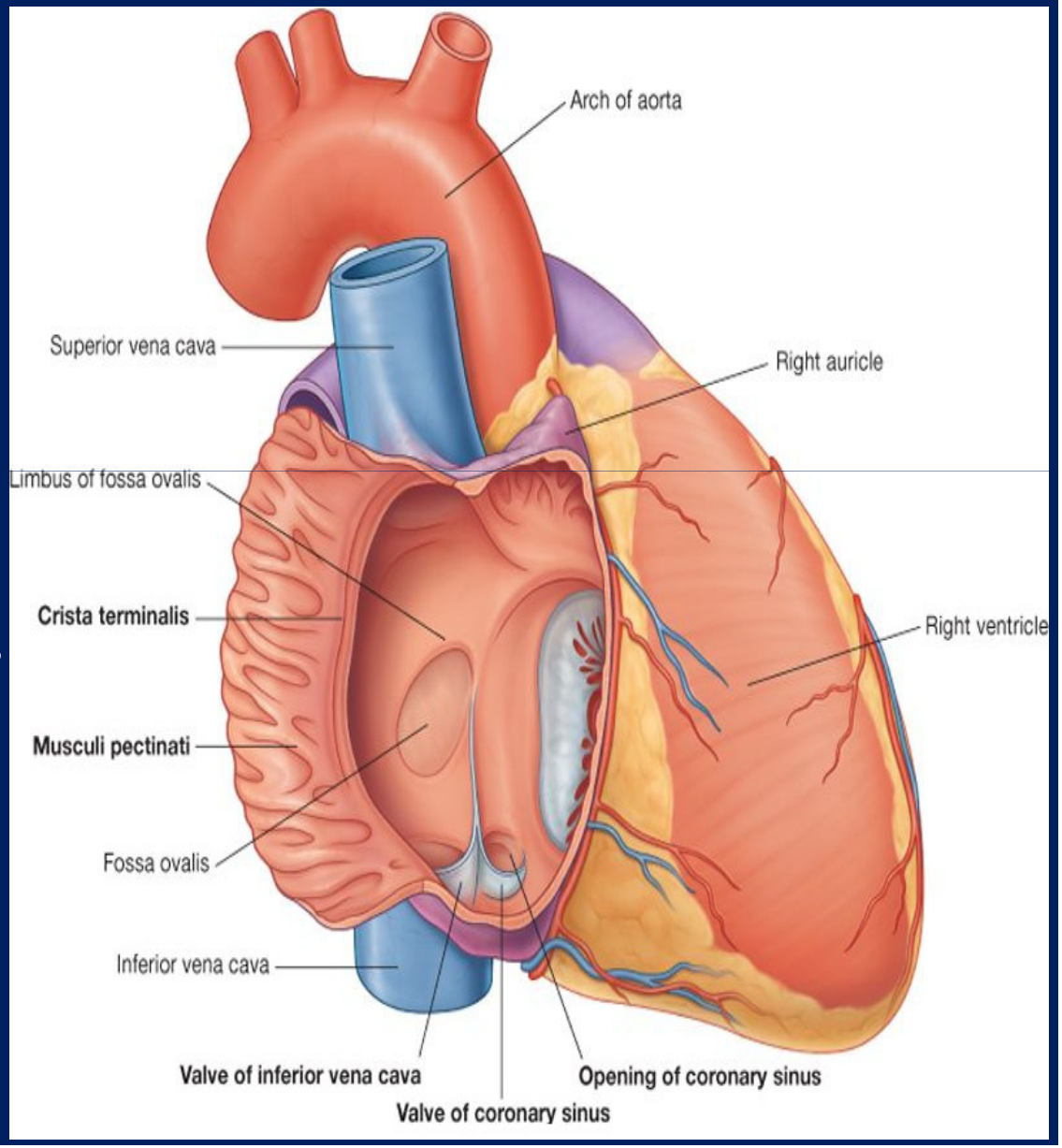

Right Ventricle

- The **right ventricle** communicates with the right atrium through **atrioventricular orifice** and with the **pulmonary trunk** through the **pulmonary orifice**. As the cavity approaches the pulmonary orifice it becomes funnel shaped, at which point it is referred to as the **infundibulum**.
- The walls of right ventricle show several internal projecting ridges formed of muscle bundles. The projecting ridges give ventricular wall a sponge like appearance and are known as **trabeculae carneae** .
- The **trabeculae carneae** are composed of three types. The **first type** comprises the **papillary muscles**, which project inward, being attached by their bases to the ventricular wall; their apices are connected by fibrous chords (the **chordae tendineae**) to the cusps of the tricuspid valve.

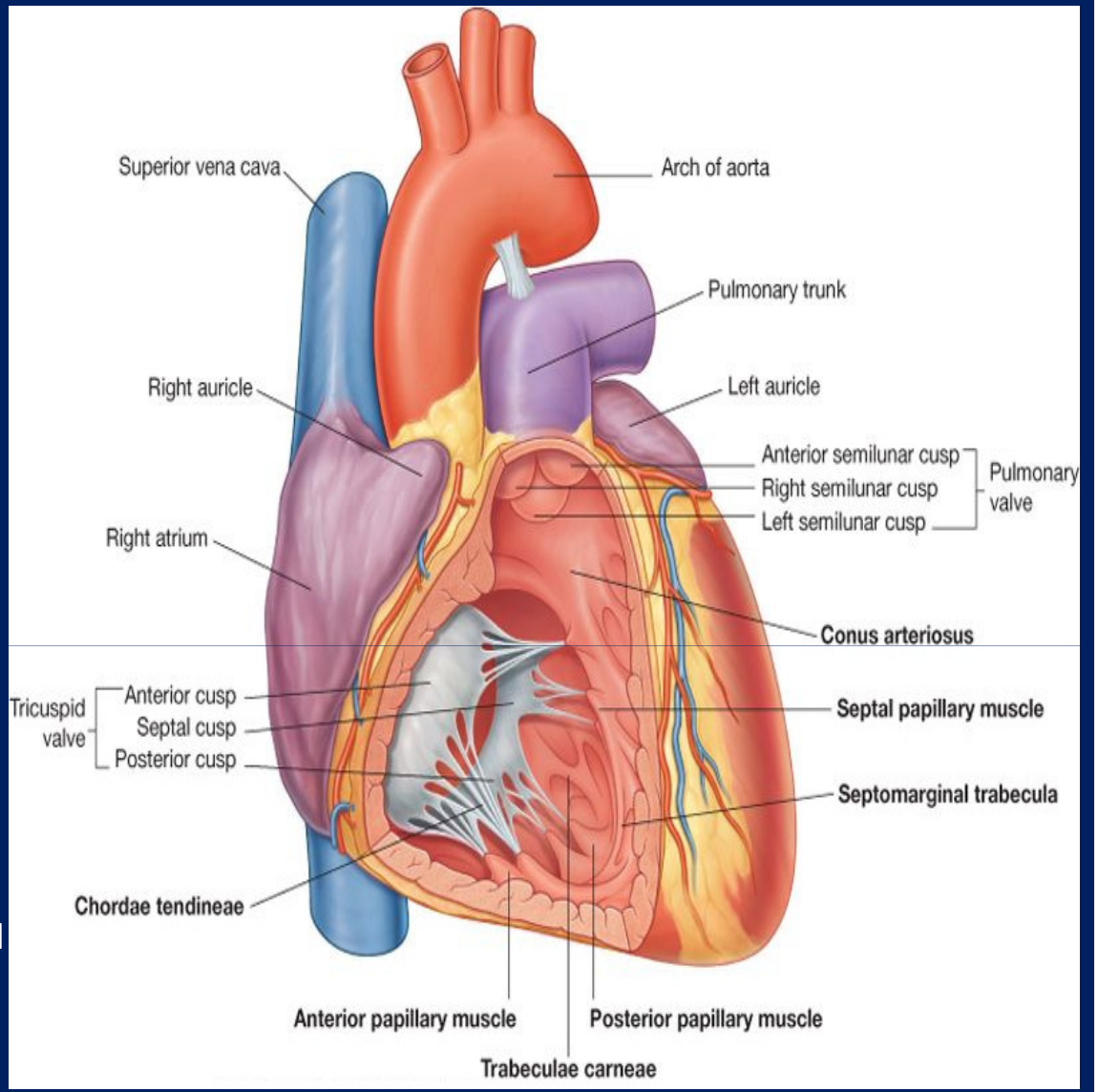

- The **second type** is a single specialized trabeculum, the **septomarginal trabecula** (**moderator band**), crosses the ventricular cavity from the septal to the anterior wall. It conveys the right branch of the atrioventricular bundle, to the anterior wall of the right ventricle.
- The **third type** is simply composed of prominent ridge.

Tricuspid Valve

- The **tricuspid valve** guards the **atrioventricular orifice** and consists of three cusps
- **Anterior**, **septal**, and **inferior** (posterior) **cusps**. The anterior cusp lies anteriorly, the septal cusp lies against the ventricular septum, and the inferior or posterior cusp lies inferiorly.
- The **bases** of the cusps are attached to the fibrous ring of the skeleton of the heart, whereas their free edges and ventricular surfaces are attached to chordae tendineae.
- The **chordae tendineae** connect the cusps to the papillary muscles. When the ventricle contracts, the papillary muscles contract and prevent the cusps from being forced into the atrium.

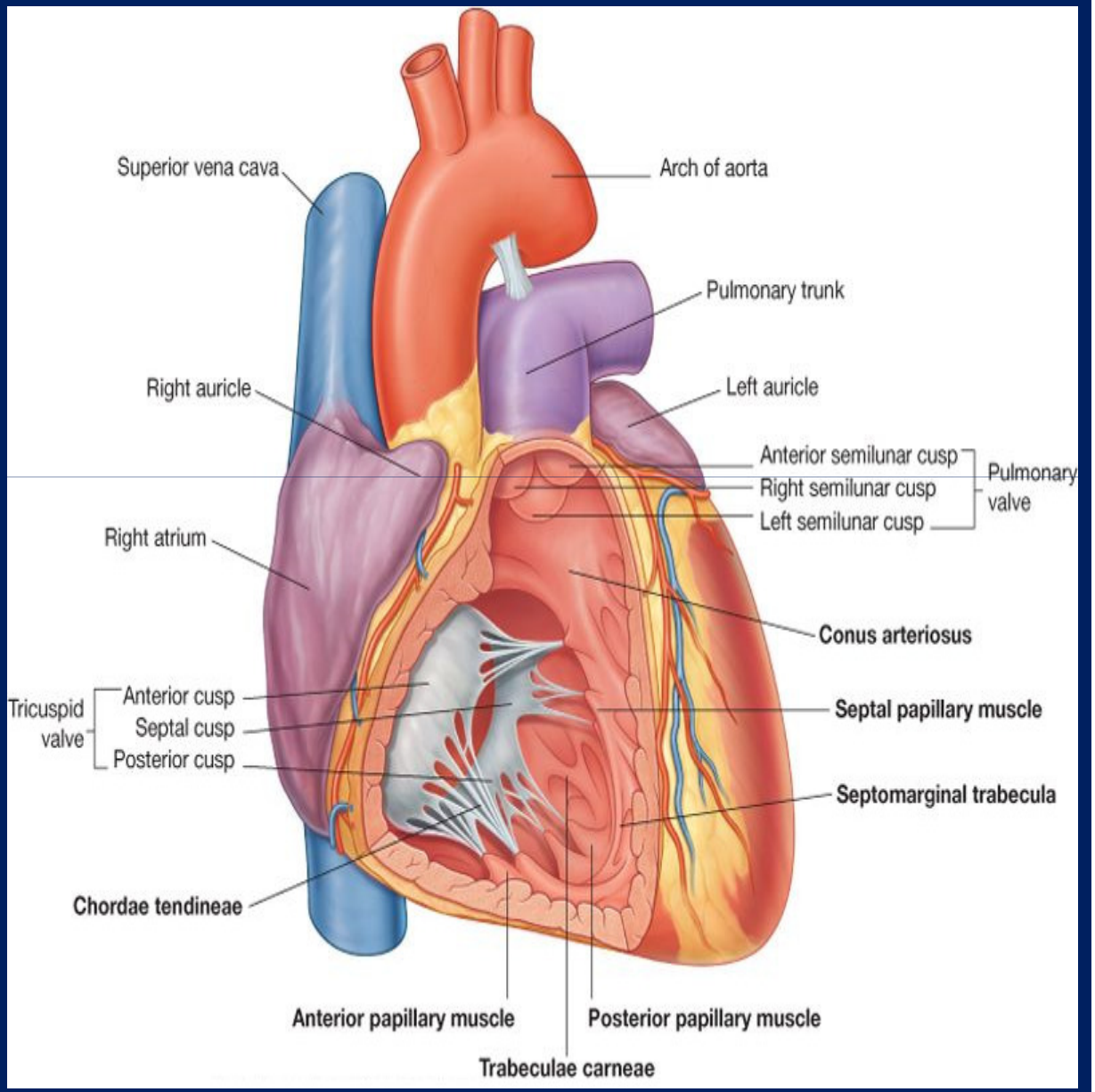

Pulmonary Valve

- The **pulmonary valve** guards the pulmonary orifice and consists of three semilunar cusps.
- The curved **lower** margins and sides of each cusp are attached to the arterial wall.
- The **open** mouths of the cusps are directed upward into the pulmonary trunk.
- **No chordae or papillary muscles** are associated with these valve cusps; the attachments of the sides of the cusps to the arterial wall prevent the cusps from prolapsing into the ventricle.
- At the root of the pulmonary trunk are three dilatations called the **sinuses**, and one is situated external to each cusp.
- The free superior edge of each cusp has a middle, thickened portion, the **nodule of the semilunar cusp**, and a thin lateral portion, the **lunula of the semilunar cusp**.
- The three semilunar cusps are arranged with one **posterior** (left cusp) and **two anterior** (anterior and right cusps).

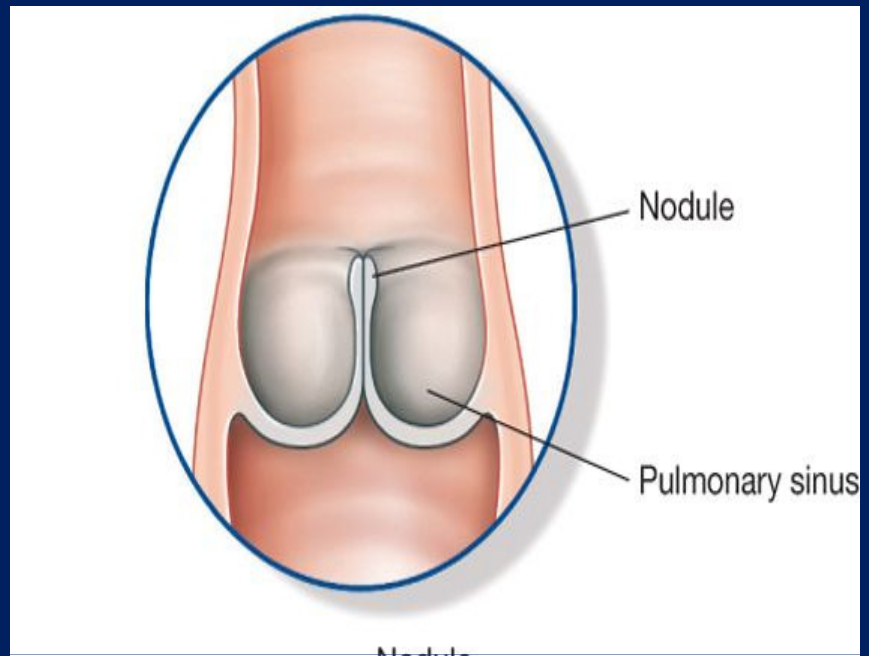

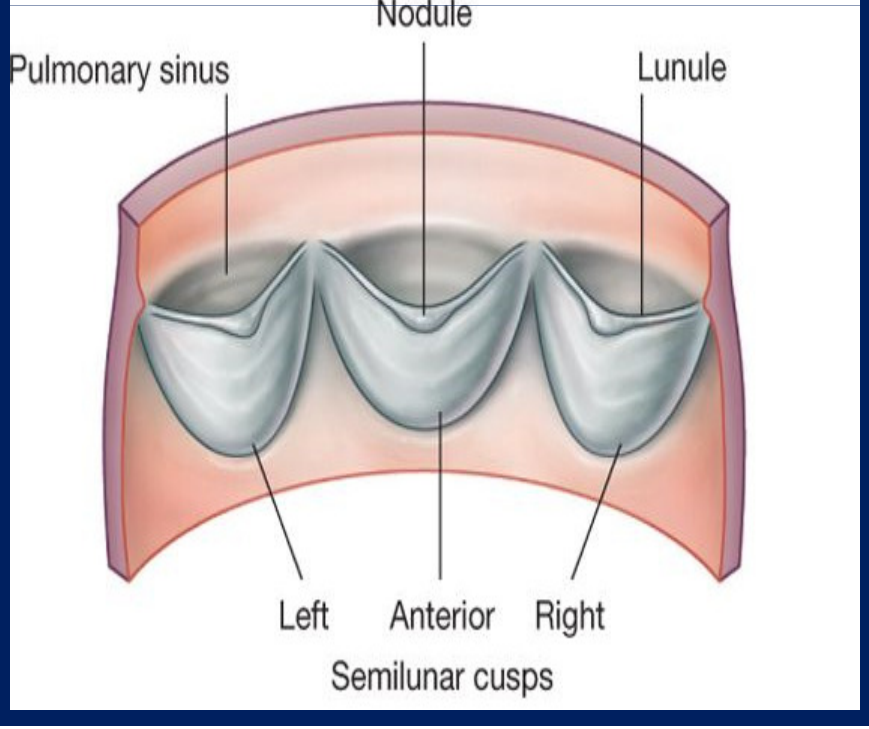

Left Atrium

- Similar to the right atrium, the left atrium consists of a main cavity and a **left auricle**.
- The **left atrium** is situated behind the right atrium and forms the greater part of the base or the posterior surface of the heart.
- Behind it lies the **oblique sinus** of the serous pericardium, and the **fibrous pericardium** separates it from the **esophagus**.
- The interior of the left atrium is smooth, but the left auricle possesses muscular ridges as in the right auricle.

Openings into the Left Atrium

- The **four pulmonary veins**, two from each lung, open through the posterior wall and have **no valves**.
- The **left atrioventricular** orifice is guarded by the **mitral** valve.

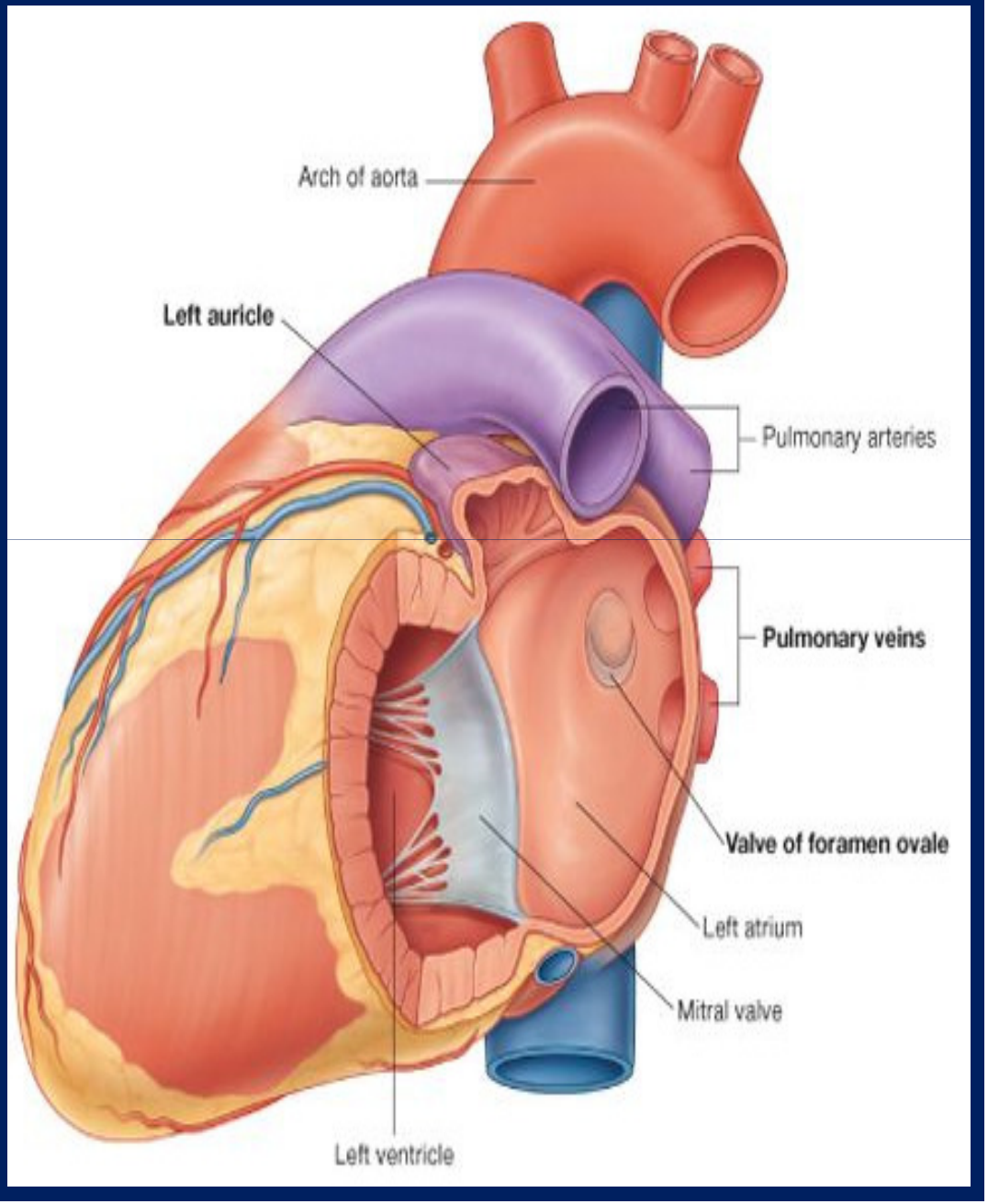

Left Ventricle

- The **left ventricle** communicates with the left atrium through the **atrioventricular orifice** and with aorta through the **aortic orifice**.
- The **walls** of the left ventricle are three times thicker than those of the right ventricle. (The left intraventricular blood **pressure** is six times higher than that inside the right ventricle.)
- In **cross section**, the left ventricle is circular; the right is crescentic because of the bulging of the ventricular septum into the cavity of the right ventricle.
- There are well-developed **trabeculae carneae**, two large **papillary muscles**, but no moderator band. The part below the aortic orifice(aortic vestibule).

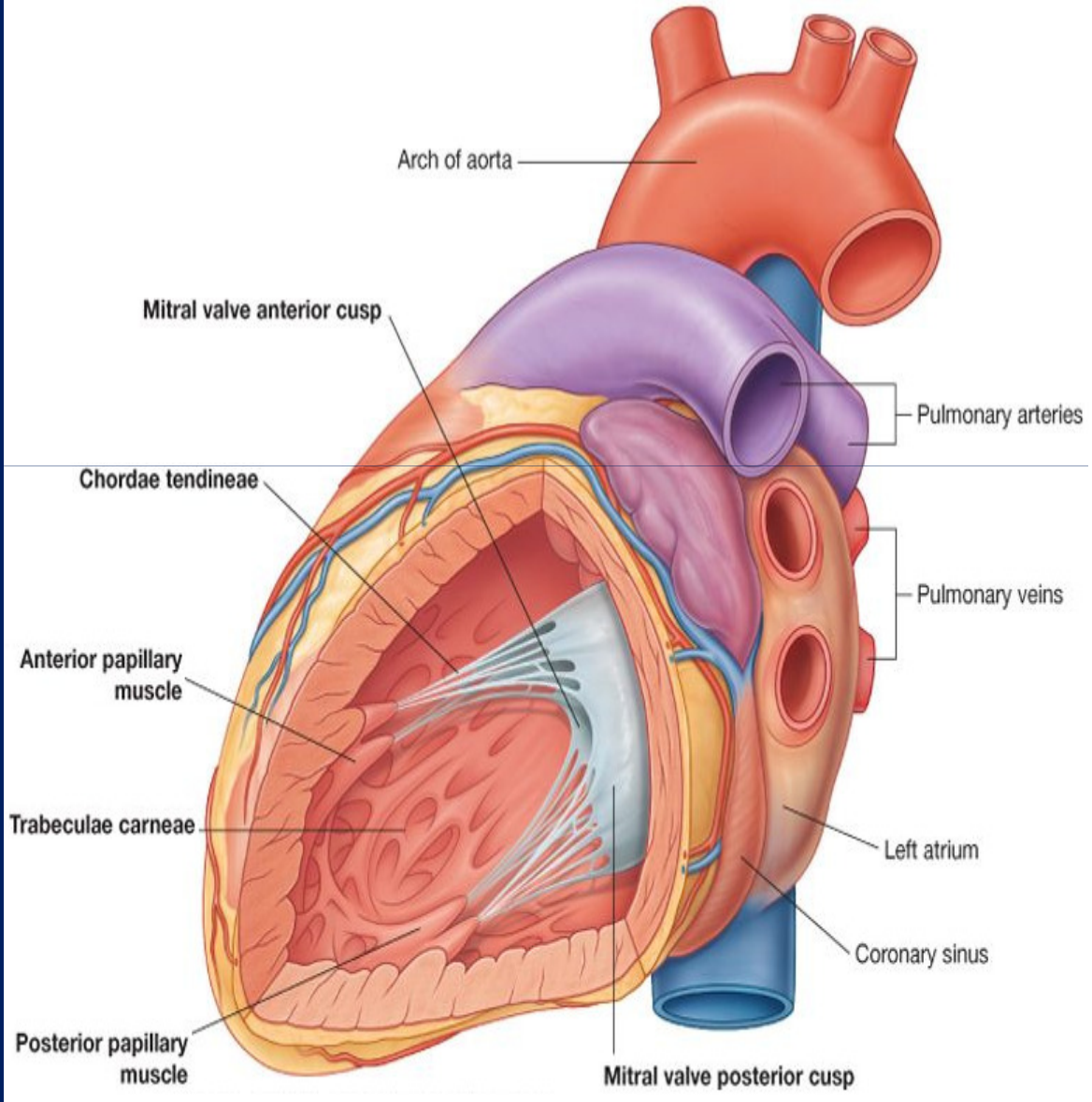

mitral valve

- The **mitral valve** guards the **atrioventricular orifice**.
- It consists of **two cusps**, one **anterior** and one **posterior**, which have a structure similar to that of cusps of the tricuspid valve.
- The **anterior** cusp is the larger and intervenes between the atrioventricular and the aortic orifices. The attachment of the chordae tendineae to the cusps and the papillary muscles is similar to that of the tricuspid valve.

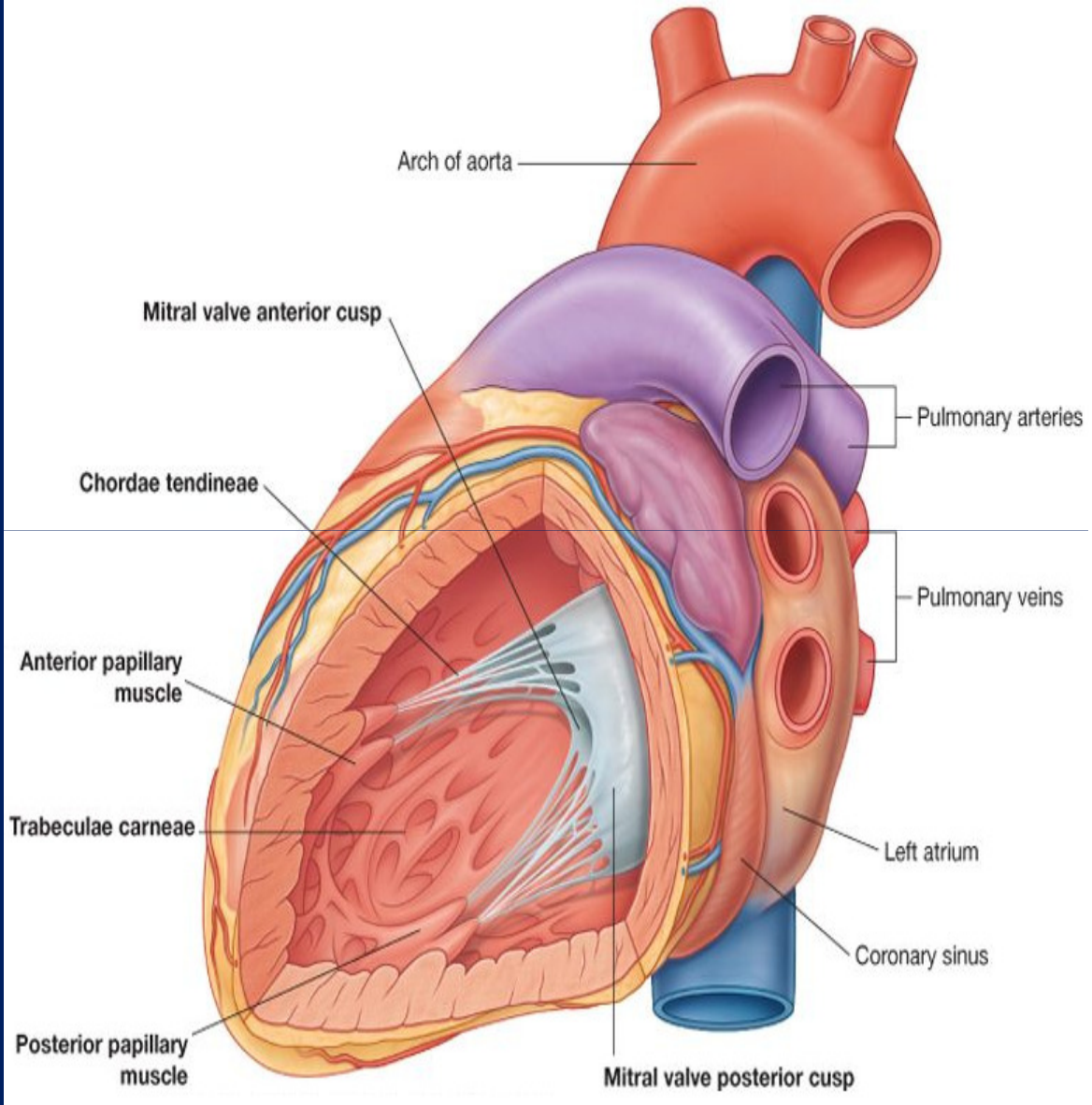

Structure of the Heart

- The walls of the heart are composed of a thick layer of cardiac muscle, the **myocardium**, covered externally by the **epicardium** and lined internally by the **endocardium**.
- The **atrial portion** of heart has relatively **thin** walls and is divided by the **atrial** (interatrial) **septum** into the right and left atria.
- The **ventricular portion** of the heart has **thick** walls and is divided by the **ventricular** (interventricular) **septum** into the right and left ventricles. The septum is placed obliquely, with one surface facing forward and to the right and other facing backward and to the left.
- Its **position** is indicated on the surface of the heart by the **anterior** and **posterior** interventricular grooves.
- The lower part of the septum is **thick** and formed of **muscle**. The smaller upper part of the septum is **thin** and **membranous** and attached to the fibrous skeleton

aortic valve

- The **aortic valve** guards the **aortic orifice** and is precisely similar in structure to the pulmonary valve.
- One cusp is situated on the anterior wall (**right cusp**) and two are located on the posterior wall (**left and posterior cusps**).
- Behind each cusp the aortic wall bulges to form an **aortic sinus**. The anterior aortic sinus gives origin to the right coronary artery, and the left posterior sinus gives origin to the left coronary artery.

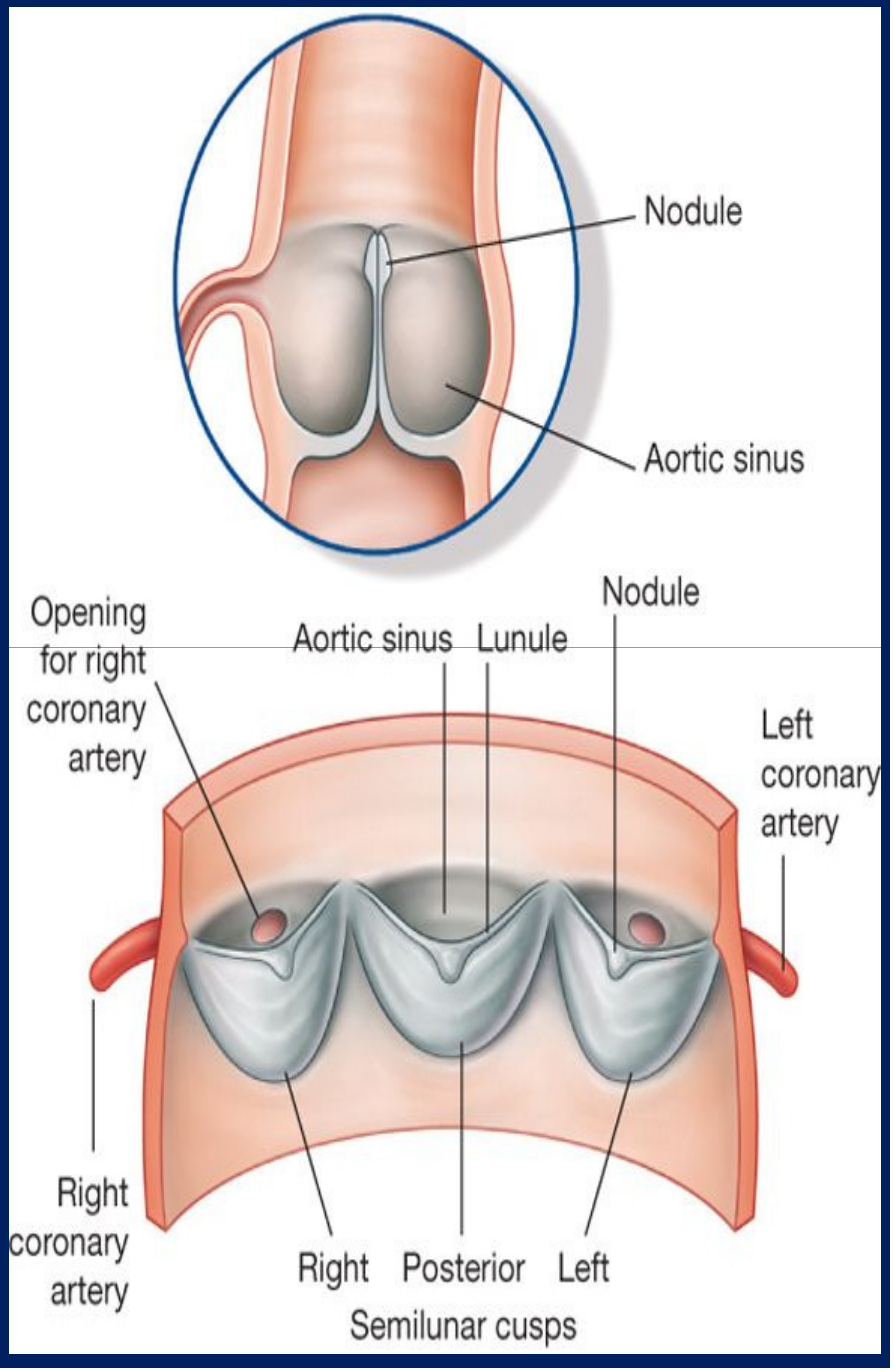

fibrous skeleton

- The so-called **skeleton** of the heart consists of **fibrous rings** that surround the atrioventricular, pulmonary, and aortic orifices and are continuous with the membranous upper part of the **ventricular septum**.
- The fibrous rings around the atrioventricular orifices separate muscular **walls** of the **atria** from those of the ventricles but provide attachment for the muscle fibers.
- The fibrous rings support the bases of the valve cusps and prevent the valves from stretching and becoming incompetent.
- The **skeleton** of the heart forms the basis of electrical discontinuity between the atria and the ventricles.

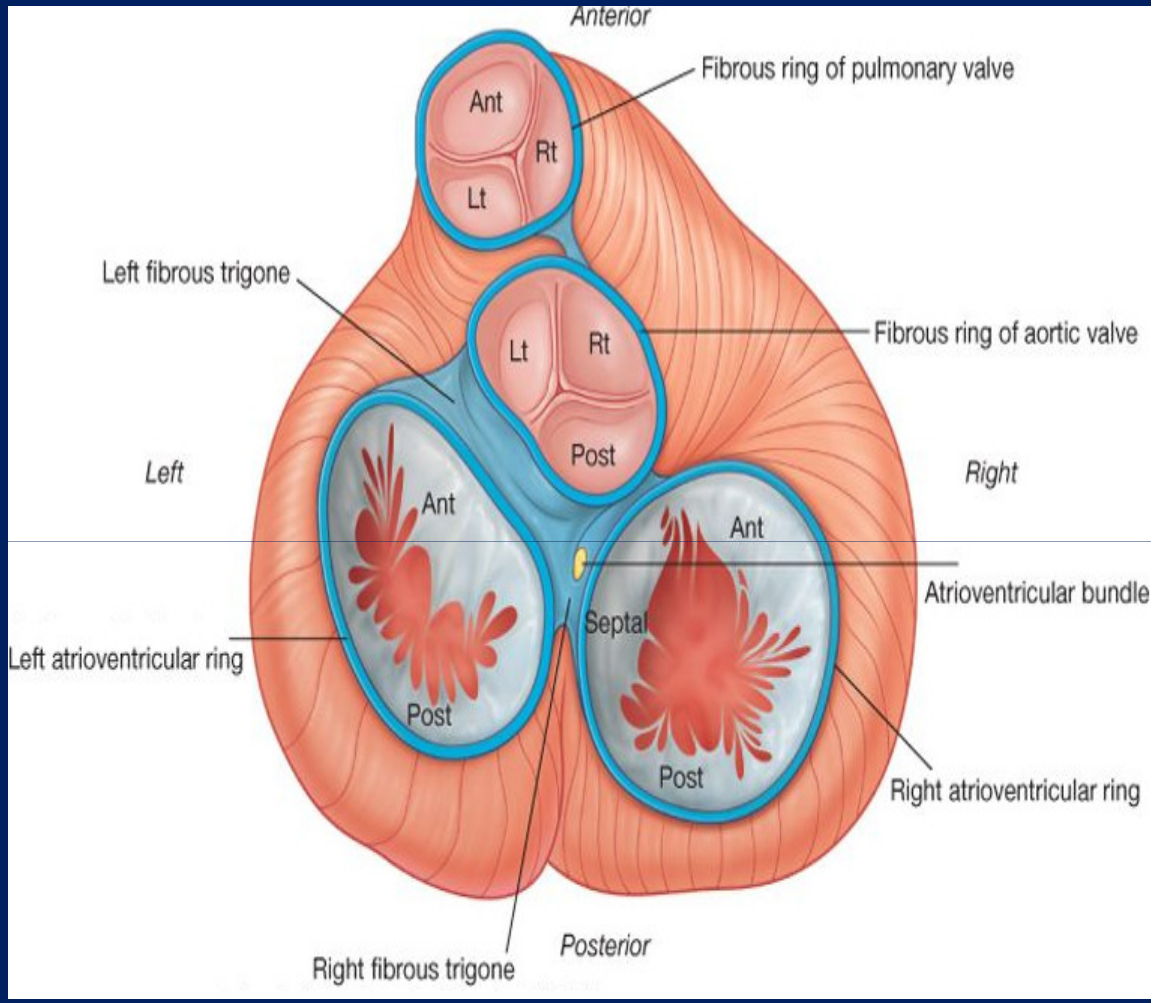

Conducting System of the Heart

The conducting system of the heart consists of specialized cardiac muscle present in the:

- Sinuatrial node,
- The atrioventricular node,
- The atrioventricular bundle and its right and left terminal branches,
- The subendocardial plexus of Purkinje fibers (specialized cardiac muscle fibers that form conducting system of the heart).

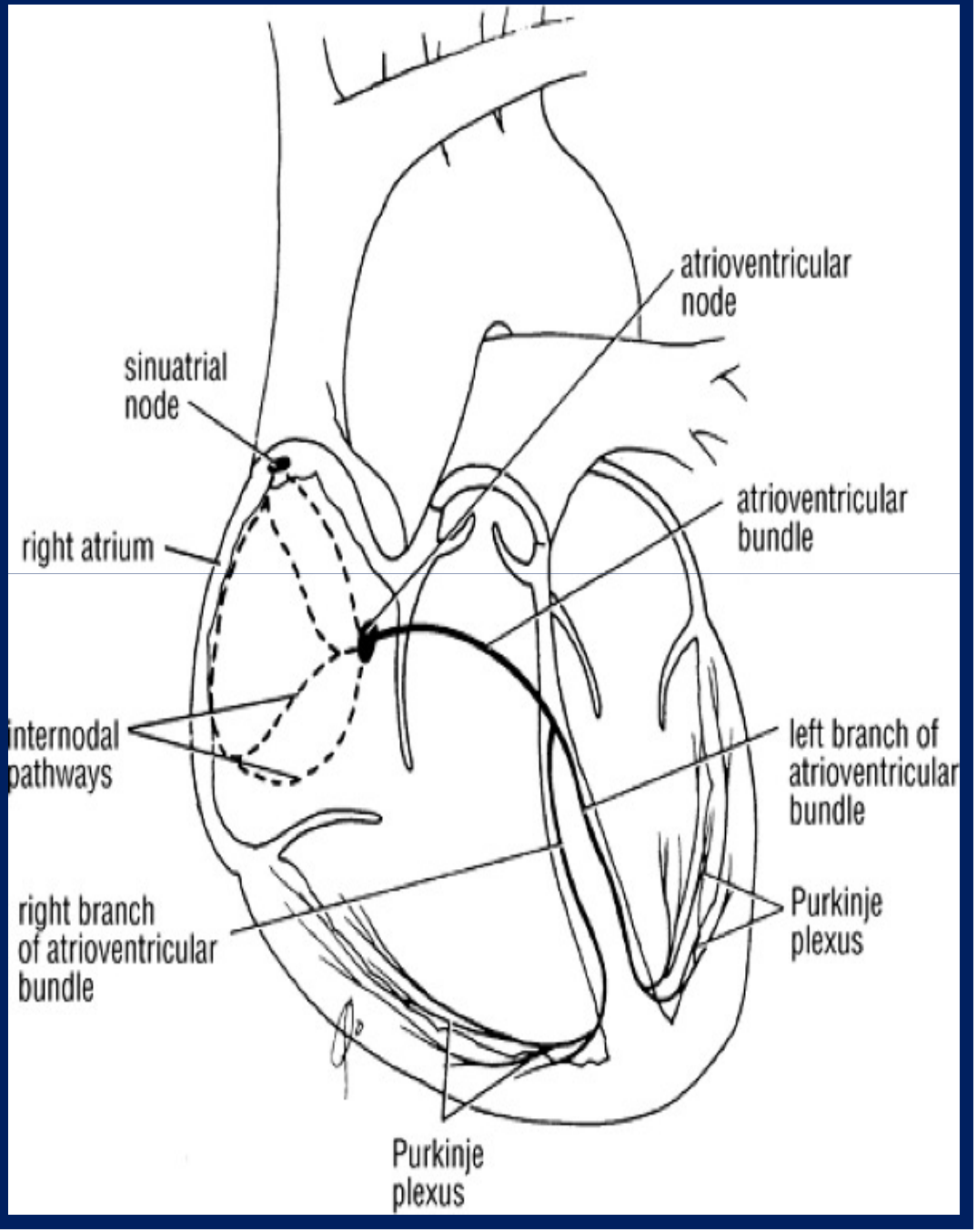

Sinuatrial Node

- The sinuatrial node is located in the wall of the right atrium in the upper part of the **sulcus terminalis** just to the right of the opening of the superior vena cava.
- The node spontaneously gives origin to **rhythmic electrical** impulses that spread in all directions through the cardiac muscle of the atria and cause the muscle to contract.

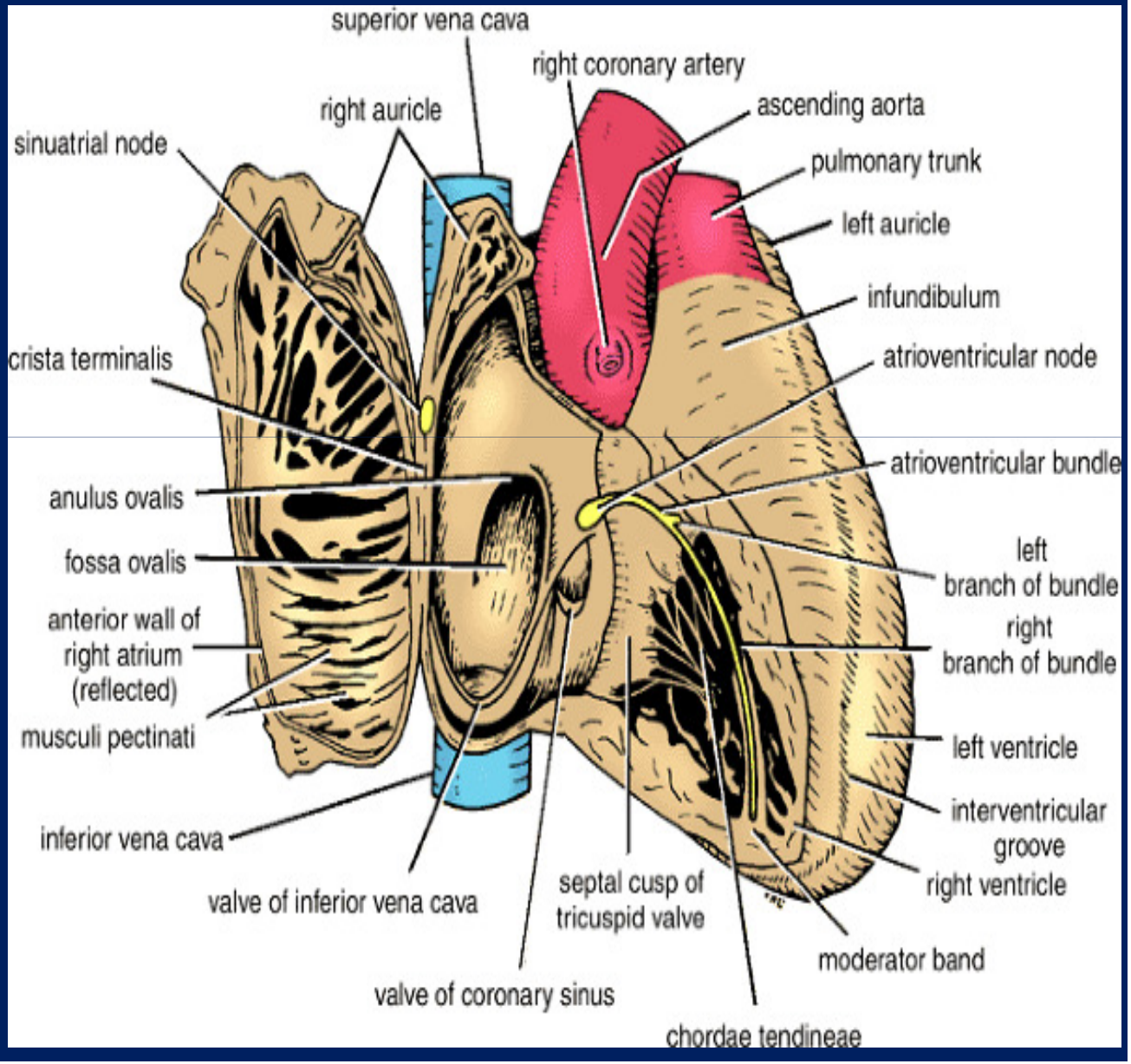

Atrioventricular Node

- The **atrioventricular node** is strategically placed on lower part of the atrial septum just above the attachment of the septal cusp of tricuspid valve.
- From it, the **cardiac impulse** is conducted to the **ventricles** by **atrioventricular bundle**.
- The **atrioventricular node** is stimulated by the excitation wave as it passes through the atrial myocardium.
- The **speed** of conduction of the cardiac impulse through the **atrioventricular node** (about 0.11 seconds) allows sufficient time for the atria to empty their blood into the ventricles before the ventricles start to contract.

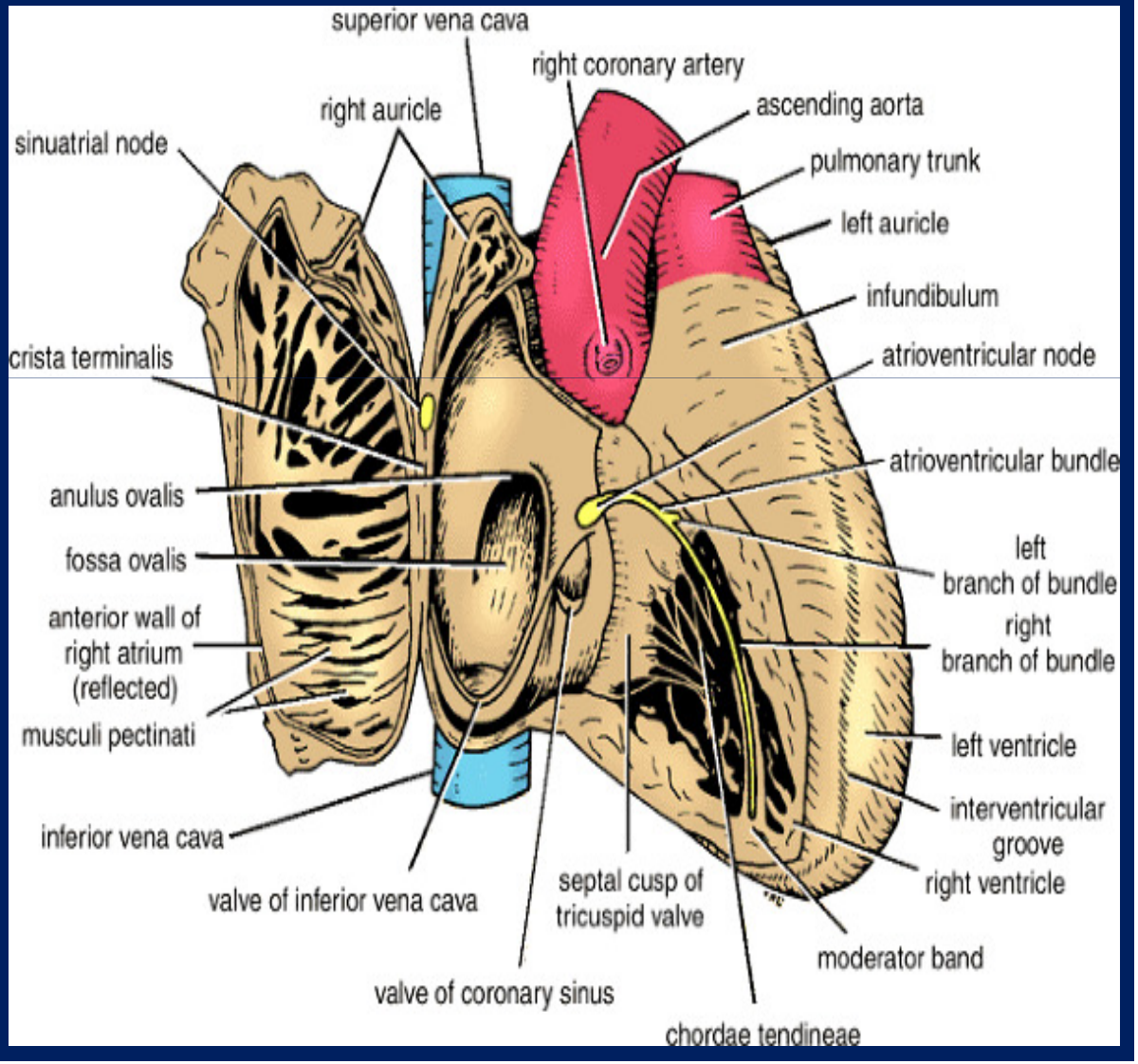

Atrioventricular Bundle

- The **atrioventricular bundle** (bundle of His) is the only pathway of cardiac muscle that **connects** the myocardium of atria and myocardium of ventricles.
- thus it is the only route along which the cardiac impulse can **travel** from the atria to the ventricles.
- The bundle **descends** through the fibrous skeleton of the heart.

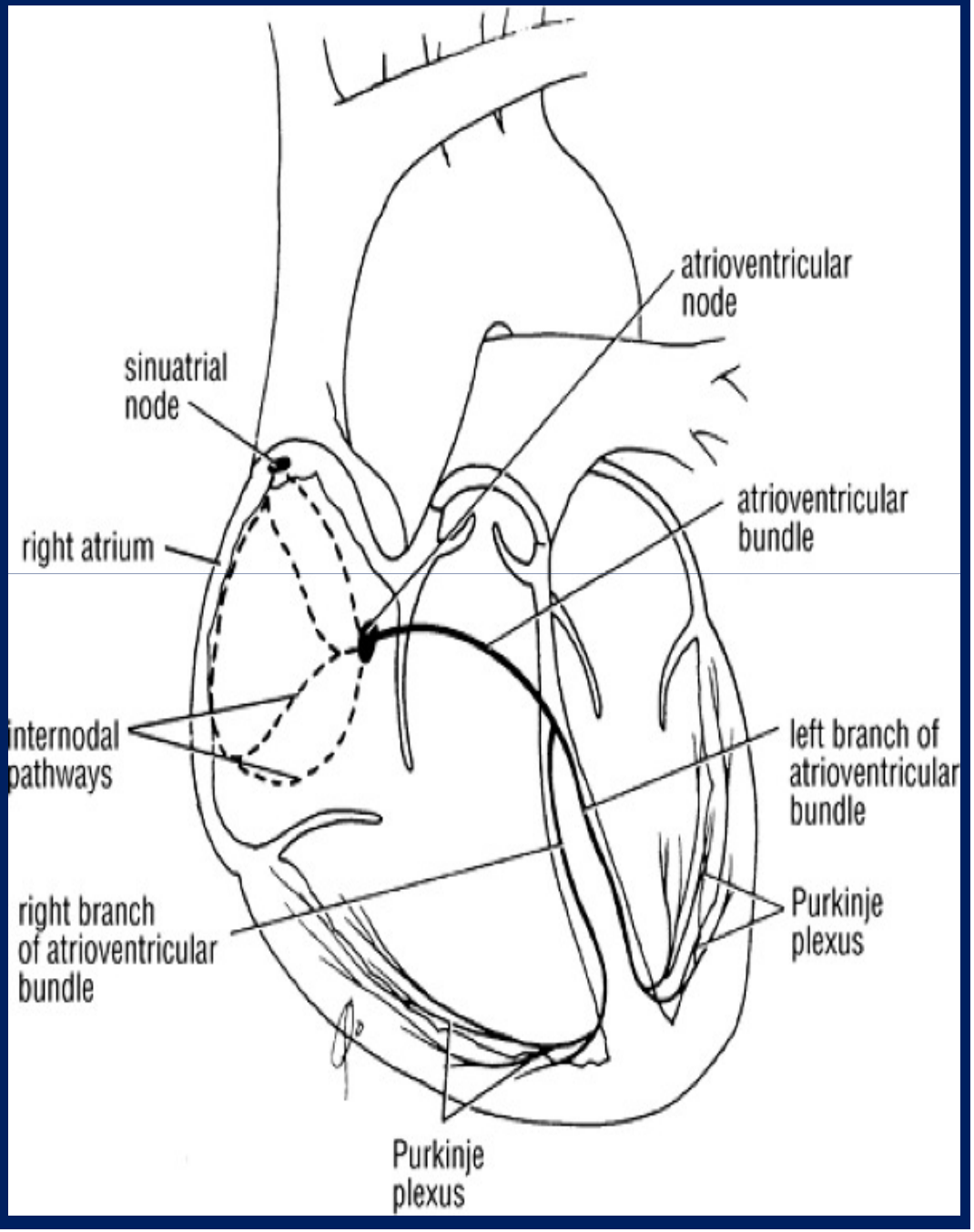

Arterial Supply of the Heart

- The arterial supply of the heart is provided by the **right** and **left** coronary arteries, which arise from the **ascending aorta** immediately above the **aortic valve**.
- The coronary arteries and their major branches are distributed over the surface of the heart, lying within subepicardial connective tissue.

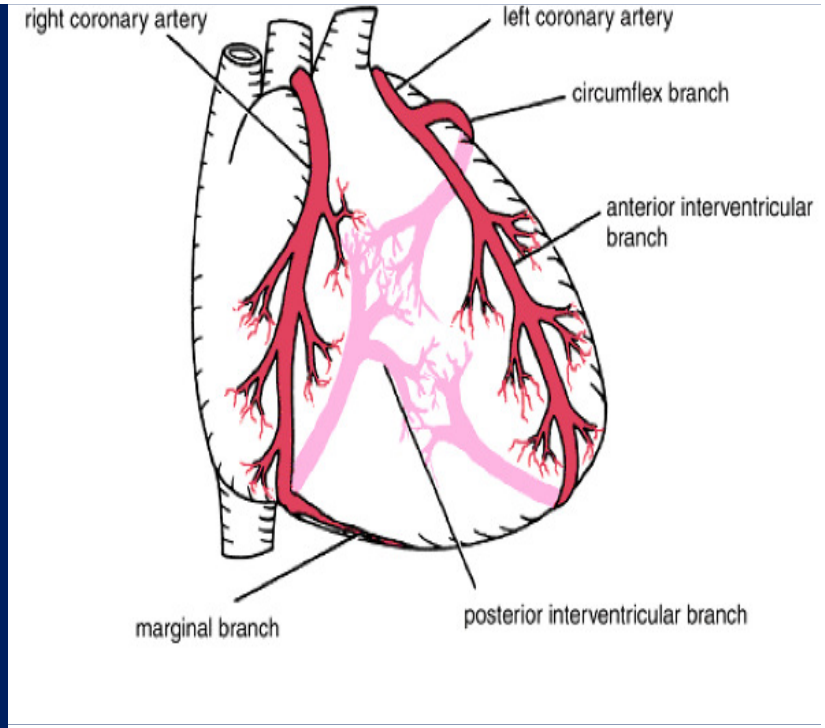

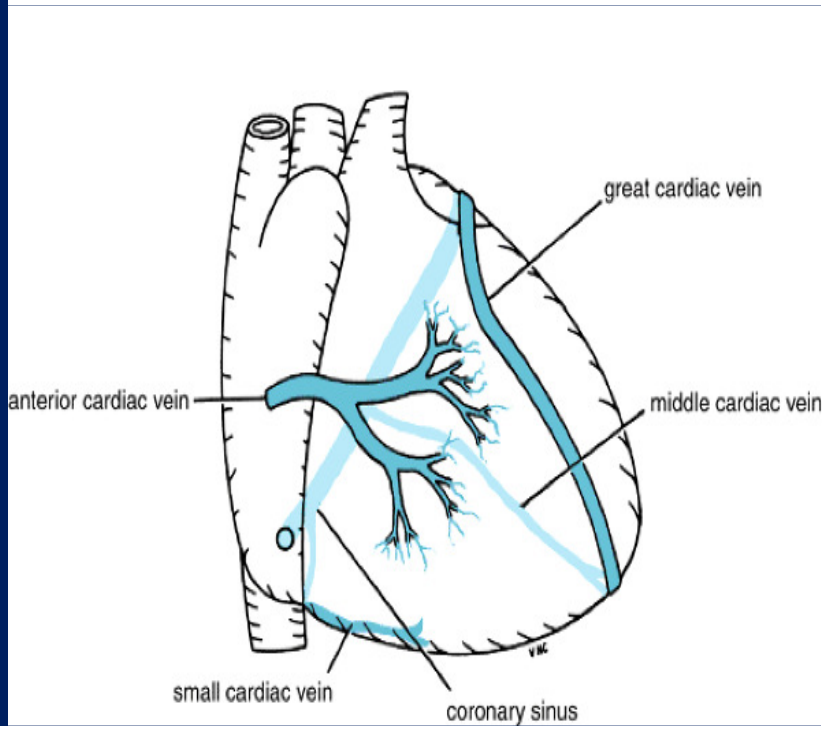

Right Coronary Artery

- The **right coronary artery** arises from the **anterior aortic sinus** of the ascending aorta and runs forward **between** the pulmonary trunk &right auricle.
- It descends almost vertically in right **atrioventricular groove**, and at the inferior border of the heart it continues posteriorly along the atrioventricular groove to **anastomose** with the left coronary artery in posterior interventricular groove.
- The following branches from the right coronary artery **supply** the **right atrium** and **right ventricle** and **parts** of the **left atrium** and **left ventricle** and the **atrioventricular septum**.

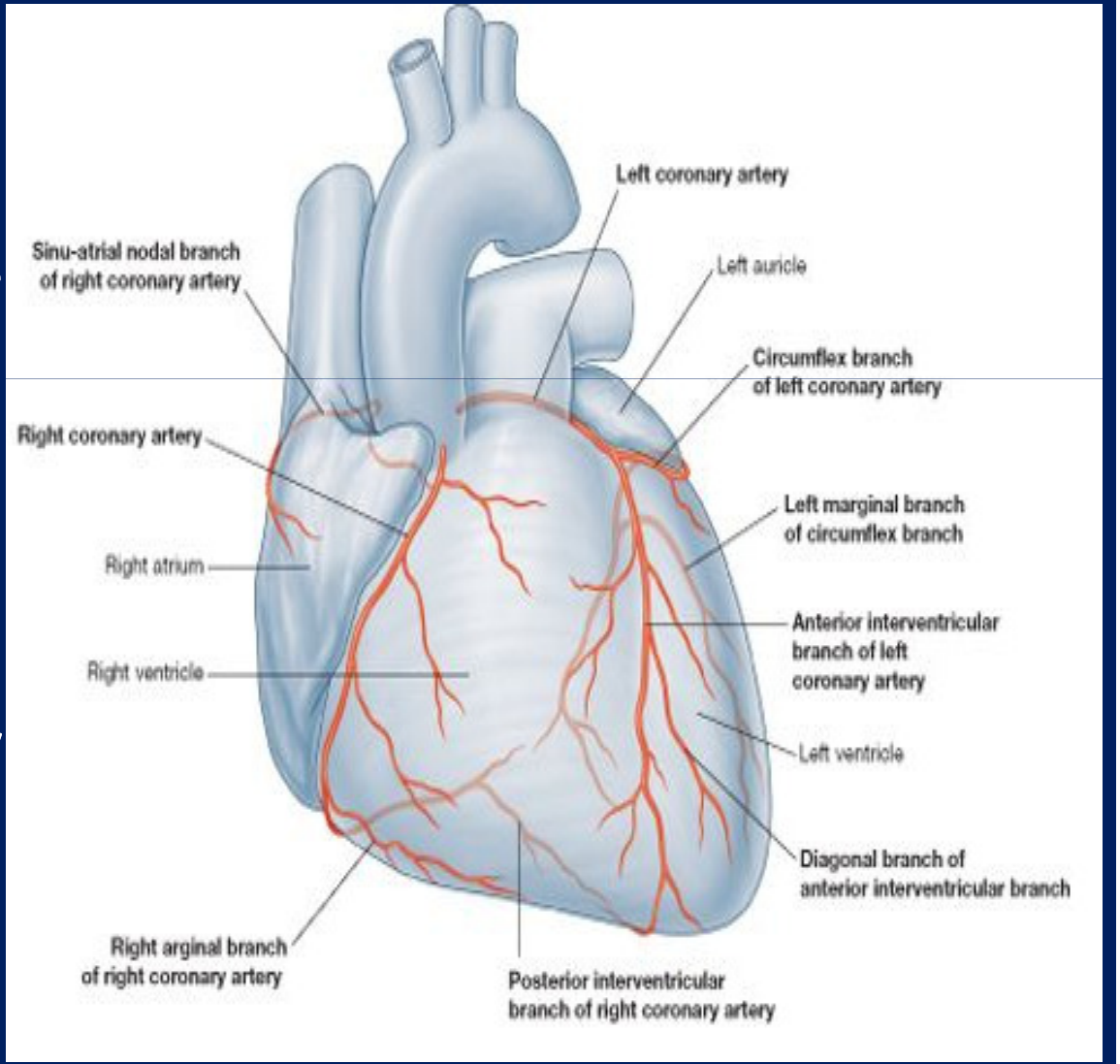

Branches of the Right Coronary Artery

- The **right conus artery** **supplies** the anterior surface of pulmonary conus (infundibulum of the right ventricle) and the upper part of the anterior wall of the right ventricle.
- The **anterior ventricular branches** are **two** or **three** in number and **supply** the anterior surface of the right ventricle. The marginal branch is largest and runs along the lower margin of costal surface to reach the **apex**.
- The **posterior ventricular branches** are usually **two** in number and **supply** the diaphragmatic surface of the right ventricle.

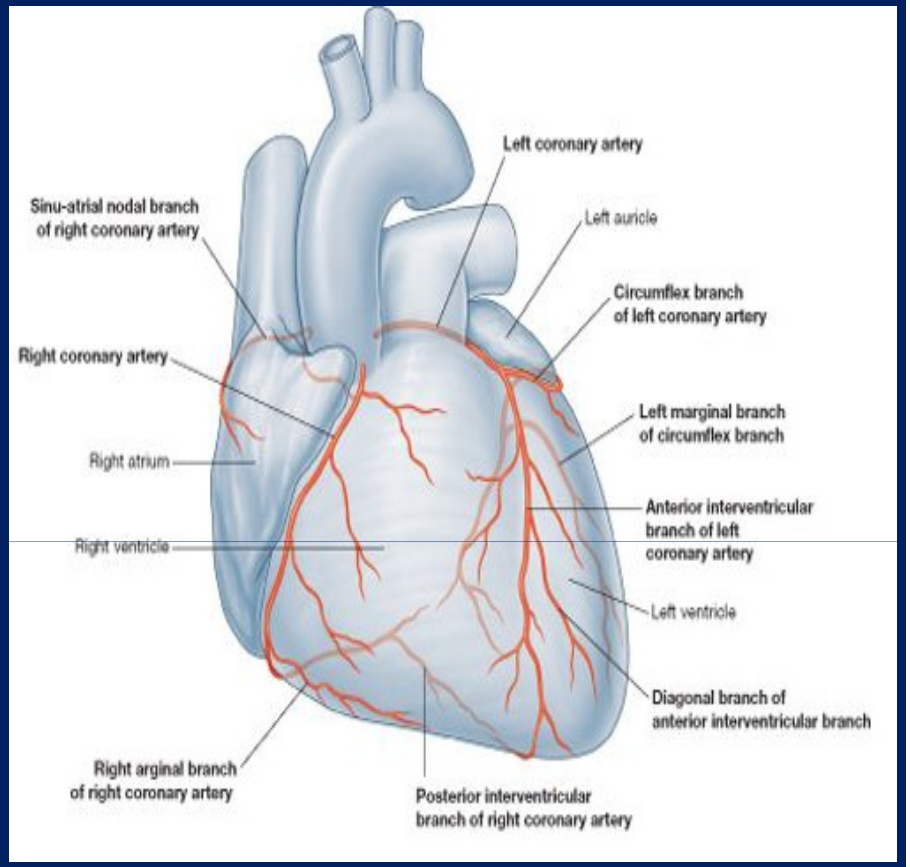

- The **posterior interventricular** (descending) artery runs toward the **apex** in the posterior interventricular groove. It gives off branches to the **right** and **left ventricles**, including its inferior wall. It **supplies** branches to the **posterior part** of the ventricular septum but not to the apical part, which **receives** its **supply** from the **anterior interventricular** branch of left coronary artery.
- The **atrial branches** **supply** the anterior and lateral surfaces of the right atrium. **One branch** **supplies** the posterior surface of both the right and left atria. (artery of the sinuatrial node).

Left Coronary Artery

- The **left coronary artery**, which is usually **larger** than the right coronary artery, **supplies** the major part of the heart, including the **greater** part of the left atrium, left ventricle, and ventricular septum.
- It arises from the **left posterior aortic sinus** of the ascending aorta and passes forward **between** the pulmonary trunk and the left auricle .
- It then enters the **atrioventricular groove** and divides into an **anterior interventricular** branch and a **circumflex** branch.

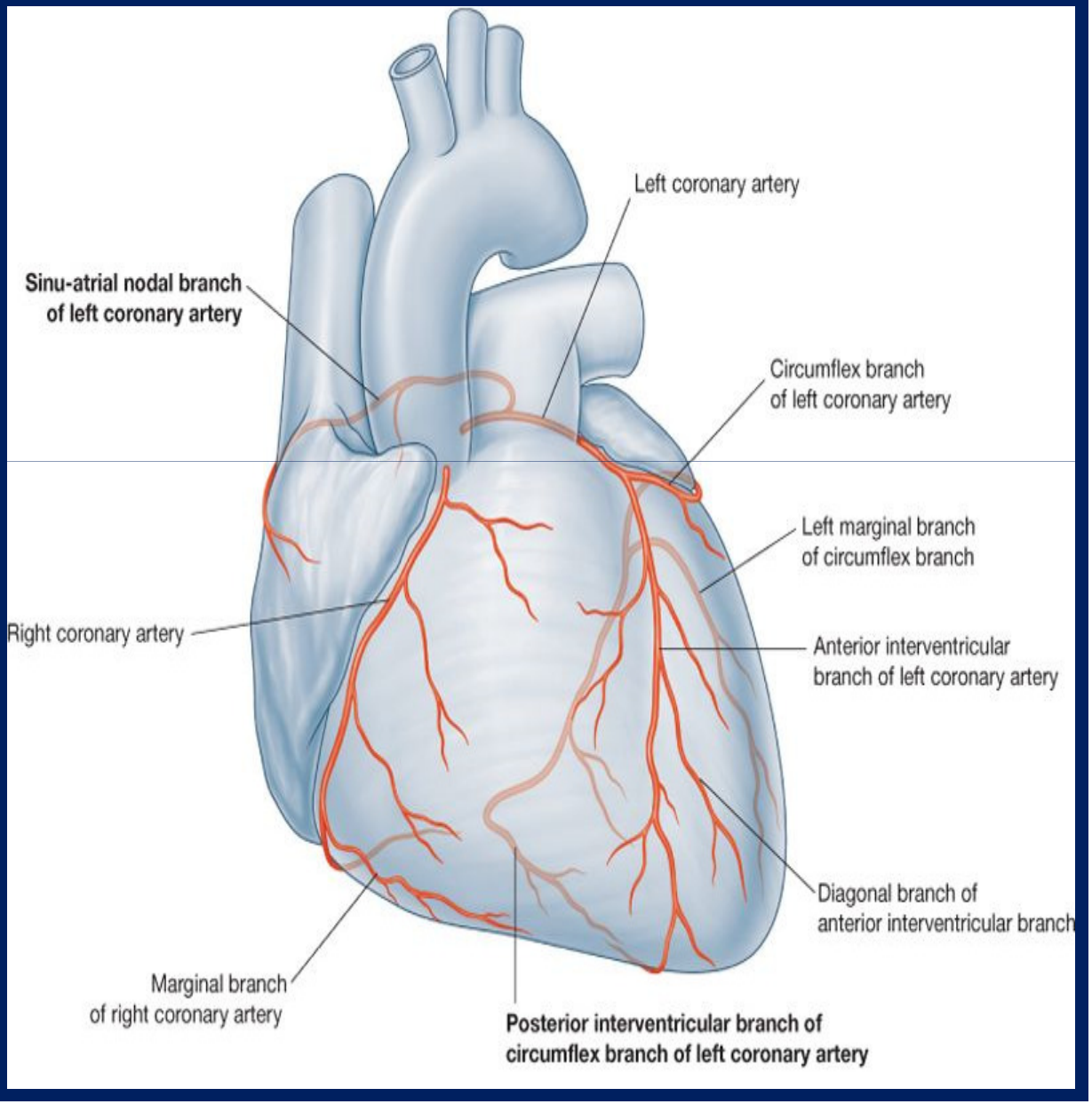

Branches of the Left Coronary Artery

- The anterior interventricular (descending) branch runs downward in the anterior interventricular groove to apex of heart. In most individuals it then passes around the **apex** of the heart to enter the posterior interventricular groove and anastomoses with the terminal branches of the **right coronary artery**.
  The anterior interventricular branch **supplies** right and left ventricles with numerous branches that also **supply** anterior part of ventricular septum.
  One of these ventricular branches (left diagonal artery) may arise directly from trunk of the left coronary artery. A small left conus A **supplies** pulmonary conus.
- The circumflex artery winds around the left margin of the heart in the atrioventricular groove.
  A left marginal artery is a large branch that **supplies** the left margin of the left ventricle down to the apex.
- Anterior and posterior ventricular branches **supply** the left ventricle.
- Atrial branches **supply** the left atrium.

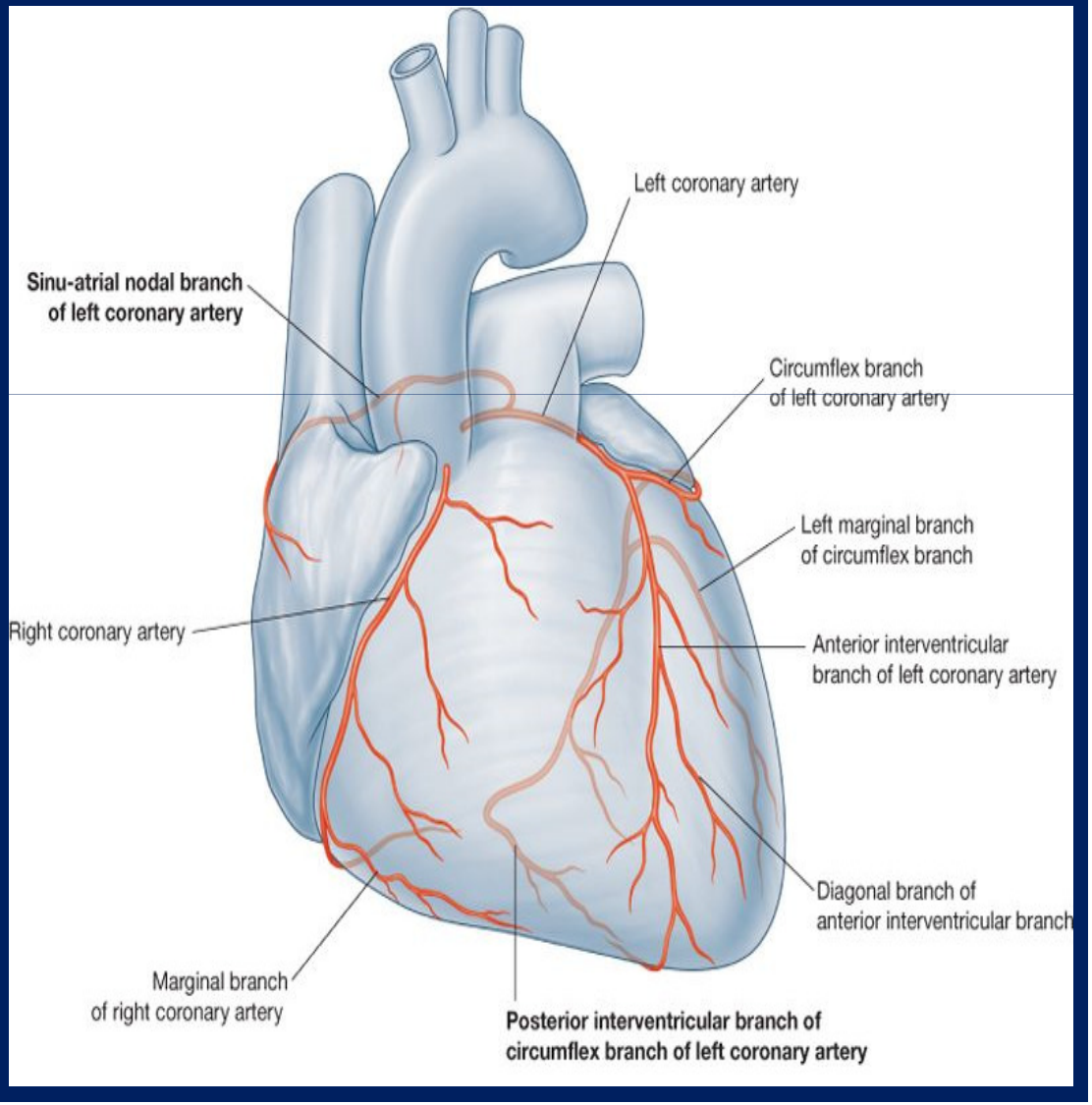

Venous Drainage of the Heart

- Most blood from the heart wall drains into the **right atrium** through the **coronary sinus**, which lies in the posterior part of the atrioventricular groove and is a continuation of the **great cardiac vein**.
- It **opens** into the **right atrium** to the left of the inferior vena cava.
- The **small** and **middle cardiac veins** are tributaries of the coronary sinus.
- The remainder of the blood is returned to right atrium by **anterior cardiac vein** &**small veins** that open directly into the heart chambers.

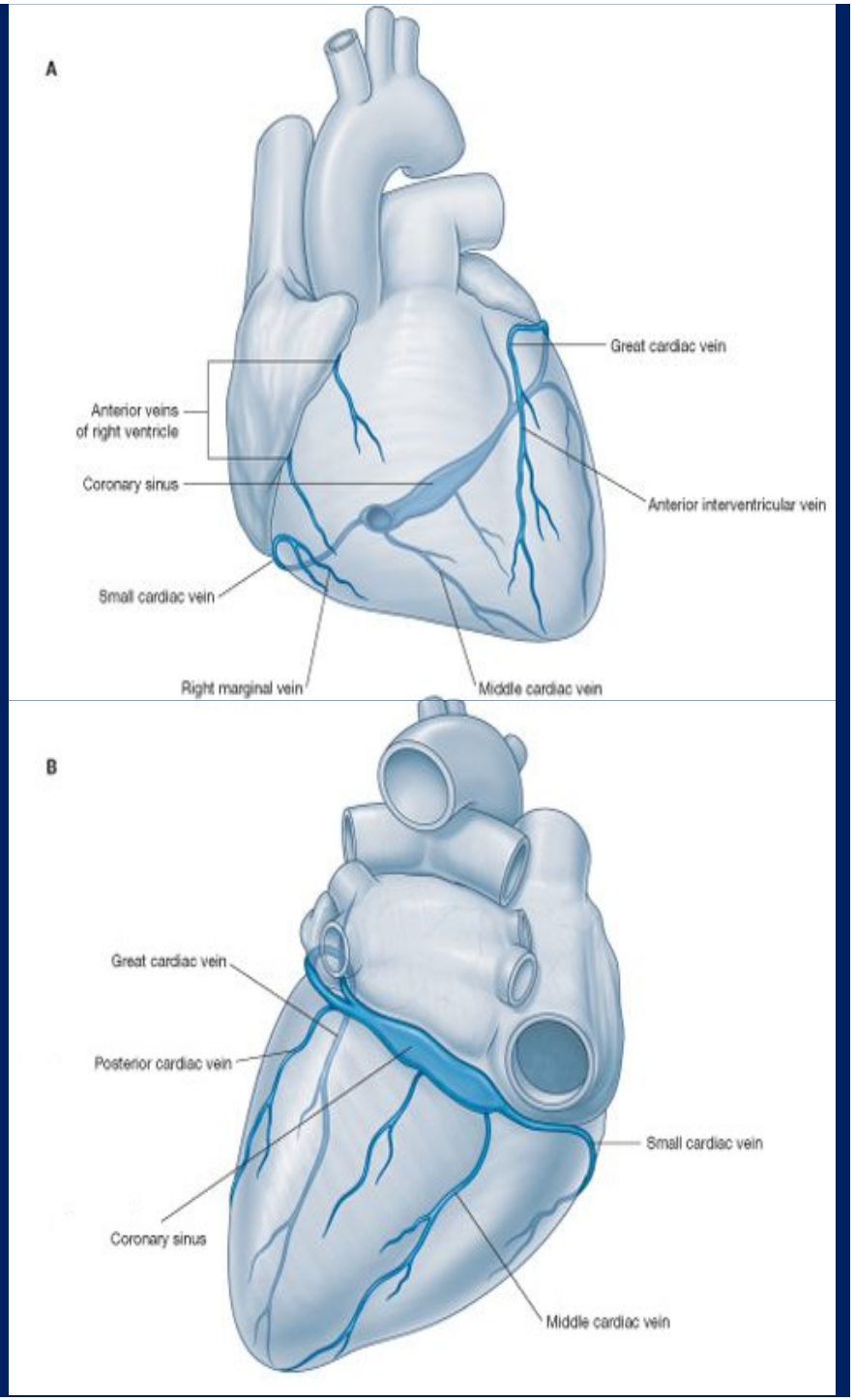

Nerve Supply of the Heart

- The heart is **innervated** by sympathetic and parasympathetic fibers of the **autonomic nervous** system via the **cardiac plexuses** situated **below** the arch of the aorta.
- The **sympathetic supply** arises from the cervical and upper thoracic portions of the **sympathetic trunks**, and the **parasympathetic supply** comes from the vagus nerves.
- The postganglionic sympathetic fibers terminate on the **sinuatrial** and **atrioventricular** nodes, on cardiac muscle fibers, and coronary arteries.

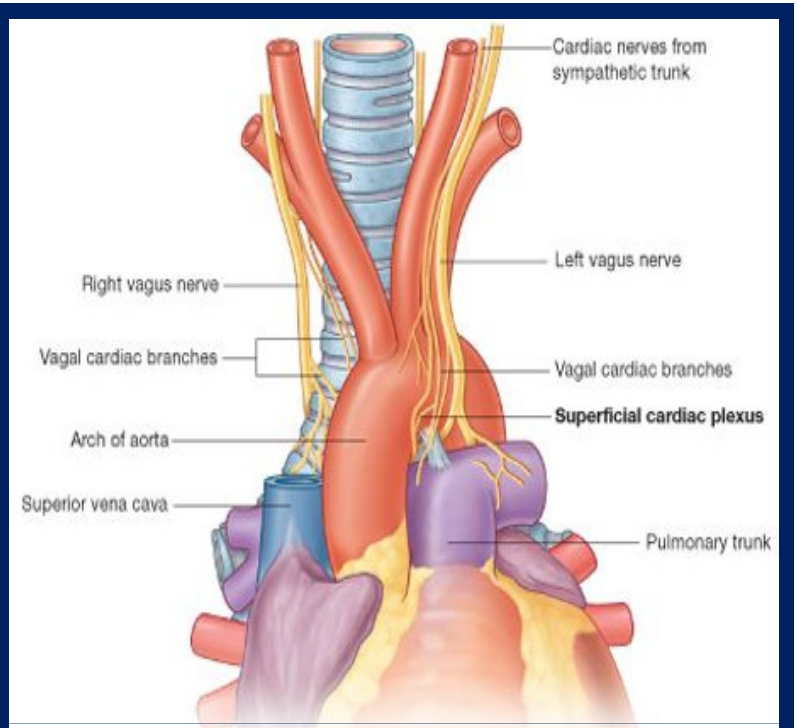

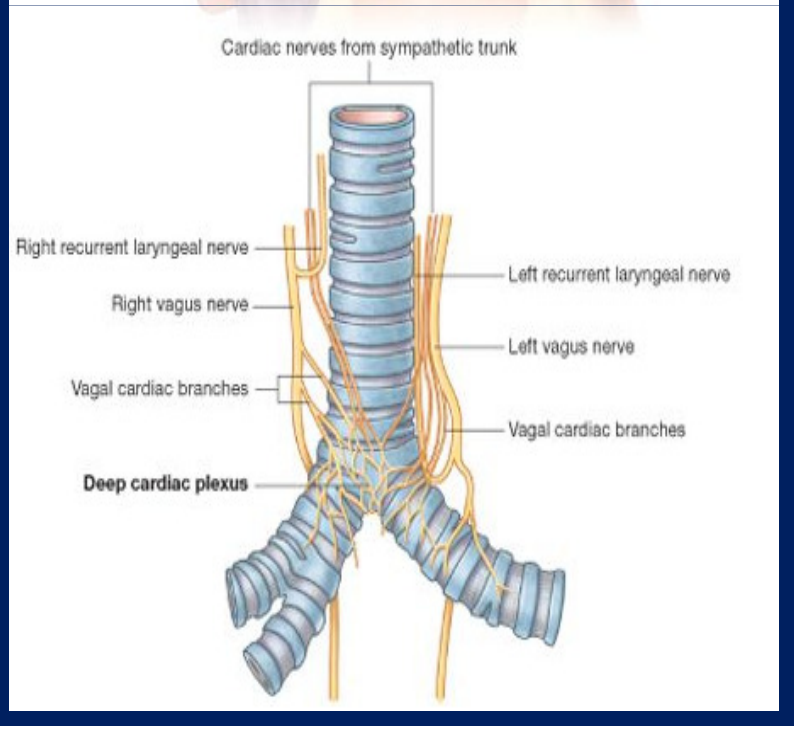

Large Veins of the Thorax

Brachiocephalic Veins

- The **right** brachiocephalic vein is formed at the root of the neck by the union of **right subclavian** and **right internal jugular veins**.
- The **left** brachiocephalic vein has a **similar origin**.
- It passes obliquely downward and to the right **behind** the **manubrium sterni** and in **front** of the large branches of **aortic arch**.
- It **joins** the right brachiocephalic vein to form the **superior vena cava**.

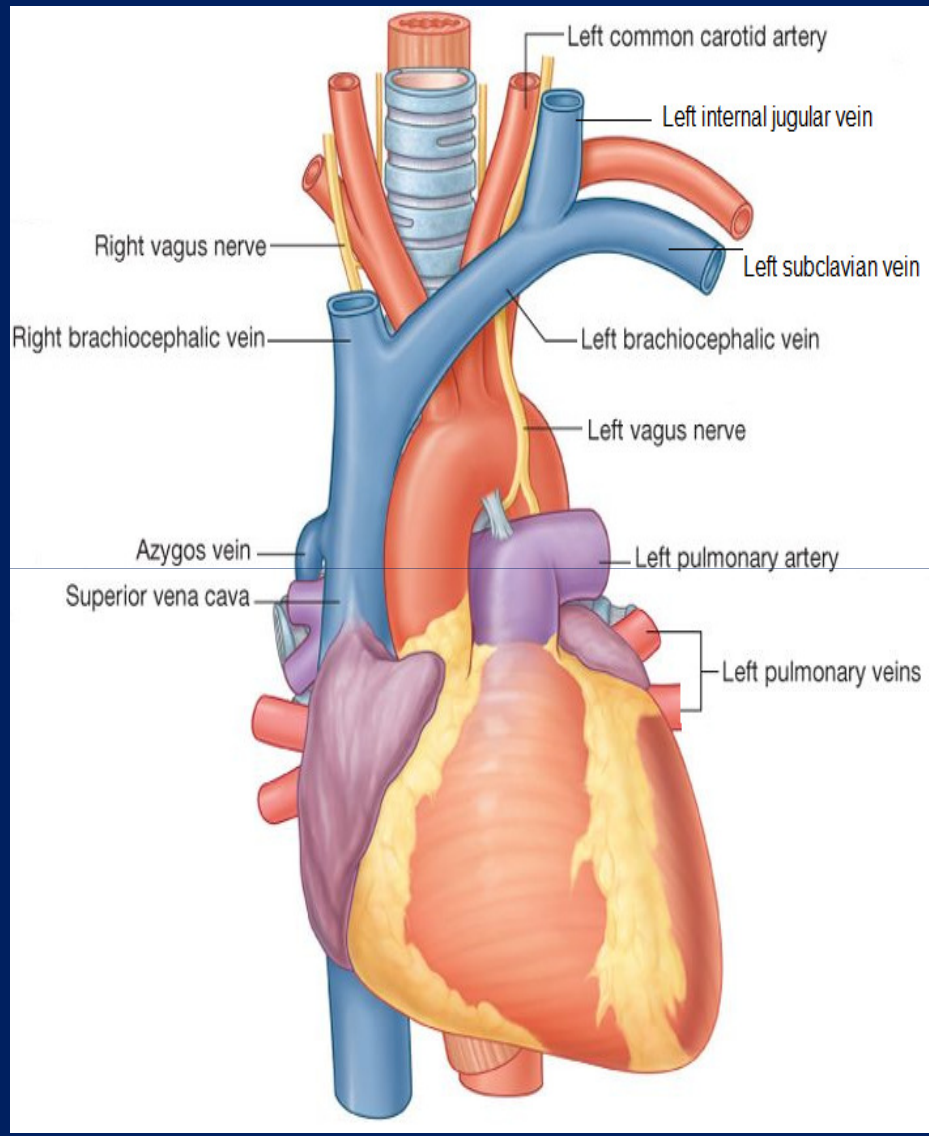

Superior Vena Cava

- The **superior vena cava** contains all the venous blood from the head and neck and **both** upper limbs and is formed by the **union** of the **two brachiocephalic veins**.
- It passes **downward** to end in the right atrium of the heart.
- The **vena azygos** joins the posterior aspect of the **superior vena cava** just before it enters the **pericardium**.

Azygos Veins

- The **azygos** veins consist of the main **azygos vein**, the **inferior hemiazygos vein**, and the **superior hemiazygos vein**.
- They drain blood from the **posterior** parts of intercostal spaces, posterior abdominal wall, the pericardium, the diaphragm, the bronchi, and the esophagus.
- The **inferior hemiazygos** vein is often formed by the **union** of the left ascending lumbar vein and the left subcostal vein.
- The **superior hemiazygos** vein is formed by the **union** of the fourth to the eighth intercostal veins .

Inferior Vena Cava

- The **inferior vena cava** pierces the central tendon of the diaphragm opposite the **eighth thoracic** vertebra and almost immediately **enters** the lowest part of the **right atrium**.

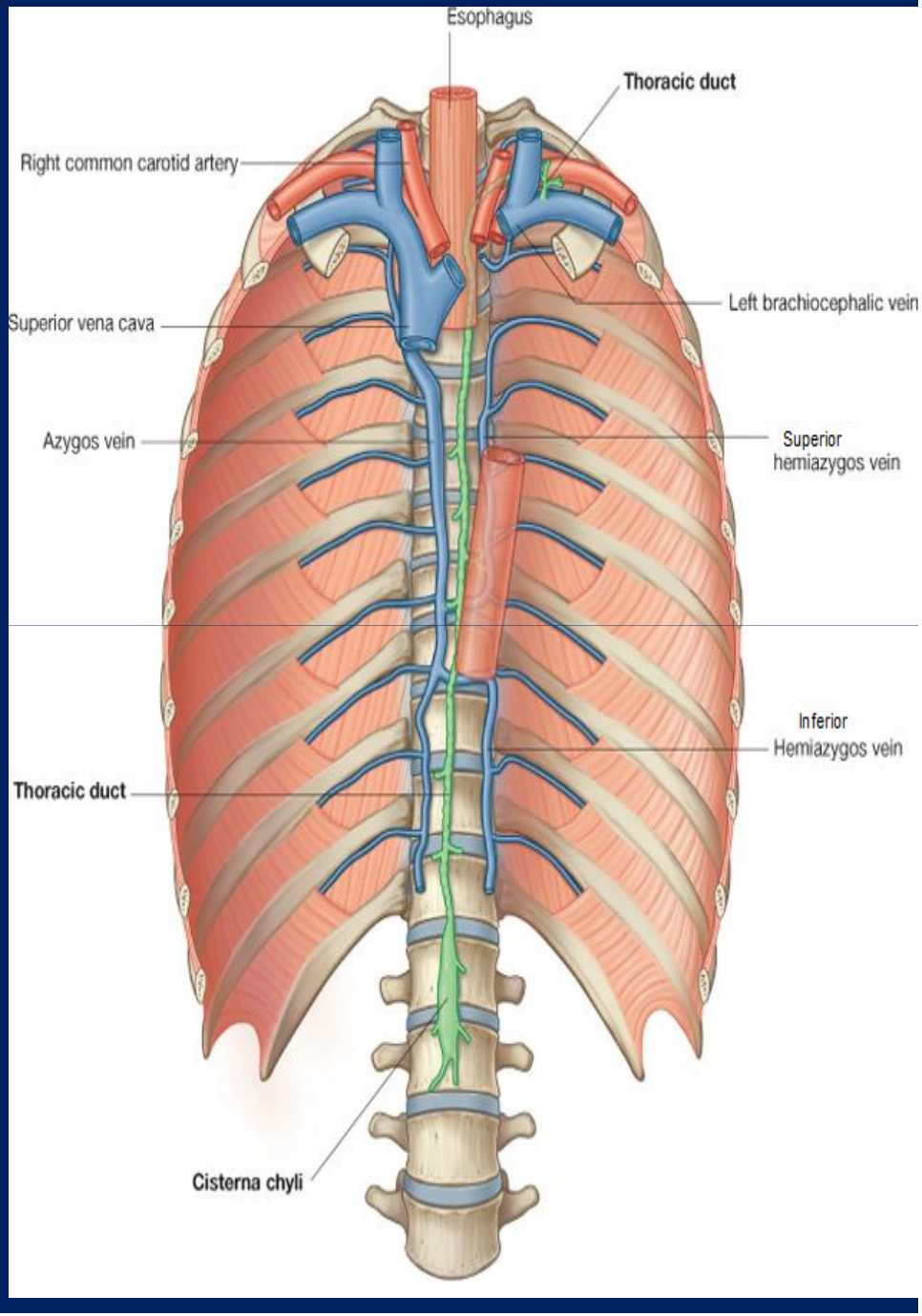

Large Arteries of the Thorax

Aorta

- The aorta is the **main arterial trunk** that delivers oxygenated blood from the left ventricle of the heart to the tissues of the body.
- It is **divided** for purposes of description into the following parts:
- ascending aorta,
- arch of the aorta,
- descending thoracic aorta,
- abdominal aorta.

Ascending Aorta

- The **ascending aorta begins** at the base of the left ventricle and runs upward and forward to come to lie **behind** the right half of the sternum at the level of the sternal angle, where it **becomes** continuous with the **arch of the aorta**.
- The ascending aorta lies **within** the fibrous pericardium and is **enclosed** with the pulmonary trunk in a sheath of serous pericardium.
- At its **root** it possesses **three bulges**, the sinuses of the aorta, one **behind** each aortic valve cusp.

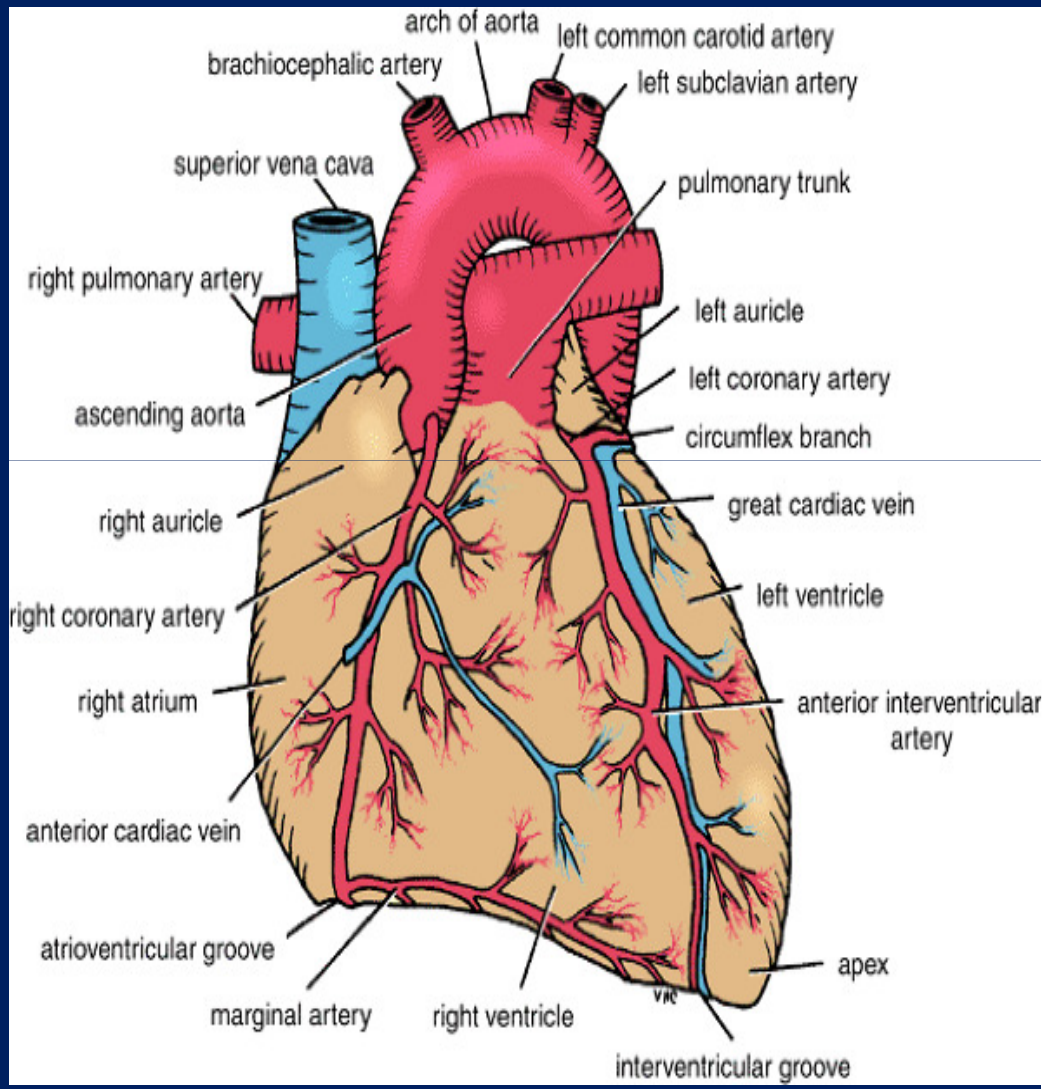

Branches

- The **right coronary artery** arises from the anterior aortic sinus, and **the left coronary artery** arises from the left posterior aortic sinus.

Arch of the Aorta

- The arch of the aorta is a continuation of the ascending aorta. It lies **behind** the manubrium sterni and arches upward, backward, and to the left in front of trachea.
- It then passes downward to the left of the trachea and, at the level of the sternal angle, becomes continuous with descending aorta

Branches

- The **brachiocephalic artery** arises from the convex surface of the **aortic arch**. It divides into right subclavian and right common carotid arteries behind right sternoclavicular J.
- The **left common carotid** artery arises from the convex surface of the **aortic arch** on the left side of the brachiocephalic artery.It enters the neck behind the left sternoclavicular joint.
- The **left subclavian artery** arises from the **aortic arch** behind left common carotid artery. It runs upward along the left side of the trachea and the esophagus to enter the root of the neck.

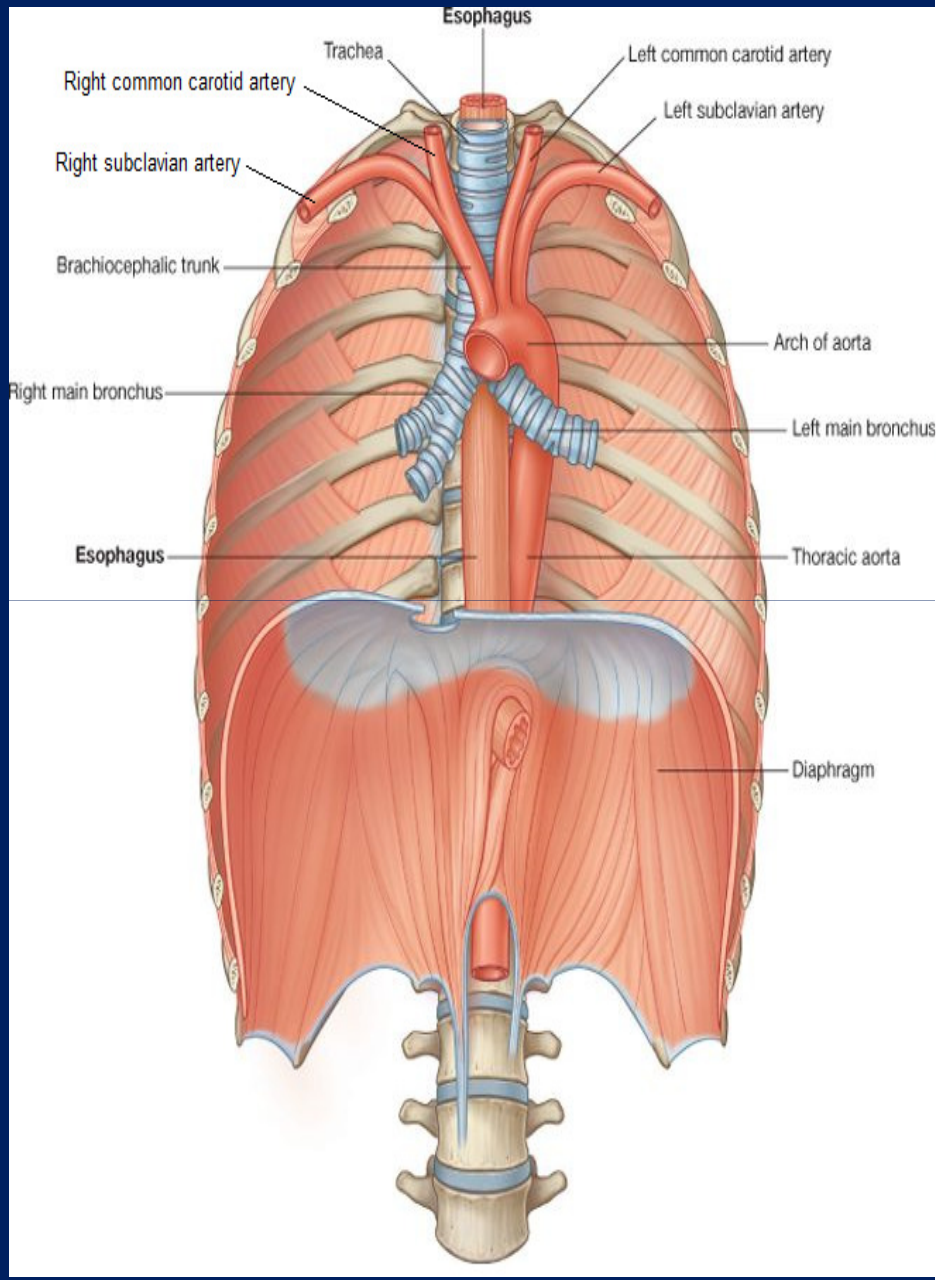

Descending Thoracic Aorta

- The descending thoracic aorta lies in posterior mediastinum and **begins** as a continuation of arch of aorta on left side(opposite sternal angle)
- At the **level** of the 12th thoracic vertebra, it passes **behind** the diaphragm (through the aortic opening) in the midline and becomes continuous with the abdominal aorta.

Branches

- **Posterior intercostal** arteries are given off to the lower **nine** intercostal spaces on each side.
- **Subcostal arteries** are given off on each side and run along the **lower border** of the 12th rib to enter the abdominal wall.
- **Pericardial**, **esophageal**, and **bronchial** arteries are small branches that are distributed to these organs.

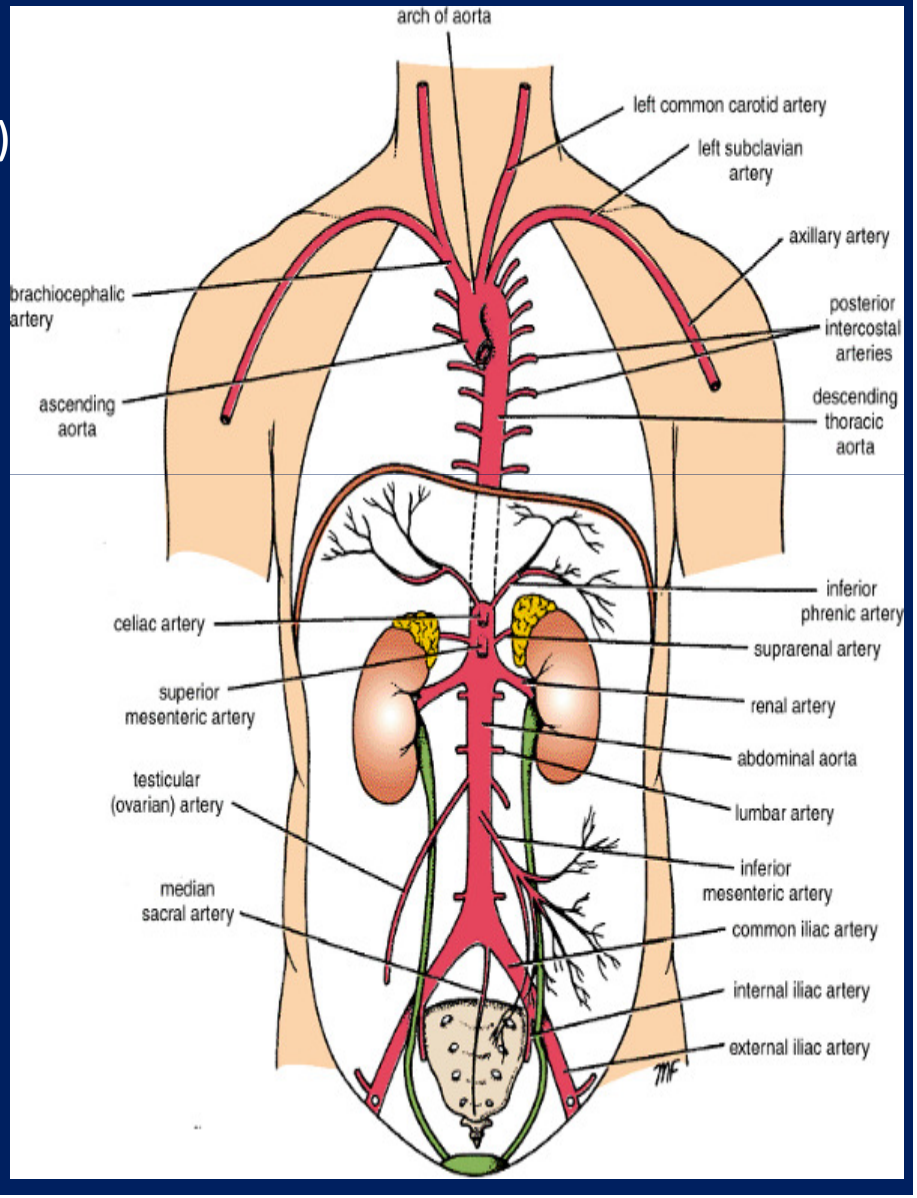

Pulmonary Trunk

- The **pulmonary trunk** conveys **deoxygenated** blood **from** right ventricle of heart to lungs.
- It is about **5 cm long** and terminates in the concavity of the aortic arch by **dividing** into right and left pulmonary arteries.
- **Together** with the ascending aorta, it is enclosed in the fibrous pericardium and a sheath of serous pericardium.

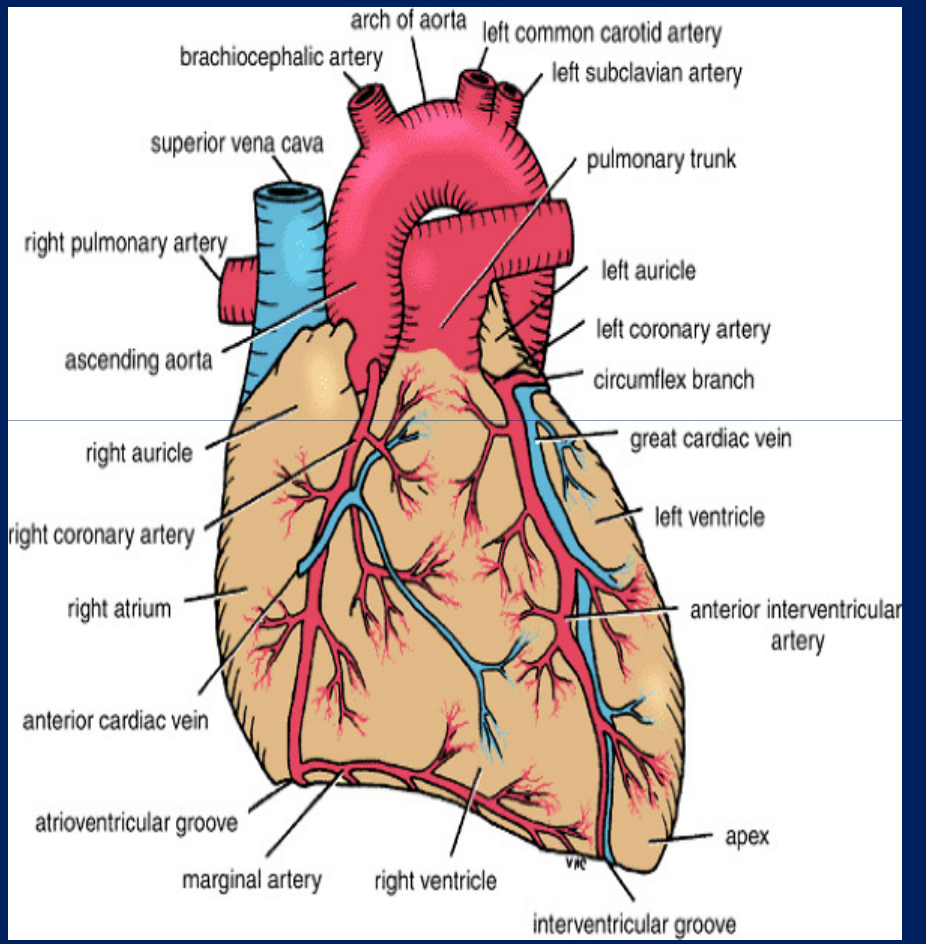

Branches

- The **right pulmonary artery** runs to the right behind the ascending aorta and superior vena cava to enter the root of the right lung.
- The **left pulmonary artery** runs to left in front of descending aorta to enter root of left lung.
- The **ligamentum arteriosum** is a fibrous band that connects the bifurcation of pulmonary trunk to lower concave surface of aortic arch.

Lymph Nodes and Vessels of the Thorax

Thoracic Wall

- The lymph vessels of the skin of the **anterior thoracic wall** drain to the **anterior axillary nodes**.
- The lymph vessels of the skin of the **posterior thoracic wall** drain to the **posterior axillary nodes**.
- The **deep** lymph vessels of the **anterior parts** of the intercostal spaces drain forward to **the internal thoracic nodes** along the internal thoracic blood vessels.
- From here, the lymph passes to the **thoracic duct** on the **left** side and the **bronchomediastinal** trunk on the **right** side.

Mediastinum

- They **drain** lymph from mediastinal structures and empty into the **bronchomediastinal trunks** and **thoracic duct**.

Thoracic Duct

- The **thoracic duct begins** below in the abdomen as a dilated sac, the **cisterna chyli**.
- It **ascends** through the aortic opening in the diaphragm, on the right side of the descending aorta.
- It enter the beginning of the left **brachiocephalic** vein.
- At the **root** of the **neck**, the thoracic duct receives the left jugular, subclavian, and bronchomediastinal lymph trunks, although they may drain directly into the adjacent large veins.
- The thoracic duct thus conveys to the blood all lymph from the lower limbs, pelvic cavity, abdominal cavity, left side of the thorax, and left side of the head, neck, and left arm.

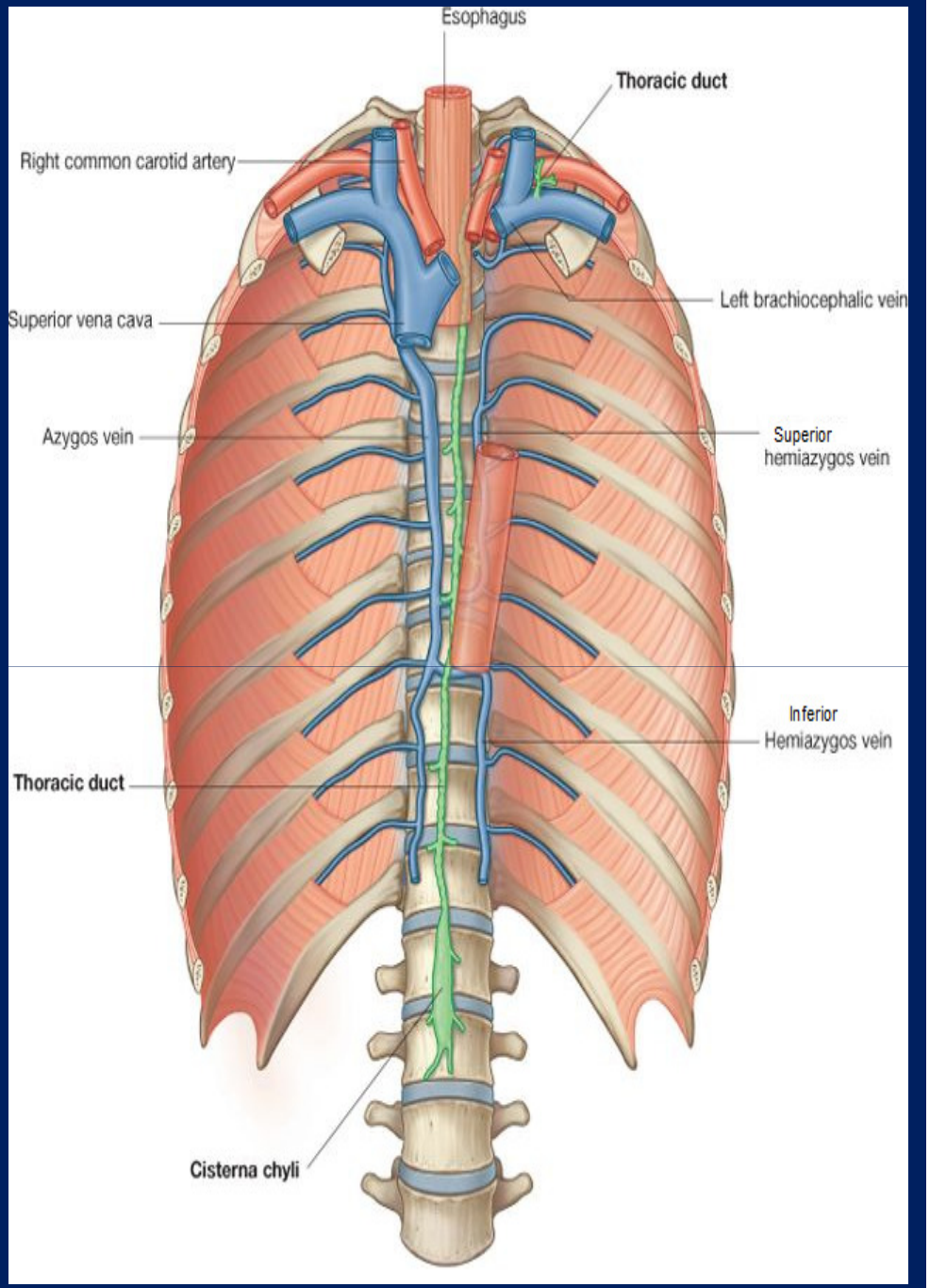

Right Lymphatic Duct

- The right jugular, subclavian, and bronchomediastinal trunks, which drain the **right** side of the head and neck, the right upper limb, and the **right** side of the thorax, respectively may join to **form** the **right lymphatic duct**.
- This common duct, **opens** into the beginning of the **right brachiocephalic vein**.

Nerves of the Thorax

Vagus Nerves

The right vagus nerve

- It **descends** in the **thorax** lateral to the trachea and medial to the terminal part of the azygos vein.
- It passes behind the **root** of the **right lung** and assists in the formation of the **pulmonary plexus**.
- On **leaving** the plexus, the vagus passes onto the posterior surface of the **esophagus** and takes part in the formation of the **esophageal plexus**.
- It then **passes** through the esophageal opening of the diaphragm behind the esophagus to reach the posterior surface of the **stomach**.

The left vagus nerve

- **descends** in the **thorax** between the left common carotid and the left subclavian arteries.
- The **vagus** then turns backward behind the **root** of **left lung** and assists in formation of the **pulmonary plexus**.
- It then **passes** onto the anterior surface of **esophagus** and takes part in formation of the **esophageal plexus**.
- It then passes through the esophageal opening.

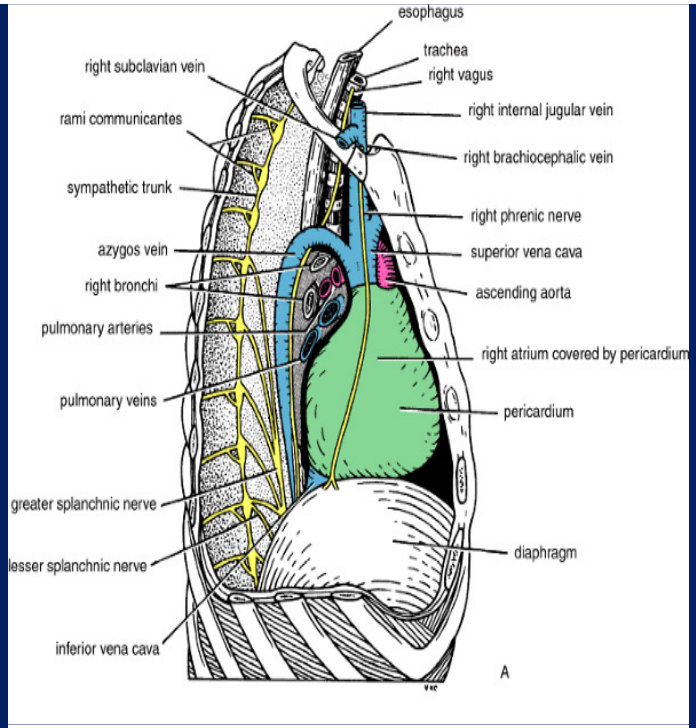

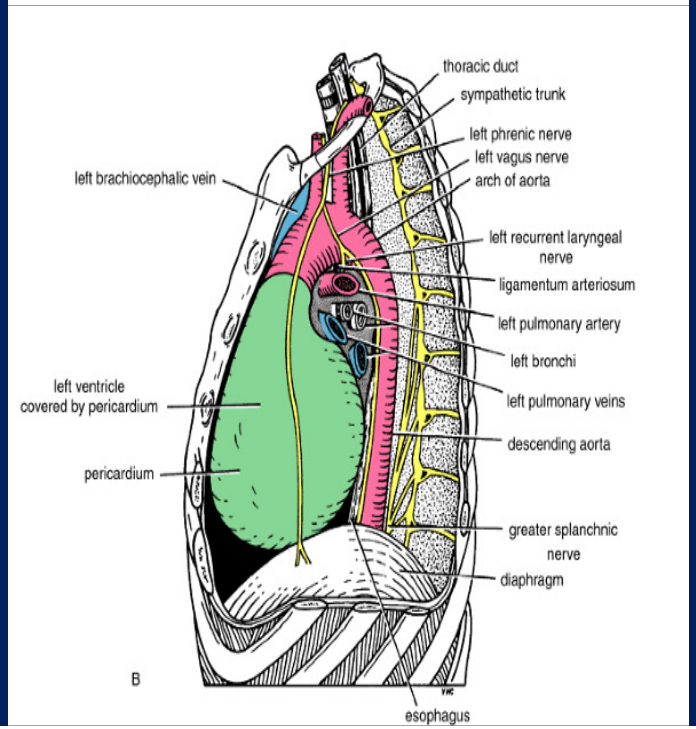

Branches of the Vagus Nerve

- **Both vagi supply** the lungs and esophagus. The right vagus gives off cardiac branches, and the left vagus gives origin to the left recurrent laryngeal nerve.

The right recurrent laryngeal nerve

- It arises from the right vagus in the neck and hooks around the **subclavian** artery and ascends **between** the trachea and esophagus.

The left recurrent laryngeal nerve

- arises from the left vagus trunk as the nerve crosses the **arch of the aorta**.
- It hooks around the ligamentum arteriosum and ascends in the groove **between** the trachea and the esophagus on the left side.
- It **supplies** all the muscles acting on the left vocal cord (except the cricothyroid muscle, a tensor of the cord, which is supplied by the external laryngeal branch of the vagus).

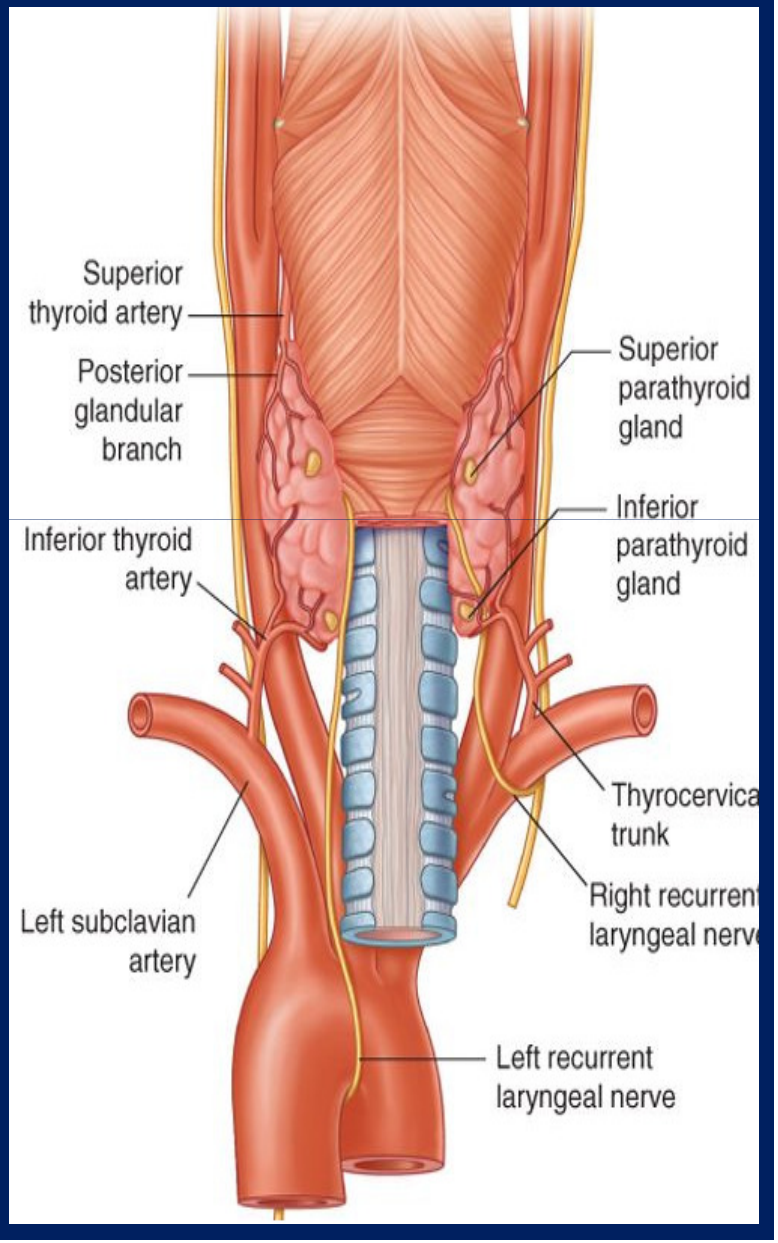

Phrenic Nerves

The phrenic nerves arise from the neck from the **anterior** rami of third, fourth, and fifth cervical nerves (3C,4C & C5).

The right phrenic nerve

- It **descends** in the **thorax** along the right side of the right brachiocephalic vein and the superior vena cava.
- It passes in front of the **root** of the **right lung** and runs along the right side of the pericardium, which separates the nerve from the **right atrium**.
- It then descends on the right side of the inferior vena cava to the **diaphragm**.
- Its terminal branches pass through the caval opening in the **diaphragm** to **supply** the **central part** of the **peritoneum** on its underaspect.

The left phrenic nerve

- It **descends** in **thorax** along the left side of left subclavian artery.
- It crosses the left side of the aortic arch and here crosses the left side of the left vagus nerve.
- It passes in front of the **root** of the **left lung** and then descends over the left surface of the pericardium, which separates the nerve from the **left ventricle**.

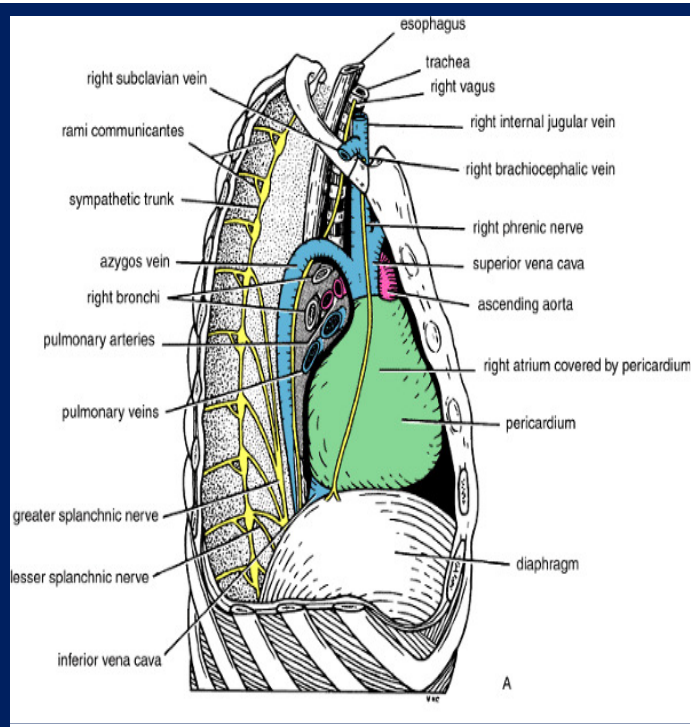

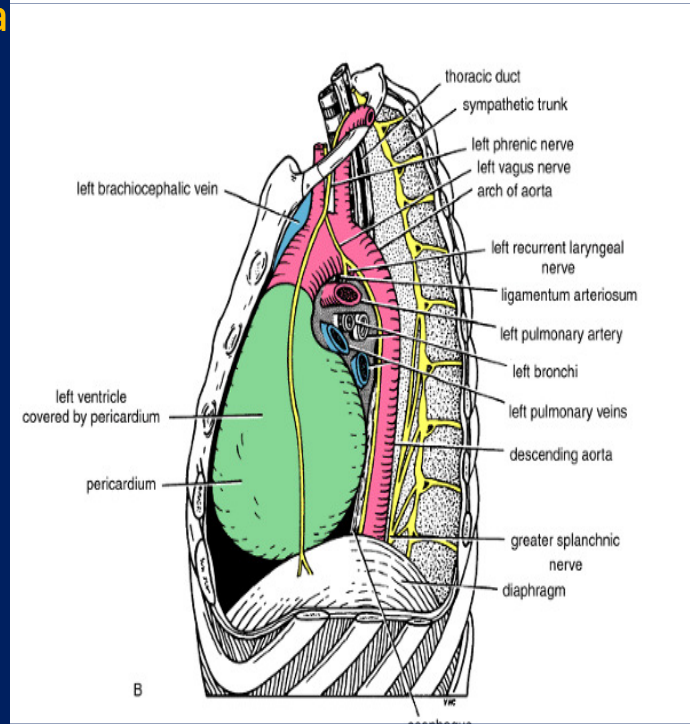

Thoracic Part of the Sympathetic Trunk

- The **thoracic part** of the sympathetic trunk is continuous **above** with the **cervical** and **below** with the **lumbar parts** of the sympathetic trunk.
- It is the most **laterally** placed structure in **mediastinum** and runs downward on the heads of the ribs. It **leaves** the thorax on the side of the body of the 12th thoracic vertebra by passing behind the **medial arcuate ligament**.

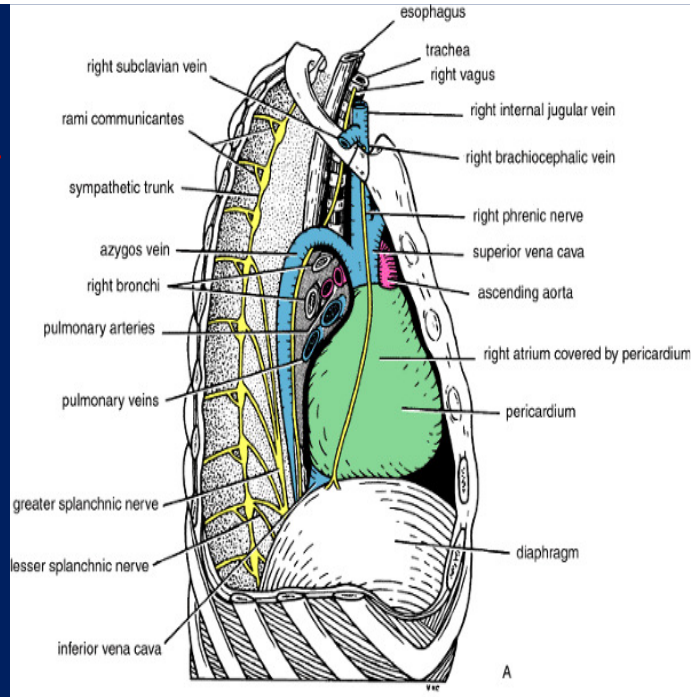

Branches

- **Gray rami communicantes** go to all the **thoracic spinal nerves**.
- **The first five ganglia** give **postganglionic fibers** to the **heart**, **aorta**, **lungs**, and **esophagus**.
- **The lower eight ganglia** mainly give **preganglionic fibers**, which are grouped together to form the **splanchnic nerves** and **supply** the **abdominal viscera**

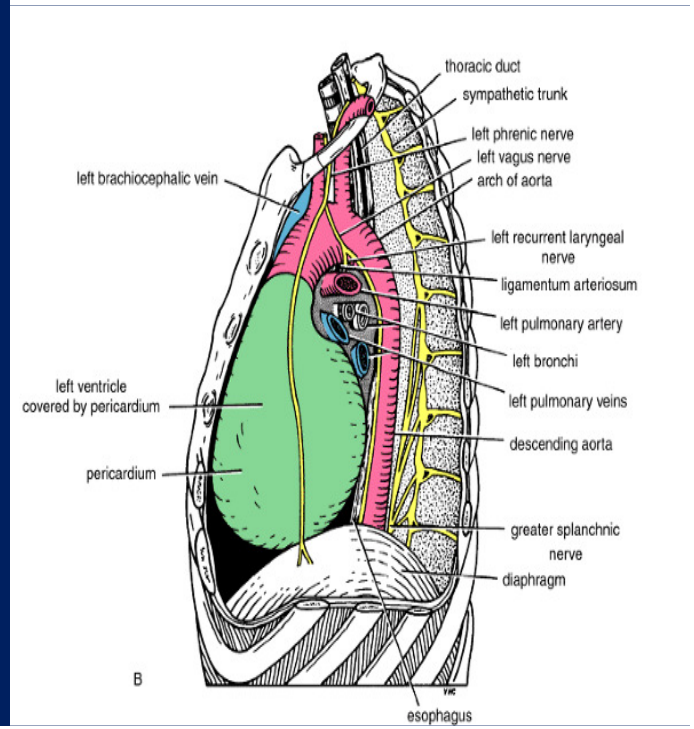

Esophagus

- The **esophagus** In the **thorax** passes downward and to the left through the **superior** and then **posterior mediastinum**.
- At the **level** of the sternal angle, the aortic arch pushes the **esophagus** over to **midline**.

The relations of the thoracic part of the esophagus

- **Anteriorly**: The **trachea** and the **left recurrent laryngeal**
- **Posteriorly**: The **bodies** of the **thoracic vertebrae**; the **thoracic duct**; the **azygos veins**; the **right posterior intercostal** arteries; and at its lower end the **descending thoracic aorta**.
- **Right side**: The **mediastinal pleura** and the terminal part of the **azygos vein**.
- **Left side**: The **left subclavian** artery, the **aortic arch**, **thoracic duct**, and **mediastinal pleura**.

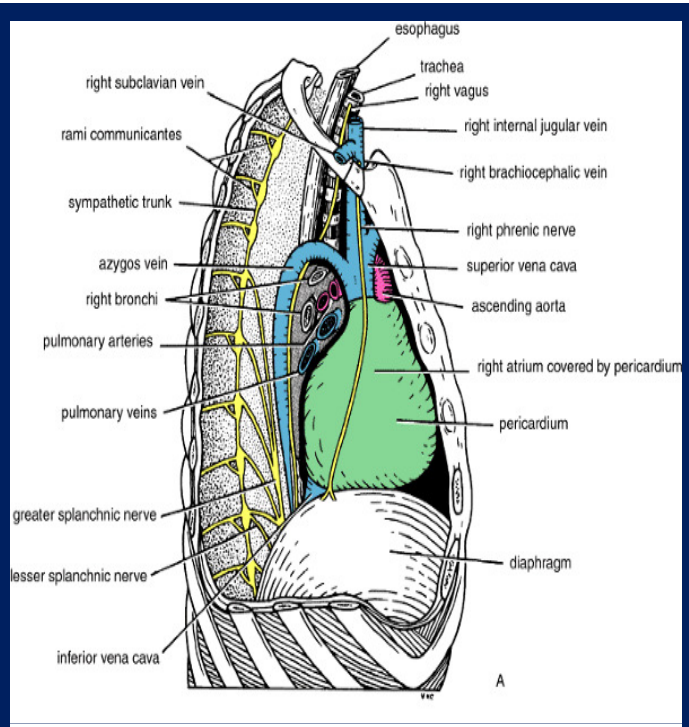

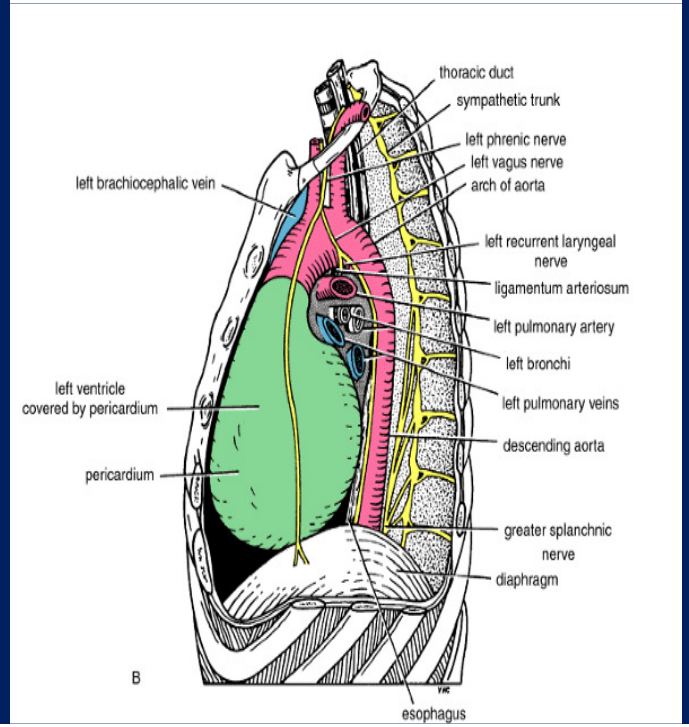

Blood Supply of the Esophagus

- The **upper third** of the esophagus is **supplied** by the **inferior thyroid artery**, the **middle third** by branches from the **descending thoracic aorta**, and the **lower third** by branches from the **left gastric artery**.
- The **veins** from the **upper third** drain into the **inferior thyroid veins**, from the **middle third** into the **azygos veins**, and from the **lower third** into the **left gastric vein**, a tributary of the **portal vein**.

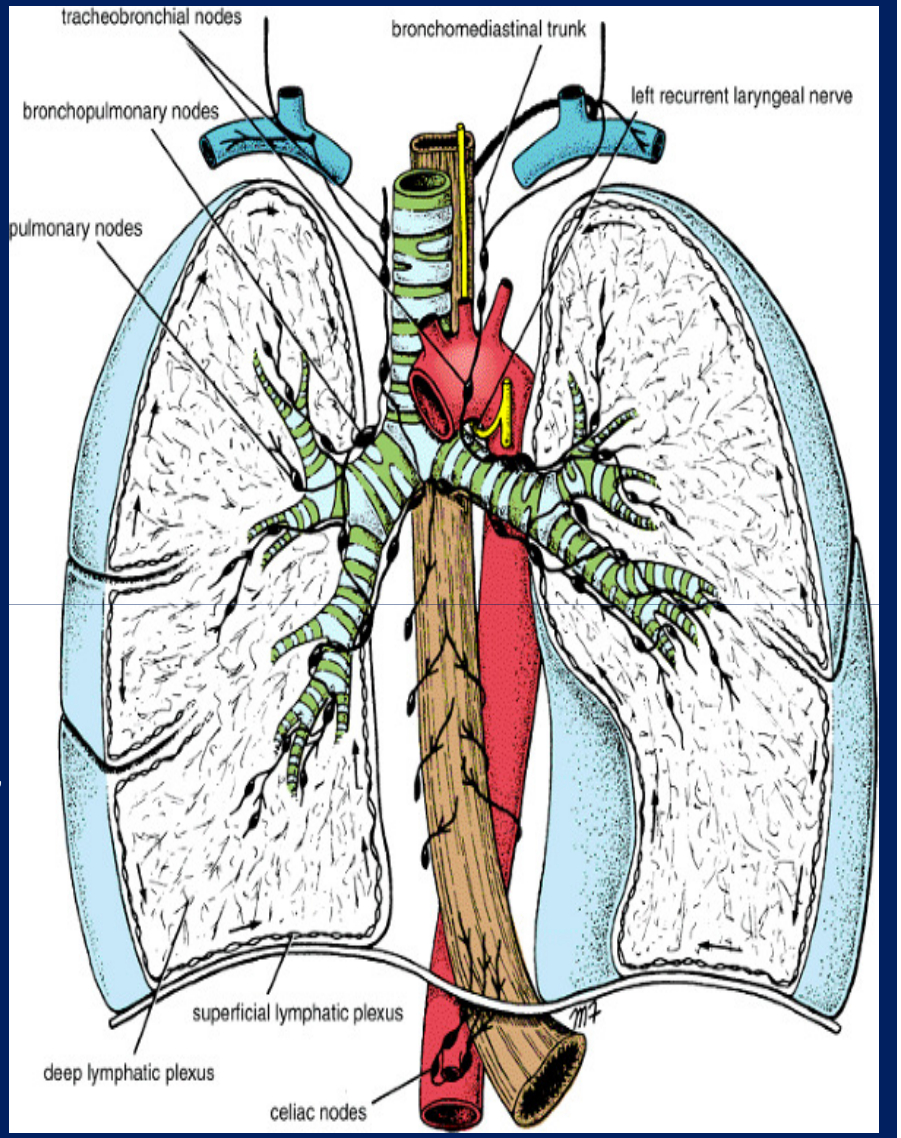

Lymph Drainage of the Esophagus

- Lymph vessels from the **upper third** of the esophagus drain into the **deep cervical nodes**, from the **middle third** into the **superior** and **posterior mediastinal nodes**, and from the **lower third** into nodes along the **left gastric** blood vessels and the **celiac nodes** .

Nerve Supply of the Esophagus

- The esophagus is supplied by **parasympathetic** and **sympathetic** (**vagi** and **sympathetic trunks**.In the **lower part** esophagus is surrounded by esophageal plexus.

Thymus

- The **thymus** is a flattened, bilobed structure **lying** between the sternum and pericardium in **anterior mediastinum**.
- At which time it may extend up through the superior mediastinum in **front** of the great vessels into the root of the neck.
- It has a **pink**, **lobulated** appearance and is the site for development of T (thymic) lymphocytes.

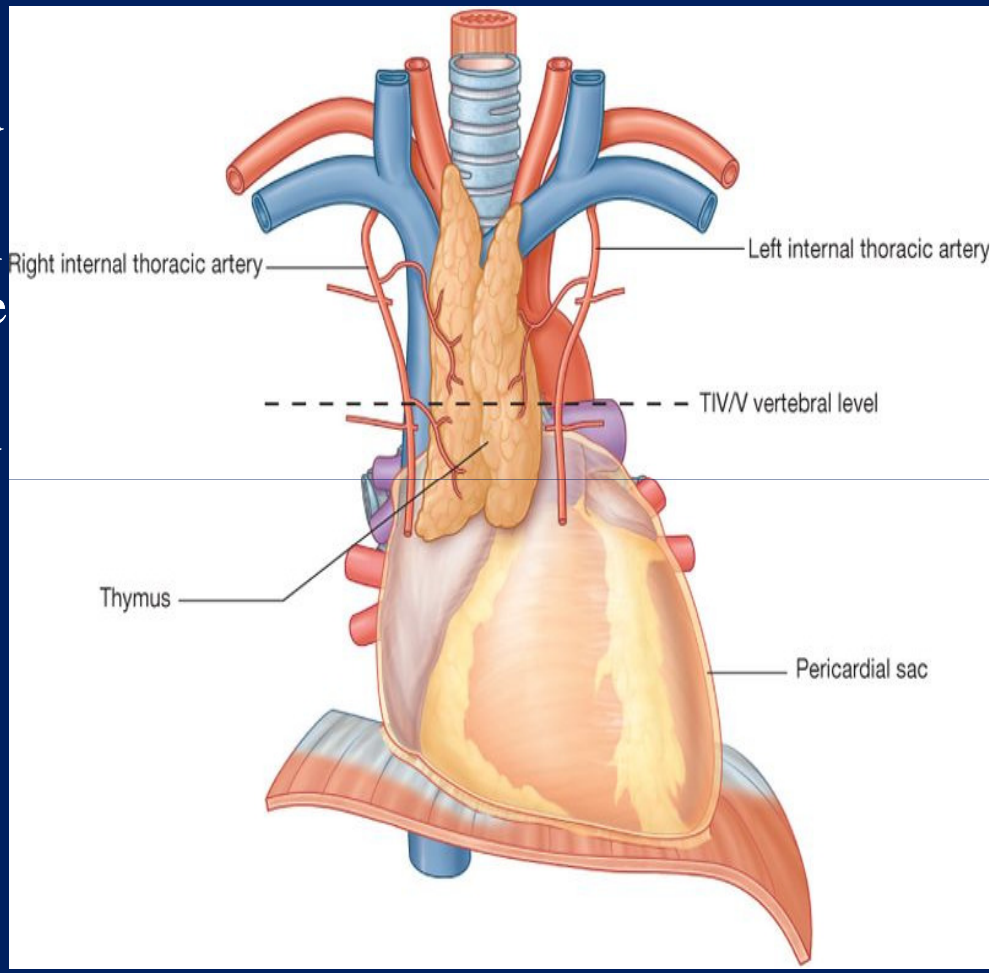

Blood Supply

- The blood supply of the thymus is from the **inferior thyroid** and **internal thoracic arteries**.

Thank You & Good Luck