ORTHOPEDIC

Lec. 1

Dr.hasan abdulhadi mohammed

Orthopaedics: *The term was coined by Nicolas Andry. Orthos means straight and paedics means child so orthopaedics means Straight child.*
Definition of orthopaedics: *the branch of surgery that deals with the prevention or correction of injuries or disorders of the skeletal system and associated muscles, joints and ligaments.*

History taking in Orthopaedic

The importance in taking history in musculoskeletal disorders is three folds:

1. Setting agenda.
2. History forv
3. History for surgery.

***Setting agenda*:**
Allow the patient to list the problems that he complains, with using of open questions. Problems can be divided in to:

1. ***Pain:*** is the main presenting symptoms it is either localized or referred. We have:
   - Grade 0: No pain even when asked about.
   - Grade I (mild): easily be ignored.
   - Grade II ((moderate)): Cannot be ignored, interfere with function & need treatment from time to time.
   - Grade III (((severe))): Present most of the time and need constant attention.
   - Grade IV ((((excruciating)))): Totally incapacitating pain.

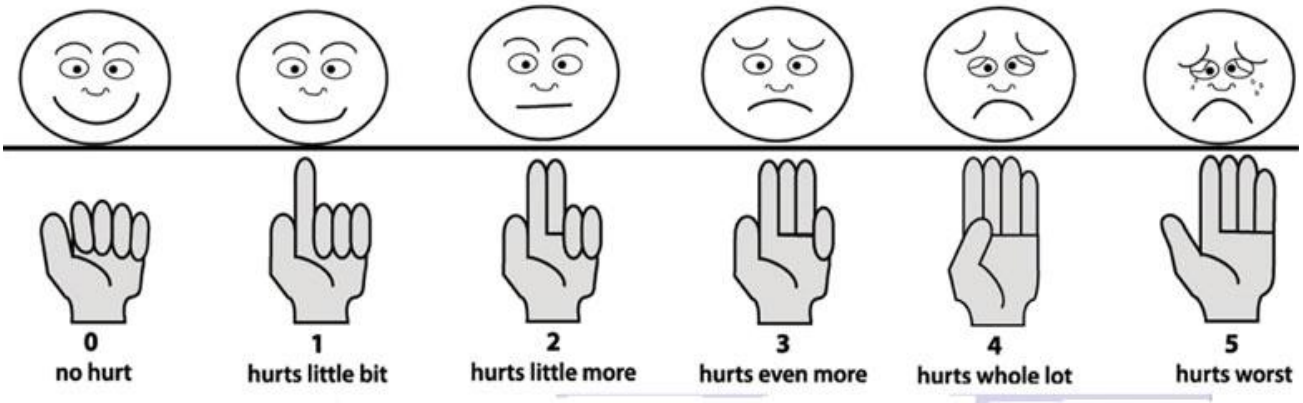

2. ***Dysfunction:*** due to pain, stiffness, weakness, swelling, instability or even locking. Firstly the patient allowed describing in his or her own word; like inability to hang clothes on the washing line. Later on these will be translated in to a clinical diagnosis.
3. ***Deformity:*** it is the presenting symptoms if it: Cause pain, Unsightly, Loss of function & Progressive.

***History for diagnosis*:**
Use direct questions to confirm or exclude a differential diagnosis derived from the history for agenda & should be cover:

- *Onset:* how the problem was first noticed?
  1. Acute:
     - Extrinsic: due to direct trauma (external trauma e.g. hit by stick).

- ❖ Intrinsic: due to indirect response to load (internal trauma e.g. anterior cruciate ligament tear in twisting injury.

2. Chronic: the problem is gradually appearing & usually not associated with trauma (e.g. OA knee).
3. Acute-on-Chronic: chronic event superimposed by an acute onset (e.g. recurrent joint effusion in meniscal injury).

- *Association:* we should ask the patient if there is an association between an event & onset of illness, which does not mean that this is correct. You may need to seek association, which had not occurred to the patient.
- *Development:* Is the natural history of the problem. If the condition spontaneously resolves, then return, the cause of the recurrence need to be sought.
- *Nature:* type of the pain may give clue to origin e.g. throbbing pain associated with sweats & chill may be infection, deep boring pain which awake the patient from sleep may be tumor.

History for surgery (co-morbidity):
Is only needed if the surgery will be the treatment option this can be divided in to:

1. Identification of conditions, which can increase the risk of the anesthesia & of surgery morbidity.
2. Determining whether those conditions have been brought into the best possible control to minimize the risk.

Factors in the history indicate high risk patient are:

1. Patient had problem with previous anesthesia.
2. History of cardiac or circulatory problem e.g. IHD, HT, TIA,.
3. History of respiratory problem e.g. asthma, chronic bronchitis, pneumonia.
4. History of metabolic problem e.g. DM, steroid therapy.
5. History of urinary problem e.g. RF, UTI, BPH.

Physical examination in Orthopedic

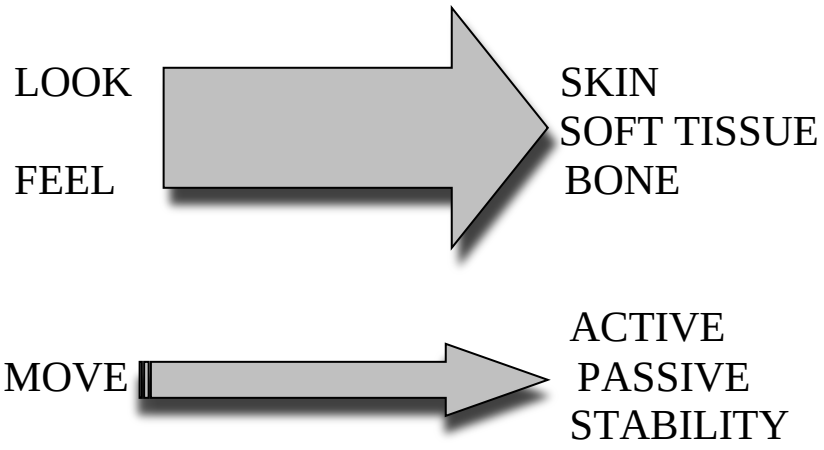

Look: firstly you should expose enough of the patient body, this means exposure of the whole part or at least one joint above & one joint bellow the area examined, the opposite normal side should also be exposed for comparison.
NB: *while looking it may be better to put your hands behind your back to remind you to look first, & to show the examiner what you are doing.*

- Skin: Color
  Bruising & wounds
  Scars

Sweating (loss indicate N. injury).

- Soft tissue: Swelling.
  Wasting.

- Bone: Shape of the skeleton.
  Deformity (unusual angles or unusual joint position).

Feel: feel the bone & joint margins gently for area of tenderness, steps & lumps. Watch the patient face and remember anatomy of the area examined.

- Skin: Temperature.
  Sensation.

- Soft tissue: Tenderness.
  Swelling & effusion.
  Distal circulation.

- Bone: Bone outlines.
  Joint margins.

Move:

- ***Active movements*:** the patient should move their own joints within the limits of pain. (Ask the patient to do what movement you do).
- ***Passive movements*:** you move the joint & the patient relaxed not move beyond the active limit & also watch the patient face.
- ***Stability*:** 2 types:
  1. Dynamic: provided by muscle power. Dynamic stability measure the forces that the patient can develop by showing the movement, then asking them to repeat it while you try to stop them. For each movement remember the muscles & nerve supply.
  2. Static stability: provided by ligaments & intact joint surfaces. The joint should be gently stress in each direction while watch the patient face & try not to hurt the patient, which will lead to muscle spasm & give false results.

Neurological examination:

- Motor functions Tone
  Power
  Reflexes

- Sensory functions

Investigations in Orthopedic

Diagnosing Imaging:

I. *Plain film radiography (x-ray)*: Radiographic images are produced by the attenuation of the X-ray as they pass through tissues before striking an appropriately sensitized plate or film. The more dense & impenetrable the tissue, the greater the attenuation & therefore the more white, the image in the film (metal & bone are white).

- *How to read a radiograph film:*
  - **a.** Patient: name, age, date, part & side (R or L) i.e. read what is written on the film.
  - **b.** Soft tissue: shape, density.
  - **c.** Bone: shape, cortical continuity, density.
  - **d.** Joint: shape, density, space, loose bodies.
- *X-ray film should follow the rule of (2 x 6):*
  - **a.** 2 views (AP & Lat.).

b. 2 joints (one above, one below).
c. 2 bones (leg, forearm).
d. 2 limbs (for comparison).
e. 2 injuries (calcanium & spine).
f. 2 occasions (fractured scaphoid).

II. X-ray using contrast media: Substances that alter x-ray attenuation characteristic can be used to produce images, which contrast with those of the normal tissue. The contrast media used in orthopedics are mostly iodine-based liquid which can be injected into:

- Sinuses---------- Sinography.
- Joint ---------- Arthrography.
- Spinal theca ---------- Myelography.

Air & gas also can be injected into the joint to produce negative image outline the joint cavity.

III. Tomography: two tubes move in two different directions to give a picture for certain depth, it is not important due to the presence of C.T. scan & MRI.

IV. CT scan: like simple tomography, CT scan produces cutting image through the selected tissue plane but much greater resolution & the images are trans axial (like transverse anatomical sections). Using contrast studies e.g. intravascular, intra-articular, intrathecal can extend the value of CT scan. CT scan guided procedures (e.g. tumor biopsy) one disadvantage of CT scan is relatively high radiation exposure.

V. MRI: It relies up on radiofrequency emissions from atoms & molecules in tissue exposed to a static magnetic field. All atomic nuclei with an odd number of protons (e.g. hydrogen) possess the property of magnetic resonance. The hydrogen ion is the one currently employed for MR imaging because it is abundant in human tissue & so easily detectable.

The intensity of the MR signal depends partly on the density of the H2 ions in the tissue scanned & partly on the spin characteristic & relaxation rate following proton excitation. Tissue contain abundant H2 (fat, cancellous bone & marrow) emit high signal intensity & produce the brightest image; those containing little H2 ions (e.g. cortical bone, ligament, tendon, air) appear black. Intermediate H2 ion content (e.g. cartilage, muscle, spinal canal) appears grey.

VI. U/S: it is of little value in orthopaedic problems except in:

1. Detecting intraarticular fluid to diagnose synovial effusion or to monitor the progress of irritable hip.
2. Recently used as a mean of screening & diagnosis DDH.

VII. Radionuclide imaging (radioisotope scanning): Photon emission by radionuclide taken up in specific tissue can be recorded by either a simple rectilinear scanner or a gamma camera, to produce an image, which reflects current activity in that tissue or organ. The ideal isotope for this purpose is the Technetium-99m. (^{99m}Tc). When Technetium-99m is linked to a bone-seeking-phosphate compound it is selectively concentrated in the skeletal tissue. Other isotopes like Gallium 67 (^{67}Ga), Indium-111-lablled leukocytes also can be used.

Synovial Fluid Analysis:

The joint should be aspirated under strict aseptic condition. Even a small quantity of fluid (less than 0.5ml) can be used for diagnostic analysis.

Indications:

1. Acute swelling after injury (blood or fluid).
2. Suspected infection.
3. Acute synovitis in adults.
4. Chronic synovitis.

Suspected condition	***Appearance***	***Viscosity***	***WBC***	***Crystals***	***Biochemistry***	***Bacteria***
Normal	Clear yellow	High	Few	-	Same plasma	-
Septic	Purulent	Low	+	-	Glu. Low	+

arthritis						
TB arthritis	Turbid	Low	+	-	Glu. Low	+
Rheu. arthritis	Cloudy	Low	+ +	-	-	-
Gout	Cloudy	Normal	+ +	Urate	-	-
Pseudogout	Cloudy	Normal	+	Pyrophosphate	-	-
OA	Clear yellow	High	Few	Often+	-	-

Bone biopsy:
It means surgical removal of the lesion or part of it and send for histopathological study. It is of two types:

1. Closed Biopsy: using a needle or trephine of adequate size to take sample of tissue. Can be done under CT guide in difficult location.
2. Open Biopsy: it is an operation used to expose the lesion & take part or whole lesion as a sample includes incisional biopsy (taken part of the tissue), & excisional biopsy (take whole lesion).

Arthroscopy:
Using an instrument, which is basically a rigid telescope, fitted with fibreoptic illumination. Tube diameter rang from 2mm (small joint) to 5mm (large joint). it carries a lens system that gives a magnified image.
The eyepiece allows direct viewing by the arthroscopist but better to fit a small camera, which produces a picture of the joint interior on the TV monitor. The procedure done under GA with muscle relaxation it is either:

1. Diagnostic Arthroscopy
2. Therapeutic Arthroscopy
3. Both.

Electrodiagnosis:
It means study nerve & muscle function by various electrical methods. It is of two types:

1. ***Nerve Conductive Study (NCS):*** these study the motor & sensory function of the nerve.
   - **Motor nerve conduction:** electrical stimulation of a motor nerve normally produces contraction of the muscles supplied by that nerve. The stimulus is applied to the skin over the nerve & a concentric needle electrode inserted into the muscle measures the motor unit response. The electrical discharge or motor action potential (MAP) is amplified & recorded on an oscilloscope (normal 50 – 60 m/sec.).
   - **Sensory nerve conduction:** if a sensory nerve is stimulated distally the sensory potential (SAP) can be recorded proximally. By measuring the distance between stimulating & recording electrodes, & the time lapse between stimulus & response, the sensory nerve velocity can be calculated.

NB. Conduction velocity is slowed in peripheral N damage or compression & sensory NC is affected before motor NC.

2. ***Electromyography (EMG):*** it does not involve electrical stimulation instead; a concentric needle in the muscle is used to record motor unit activity at rest & when attempts are made to contract the muscle.
   - *At rest* normally there is no electrical activity, while in partial or complete denervation there are spontaneous discharges, which are due to increase sensitivity of the de-nervated muscles to circulating catecholamine.
   - *At voluntary* muscle contraction characteristic oscilloscope pattern appear, number, shape, amplitude & duration of these action potential (AP) is recorded.

In myopathic disease --------- AP smaller.

In neuropathic disease -------- AP large & extended.



Operation Planning: require good history, examination, & investigation to prepare the optimal condition for orthopaedic operation.

Equipment: minimal require

1. Drill ---- for boring holes in the bone.
2. Osteotome---- for cutting cancellous bone.
3. Saws---- for cutting cortical bone.
4. Chisel---- for shaping bone
5. Gouges---- for removing bone.
6. Plate, screws & screwdrivers---- for fixing bone.

Bloodless field: by applying tourniquet to limb many operations can be done accurately & rapidly.

- Tourniquet of three types: Electronic, pneumatic & rubber.
- Cuff width should be as wide as the diameter of the limb.
- Exsanguination means draining of the blood from the limb before applying tourniquet by either:
    1. Elevation the limb for 5min.
    2. Sequential squeezing of the limb in proximal direction.
    3. Wrapping rubber bandage from distal to proximal.
- Tourniquet Pressure:
    - 80 – 100 mmHg above systolic BP for UL.
    - 150 mmHg above systolic BP for LL.
- Tourniquet time: maximum (2hr for UL 3hr for LL)



Operations on the bones:

Osteotomy: it is used to:

1. Correct deformity.
2. Change the shape of the bone.
3. Relieve pain in arthritis by redirecting the load trajectories.

Preoperative planning essential to determine:

1. The exact site of bone cutting.
2. The amount of correction required.
3. The type of osteotomy (closed or open wedge, V-shape, dome shape).
4. The method of fixation.

Complication of osteotomy:

1. General complications e.g. cardio-respiratory complications, DVT.
2. Undercorrection & over correction.
3. Nerve injury due to stretching.
4. Compartment syndrome.
5. Nonunion.

Bone Graft: mean taking part of bone from one site (donor) & putting it in new site (host bed).

- *The graft acts as:*
  1. **Osteoinductive:** stimulation of the osteoprogenitor cells in the host bed by the bone morphogenic protein in the graft matrix.
  2. **Osteoconductive:** provide linkage across defects & a scaffold upon which new bone can form.
  3. **Osteogenic:** through some surviving cells on the surface of the graft.
- *Types of bone graft:* cancellous, cortical, corticocancellous, & vascularized graft.
- *Sources:*
  1. **Autograft:** bone moved from one place to other in the same individual. It is immunological acceptable but give limited amount.
  2. **Allograft:** bone is taken from another individual (live or dead) of the same species. It is immunologically unacceptable but gives unlimited amount.
  3. **Xenograft:** from other mammalian (e.g. pigs or cow) rare used.

Leg length equalization:

Causes of inequality of leg:

1. Congenital anomalies.
2. Malunited fracture.
3. Physeal injuries.
4. Infection.
5. Paralysis.

Inequality

< 2 cm can be compensated by the body.

2 – 4 cm treated by shoe rise.

> 4 cm need surgery.

Surgery includes 4 choices:

1. Lengthening of the shorter limb by callotasis or chondrodiatasis.
2. Speeding up growth of the shorter limb by periosteal division.
3. Shortening of the longer limb for up to 8 cm.
4. Slowing growth of the longer limb by epiphysiodesis.

Operations to increase stature: bilateral limb lengthening can be used to increase length in a short stature individual & in achondroplastic patient gain in height average 30 cm can be achieved by combining the bone lengthening with soft tissue release we should told the patient that the treatment is painful, prolonged & may be associated with complications e.g. pin tract infection, angulatory deformity or fracture.

Operation on the joints:

Arthrotomy: means opening the joint.

Indications:

1. Inspect the interior or perform a Synovial biopsy.
2. Drain a hematoma or abscess.
3. Remove a loose bodies or damaged structures e.g. meniscus
4. Excise inflamed synovium (synovectomy).

Arthrodesis: Arthrodesis, also known as artificial ankylosis or syndesis, is the artificial induction of joint ossification between two bones via surgery in a functional position. This is done to relieve intractable pain in a joint, which cannot be managed, by pain medication, splints, or other normally indicated treatments. Fusion of the joint also used for destroyed, unstable joint.

Principles of Arthrodesis:

1 Exposure: both J surfaces should be adequately visualized.
2 Preparation: both articular cartilages are denuded of cartilage & subchondral bone is feathered to increase contact.
3. Cooptation: the prepared surfaces are apposed in optimal position
4. Fixation: surfaces are held rigidly by internal or external fixation.

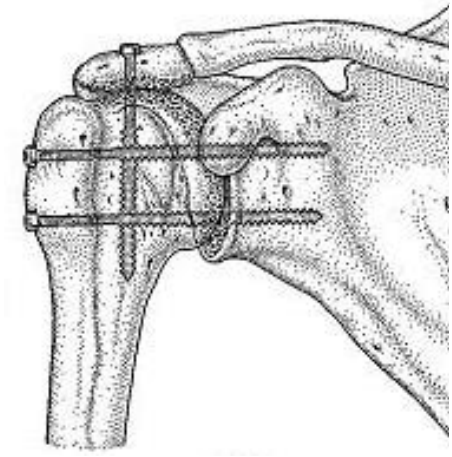

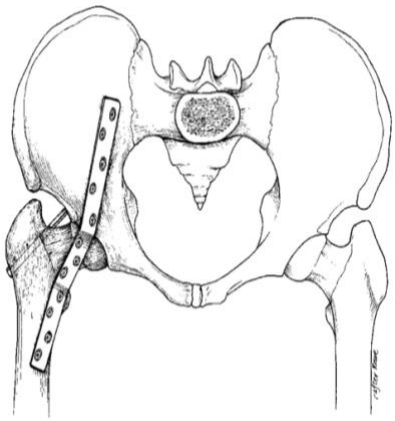

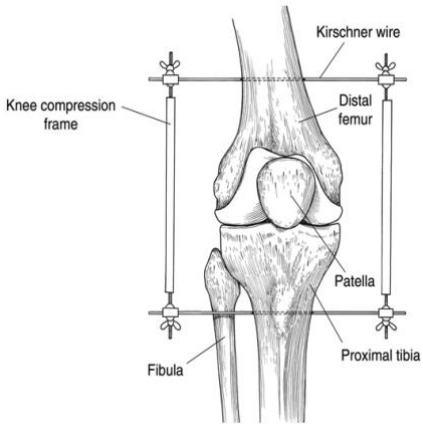

Arthroplasty: it means surgical refashioning of a joint. It is a surgical procedure to restore the integrity and function of a joint. A joint can be restored by resurfacing the bones. An artificial joint (called a prosthesis) may also be used.

Aim to:

1. Relieve pain.
2. Restore function.

Types:

1. **Excisional Arthroplasty:** sufficient bone is excised to create a gap at which movement can occur (e.g. Girdlestone's hip arthroplasty).

2. **Partial Arthroplasty:** one articular component of a joint only replaced by implant (e.g. Austin moor prosthesis).
3. **Total Arthroplasty:** both components are replaced by prosthetic implant.
4. **Resurfacing Arthroplasty:** Total resurfacing arthroplasty is a bone-preserving procedure that helps restore comfort and function to patient.

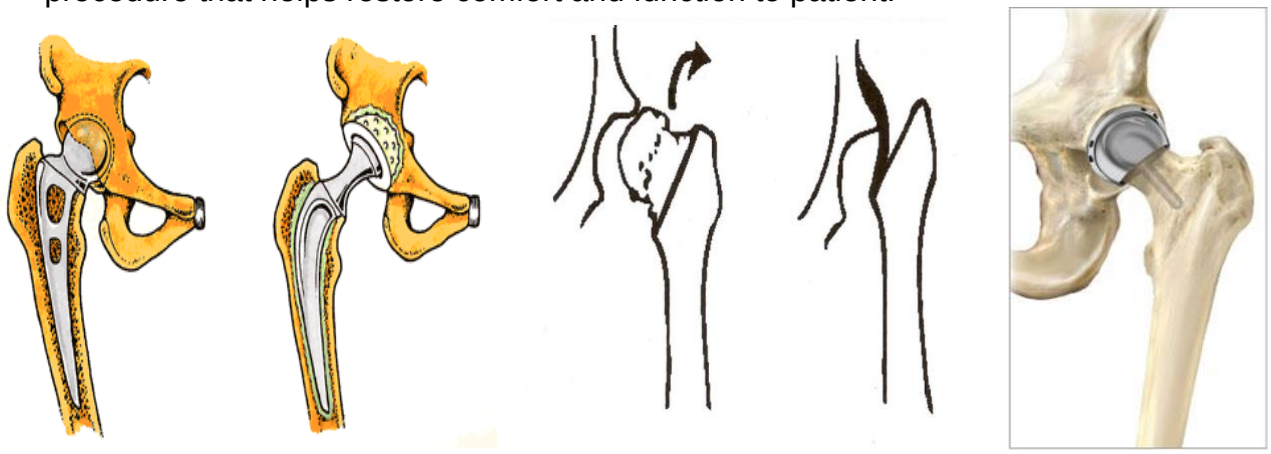

Amputation & Disarticulation

It means excision of the extremity or part of the extremity at a certain level through the bone, While Cutting of the extremity or part of the extremity through the joint is disarticulation

An amputation being performed in the eighteenth century.

Indication: (3 D)

1. Dead limb e.g. Peripheral vascular disease, Sever traumatized limb, Burns, Frostbite.
2. Dangerous limb e.g. malignancy, lethal sepsis, & crushing injury.
3. Damn nuisance: retaining the limb may be worse than having no limb at all because of pain, recurrent infections, gross deformity& severe loss of function.

Types:

1. **Provisional (Primary) amputation:** it is the amputation at the site of election (within first 24 hours) when primary healing is uncertain & the patient condition is unstable. Re-amputation is done when the stump condition is favorable.
2. **Definitive (Secondary) amputation:** Commonest variety of amputation in upper limb & lower limb amputations it is of 2 types:
   A. **End-bearing amputation:** is performed when weight is to be taken through the end of the stump. So the scar must not to be terminal, & the bone end must be solid, not hollow (i.e. the cut is through the metaphysis near the joint) e.g. Syme amputation, through knee amputation.

B. Non-end-bearing amputation: the weight is not to be taken at the end of the stump, the scar can be terminal & the bone cut anywhere e.g. transtibial, transfemoral amputation.

Levels of amputation:

The " sites of election " are determined by:

1. The demand of the prosthetic design
2. Local function e. g bellow the most distal palpable arterial pulsation

- Too short a stump →→→ slips out from the prosthesis
- Too long a stump →→→ painful, ulcerate, complicates the incorporation of the joint in the prosthesis

Now a day the skill of orthotiest make amputation possible at any level

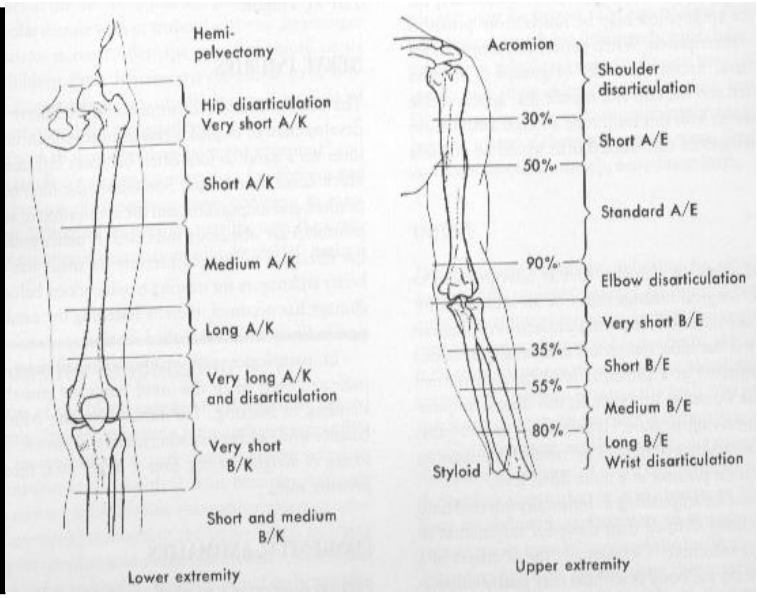

Steps of Amputation:

I. Cutting of soft tissue.
II. Treatment of periosteum and cutting of bone.
III. Homeostasis and Myodesis.
IV. Stump treatment.

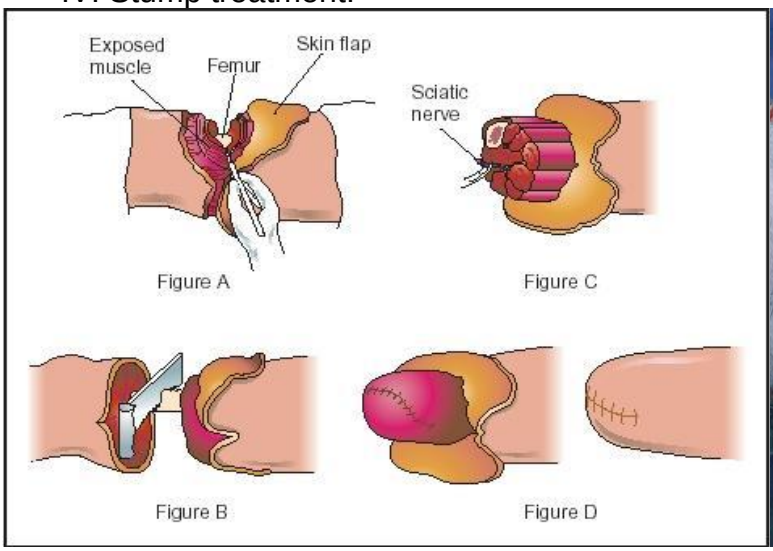

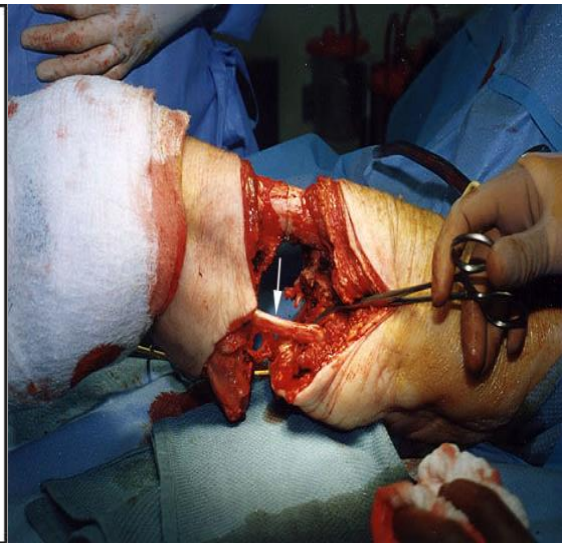

Complications:

Early:

1. Bleeding from amputation stump: Massive hemorrhage occurs when a suture ligature becomes loose or slipped.

2. Infection of the amputation stump: Superficial infection or even Osteomyelitis.
3. Breakdown of skin flaps due to ischemia, suturing under tension, long bone end pressing on the flap.
4. Gas gangrene.

Late:

1. Skin: eczema, ulceration.
2. Muscle: if too much muscle is left at the end of the stump, the resulting unstable cushion induces a feeling of insecurity, which may prevent proper use of the prosthesis.
3. Artery: Poor circulations lead to a cold, blue stump, which may ulcerate.
4. Nerve: painful neuroma, phantom limb (feeling that the amputated limb is still present) & painful phantom limb (pain & unpleasant sensation in the removed limb).
5. Joint: stiffness or deformity of the joint above the amputation site e.g. flexion deformity of the hip in above knee amputation.
6. Bone: Spur infection & fracture.

Implant materials

I. Metal: In form of screw, plates, & prosthesis metal used of 3 types:

1. Iron based-----e.g. Stainless steel.
2. Cobalt based------e.g. Cobalt - Chromium alloys, Vitallium.
3. Titanium based-----e.g. Titanium alloys.

Ideal implant materials should be: tough, strong, non-corrodible, biological inert, & easily handle & sterilizable.

II. High density polyethylene (HDPE): is an inert thermoplastic polymer ideal for joint replacement.

III. Silicon compound: e.g. silicone rubber (silastic) it is firm, tough, flexible & inert. Used to make hinges for replacing finger & toe & for spacers to replace resected bone

IV. Ceramics: used either alone or bounded to metal for joint replacement prosthesis

V. Carbon: carbon fiber may be used to replace ligament. Carbon composites may be used in plate & J prosthesis.

VI. Acrylic cement: prosthesis in joint replacement is often fixed to the bone with acrylic cement (polymethylmethacrylate), which acts as a grouting material.