ORTHOPEDIC

Lec.6
Dr.Hasan AbdulHadi

Injuries of the Shoulder & the Arm

Fractures of Clavicle

Clavicle fractures constitute 5 to 10 percent of all fractures. Most occur in men younger than 25 years; however, they are also more common in men older than 55 and in women older than 75.

The anatomic site of the fracture is typically described using the Allman classification, (*Figure 1)* which divides the clavicle into thirds.

- Group I (midshaft) fractures occur on the middle third of the clavicle,
- Group II (distal) fractures occur on the lateral third,
- Group III (proximal) fractures occur on the medial third.

Midshaft fractures account for approximately 75 to 80 percent of all clavicle fractures and typically occur in younger persons. Distal third fractures represent about 15 to 25 percent of clavicle fractures. Medial third fractures are least common, accounting for less than 5 percent of clavicle fractures.

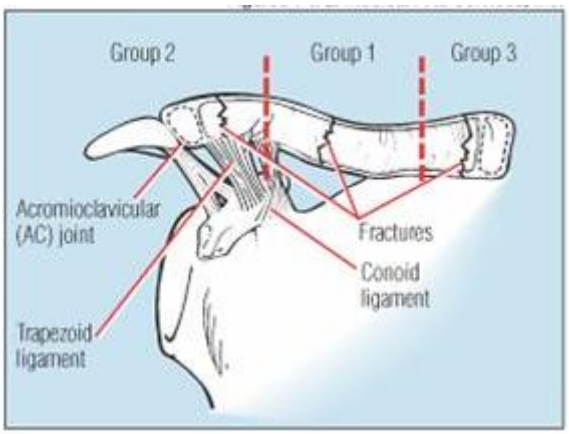

Figure 1: Allman classification, according to anatomical site.

Clinical Anatomy:

The anatomy of the clavicle is shown in (*Figure 2)*. The clavicle is easily fractured because of its subcutaneous, relatively anterior location and frequent exposure to transmitted forces. The middle third, or midshaft, is the thinnest, least medullous area of the clavicle, and thus the most easily fractured; the lack of muscular and ligamentous support makes it vulnerable to injury. The acromioclavicular (AC) and sternoclavicular (SC) joints have robust ligamentous and capsular support.

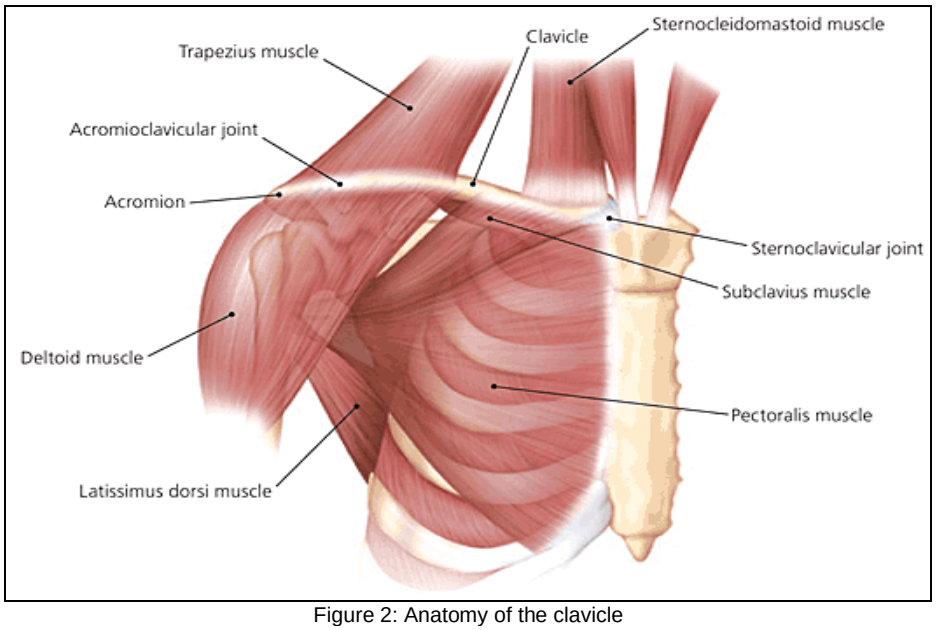

Figure 2: Anatomy of the clavicle

The clavicle has many important functions:

1. It connects the axial skeleton to the upper extremity.
2. It contributes to the motion and stability of the upper extremity.
3. With the subclavius muscle, it provides protection to the underlying neurovascular structures (i.e., subclavian vessels and brachial plexus).

Malunion may impair these functions. In addition, callus formation or displacement can lead to thoracic outlet compression.

Mechanism of injury:

The usual mechanism of a clavicle fracture is a fall directly on the shoulder with the arm at the side (indirect force). Rarely, clavicle fractures can occur from a direct blow or from a fall on an outstretched hand. In children and young adults, these injuries are typically related to sports participation, especially in contact sports such as football and rugby where participants are driven to the ground and land with the weight of their opponent on top of them.

Clinical evaluation:

Patients who have sustained clavicle fractures typically hold the affected arm adducted close to the body, often supporting the affected side with the opposite hand. This position is most comfortable because it limits the pull from the weight of the arm on the fractured bone. Physical examination may reveal ecchymosis, edema, focal tenderness, and crepitation on palpation over the clavicle. The defect in the bone may be seen by visual inspection or localized by palpation. Despite the low incidence of complications, it is important to perform a neurovascular and lung examination, because the subclavian vessels, brachial plexus, and lung apex can be injured in posteriorly displaced fractures.

Radiography should be performed on all patients with suspected clavicle fractures. Most fractures can be seen on a standard anteroposterior view of the clavicle; however, an anteroposterior view with 45-degree cephalic tilt minimizes the overlap of the ribs and scapula and allows for better assessment of displacement in the anterior and posterior plane (figure 3). Advanced imaging such as computed tomography is indicated only in rare cases of distal or proximal fracture to assess the extent of intra-articular involvement.

Figure 3: AP radiograph of a nondisplaced mid-shaft clavicle fracture

Mid-shaft Clavicle Fractures

Diagnosis of mid-shaft clavicle fractures by history, examination, and radiography is relatively straightforward (figure 4). The medial segment is pulled superiorly by the sternocleidomastoid. The weight of arm pulls lateral segment inferiorly through the coracoclavicular ligaments, but is opposed by trapezius. In addition, pectoralis major and latissimus dorsi pull the lateral segment inferomedially with resultant shortening (figure 5).

Figure 4: Radiograph of displaced midshaft clavicle fracture

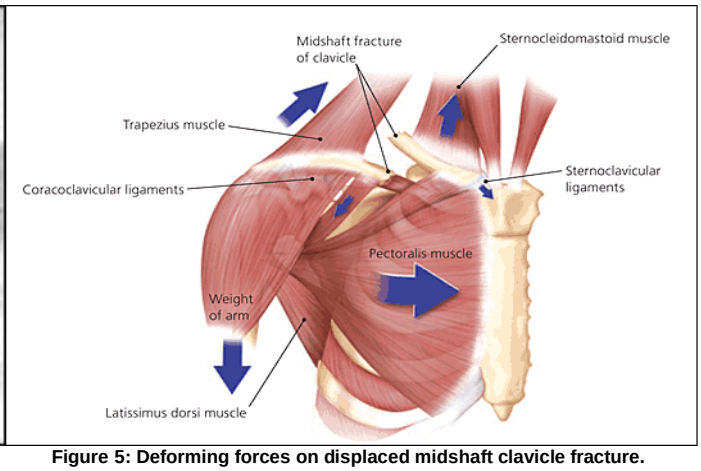

Figure 5: Deforming forces on displaced midshaft clavicle fracture.

The goals of treatment are to restore normal anatomy, limit pain, and promote a quick return to activity or play. Nonoperative management remains the most common approach to nondisplaced mid-shaft clavicle fractures. This consists of immobilization in a sling or figure-of-eight dressing. Although the figure-of-eight dressing is still widely used, several studies have demonstrated similar union rates and increased satisfaction in patients treated with a simple arm sling. Immobilization is maintained for comfort and can be discontinued in one to two weeks or when the major pain subsides. Range-of-motion pendulum exercises can be started as soon as pain allows, with gradual progression to active range-of-motion and strengthening exercises over four to eight weeks.

Figure-of-eight dressing

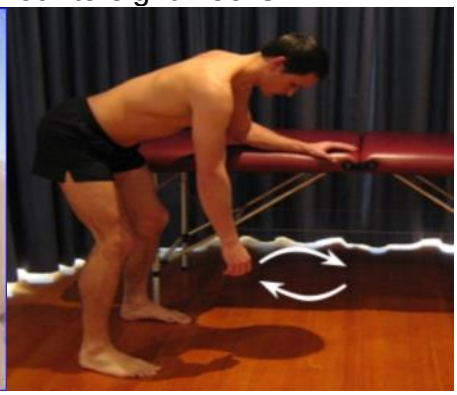

simple arm sling



pendulum exercises

Displaced mid-shaft clavicle fractures have higher rates of nonunion and a greater risk of long-term sequelae. Studies have shown that operative treatment results in a lower rate of

fracture nonunion and improved patient-oriented outcomes compared with nonoperative treatment. Therefore, although nonoperative treatment is a viable option to treat displaced mid-shaft fractures, operative repair should be considered in patients with multiple risk factors for nonunion, especially significant fracture displacement or clavicle shortening (table 1):

TABLE1: Risk Factors for Nonunion of Midshaft Clavicle Fractures

Clavicle shortening > 15–20 mm
Female sex
Fracture comminution
Fracture displacement
Greater extent of initial trauma
Older age

Complications from mid-shaft clavicle fractures are rare, despite the proximity of neurovascular structures and lung apices, but include pneumothorax and neurovascular injury. Long-term sequelae include pain at rest or during activity, weakness, paresthesia, and cosmetic defects. Displacement of more than one bone width is the strongest radiographic risk factor for symptoms and sequelae.

Mid-shaft Clavicle Fractures In Children

For young adults, the most common cause of midshaft clavicle fractures is sports-related injuries. The mean age of patients with sports-related clavicle fractures is 21 years. The mean age of patients with non-neonatal clavicle fractures is eight years; 88 percent of these fractures are midshaft. Nearly all mid-shaft clavicle fractures in children heal well because of the great periosteal regenerative potential. Children often develop a significant callus formation, and it is important to educate parents about this normal progression of healing. Healing usually occurs within four to six weeks.

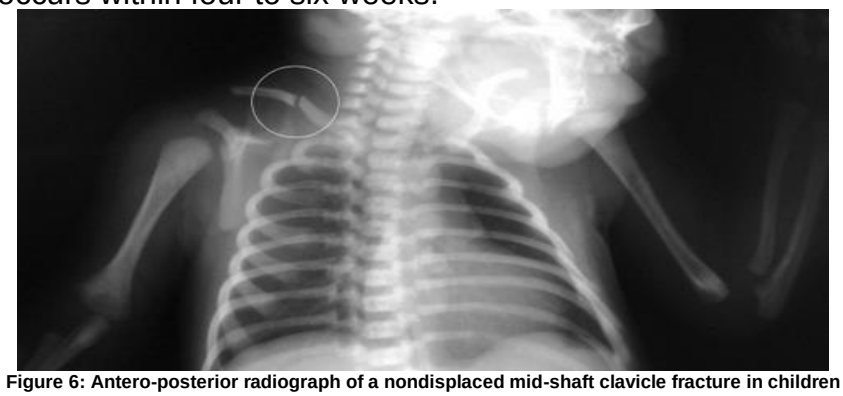

Figure 6: Antero-posterior radiograph of a nondisplaced mid-shaft clavicle fracture in children

Distal Clavicle Fractures

The primary restraints to vertical stability of the distal clavicle are the coracoclavicular ligaments. There are two distinct coracoclavicular ligaments: conoid and trapezoid. The classification and treatment of distal clavicle fractures depend on where the fracture occurs in relation to these ligaments.

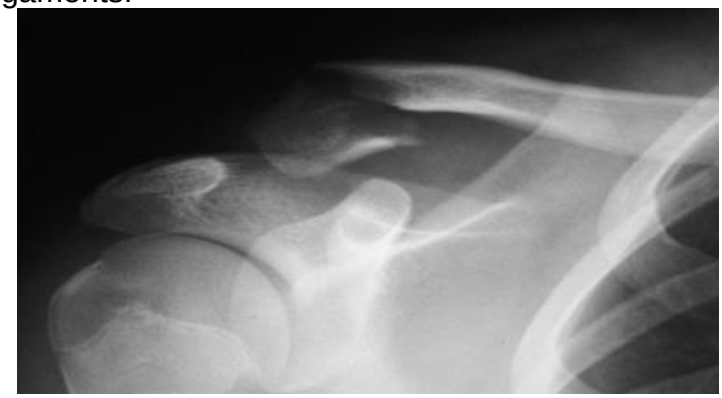

Figure 7: Antero-posterior radiograph of a displaced distal third clavicle fracture

The original classification by Neer in the 1960s described two types of distal clavicle fractures: type I, in which the coracoclavicular ligaments remain intact; and type II, in which the coracoclavicular ligaments are torn from the medial fragment and only the trapezoid ligament remains attached to the lateral fragment. The classification was later revised to include type III fractures, which involve extension into the AC joint.

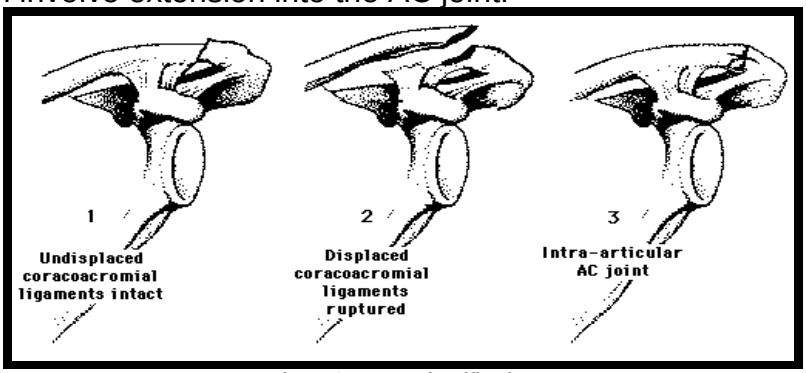

Figure 8: Neer's classification

Types **I** and **III** fractures are inherently stable and do not displace; therefore, these types of fractures can be treated nonoperatively with a sling for comfort and early range-of-motion exercises as pain allows. Bony union occurs by six weeks, but return to contact sports should be delayed for two to four months until the bony union is solid.

Much of the controversy in treating distal clavicle fractures centers around how best to treat type II fractures, which have a tendency to displace. The lateral fracture fragment is held in place by the coracoclavicular ligaments, but pulled downward and medially by the weight of the arm and by the pectoralis and latissimus dorsi muscles, while the trapezius and sternocleidomastoid muscles pull the medial fragment superiorly. Because of this displacement, there tends to be a high rate of nonunion. Despite this, outcome studies have demonstrated similar results in terms of function, strength, and pain in fractures united operatively, those united nonoperatively, and those that go on to nonunion. Therefore, even displaced fractures can be treated nonoperatively in the same way as types I and III fractures. However, the decision to treat a displaced type II fracture operatively in the acute setting may be made if the displacement is so severe that it is at risk of compromising skin integrity.

Proximal Clavicle Fractures

Fractures of the proximal third of the clavicle are uncommon. The proximal clavicle and sternoclavicular joint also have good ligamentous support, so when fractures do occur they typically do not displace. Nondisplaced fractures can be treated with a sling for comfort and gradual increase in range of motion, as pain allows.

Displaced fractures should be carefully evaluated for signs of neurovascular compromise; if present, this should be acutely reduced. In a setting capable of handling an airway or hemodynamic emergency, this reduction can be achieved acutely by grasping the clavicle with a towel clip and applying anterior traction. In the absence of neurovascular compromise computed tomography should be performed to fully visualize posteriorly displaced fragments; if necessary, reduction can be performed under anesthesia.

Figure 9: AP film of a displaced proximal third clavicle fracture

Fractures of the Scapula

Mechanism of the injury: The body of the scapula is fractured by crushing force, which usually also fractures ribs & may dislocate the sternoclavicular joint. The neck of the scapula may be fractured by a blow or by a full on shoulder.

Clinical features: Shoulder movements are painful but possible. If breathing also is affected, thoracic injury must be excluded.

X-Ray: show comminuted fracture of the body of the scapula or fracture scapular neck. Occasionally a crack is seen in the acromion or the coronoid processes C.T. scan is useful for diagnose glenoid fracture.

Treatment: conservative by sling & start early active exercise.

Acromioclavicular Joint Injuries

Mechanism of injury:

A fall on the out stretched hand tears the acromioclavicular (A-C) ligament, & upward subluxation of the clavicle may occur, more severe injury also tears the coracoclavicular (C-C) (Coniod & trapezoid) ligaments & result in complete dislocation of the joint. So the injuries can be classified in to:

- Grade I: Sprain (Partial tear of the A-C ligament).
- Grade II: Subluxation (Compete tear of the A-C ligament).
- Grade III: Dislocation (Tear of the A-C & C-C ligaments).

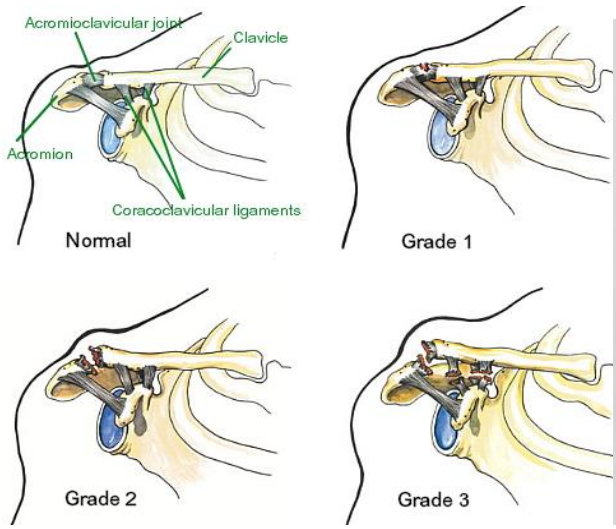

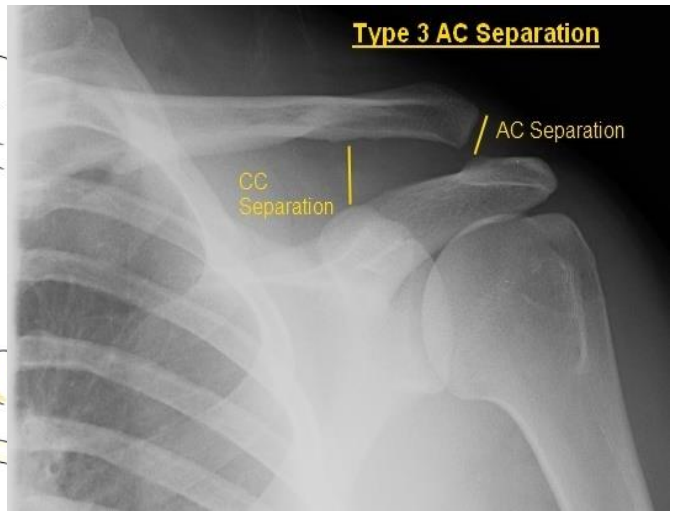

X-Ray:

The film shows either a subluxation with only slight elevation of the clavicle or dislocation with considerable separation. A stress view, taken with the patient holding a 5Kg weight in each hand, may reveal the displacement more clearly.

Treatment:

- Subluxation & sprain ----- sling till pain decrease then exercise.
- Dislocation ----- padding & strapping + sling & exercise. Surgery only indicated in sportsman by open reduction, repair the torn ligament & hold reduction by a screw inserted from the clavicle downward into the coracoid process, (the screw removed after 8wk).

Sternoclavicular Dislocation

- **Anterior Dislocation:** this uncommon injury is caused by a fall on the shoulder. The inner end of the clavicle springs forward, producing a visible & palpable prominence. The joint can usually be reduced quite easily by direct pressure on the prominent clavicle while the shoulders are relaxed.

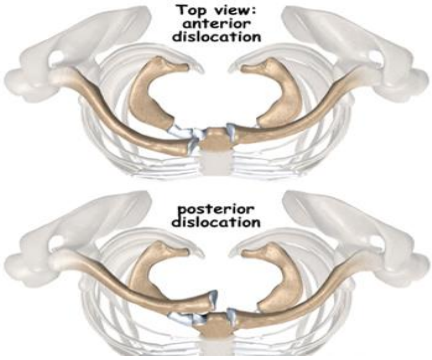

- **Posterior dislocation:** this is very rare, but it can cause compression of the large vessels in the neck & should be reduced as a matter of urgency. Closed reduction can sometimes be achieved by laying the patient supine with a sand bag between the shoulder blades & then pulling on the arm with the shoulder abducted & extended, the joint reduces with a snap. The shoulders are braced backwards with a figure of 8 bandages, which is kept in place for 3wk. if closed reduction fails, operative reduction is needed. The displaced clavicle is pulled forward with a hook.

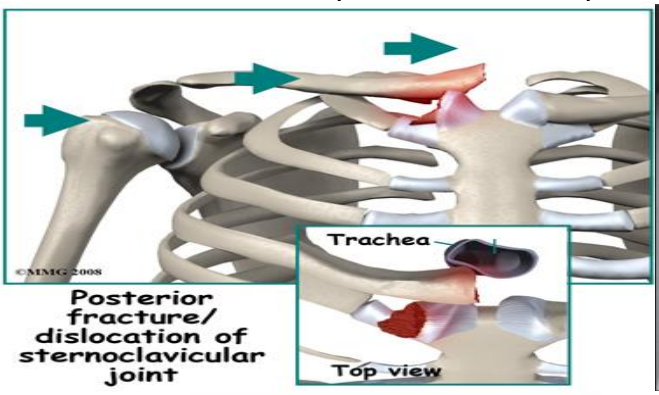

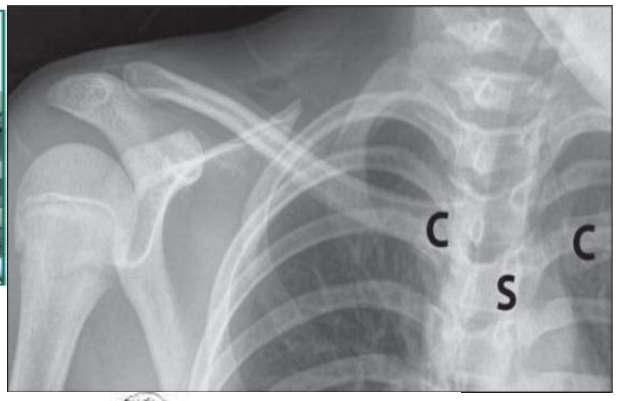

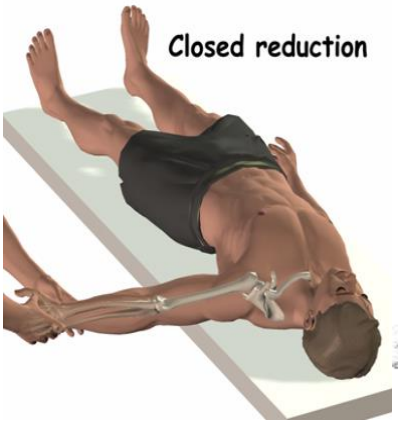

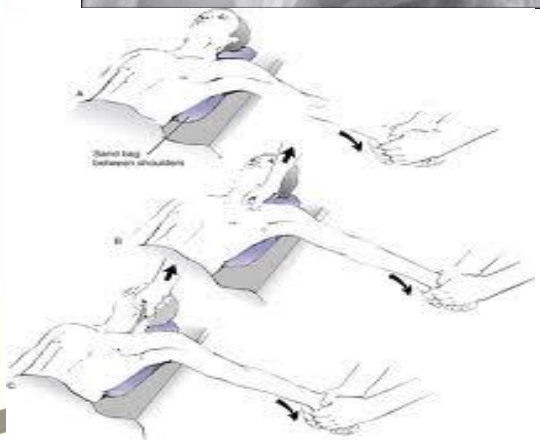

Shoulder Dislocation

The shoulder region is made of three bones, which come together at one place. The arm bone (humerus), the shoulder blade (scapula), and the collarbone (clavicle) all meet up at the top of the shoulder. The shoulder is the most commonly dislocated large joint seen in the emergency department, and anterior dislocations account for 90-98% of cases. It is the commonest joint to be dislocated due to:

1. The shallowness of the glenoid socket.
2. The extra ordinary range of movement.
3. Underlying conditions such as ligament laxity or glenoid dysplasia.
4. The sheer vulnerability of the joint during stressful activity of the upper limb.

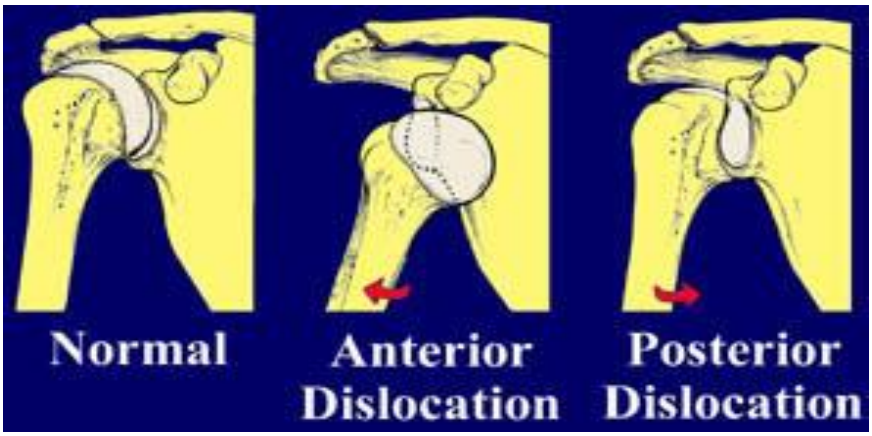

A) Anterior Dislocation:

Mechanism of injury: is caused either by a full on the backward stretching hand or by forced abduction & external rotation of the shoulder. The head of the humerus is driven forward, tearing the capsule or avulsing the glenoid labrum, & usually ends up just below the coracoid process there may be an associated fracture of the proximal end of the humerus.

Clinical features: pain is severe the patient supports the arm with the opposite hand & is loath to permit any kind of examination the lateral shoulder contour is flattened & a small bulge may be seen & felt just below the clavicle. The arm must always be examined for nerve & vessels injury.

X-Ray: this is showing the overlapping shadows of the humeral head & glenoid fossa, with the head usually lying below & medial to the socket.

Treatment: reduction is most easily carried out under GA & full relaxation, so as to minimize the risk of further damage. Methods of closed reduction:

1. *Hippocratic method:* gently increasing traction is applied to the arm with the shoulder in slightly abduction, while the assistant applies firm counter traction to the body (under axilla).

2. *Kocher's method:* the elbow is flexed to 90° & held closed to the body (no traction is applied). The arm is slowly rotated 75° laterally, then the point of the elbow is lifted forwards & adducted, & finally the arm is rotated medially.

3. *Stimson's method:* the patient is left prone with the arm hanging over the side of the bed, after 15 – 30 min the shoulder reduces.

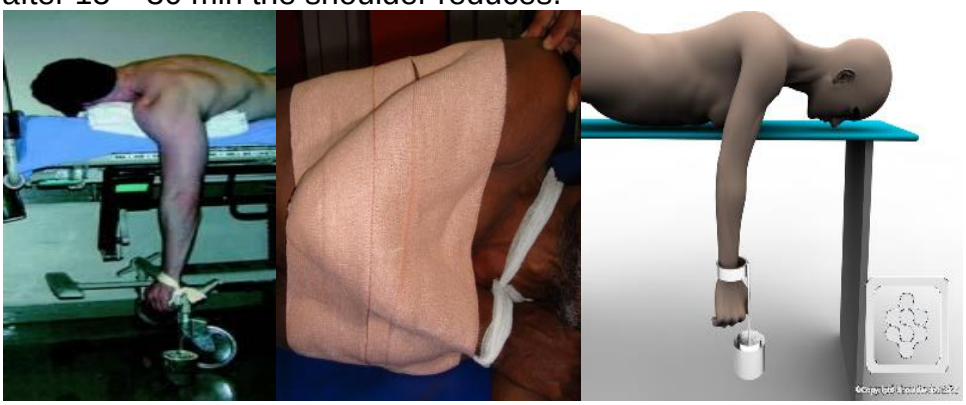

An X-ray is taken to confirm reduction & exclude a fracture. When the patient is fully awake active abduction is gently tested to exclude an axillary nerve injury. The arm is rested in a sling for week or 2 & active movements are then begun, but combined abduction & lateral rotation must be avoided for at least 3wk.

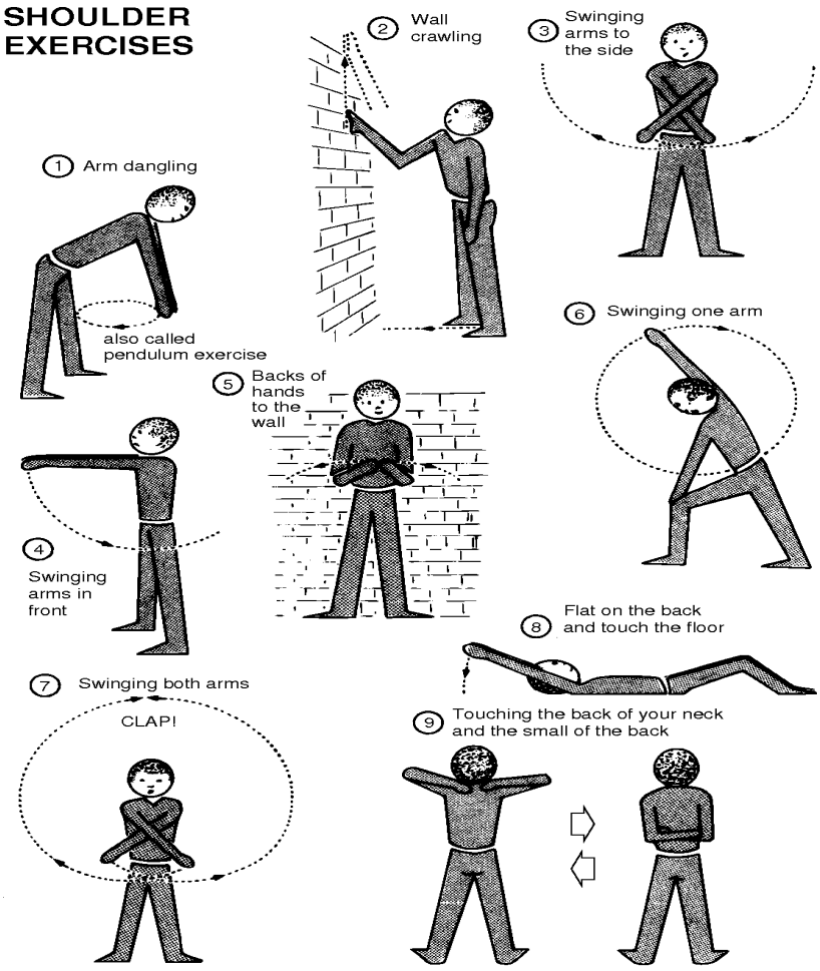

Complication:

1. Nerve injury: axillary nerve may be injured the patient is unable to contract the deltoid muscle & there is anesthesia over the top of the shoulder. The lesion is usually a neuropraxia, which recur spontaneously after a few weeks.
2. Vascular injury: the axillary artery may be damaged.
3. Fracture \ Dislocation: e.g. fracture humerus, ORIF will be needed.
4. Recurrent dislocation: due to tear or detachment of the labrum.
5. Shoulder stiffness.

B) Posterior Dislocation: rare about 2%

Mechanism of the injury:

- *Indirect force:* producing marked internal rotation & adduction needs be very severe to cause a dislocation e.g. after a fit or convulsion or with electric shock.
- *Direct force:* blow to the front of the shoulder of a full on the flexed adducted arm.

Clinical Feature: the diagnosis is frequently missed because in the AP X-ray the humeral head may seem to be in contact with the glenoid. Clinically the condition is unmistakable because the arm is held in medial rotation & is locked in that position.

X-Ray: in AP view the humeral head, because it is medially rotated, looks somewhat globular. A lateral view is essential for the diagnosis.

Treatment: the arm is pulled (under GA) with the shoulder in adduction, a few minutes are allowed for the head of the humerus to disengaged & the arm is then gently rotated laterally while the humeral head is pushed forward. Then the arm rested in sling for 2 – 3 weeks then start exercise.

Fractures of Proximal Humerus

Usually occur after middle age & are most common in osteoporotic & post-menopausal women.

Mechanism of injury: the patient falls on the outstretched hand, fracturing the surgical neck; one or both tuberosity may also be fractured.

Clinical Features: pain may not be very severe because the fracture is often firmly impacted. There may be large bruise in the upper arm. The patient should be examined for nerve & vascular injury.

X-Ray & Classification: the most widely accepted classification is that of Neer who drew attention to the four major segments involve in these injury:

1. The Head of the humerus.
2. The Lesser tuberosity.
3. The Greater tuberosity.
4. The Shaft.

The displacement is defined as more than 45° angulation or more than 1cm separation.

Classified as follow:

- *One-part fracture ----the fragments are undisplaced.*
- *Two-part fracture ----one fragment is displaced.*
- *Three-part fracture ----two fragments are displaced.*
- *Four-part fracture ----all fragment are displaced.*
- *Fracture \ Dislocation ---- in addition to above there is dislocation.*

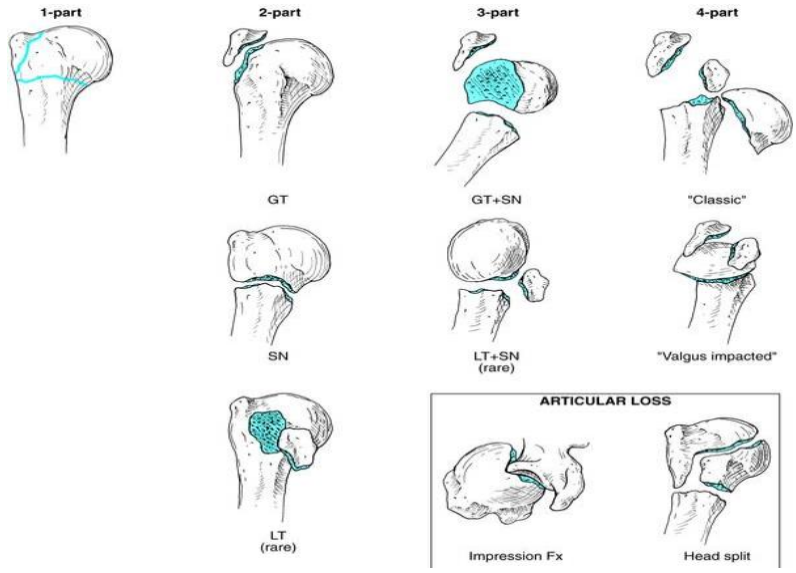

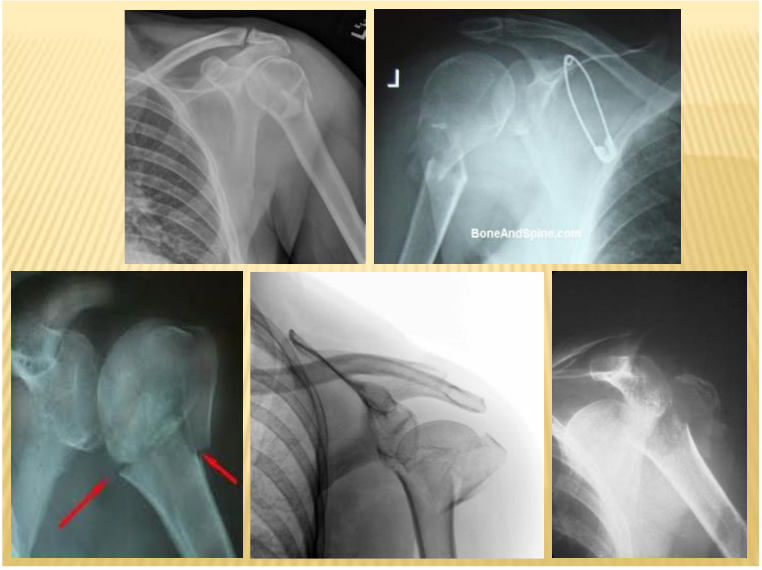

Treatment:

1. *One part fracture:* need no treatment apart from a short period of rest with sling for 6wk.
2. *Two part fracture:* can be reduced closed, the arm is then bandaged to chest for 6 – 8wk after which shoulder exercises are commenced.
3. *Three part fracture:* in young require ORIF. In elderly closed reduction followed by physiotherapy.
4. *Four part fracture:* prosthetic replacement.
5. *Fracture \ Dislocation:* the dislocation should reduce (may require surgery) and the fracture treats as above.

Fractures of Humeral Shaft

Mechanism of injury:

1. *Indirect Force:* a full on the hand may twist the humerus, causing spiral fracture.
2. *Direct Force:* blow cause either transverse or comminuted fracture
3. *Pathological fracture:* in elderly may be due to secondary metastasis.

Clinical Features: the arm is painful, bruised & swollen active extension of the wrist & fingers should be tested before & after treatment because the radial nerve may be damaged.

X-Ray: the fracture is usually obvious but not forgets the pathological lesion e.g. fractures through bone cyst or metastasis.

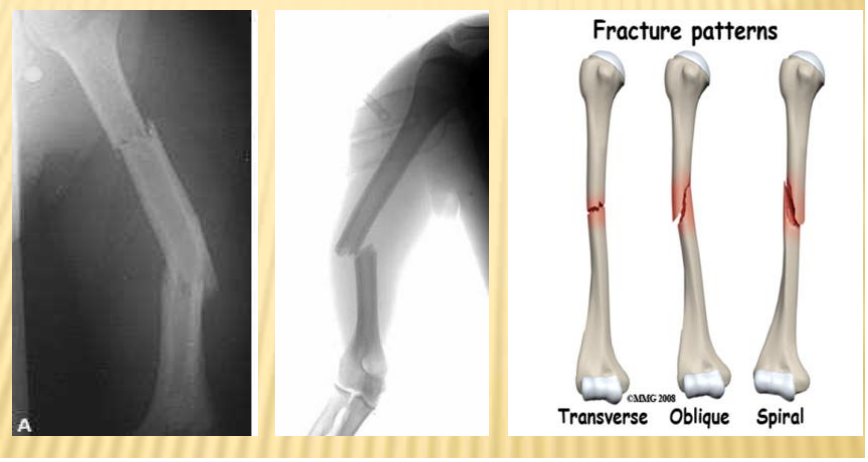

Treatment: fractures of the humerus require neither perfect reduction nor total immobilization.

- *Conservative Treatment:* by hanging POP cast which is applied from the shoulder to the wrist with the elbow flexed to 90o; after 2 – 3wk it may be replaced by a short cast (shoulder to elbow) or by a removable brace. Exercise of the shoulder can be started within a week, but abduction is avoided until the fracture united.

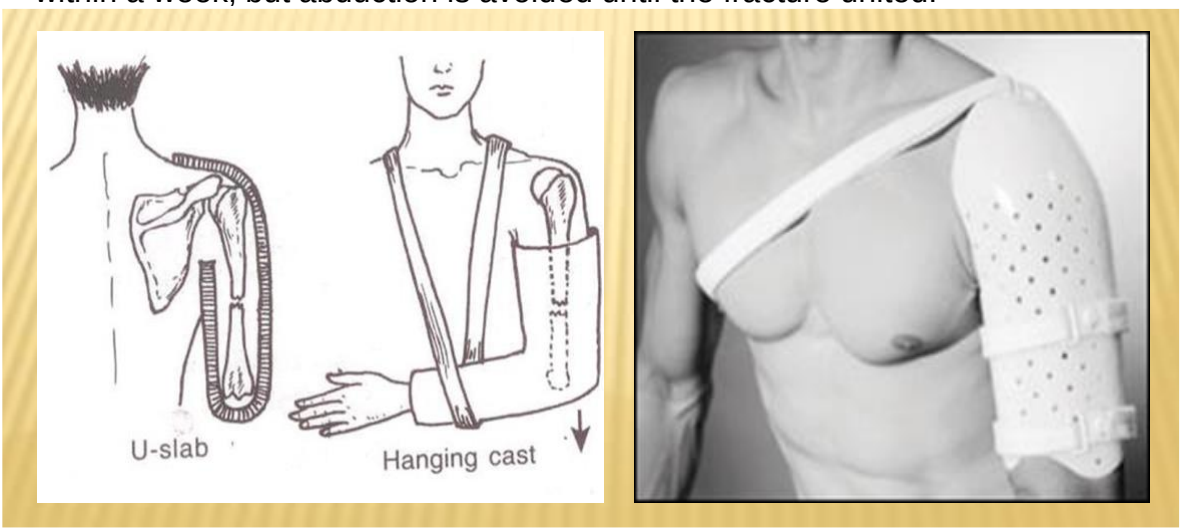

- ***Operative treatment:***
  1. Open fracture.
  2. Severe multiple injuries.
  3. Segmental fracture.
  4. Floating elbow (fracture humerus + fracture forearm bones).
  5. Nonunion
  6. Pathological fracture.
  7. Bilateral fracture humerus.

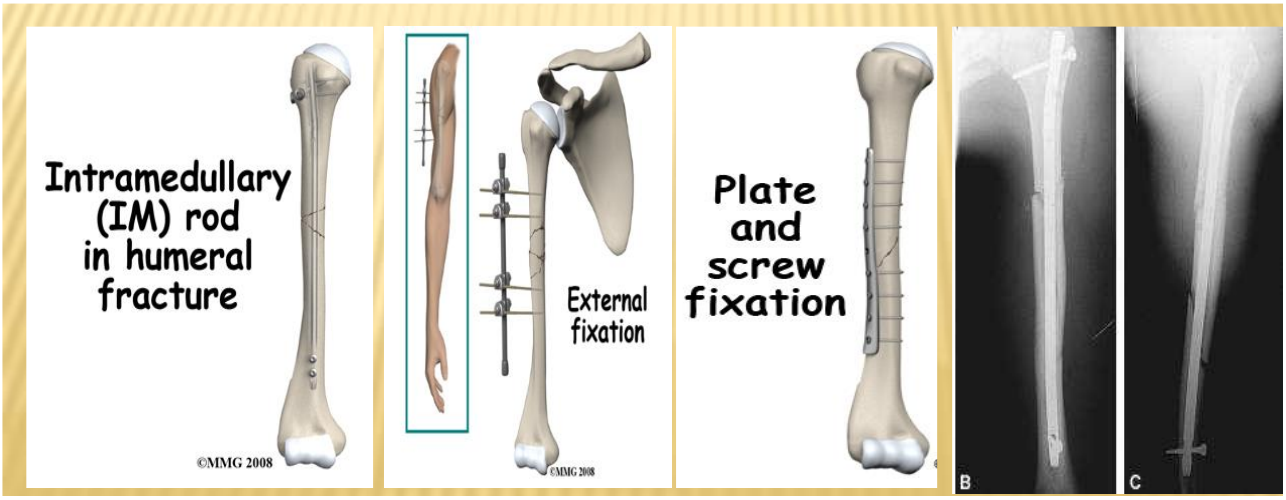

Complication:

- ***Early:***
  1. *Vascular injury:* e.g. brachial artery or Profanda brachii artery.
  2. *Nerve injury:* radial nerve palsy (wrist drop & paralysis of the metacarpophalangeal extensors) may occur with shaft fracture especially oblique fracture at the junction of the middle thirds & distal third of the bone (Holestien fracture). Usually the nerve not divided (neuropraxia) & there is no hurry to operate. If there is no sign of recovery by 12wk the nerve should be explored.

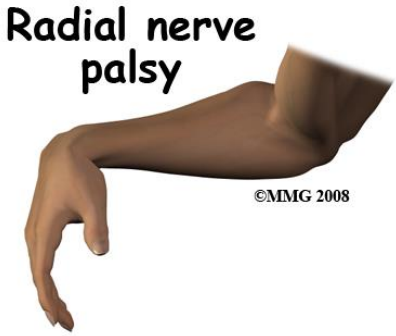

- ***Late:***
  1. *Nonunion:* need ORIF+BG.
  2. *Joint stiffness:* need physiotherapy.

Supracondylar Fractures of the Humerus

These are the commonest fracture in children, the distal fragment may be displaced either: Posterior (95%) or Anterior (5%).

Mechanism of Injury:

a. Posterior Displacement: due to hyperextension injury e.g. in a full on the outstretch hand. The distal fragment is pushed backward & because the forearm is usually in pronation the fragment will twist inward.
b. Anterior Displacement: due to direct violence (e.g. a fall on the point of the elbow) with the joint in flexion.

Classification: Wilkin's classification.

- Type I ------ undisplaced fracture
- Type IIa ------ displaced & angulated but posterior cortex still in continuity.

- Type IIb ------ displaced & rotated.
- Type III ------ completely displaced.

Clinical Features: following a fall, the child is in pain & the elbow is swollen with a posterior displaced fracture the S-deformity of the elbow is usually obvious & the bony landmarks are abnormal. The limb should be examine for vascular & nerve injury.

X-Ray:

- *In lateral view*: posterior displaced fracture the distal fragment is tilted & shifted backward. In anterior displaced fracture the distal fragment is shifted & tilted forward.
- *In AP view*: the distal fragment is shifted or tilted sideway & rotated medially. Measurement of the Baumann's angle is useful in assessing degree of the medial angulation & rotation (normal 60° – 80°) it is the angle between the longitudinal axis of the humerus & coronal axis of the capitellar physis.

Treatment:

- *Undisplaced* fracture (type I): the elbow is immobilized in 90° neutral position back slab for 5 – 7 days then to re-examined by X-ray if still undisplaced the slab will be replaced by complete cast for 3 – 4 wk then exercise
- *Posterior Angulated* fracture (type II): swelling is usually not severe & the risk of vascular injury is low. If the posterior cortices are in continuity, the fracture can be reduced under GA as follow:
    1. Traction for 2 – 3 minutes in length of arm with counter-traction above elbow.
    2. Correction of any sideway tilt or shift & rotation (in comparison with other arm).
    3. Gradual flexion of elbow to 120° & pronation of the forearm while maintaining traction & exerting finger pressure behind the distal fragment to correct tilt.
    4. Feel pulse & check the capillary return; if the distal circulation is suspected, immediately relax the amount of flexion until pulse return.
    5. X-Ray taken to confirm reduction.
    6. If reduction is unstable ----- closed percutaneous K wire fixation.
- *Posterior Displaced* fracture (type III): the fracture reduced as above & then held with percutaneous crossed K wire fixation.

Following reduction the arm is held in collar & cuff the circulation should be checked repeatedly during the first 24hr.

Complications:

1. Vascular injury: occur in 10% (brachial A.).
2. Compartment syndrome: due to forearm edema. <u>*S&S*</u> undue pain tense & tender forearm, an absent pulse, blunted sensation or reduced capillary filling on pressing the finger pulp & positive stretch test.
   <u>*Treatment;*</u> the flexed elbow must be extended & all dressing removed, if circulation negative then do urgent angiography or Dopplar U\S or even surgical exploration.
3. Nerve injury: Median N (5 – 20%).
4. Malunion:
    - Shift: can be remodel during growth (accepted).
    - Tilt:

1. Backward or forward: can be accepted (may limit flexion & extension).
2. Sideway or Rotation: severe deformity not improved with growth e.g. cubitus varus or cubitus valgus ----- corrective osteotomy.

5. Elbow stiffness: this may take months & should not be hurried because of the risk of myositis ossificans after forced movement.

Fractures of the Lateral Condyle

The distal humeral epiphysis begins to ossify at about 2yr & fused with the shaft about 16yr between these ages the condyle or the epicondyle may be sheared off or avulsed by the sudden pull of the forearm muscles during a fall on the hand.

Mechanism of the Injury: fall on the out stretched hand with the elbow stressed in varus.

X-Ray: the epiphysis is cartilaginous & only the ossific center is visible so may need x-ray of the normal other side for compression.

Treatment:

- *Undisplaced* fracture need splint for 2 – 3wk then start exercise.
- *Displaced* fracture may be reduced by manipulation but if this fails operative treatment is needed & the fragment fixed by screw or K wire.

Complications:

1. *Malunion:* result in cubitus valgus if the deformity severe needs correction by supracondylar osteotomy.
2. *Nonunion:* if the condyle left capsized nonunion occur & the elbow becomes increasingly valgus & the ulnar nerve palsy is then likely to develop.

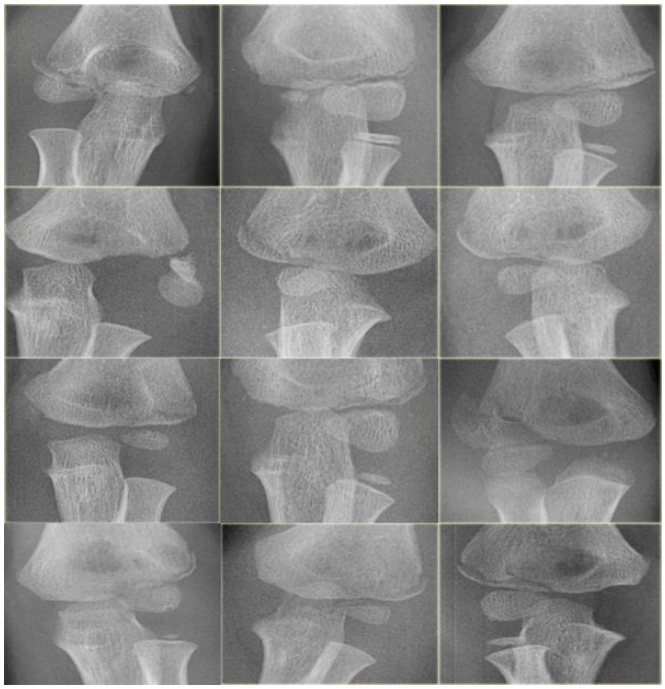

Fractures of the Medial Epicondyle

Medial epicondyle epiphysis begins to ossify at about 5yr & fuse at about 16yr between these ages may be avulsed by severe muscle or ligament strain.

Mechanism of injury: fall on outstretch hand & elbow stressed in valgus.

Clinical Features: the medial side of the elbow is painful, swollen & acutely tender.

X-Ray: has to be studied very carefully to detect the tiny ossific center & its position.

Treatment: undisplaced or minor displaced fracture need splint 2 – 3weeks then exercise. Displaced fracture need manipulation with the elbow in valgus & the wrist hyperextended (to pull the flexor muscle) if the fragment trapped in the joint then do surgery.

Fractured Capitellum

This is an intra-articular fracture, which occurs only in adult.
Mechanism of injury: falls on the hand, usually with the elbow straight the anterior part of the Capitellum is sheared off & displaced.
Clinical Features: pain & fullness in the front of the elbow & the lateral side is tender & flexion is grossly restricted.
X-Ray: lateral view part of the bone is seen in front of the lower humerus.
Treatment: undisplaced fracture need splint for 2 – 3wk then exercise. Displaced fracture need surgery either excision of the piece or fixation.

Fractures of Distal Humerus in Adults

These are 3 types:

- *Type A*------ Extra-articular Supracondylar fracture.
- *Type B* ------ Intra-articular Unicondylar fracture.
- *Type C* ------ Intra-articular Bicondylar fracture.

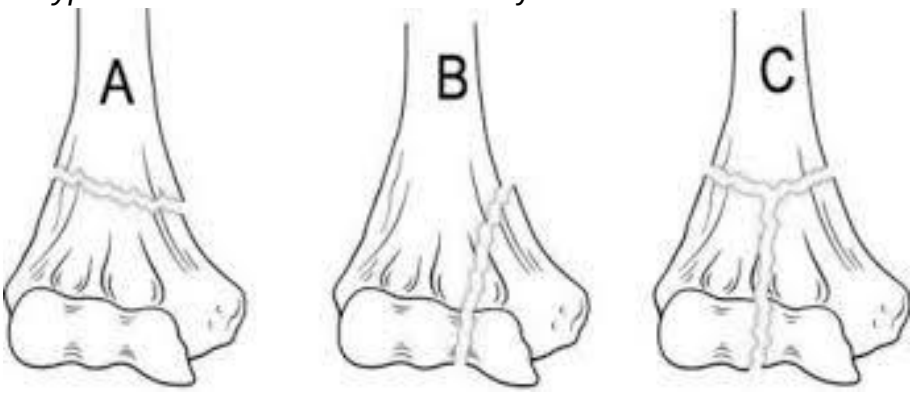

Treatment:
Undisplaced fracture ------ conservative treatment.

Displaced fracture ------ operative treatment.