Periodontal Ligament

The **periodontium** is defined as those tissue supporting and investing the tooth and consists of cementum , Periodontal Ligament (PDL) ,bone lining the alveolus (socket), and that part of gingival facing the tooth.

Periodontal Ligament is that soft, specialized C.T situated between the cementum covering the root of the tooth and the bone forming the socket wall. The PDL occupies the periodontal space and is composed of cells and intercellular substance. It has thickness 0.15-0.38 mm, it is thinnest in the middle third of the root, and decrease slightly in thickness with aging.

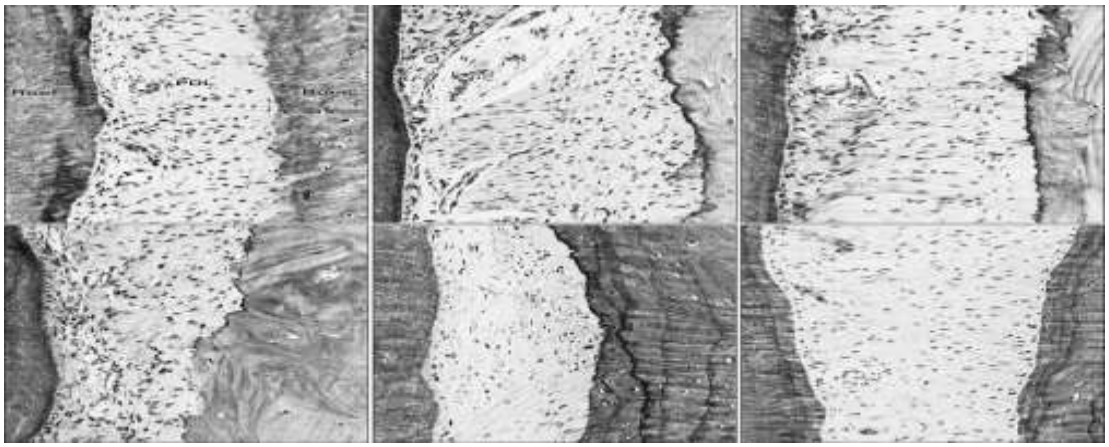



Development of PDL

The formation of PDL occurs after the cells of hertwigs epithelial root sheath have separated , forming the strand known as the epithelial rest of malassez .This separation permits the cells of the dental follicle to migrate to the external surface of the newly formed root dentin. These migrant follicle cells then differentiate into cementoblast and deposit cementum on the surface of dentin. Other cells of the dental follicle differentiate into fibroblast, which synthesize the fibers and ground substance of PDL. The fibers of PDL become embedded in newly developed cementum and alveolar bone , and as the tooth erupt, are oriented in characteristic fashion.

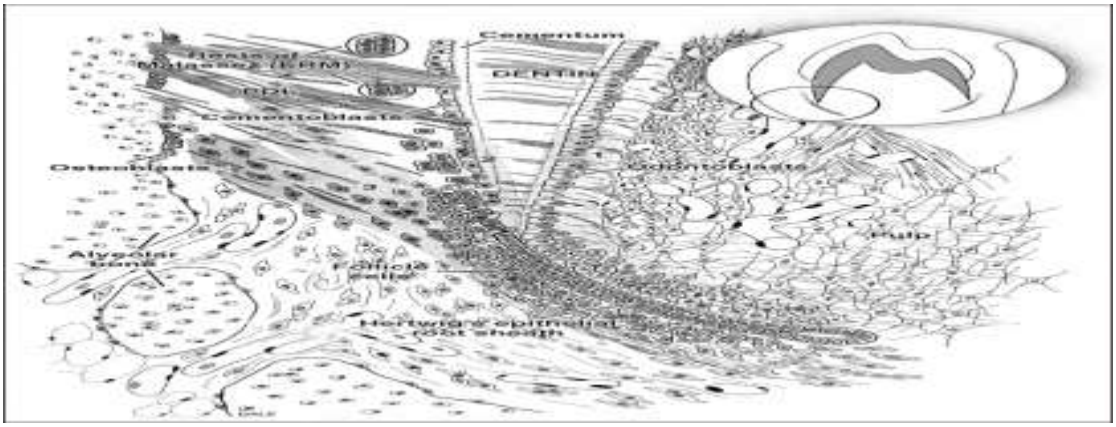

Cells of the PDL

1. Synthetic cells

Osteoblast, fibroblast and cementoblast

a. Fibroblasts are the most numerous cells seen in the PDL because of the high collagen density of this tissue. The abundant of fibroblasts allows rapid replacement of fibers. Fibroblast appear to be oriented parallel to the oriented bundles of collagen fibers. Some fibroblast form and destroy collagen as it has ability to simultaneously synthesized and degrade collagen, a process essential to the physiological turnover or remodeling of PDL.

b. Osteoblasts

These are located along the surface of the alveolar bone in various stages of differentiation, also their progenitor cells are found, as well as osteoclasts.

c. Cementoblasts

They appear near the cementum of variously differentiated stages and their progenitors.

2.Resorptive cells

a.Osteoclasts

These are cells that resorpe bone and tened to be large and multinucleated but can be small and mononuclear. Osteoclasts originate from monocytes within the blood vascular systemand become the multinucleated cells seen in the lacunae of resorption sites in hard tissue. They appeared to occupy bays in bone (howship's lacunae) or surround the end of the bone spicule. They have characteristic folds termed the ruffled or striated border. The ruffled border disappears in inactive osteoclasts. Histochemical tests showed that oseoclasts are rich in acid phosphatase, which is contained in lysosomes . The presence of osteoclasts indicates that resorption was active.

Osteoclasts are seen regularly in normal functioning PDL, in which the cells play a part in the removal and deposition of bone that are responsible for its remodeling, a process that allows functional changes in the position of teeth that must be accommodated by supporting tissues.

b. Cementoclasts

They resemble osteoclast and occasionally found in the normal functioning PDL . They resorbed cementum under certain circumstances; and in these instances mononuclear or multinucleated gaint cells located in Howship's lacunae, are found on the surface of the cementum.

3. Epithelial rests of Malassez

Epithelial rests are normal constituents of the PDL that are seen throughout the life, they are found close to the cementum and are remnants of the epithelial root sheath, they persist as a network, strand, island, or tubule-like structures and parallel to the surface of the root. When certain pathological conditions are present, cells of epithelial rests can undergo proliferation and can produce a variety of cysts and tumors that unique to the jaws.

4. Macrophages

They are important defense cells because of their phagocytic activity and mobility; they take up bacteria , dead cells and foreign bodies. Lymphocytes, leukocytes, and plasma cells also appear when PDL is stressed by disease.

5.Progenitor cells

All C.T ,including PDL contain progenitor cells that have the capacity to undergo mitotic division , and replace dying differentiated cells at the end of their life span or as a result of truma.

Extracellular substance

The extracellular substance of the PDL comprises the following :

Fibers

-Collagen

-Oxytalan

Ground substance:

The space between cells, fibers , blood vessels and nerves in PDL is occupied by ground substance its make up of 2 major groups of substance (Proteoglycans and Glycoproteins).

Fibers : The fibers of the PDL are made up of collagen and oxytalan. The majority of fibers in the PDL are collagen.

Oxytalan fibers these are fine elastic- like fibers, small in diameter and appear to interlace with the collagen bundles, supporting the collagen fibers and the blood vessel walls as well. When viewed through a light microscope they appear to be almost longitudinal in the ligament.

Collagen fibers is a specific , high molecular weight protein to which are attached a small number of sugars . The PDL appears to be made up predominantly of type I collagen and type III collagen are also present. Collagen macromolecules are arranged to form fibrils , these fibrils are packed to form bundles or fibers that oriented relative to periodontal space and these are termed **principal fibers**. Groups of principal fibers are named according to their location with respect to the teeth , there are two groups: the **gingival group**, located around the necks of the teeth , and the **dentoaleveolar group** , which surround the roots.

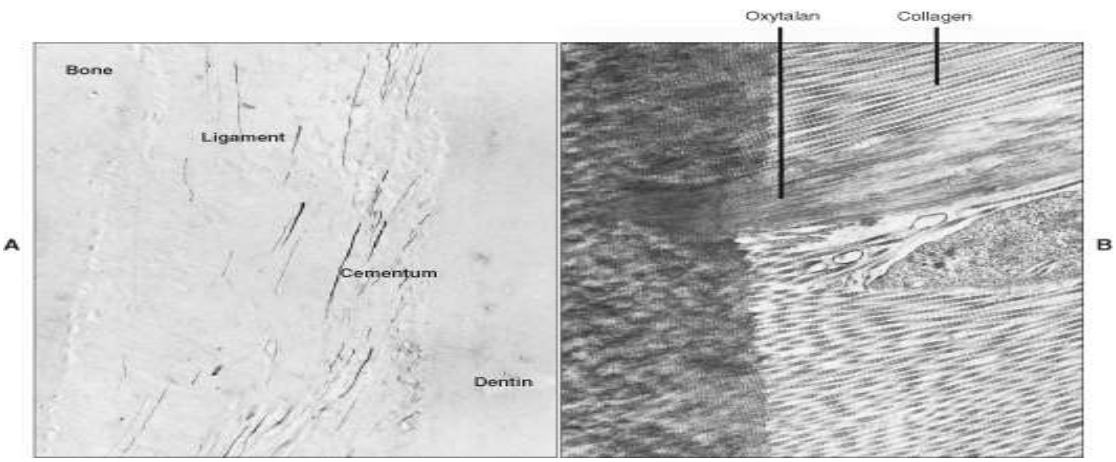

Gingival group

The fibers of this represent four groups of principal fibers , each having a different orientation and function in support of gingival tissues.

1.Free gingival fibers
2.Attached gingival fibers
3.Circumferential fibers
4.Transseptal fibers

Dentoaleveolar group

This group consist of five differently oriented types of principal fibers groups named according to their origin and insertion in the dentoaleveolar process

1.Aveolar crest group
2.Horizontal group
3.Oblique group
4.Apical group
5.Interradicular group

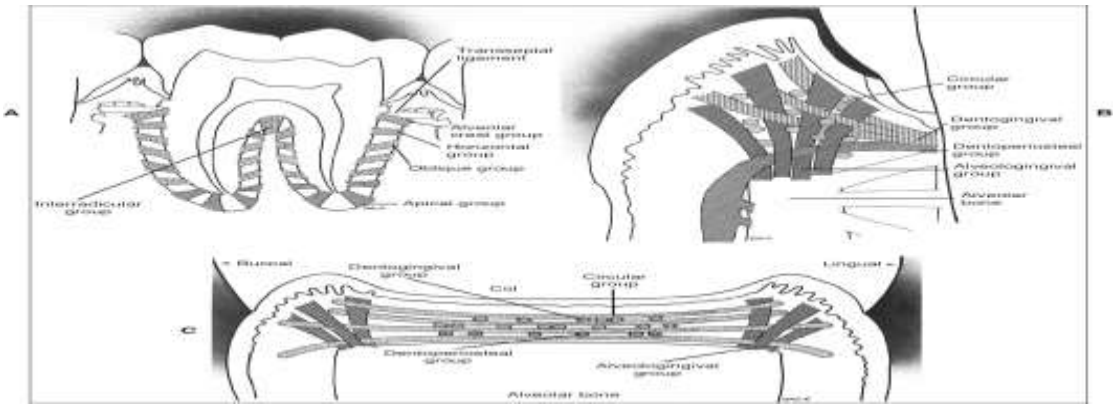

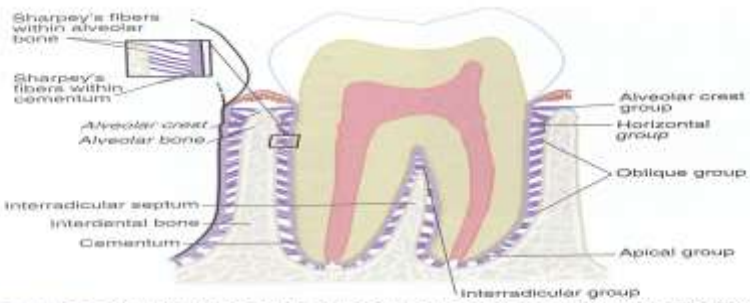

FIGURE 14-27 A sagittal section of the tooth and periodontal ligament. The fiber groups of the alveolodental ligament are identified: alveolar crest, horizontal, oblique, and apical as well as interradicular on multirooted teeth.

The principal fibers run in a wavy course from cementum to bone. Microscopical examination showed that fibers arising from cementum and bone are joined in the mid- region of periodontal space , giving rise to a zone of distinct appearance, called **intermediate plexus** , this region provides a sit where rapid remodeling of fibers occurs , allowing adjustments in the ligament to be made to accommodate small movements of tooth. The embedded portion of fibers into cementum on one side and into aleveolar bone on the other are termed **Sharpey's fibers**.

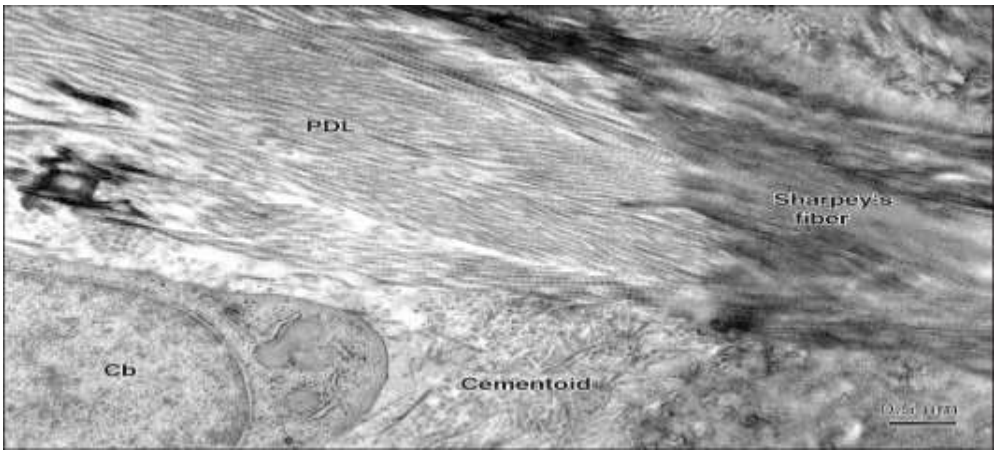

Intercellular tissue

Surrounds and protects the cells of the PDL and also the product of these cells, composed of ground substance (glycoprotein and proteoglycans) that Surround the collagen fibers, these protein and polysaccharides provide the cells with vital substance that arise from the blood capillaries and return catabolites from these cells to the vessels.

Interstitial tissue

Some f blood vessels, lymphatic and nerves of PDL are surrounded by loose C.T, these area termed interstitial tissue, they occupy spaces between bundles of principal fibers called interstitial space, these spaces are designed to withstand the impact of masticatory force.

Structures present in PDL

-Blood vessels
-lymphatic
-Nerves
-Cementicles

Blood vessels

The arterial vessels f the PDL are derived from three sources

1.Branches in the PDL from apical vessels that supply the dental pulp.

2. Branches from intra-alveolar vessels, these branches run horizontally, penetrating the alveolar bone to enter PDL.

3.Branches from gingival vessels enter PDL from the coronal direction

There is rich vascular plexus at the apex and in the cervical part of the ligament. The venous vessels tend to run axially to drain to the apex.

Lymphatic

Network of Lymphatic vessels following the path of the blood vessels. It drains lymph from PDL into the adjacent alveolar bone.

Nerves

The larger nerve trunks traverse the PDL in the central zone of the tooth's long axis. The nerve fibers are either of large diameter and myelinated concerned with the sensation of touch or be small diameter may or may not be myelinated concerned with pain. Pressure receptors are located among principal fibers of the ligament. Autonomic nerve fibers are associated with blood vessels.

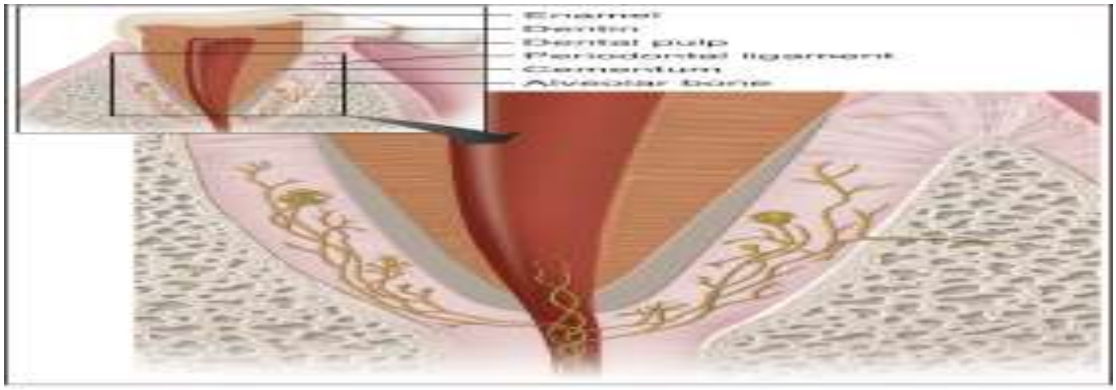

Cementicales

These are calcified bodies found in PDL seen in older individual, they may remain free in C.T. or they may fuse into large calcified masses joined with cementum.

Function of the periodontal ligament

1.Supportive

When a tooth is moved in its socket as a result of forces acting on it during mastication or through application of an orthodontic forces, part of the periodontal space will be narrowed and the PDL contained in these areas will be compressed. Other parts of the periodontal space will be widened. The compressed PDL provides support for the loaded tooth and act as a cushion for the displaced tooth.

2.Sensory

The PDL is supplied with abundant receptors and nerves that sense any movement in function when the receptors sense pressure the nerve send signals to the brain to inform the masticatory apparatus, including the temporomandibular joint and muscles of mastication.

3.Nutritive

The blood vessels of the ligament provide the essential nutrient for the ligaments' vitality and the heart tissue of the cementum and bone. All cells require nutrition which is carried by the blood vessels to the ligament and also the blood vessels are concerned with the removal of catabolite.

4.Homeostatic

It is evident that the cells of the PDL have the capacity to resorb and synthesize the extracellular substance of the C.T. of the ligament, alveolar bone and cementum. Alveolar bone appears to be resorbed and replaced (remodeled) at a rate higher than other bone tissue in the jaws. Furthermore, the collagen of the PDL is turned over at a rate that may be fastest of all C.T. in the body.