ORTHODONTICS

د.عاصم عباس

Lec. 3 & 4

Cephalometrics

Definition:

Cephalometry is the analysis and interpretation of standardized radiographs of the facial bones. In practice cephalometries has come to be associated with a true lateral view (Fig. 1).

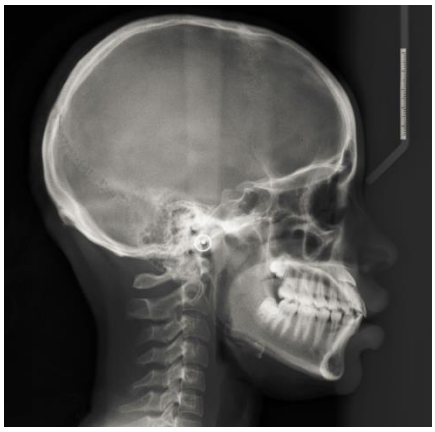

Fig. 1: Lateral cephalometric radiograph.

INTRODUCTION

Cephalometric radiography is a standardized method of production of skull radiographs, which are useful in making measurements of the cranium and the orofacial complex. The radiograph thus obtained is called a cephalogram.

For many years anatomists and anthropologists were confined to measuring the craniofacial dimensions of skulls of dead individuals. This was not possible in case of living individuals, where the varying thickness of soft tissues interfered with the accuracy of these measurements. With the advent of radiography, an alternative method was provided which enabled the researchers to obtain indirectly but with sufficient accuracy, and convenience the skeletal measurements of the human skull. The reproducibility of these radiographs allowed for a longitudinal serial study of growth of living individuals.

The cephalostat

In order to be able to compare the cephalometric radiographs of one patient taken on different occasions, or those of different individuals, some standardization is necessary. To achieve this aim the cephalostat was developed by B. Holly Broadbent in the period after the First World War (Fig. 2). The cephalostat consists of an X-ray machine which is at a fixed distance from a set of ear posts designed to fit into the patient's external auditory meatus, which also serve to stabilize the patient's head. The position of the head in the vertical axis is standardized by ensuring that the patient's Frankfort plane (for definition see below) is horizontal. This can be done by manually positioning the subject or, alternatively, by placing a mirror some distance away level with the patient's head and asking him or her to look into their own eyes. This is termed the natural head position.



Fig. 2: Cephalostat.

For standardization purposes the distances from the tube to the patient is usually set between 5 and 6 feet (1.5 to 1.8 m) and from the patient to the film is usually set around 1 foot (around 30 cm), but despite of that some magnification (usually of the order of 7-8 per cent) is inevitable with a lateral cephalometric film. In order to be able to check the magnification and thus the comparability of different films, it is helpful if a scale is included in the view.

Indications and uses of cephalometrics:

1. An aid to diagnosis:

It is possible to carry out successful orthodontic treatment without taking a cephalometric radiograph, particularly in Class I malocclusions. However, the information that cephalometric analysis yields is helpful in assessing the probable aetiology of a malocclusion and in planning treatment. A lateral cephalometric

radiograph is best limited to patients with a skeletal discrepancy and/or where anteroposterior movement of the incisors is planned. In addition, a lateral view is often helpful in the accurate localization of unerupted displaced teeth and other pathology.

2. A pre-treatment record:
A lateral cephalometric radiograph is useful in providing a baseline record prior to the placement of appliances, particularly where movement of the upper and lower incisors is planned.

3. Monitoring the progress of treatment:
In the management of severe malocclusions, where tooth movement is occurring in all three planes of space (for example treatments involving functional appliances, or upper and lower fixed appliances), it is common practice to take a lateral cephalometric radiograph during treatment to monitor incisor inclinations and anchorage requirements. A lateral cephalometric radiograph may also be useful in monitoring the movement of unerupted teeth and is the most accurate view for assessing upper incisor root resorption if this is felt to be a significant risk during treatment.

4. Research purposes:
Views which are taken routinely during the course of orthodontic diagnosis and treatment can be used to study the effects of growth and treatment.

Evaluating a cephalometric radiograph
Before starting a tracing it is important to examine the radiograph for any abnormalities or pathology. For example, a pituitary tumour could result in an increase in the size of the sella turcica. A lateral cephalometric view is also helpful in assessing the patency of the airway, as enlarged adenoids can be easily seen.

Hand tracing:
The tracing should be carried out in a darkened room on a light viewing box. Proprietary acetate sheets are the best medium as their transparency facilitates landmark identification. The acetate sheet should be secured onto the film with masking tape. For landmarks which are bilateral (unless they are directly superimposed) an average of the two should be taken. Tracing is best done using a propelling pencil.

Digitizing:

For digital radiographs the points can be entered directly by a mouse click. Specialized software can then be employed to utilize the information entered to produce a tracing and/or the analysis of choice (fig. 3). Studies have shown digitizers to be as accurate as tracing a radiograph by hand. Clearly, this approach is particularly useful for research as any number of radiographs can be entered, superimposed, and/or compared statistically.

Fig. 3: easyceph® computer software for cephalometric tracing.

Commonly used cephalometric points:

A point (A): this is the point of deepest concavity on the anterior profile of the maxilla. It is also called subspinale. This point is taken to represent the anterior limit of the maxilla and is often tricky to locate accurately. However, tracing the outline of the root of the upper central incisor first and shielding all extraneous light often aids identification. The A point is located on alveolar bone and is liable to changes in position with tooth movement and growth.

Anterior nasal spine (ANS): this is the tip of the anterior process of the maxilla and is situated at the lower margin of the nasal aperture.

B point (B): the point of deepest concavity on the anterior surface of the mandibular symphysis. The B point is also sited on alveolar bone and can alter with tooth movement and growth.

Gonion (Go): the most posterior inferior point on the angle of the symphysis. This point can be 'guesstimated', or determined more accurately by bisecting the angle formed by the tangents from the posterior border of the ramus and the inferior border of the mandible.

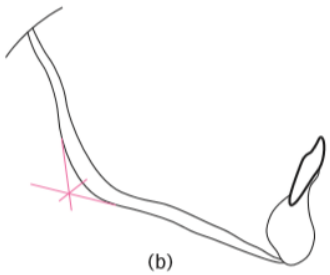

Menton (Me): the lowest point on the mandibular symphysis.

Nasion (N): the most anterior point on the frontonasal suture. When difficulty is experienced locating nasion, the point of deepest concavity at the intersection of the frontal and nasal bones can be used instead.

Orbitale (Or): the most inferior anterior point on the margin of the orbit. By definition, the left orbital margin should be used to locate this point. However, this can be a little tricky to determine radiographically, and so an average of the two images of left and right is usually taken.

Pogonion (Pog): the most anterior point on the mandibular symphysis.

Porion (Po): the uppermost outermost point on the bony external auditory meatus. This landmark can be obscured by the ear posts of the cephalostat, and some advocate tracing these instead. However, this is not recommended as they do not approximate to the position of the external auditory meatus. The uppermost surface of the condylar head is at the same level, and this can be used as a guide where difficulty is experienced in determining porion.

Posterior nasal spine (PNS): this is the tip of the posterior nasal spine of the maxilla. This point is often obscured by the developing third molars, but lies directly below the pterygomaxillary fissure.

Sella (S): the midpoint of the sella turcica.

Commonly used cephalometric reference lines and planes:

SN line: this line, connecting the midpoint of sella turcica with nasion, is taken to represent the cranial base.

Frankfort plane: this is the line joining porion and orbitale. This plane is difficult to define accurately because of the problems inherent in determining orbitale and porion.

Mandibular plane: The line joining gonion and menton. This is only one of several definitions of the mandibular plane, but is probably the most widely used.

Maxillary plane: the line joining anterior nasal spine with posterior nasal spine. Where it is difficult to determine ANS and PNS accurately, a line parallel to the nasal floor can be used instead.

Functional occlusal plane: a line drawn between the cusp tips of the permanent molars and premolars (or deciduous molars in mixed dentition). It can be difficult to decide where to draw this line, particularly if there is an increased curve of Spee, or only the first permanent molars are in occlusion during the transition from mixed to permanent dentition. The functional plane can change orientation with growth and/or treatment.

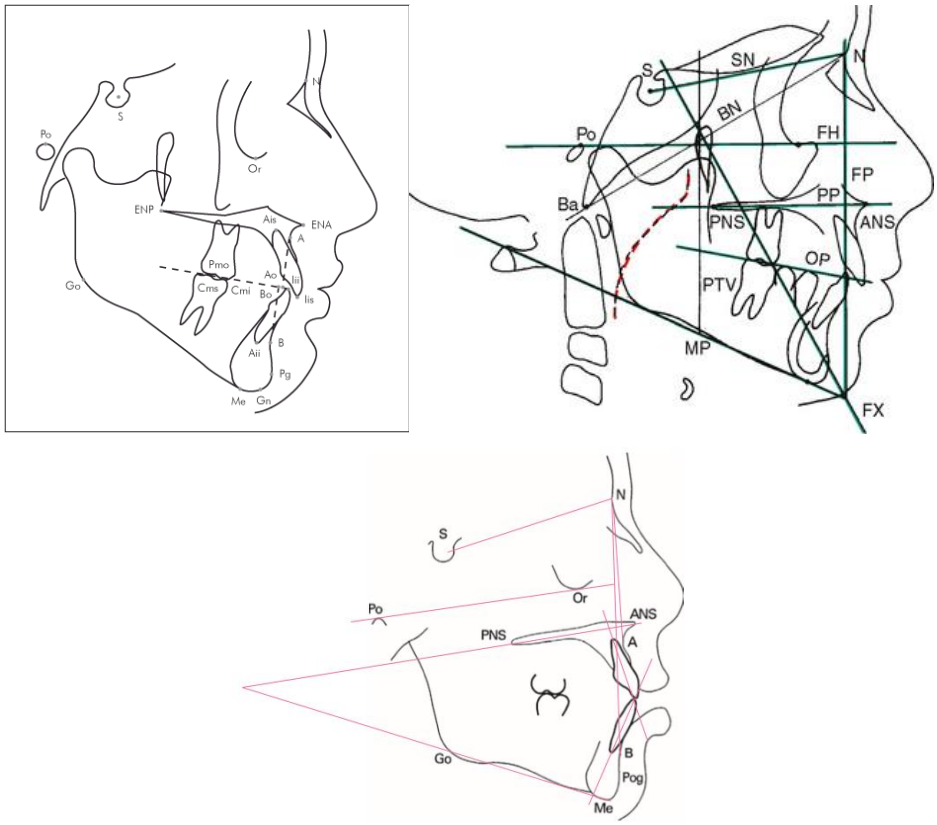

Fig. 4: commely used ceph. Points and lines (planes).

Anteroposterior skeletal pattern:

Angle ANB:

In order to be able to compare the position of the maxilla and mandible, it is necessary to have a fixed point or plane. The skeletal pattern is often determined cephalometrically by comparing the relationship of the maxilla and mandible with the cranial base by means of angles SNA (81°± 3°) and SNB (78° ± 3°) (fig. 5). The difference between these two measurements, angle ANB (3° ± 2°), is classified broadly as follows:

ANB < 2°	Class Ill
2° < ANB < 4°	Class I
ANB > 4°	Class II

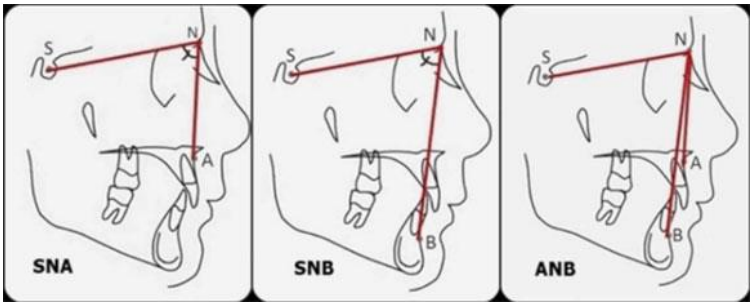

Fig. 5: SNA, SNB and ANB.

Vertical skeletal pattern (fig. 6)**:**

1. The Maxillary-Mandibular Planes Angle (MMPA): The average angle between the maxillary plane and the mandibular plane. MMPA is 27 + 4°.

2. The Frankfort-mandibular planes Angle (FMPA): Some analyses measure this angle instead of the MMPA. However, the maxillary plane is easier to locate accurately and therefore the MMPA is preferred. FMPA is 28 + 4°.

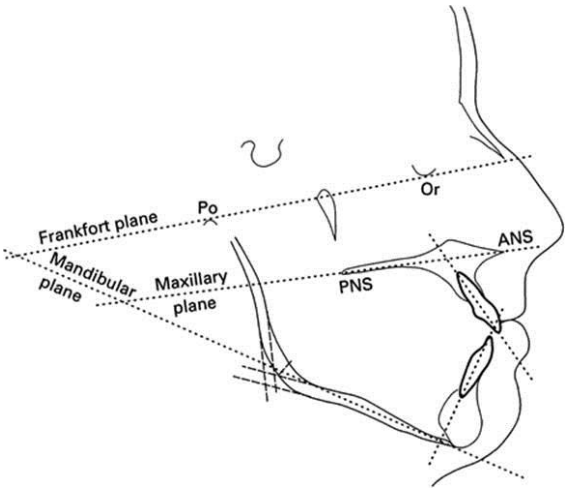

Fig. 6: MMPA and FMPA.

3. Anterior and posterior face heights:

Anterior and posterior face heights are also used as a measure of vertical facial relationships (Fig. 7):

• **Total anterior face height (TAFH):** extends from nasion to menton, with both lines constructed perpendicular to the maxillary plane (mean 119 mm in an adult male).

TAFH is further subdivided into:

a. **Upper anterior face height (UAFH):** nasion to maxillary plane (mean 54 mm).

b. **Lower anterior face height (LAFH):** maxillary plane to menton (mean 65 mm).

The LAFH should be approximately 55% of the TAFH.

• **Total posterior face height (TPFH):** extends from sella to gonion, with both lines constructed perpendicular to the maxillary plane (mean 79 mm in an adult male).

TPFH is therefore subdivided into:

a. Upper posterior face height (UPFH): sella to maxillary plane (mean 46 mm).

b. Lower posterior face height (LPFH): maxillary plane to gonion (mean 33 mm).

The TPFH should be approximately 65% of the TAFH.

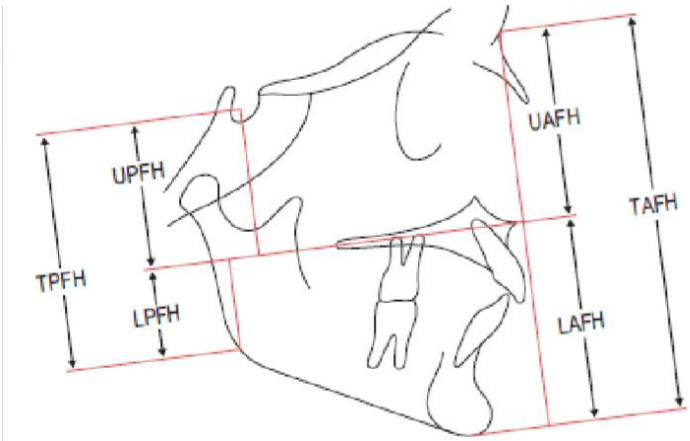

Fig. 7: Anterior and posterior facial heights.

Incisor position (Fig. 8)**:**

1. Maxillary incisor relationship:

The inclination of the most prominent maxillary incisor is constructed using a line through long axis of upper incisor and measured in relation to the maxillary plane. The mean value is 109° ± 6°.

2. Mandibular incisor relationship:

The inclination of the most prominent mandibular incisor is constructed using a line through long axis of lower incisor and measured in relation to the mandibular plane. The mean value is 93° ± 6°.

3. Inter-incisal angle:

The inter-incisal angle is the angle formed between the most prominent maxillary and mandibular incisors. The mean value is 135° ± 10°.

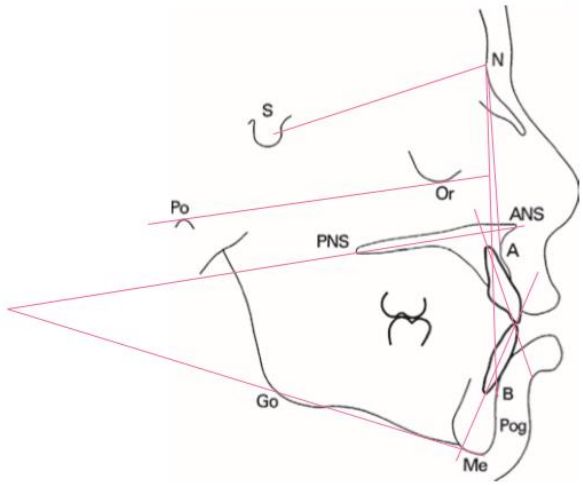

Fig. 8: Maxillary incisor relationship, Mandibular incisor relationship and Inter-incisal angle.

Good luck