CARDIOVASCULAR SYSTEM 1

by
Dr. Nahidah Ibraheim

College of pharmacy /Dep. Clinical laboratory Science

stage 1

Date:21/11/2020

CARDIOVASCULAR SYSTEM 1

By the end of this lecture, students are expected to:

1. List and describe the layers of the hart.
2. Outline the histological features of the pericardium.
3. Outline the different types of epithelium simple squamous cells found in heart.
4. Summarize the functional and histological structure of Purkinje fibres.

The circulatory system pumps and directs blood cells and substances carried in blood to all tissues of the body. It includes both the blood and lymphatic vascular systems, and in an adult the total length of its vessels is estimated at between 100,000 and 150,000 kilometers.

This system consists of the heart, major arteries, arterioles, capillaries, venules, and veins.

The main function of this system is to deliver oxygenated blood to cells and tissues and to return venous blood to the lungs for gaseous exchange

1- heart :

The heart is a modified blood vessel that serves as a double pump and consists of four chambers. On the right side, the atrium receives blood from the body and the ventricle propels it to the lungs The left atrium receives blood from the lungs and passes it to the left ventricle, from which it is distributed throughoutthe body. The wall of the heart consists of an lining layer (**endocardium**), a middle muscular layer (**myocardium**),and an external layer of connective tissue. (**epicardium**).

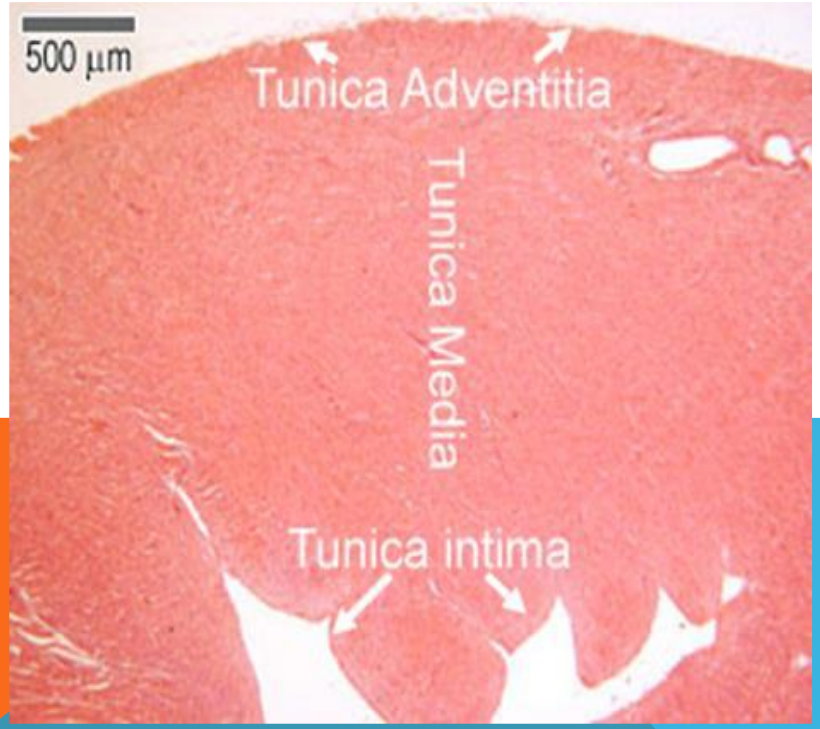

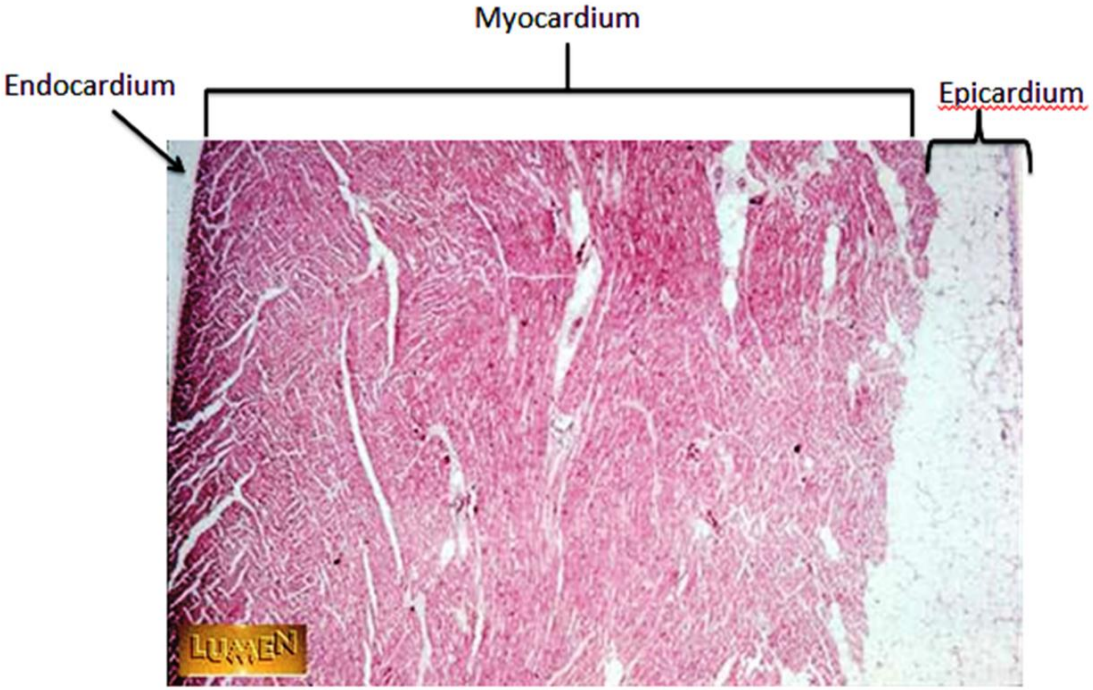

1-ENDOCARDIUM :

The endocardium forms the inner lining of the atria and ventricles and is continuous with and comparable to the inner lining of blood vessels. It consists of a single layer of polygonal squamous (endothelial) cells with oval or rounded nuclei .The endothelial cells rest on a continuous layer of fine collagen fibers, separated from it by a basement membrane.The fibrous layer is called the subendothelial layer.

Deep to it is a thick layer of denser connective tissue hat forms the bulk of the endocardium and contains elastic fibers and some smooth muscle cells. a loose connective tissue constituting the subendocardial layer binds the endocardium to the underlying heart muscle and contains collagen fibers, elastic fibers, and blood vessels. In the ventricles it also contains the specialized cardiac muscle fibers of the conducting system (purkinje fibers).

PURKINJE FIBERS

Purkinje fibers are thicker and larger than cardiac muscle fibers and contain a greater amount of glycogen. They also contain fewer contractilefilaments. Purkinje fibers are part of the conduction system of the heart. These fibers are located beneath the endocardium on either side of the interventricular septum and are recognized as separate tracts. Because Purkinje fibers branch throughout the myocardium, they deliver continuous waves of stimulation from the atrial nodes to the rest of the heart musculature via the gap junctions. This produces ventricular contractions (systole) and ejection of blood from both ventricular chambers.

PURKINJE FIBERS

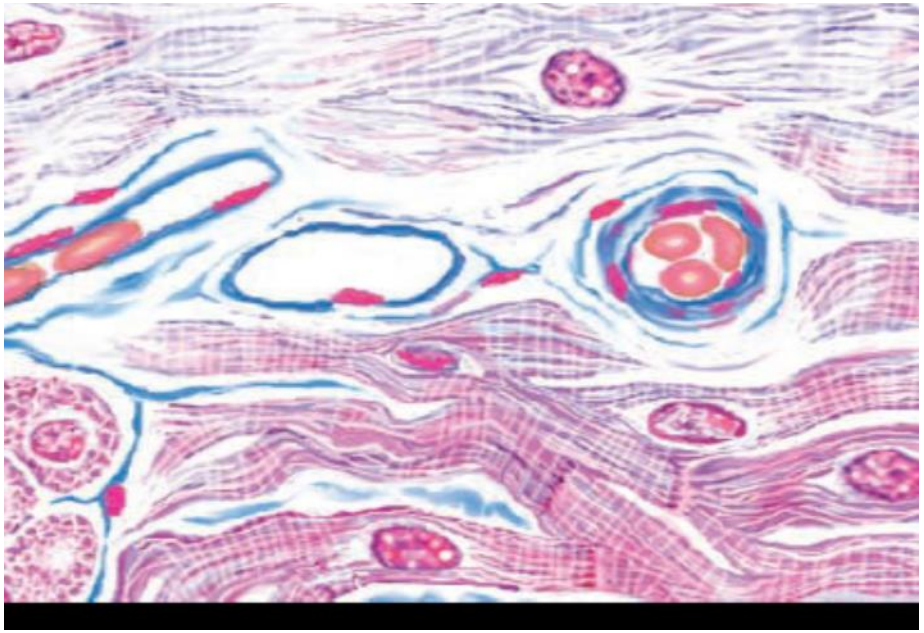

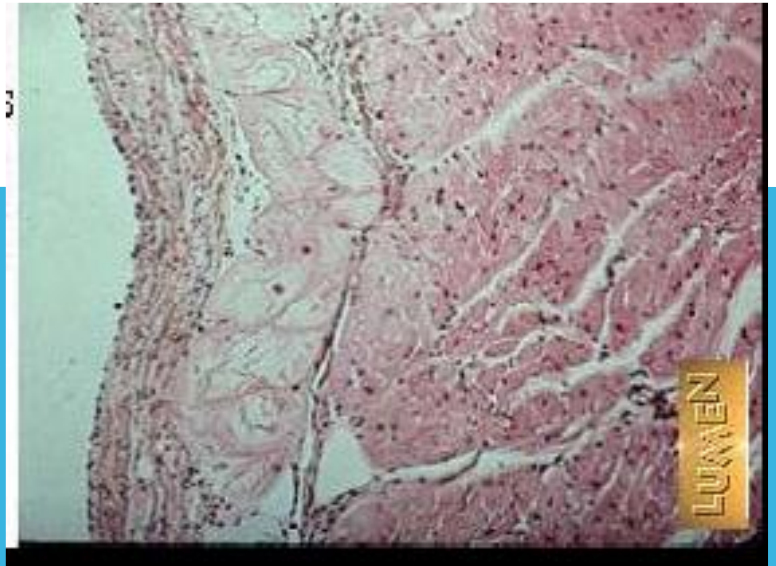

2-MYOCARDIUM

The myocardium is the middle layer of the heart and consists primarily of cardiac muscle. The myocardium is a very vascular tissue. The myocardium is the thinnest in the atria and thickest in the left ventricle. It consist of cardiac muscle cells = myocytes .Different from smooth or skeletal muscle cells due to placement of nuclei, cross striations, and intercalated disks. Intercalated disks Junctional complexes that contain fascia adherens, desmosomes, and gap junction to provide connection and communication. Bind myocytes and allow ion exchange to *facilitate* electrical impulses to pass.

The capillaries completely surround individual cardiac myocytes and are held in close apposition to them by the enveloping delicate connective tissue that occurs between individual muscle cells. The myocardium is arranged in layers that form complex spirals about the atria and ventricles. In the atria, the cardiac muscle cells are smaller and contain a number of dense granules not seen elsewhere in the heart. These myocytes have properties associated with endocrine cells. They are most numerous in the right atrium and release the secretory granules when stretched

MYOCARDIUM

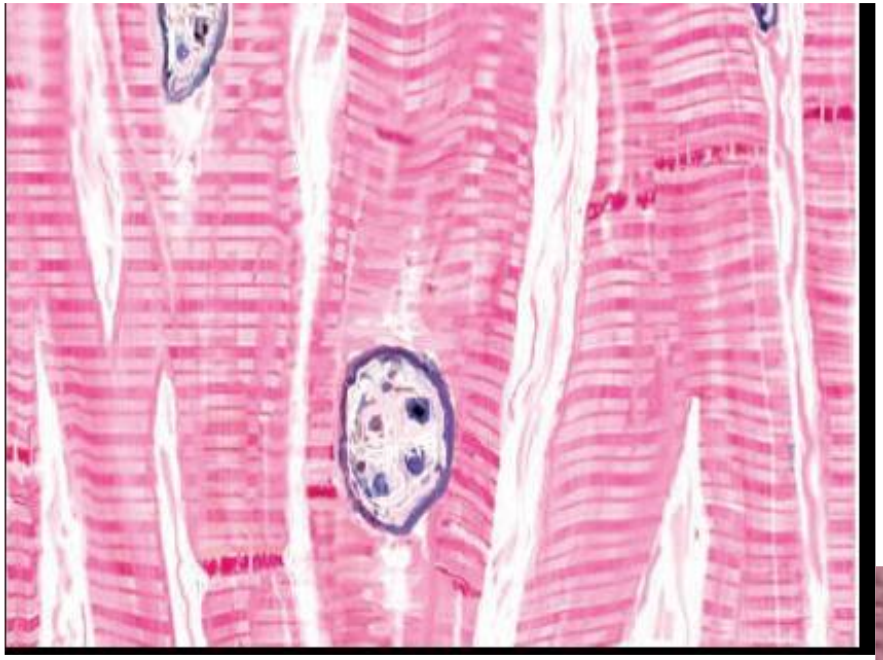

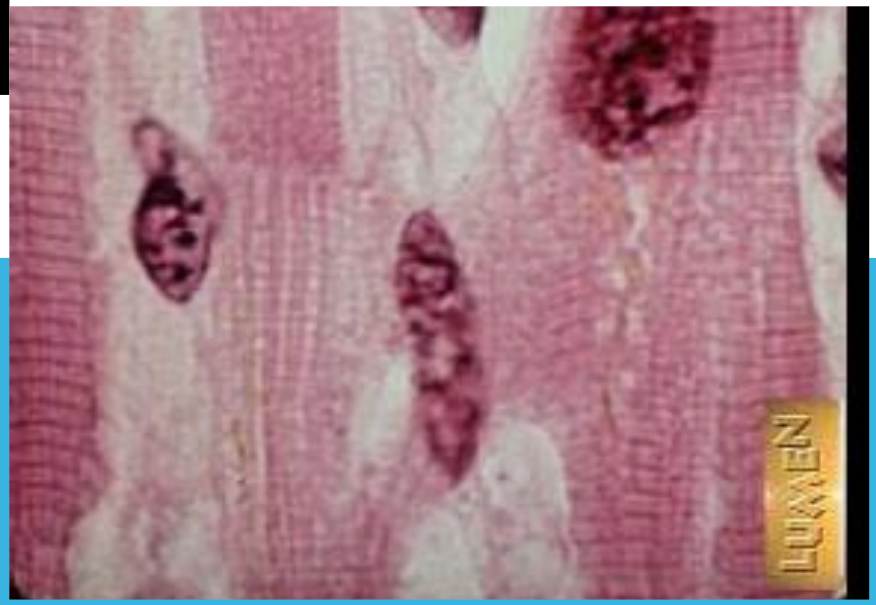

Atrial Natriuretic Hormone

Certain cardiac muscle fibers in the atria exhibit dense granules in their cytoplasm. These granules contain **atrial natriuretic hormone**, a chemical that is released in response to atrial distension or stretching. The main function of this hormone is to decrease blood pressure by regulating blood volume. This action is accomplished by inhibiting the release of renin by the specialized cells in the kidney and aldosterone from the adrenal gland cortex. This induces the kidney to lose more sodium and water (diuresis).As a result, the blood volume and blood pressure are reduced, and the distension of the atrial wall is relieved.

Gap junctions:

functionally couple all cardiac muscle fibers to rapidly spread the stimuli for contraction of the heart muscle.

EPICARDIUM

The epicardium is a simple squamous mesothelium supported by a layer of loose connective tissue containing blood vessels and nerves . The epicardium corresponds to the visceral layer of the pericardium, the membrane surrounding the heart. Where the large vessels enter and leave the heart, the epicardium is reflected back as the parietal layer lining the pericardium.

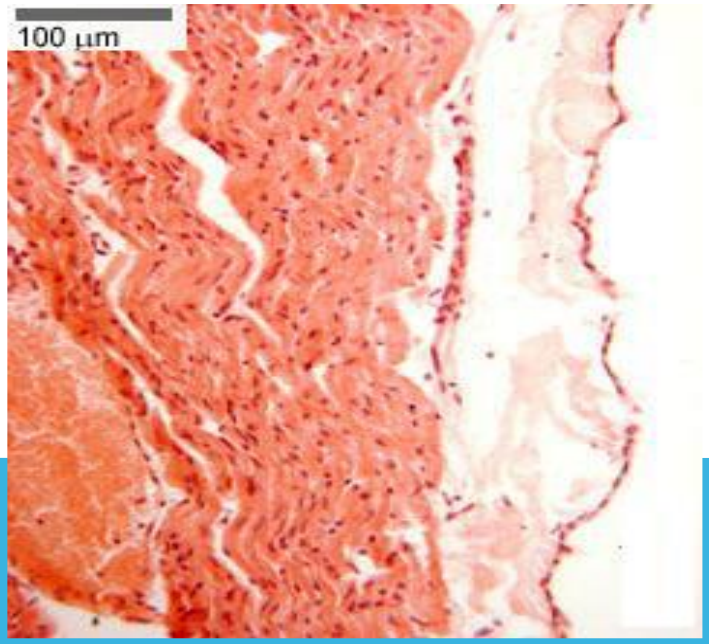

Tunica Adventitia (Epicardium)

HEART IMPULS

First, impulses are generated by the sinoatrial node (SA), which is found in the wall of the superior vena cava. It is a small mass of specialized cardiac muscle fibers and associated connective tissue, and is supplied by nerve fibers from the autonomic nervous system, excitation of the SA node sets of a wave of depolarization around the atria via gap junctions between the muscle fibers, next the atrioventricular node (AV) starts impulse generation around the ventricles , the AV node lies in the interatrial septum, impulses are sent from the AV node into the AV bundle, or bundle of his, which branches to form Purkinje fibers, the AV node is also supplied by nerve fibers from the autonomic nervous system that speed up and slow down the heart rate.

Purkinje fibers lie in the deepest layer of the endocardium and supply the papillary muscles. Hence the apex of the heart contracts first, followed by the papillary muscles, and then the wave of depolarization spreads up the walls of the ventricles from the base upwards, as shown in the diagram.

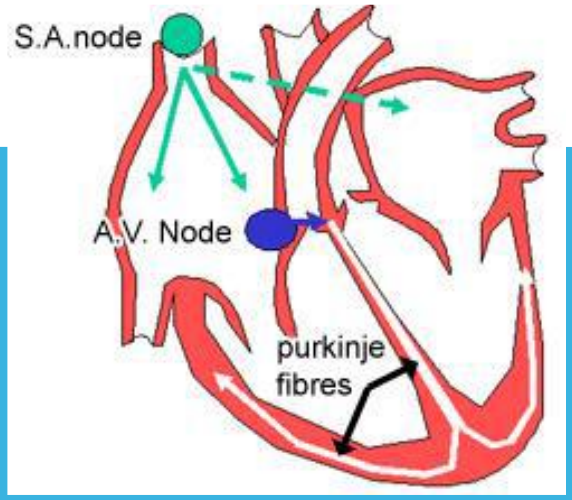

2- BLOOD VESSELS

:

blood vessels differ in size, distribution,and function, structurally they share many common features. As in the heart, the walls of blood vessels consist of three major coats or tunics. From the lumen outward, the wall of a blood

vessel consists of :

1-tunica intima,

2- tunica media, and

3- tunica adventitia

CONT.

1- TUNICA INTIMA :

The tunica intima corresponds to and is continuous with the endocardium of the heart. It consists of an endothelium of flattened squamous cells resting on a basal lamina and is supported by a subendothelial connective tissue.

2- TUNICA MEDIA :

The tunica media is the equivalent of the myocardium of the heart and is the layer most variable both in size and structure. Depending on the function of the vessel, this layer contains variable amounts of smooth muscle and elastic tissue.

3- TUNICA ADVENTITIA :

The tunica adventitia also varies in thickness in different parts of the vascular circuit. It consists mainly of collagenous connective tissue and corresponds to the epicardium of the heart, but it lacks mesothelial cells.

BLOOD VESSEL (ARTERY

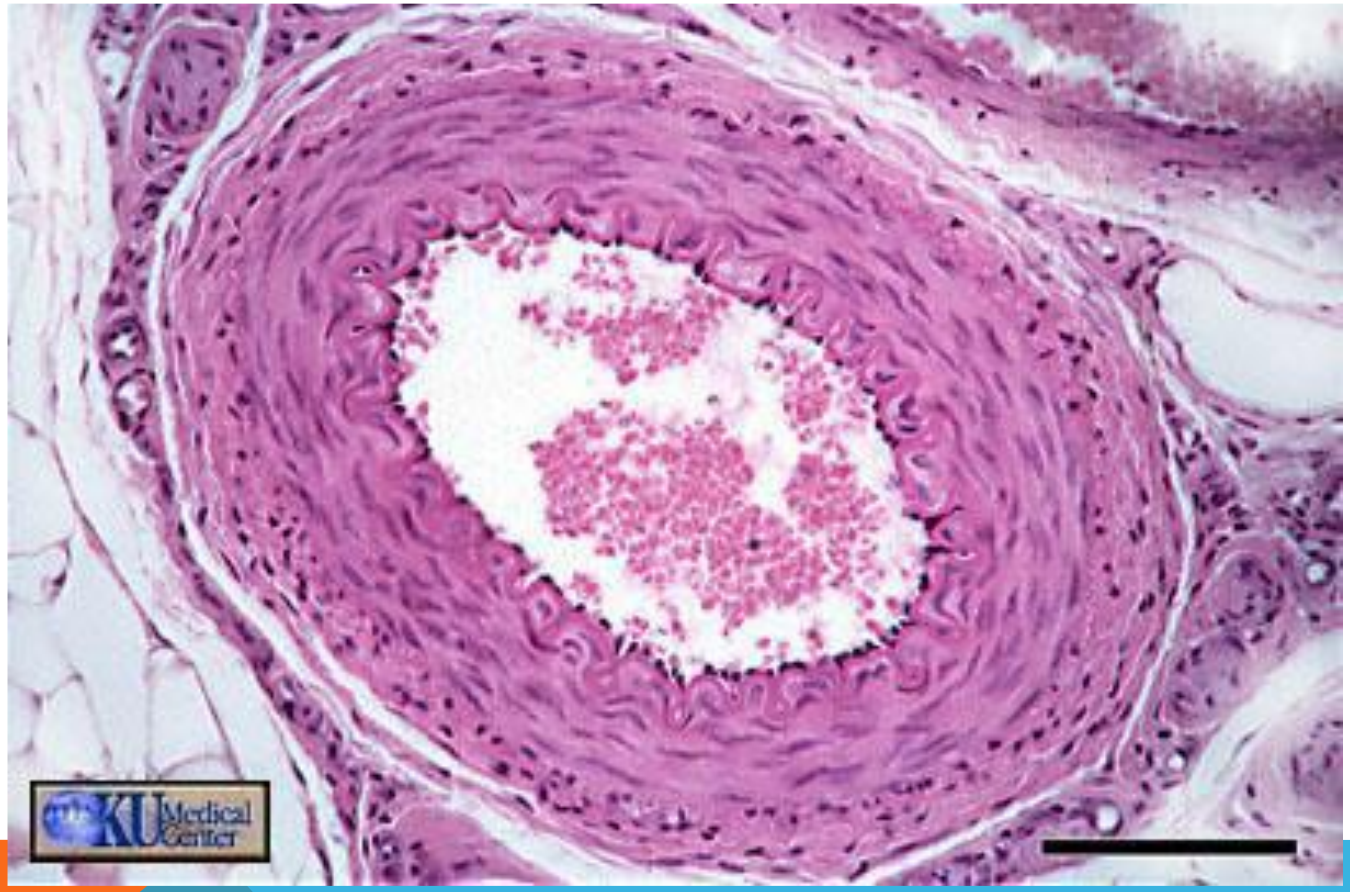

TYPES OF ARTERIES :

Three classes of arteries can be distinguished:

large elastic or conducting arteries,

medium-sized muscular or distributing arteries,

and **small arteries** and **arterioles.**

A characteristic feature of the entire arterial side of the blood vasculature system is the prominence of smooth muscle in the tunica media.

Arteries that leave the heart to distribute the oxygenated blood exhibit progressive branching. With each branching, the luminal diameters of the arteries gradually decrease, until the smallest vessel, the capillary, is formed.

STRUCTURAL PLAN OF ARTERIES

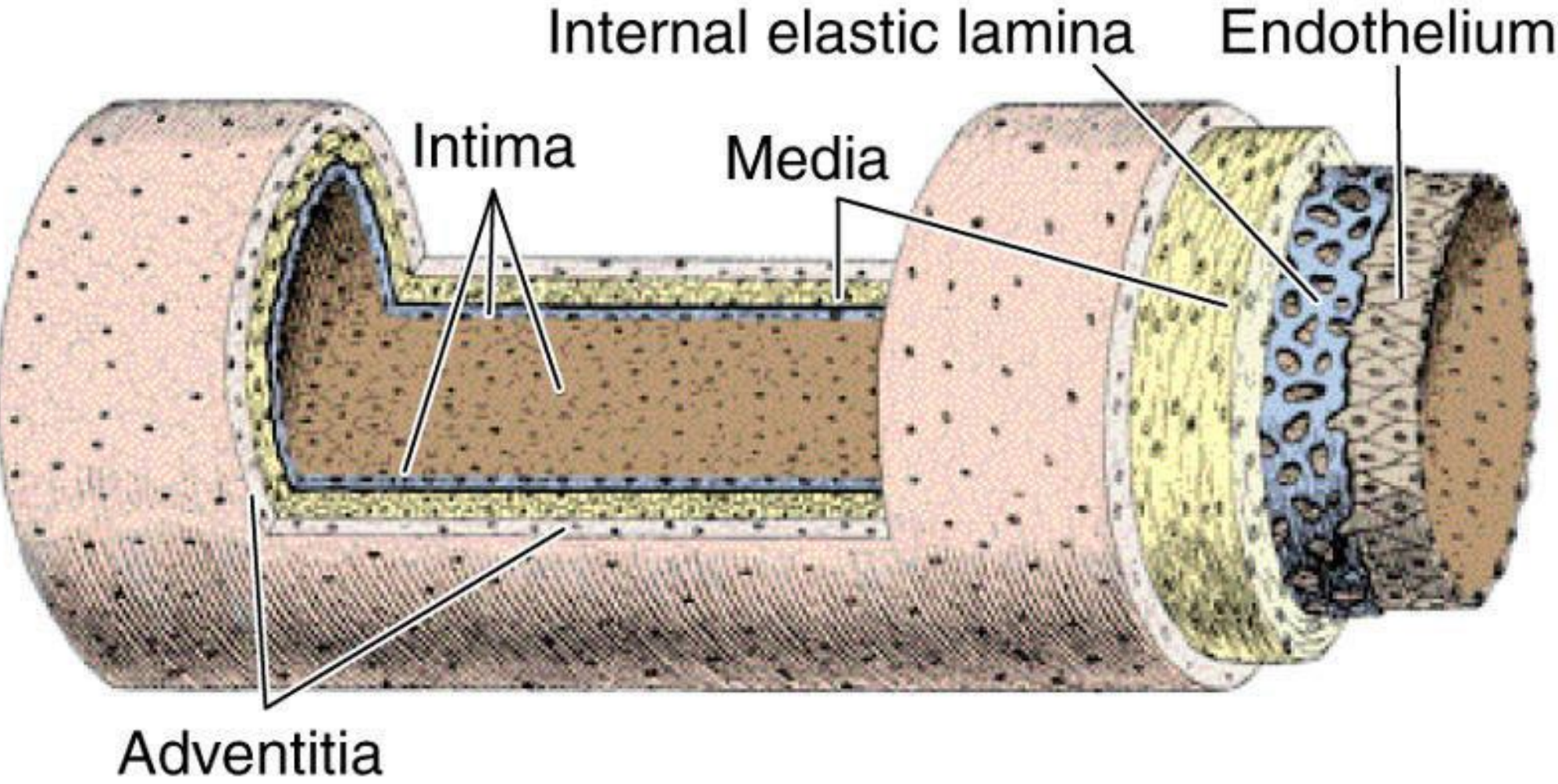

ARTERY

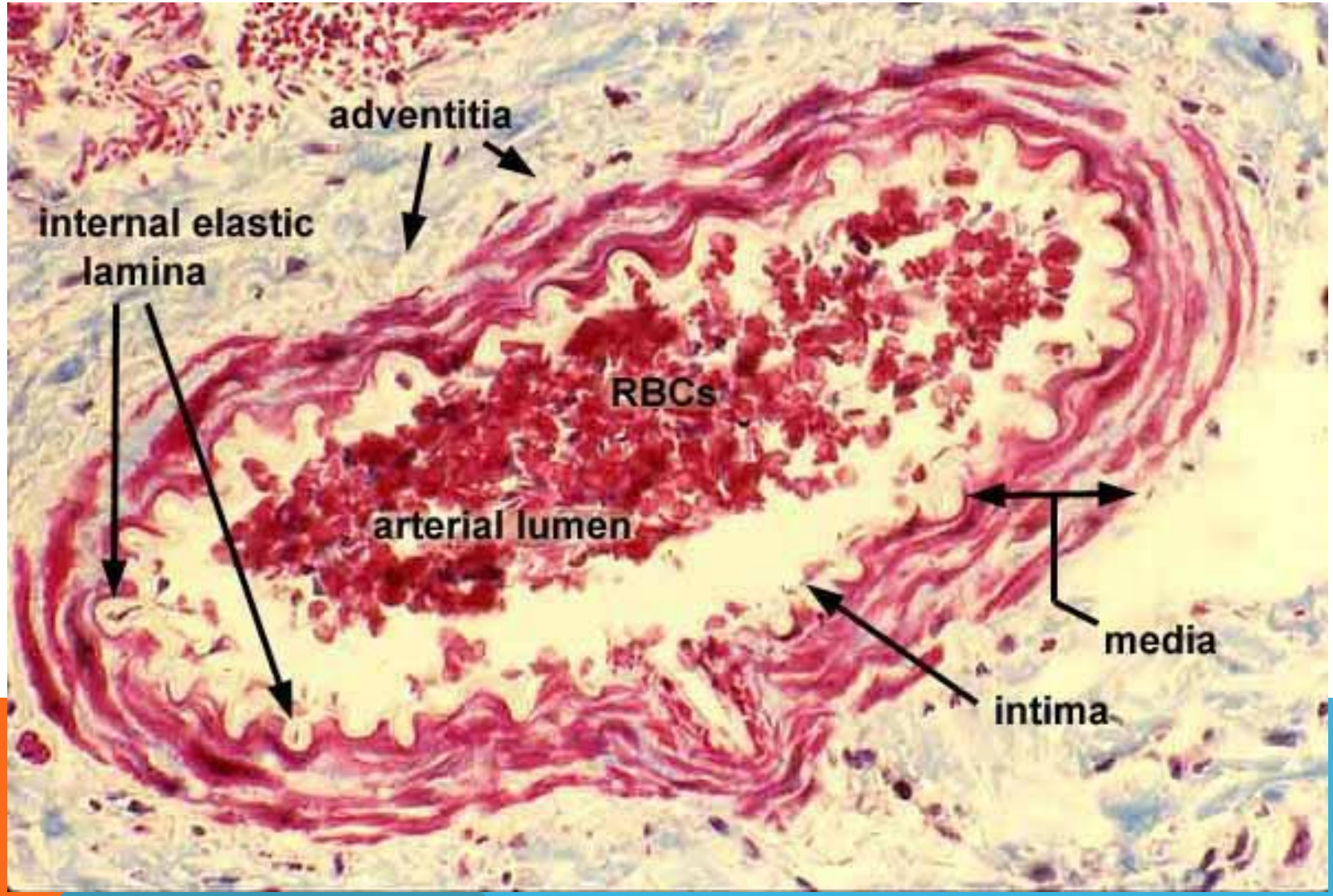
adventitia
internal elastic lamina
RBCs
arterial lumen
media
intima

1- ELASTIC ARTERIES :

Elastic arteries are the largest blood vessels in the body and include the pulmonary trunk and aorta with their major branches, the brachiocephalic, common carotid, subclavian, vertebral, pulmonary, and common iliac arteries. The walls of these vessels are primarily composed of elastic connective tissue fibers. These fibers provide great resilience and flexibility during blood flow.

The tunica intima is relatively thick and is lined by a single layer of flattened, polygonal endothelial cells that rest on a complete basal lamina, about one-fourth of the total thickness of the intima is formed by the subendothelial layer, a layer of loose connective tissue that contains elastic fibers and a few smooth muscle cells

The tunica media is the thickest layer and consists largely of elastic tissue. Smooth muscle cells are the only cells present in the media of elastic arteries and synthesize and maintain the elastic fibers and collagen. The tunica adventitia is relatively thin andcontains bundles of collagen fibers (type 1) and a few elastic fibers,

LARGE ELASTIC ARTERY

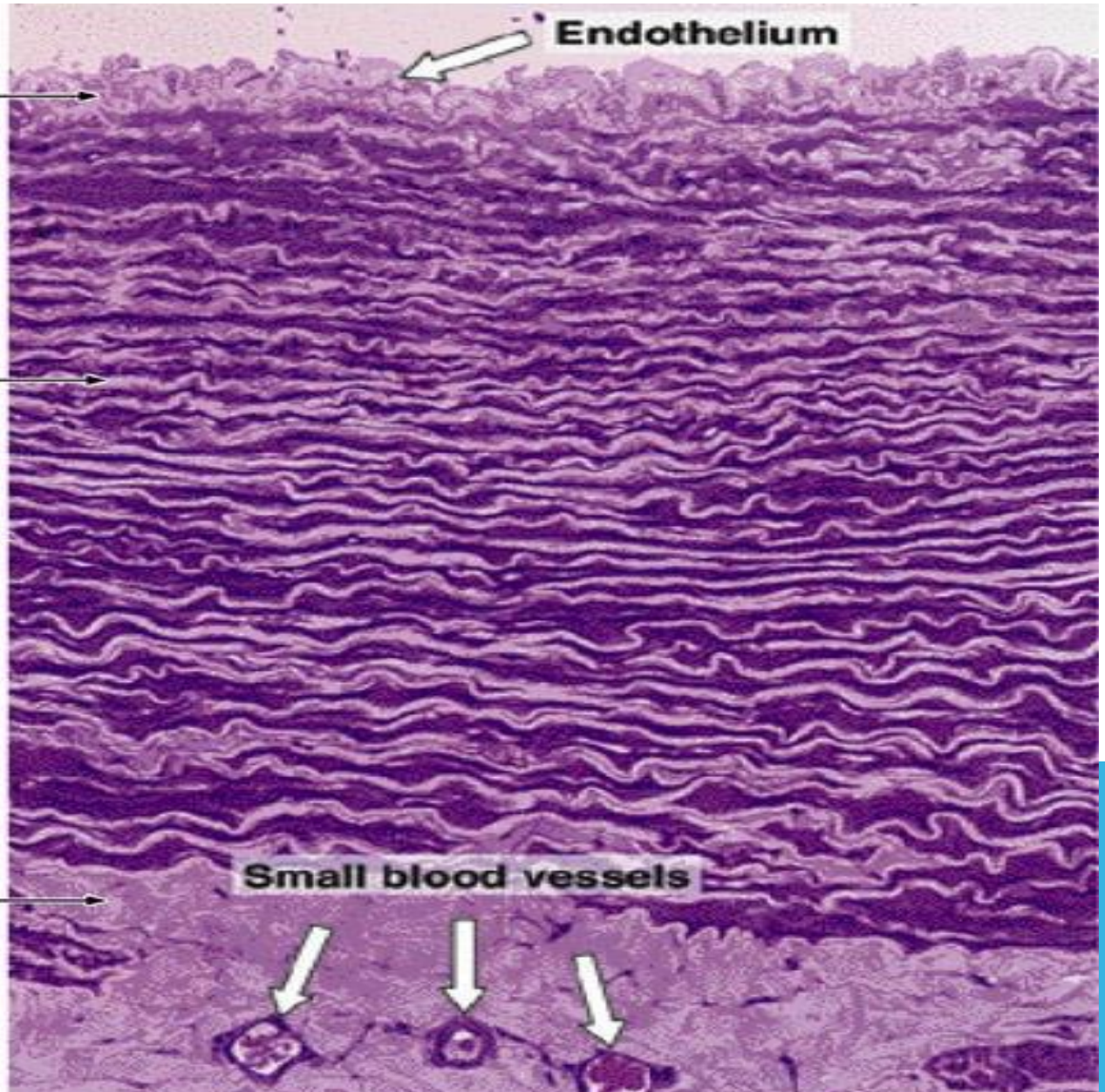

WALL OF A LARGE ELASTIC ARTERY: AORTA

2- MUSCULAR ARTERIES:

The large elastic arteries branch and become medium-sized muscular arteries, the most numerous vessels in the body. In contrast to the walls of elastic arteries, those of muscular arteries contain greater amounts of smooth muscle fibers. The tunica intima consists of an endothelium, a subendothelial layer, and an internal elastic lamina. The endothelium and subendothelial layers are similar to those of elastic arteries, but as the size of the vessel decreases, the subendothelial layer becomes thinner.

The tunica media is the thickest coat and consists mainly of smooth muscle cells arranged in concentric, helical layers. The number of layers varies from 3 to 4 in smaller arteries to 10 to 40 in the large muscular arteries. The tunica adventitia is prominent in muscular arteries and in some vessels may be as thick as the media. It consists of collagen and elastic fibers that are longitudinal in orientation

The walls of some muscular arteries also exhibit two thin, wavy bands of elastic fibers. The internal elastic lamina is located between the tunica intima and the tunica media; this layer is not seen in smaller arteries. The external elastic lamina is located on the periphery of the muscular tunica media and is primarily seen in large muscular arteries.

MUSCULAR ARTERY

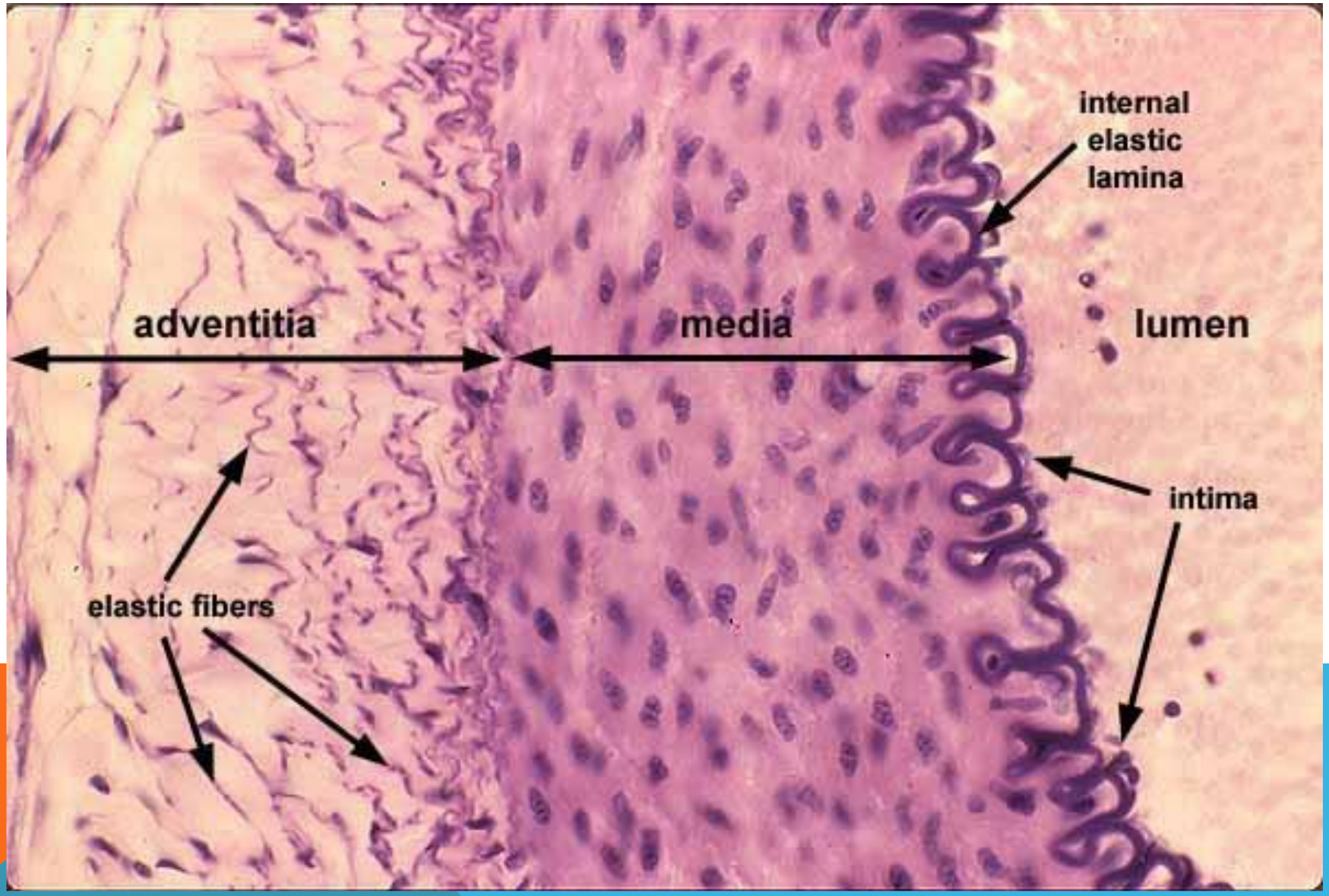

ELASTIC & MUSCULAR ARTERY

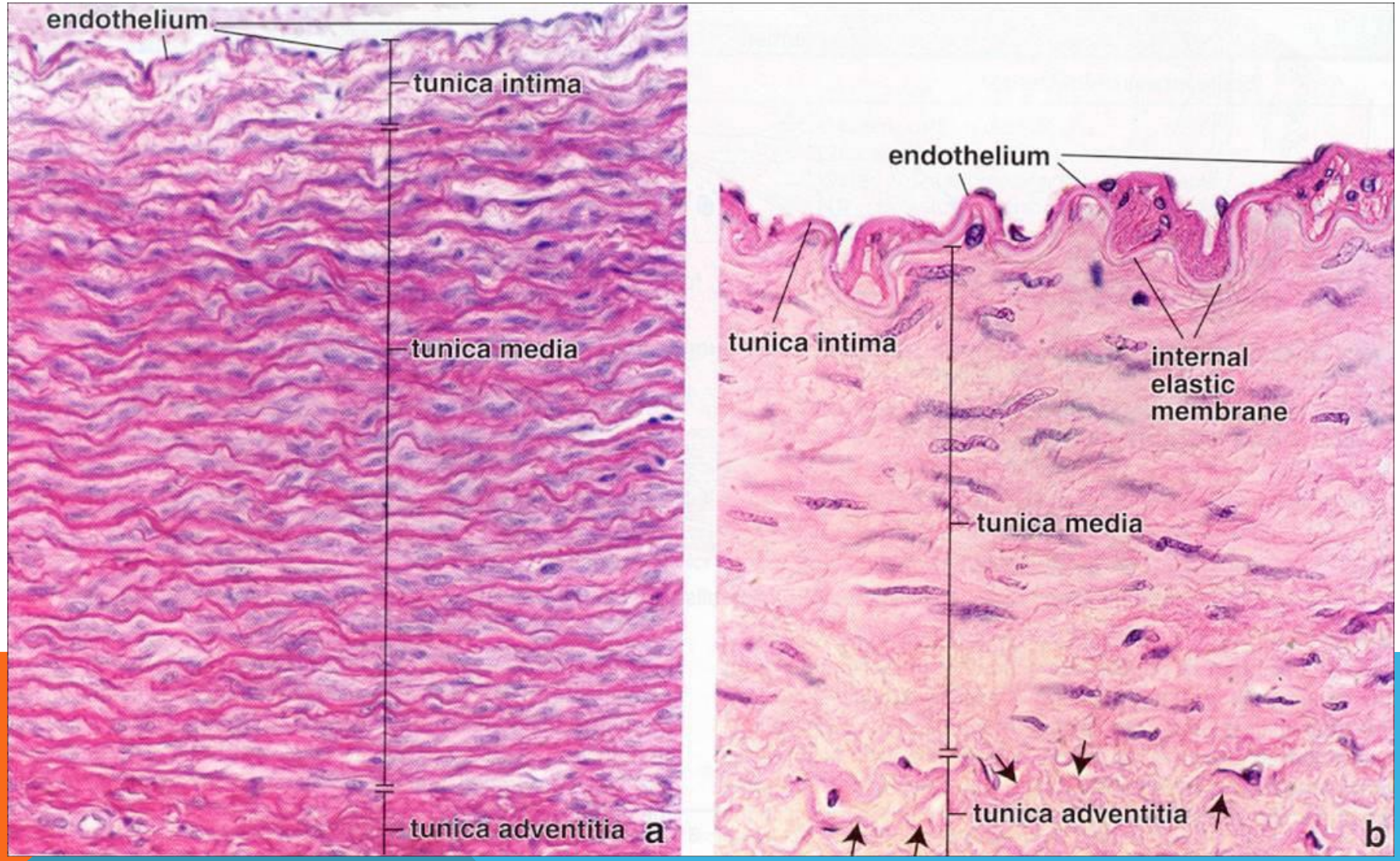

FUNCTIONAL CORRELATIONS :

The elastic arteries transport blood from the heart and move it along the systemic Vascular path. The presence of an increased number of elastic fibers in their walls allows the elastic arteries to greatly expand in diameter during systole (heart contraction), when a large volume of blood is forcefully ejected from the ventricles into their lumina. In contrast, the muscular arteries control blood flow and blood pressure through vasoconstriction or vasodilation of their lumina. Vasoconstriction and vasodilation, owing to a high proportion of smooth muscle fibers in the artery walls, are controlled by unmyelinated axons of thesympathetic division of the autonomic nervous system. Similarly, by autonomic constriction or dilation of their lumina, the smooth muscle fibers in smaller muscular arteries or arterioles regulate blood flow into the capillary beds .

During diastole (heart relaxation), the expanded elastic walls recoil upon the volume of blood in their lumina and force the blood to move forward through the vascular channels. As a result, a less variable systemic blood pressure is maintained, and blood flows more evenly through the body during heart beats.

3- ARTERIOLES :

Arterioles are the smallest branches of the arterial system. Their walls consist of one to five layers of smooth muscle fibers. tunica intima consists only of endothelium and a fenestrated internal elastic lamina. Tunica adventitia also decreases in thickness, becoming extremely thin in the smallest arterioles.

Arterioles deliver blood to the smallest blood vessels, the capillaries. Capillaries connect arterioles with the smallest veins or venules

ARTERIOLE

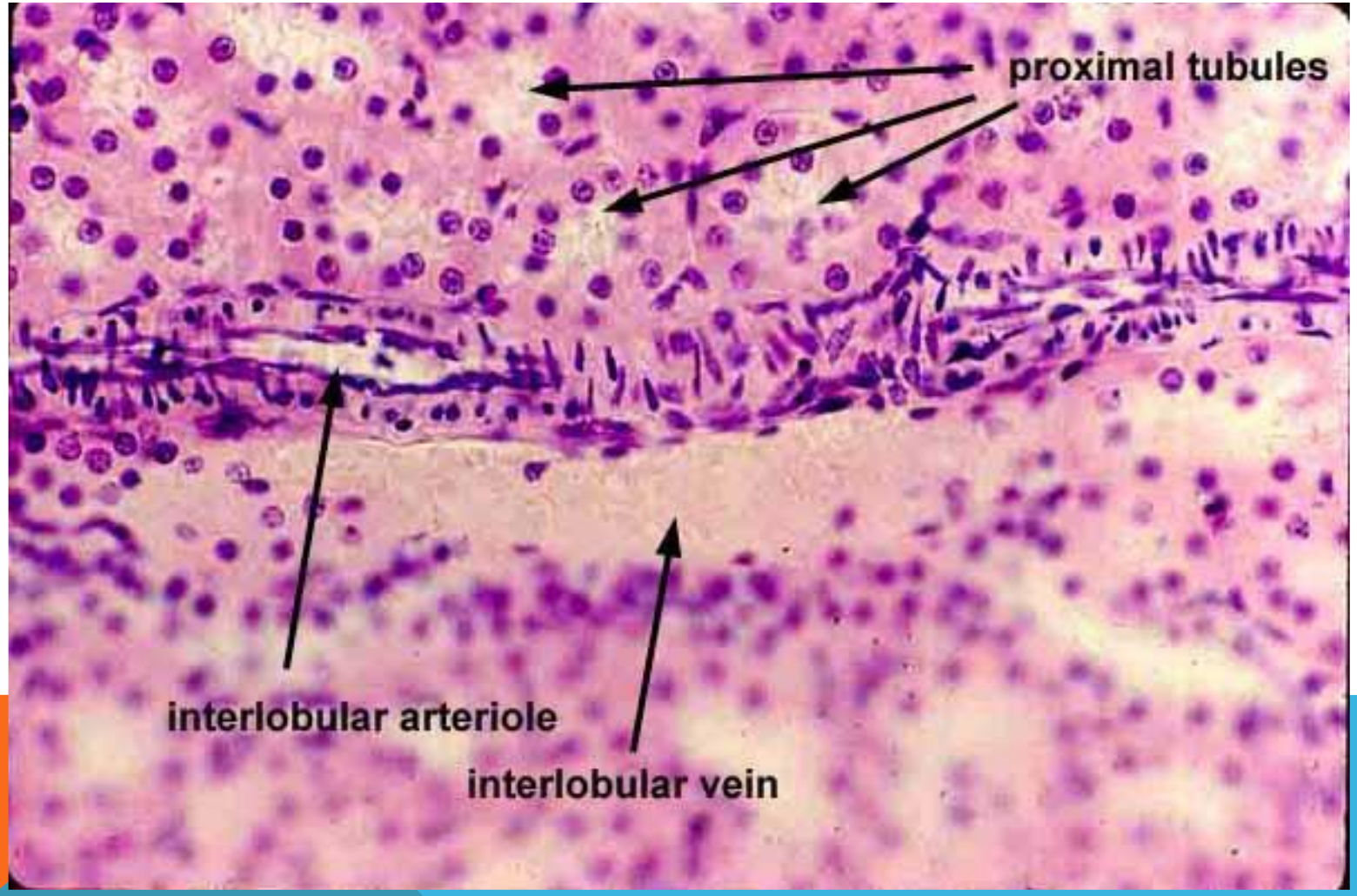
proximal tubules
interlobular arteriole
interlobular vein

SMALL ARTERY &VEIN

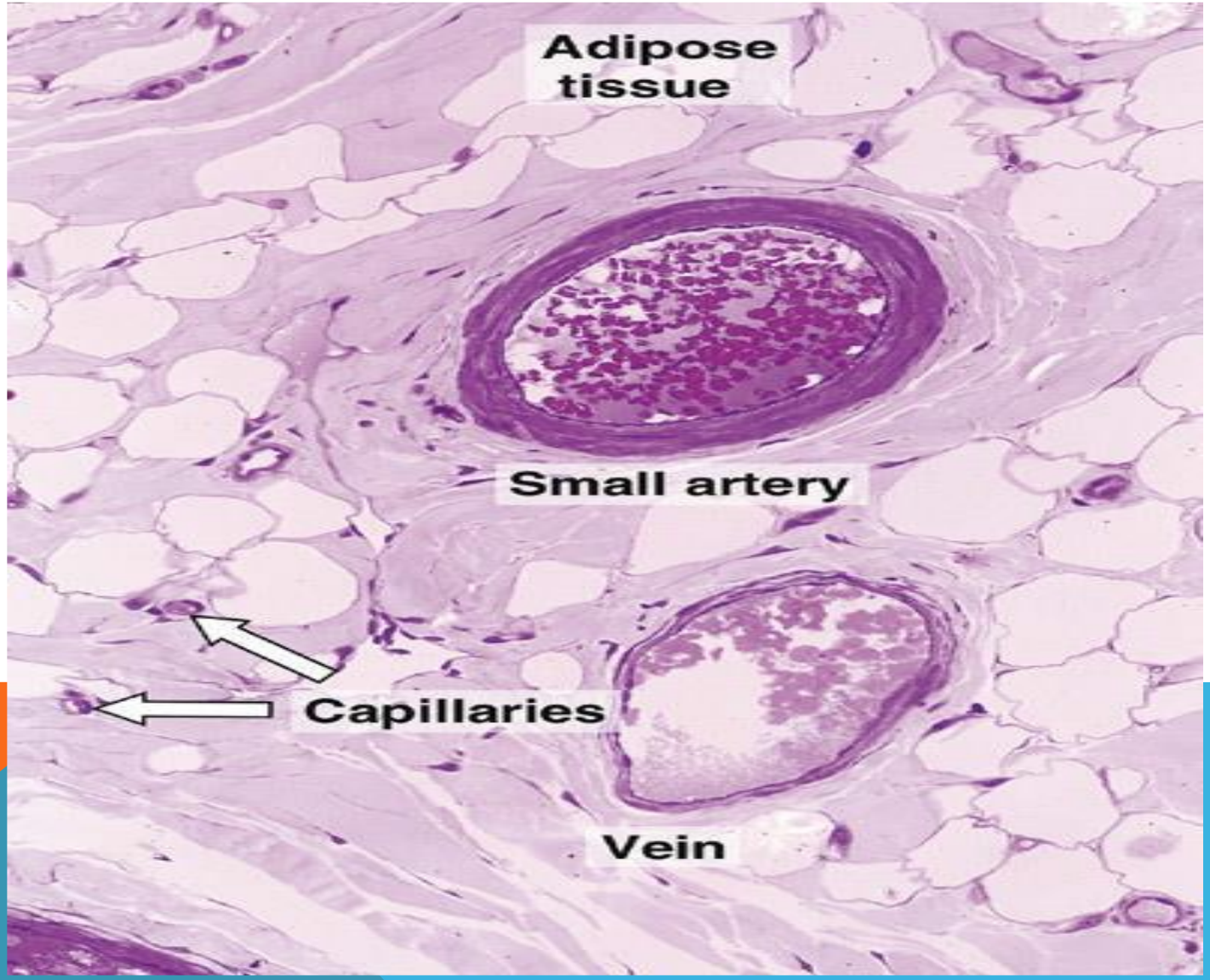

CAPILLARY

Metarterioles are intermediate between capillaries and arterioles and regulate the flow of blood through capillary beds. They also are called capillary sphincter areas or precapillary arterioles,their lumina generally are wider than those of the capillaries .

STRUCTURAL PLAN OF VEINS

Capillaries unite to form larger blood vessels called venules; venules usually accompany arterioles. The venous blood initially flows into smaller postcapillary venules and then into veins of increasing size. The veins are classified as small, medium, and large. Compared with arteries, veins typically are more numerous and have thinner walls, larger diameters, and greater structural variation. Small-sized and medium-sized veins, particularly in the extremities, have valves. The presence of valves in veins assists venous blood flow by preventing back flow. When blood flows toward the heart, pressure in the veins forces the valves to open. As the blood begins to flow backward, the valve flaps close the lumen and prevent back flow of blood. Valves are absent in veins of the central nervous system, the inferior and superior venae cavae, and viscera. The walls of the veins, like the arteries, also exhibit three layers or tunics. However, the muscular layer is much less prominent. The tunica intima in large veins exhibits a prominent endothelium and subendothelial connective tissue. In large veins, the muscular tunica media is thin, and the smooth muscles intermix with connective tissue fibers . In large veins, the tunica adventitia is the thickest and best-developed layer . bundles of smooth muscle fibers are common in the connective tissue of this layer. Vasa vasorum are present and may extend into the Media.

WALL OF A LARGE VEIN: PORTAL VEIN

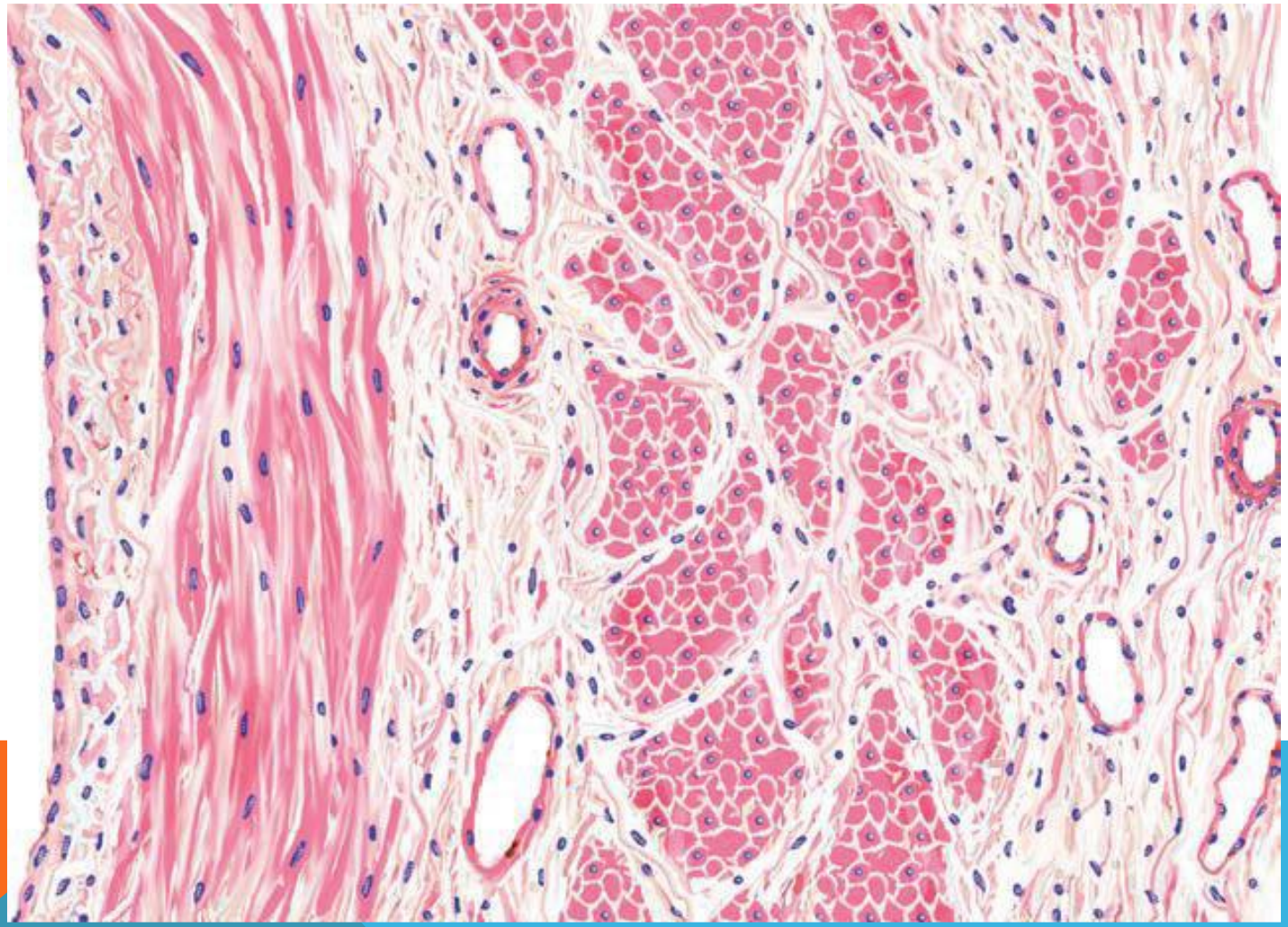

ARTERY &VEIN

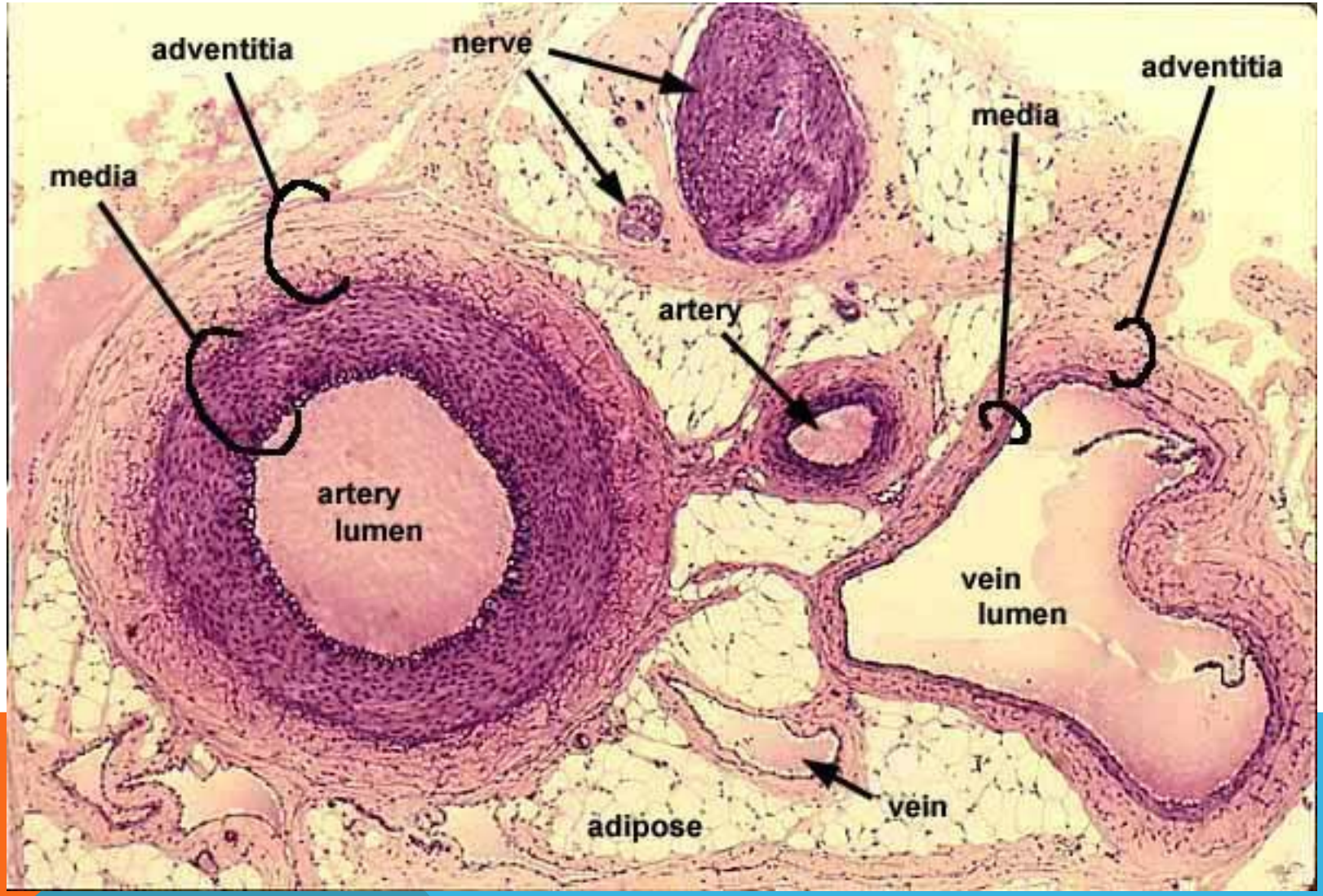
adventitia
nerve
adventitia
media
media
artery
artery
lumen
vein
lumen
vein
adipose

ARTERY &VEIN

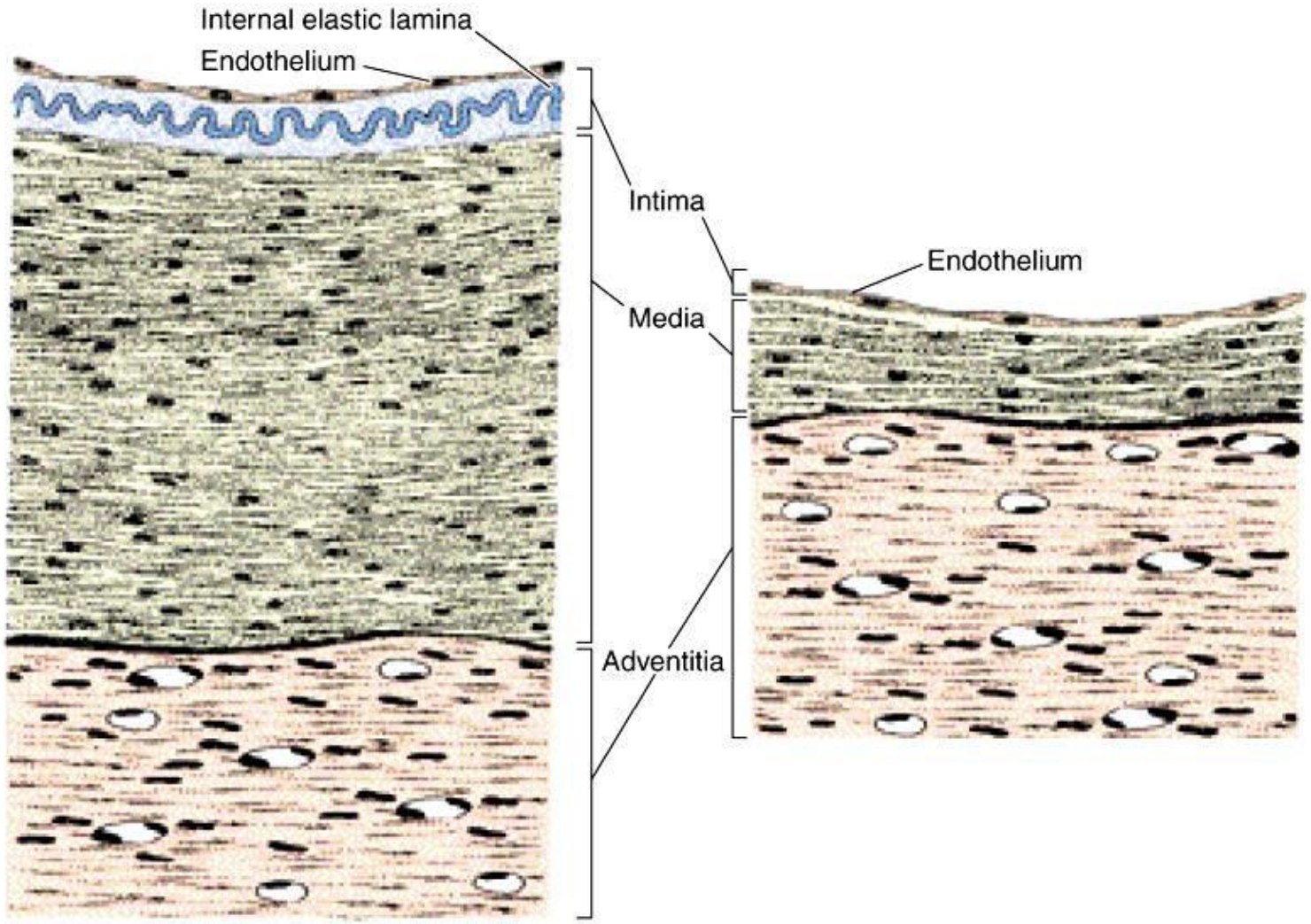
Internal elastic lamina
Endothelium
Intima
Media
Adventitia
Endothelium

VALVE WITH A VEIN

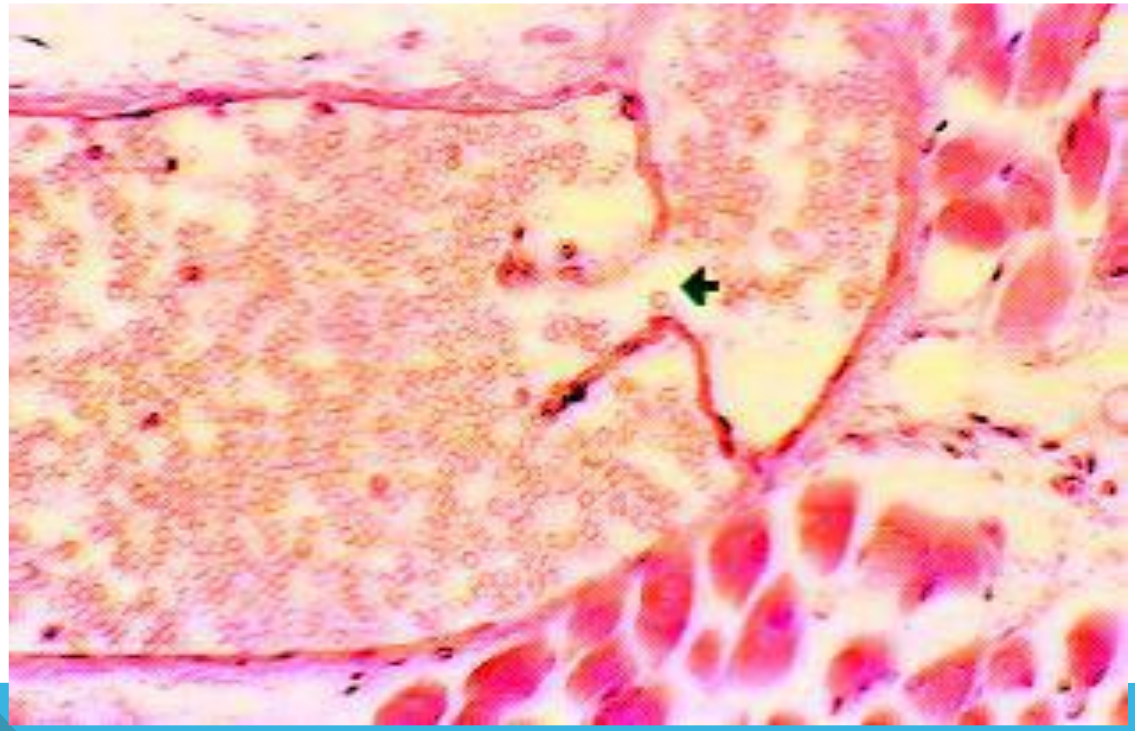

\FUNCTIONAL CORRELATIONS :

In veins, blood pressure is lower than in the arteries.As a result, venous blood flow is passive. Venous blood flow in the head and trunk is primarily owing to negative pressures in the thorax and abdominal cavities resulting from respiratory movements. Venous blood return from the extremities is aided by surrounding muscle contractions and prevented from flowing back by numerous valves in the large veins of the extremities.

MEDIUM VEINS

The medium size veins, includes most of the named veins of gross anatomy except for major trunks. The thin tunica intima consists of endothelial cells resting on a basal lamina, but a narrow subendothelial layer may be present. but a poorly defined internal elastic lamina is formed only in the larger vessels. In most medium veins, the tunica media, is thinner than in corresponding arteries. The thick tunica adventitia forms the bulk of the wall and is larger than the tunica media. It consists of collagen and elastic fibers and contains smooth muscle cells. Vasa vasorum are present in the larger vessels of this class . Valves are present in most of the medium size veins

VENULES :

Venules arise from the union of several capillaries to form vessels . The junctions between venules and capillaries are important sites of fluid exchange between tissues and blood. The tunica intima consists of a thin,continuous endothelium. The tunica media is missing in the smallest venules, and the relatively thin adventitia contains a few collagen fibers,

VASA VASORUM :

The walls of larger arteries and veins are too thick to receive nourishment by direct diffusion from their lumina. As a result, these walls are supplied by their own small blood vessels called the vasa vasorum (vessels of the vessel). The vasa vasorum allows for exchange of nutrients and metabolites with cells in the tunica adventitia and tunica media

BLOOD VESSELS

TYPES OF CAPILLARIES :

Capillaries are the smallest blood vessels. Their size, is about the size of an erythrocyte (red blood cell). There are three types of capillaries: ---

continuous capillaries,

fenestrated capillaries,

sinusoids.

These structural variations in capillaries allow for different types of metabolic exchange between blood and the surrounding tissues.

Regardless of the type, the basic structure of capillaries is similar and represents an extreme simplification of the vessel wall. The tunica intima consists of endothelium and a basal lamina; the tunica media is absent and the tunica adventitia is greatly reduced

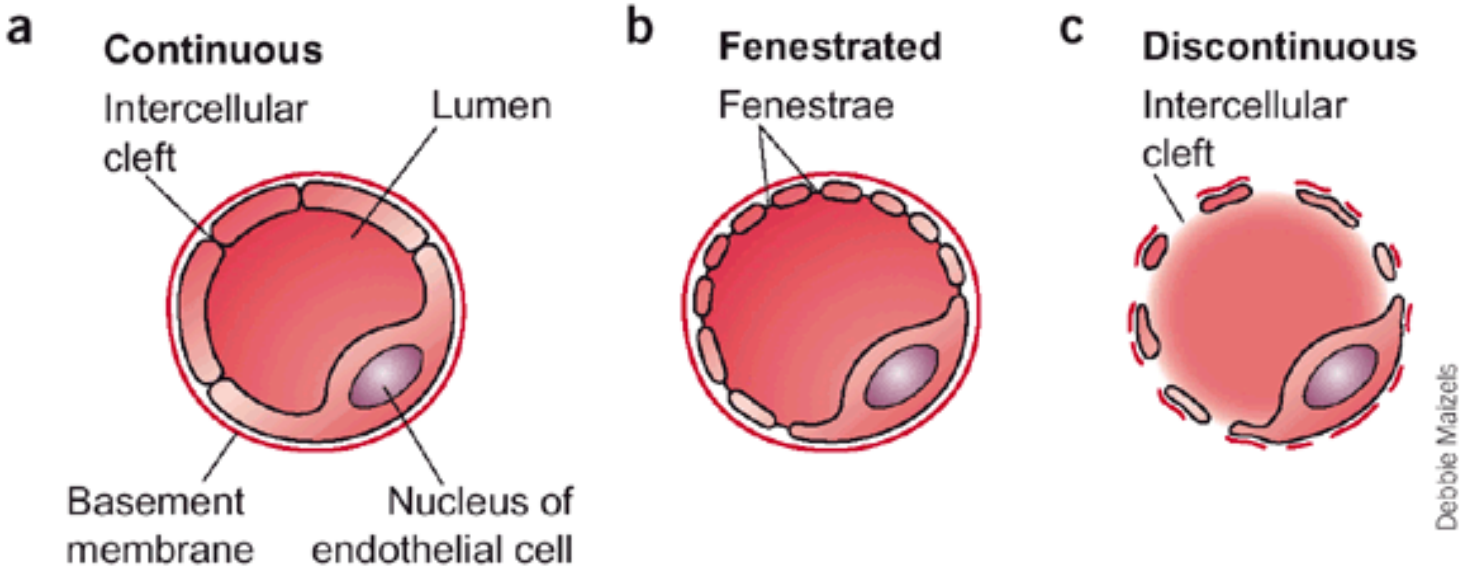
a
Continuous
Intercellular cleft
Lumen
Basement membrane
Nucleus of endothelial cell
b
Fenestrated
Fenestrae
c
Discontinuous
Intercellular cleft
Debbie Maizels

1- CONTINUOUS CAPILLARIES :

Continuous capillaries are the most common. They are found in muscle, connective tissue, nervous tissue, skin, respiratory organs, and exocrine glands. In these capillaries, the endothelial cells are joined and form an uninterrupted, solid endothelial lining. Pericytes are irregular, branched, isolated cells that occur at intervals along capillaries, enclosed by the basal lamina of the endothelium. The cells resemble fibroblasts

2- FENESTRATED CAPILLARIES :

Fenestrated capillaries are characterized by fenestrations (pores) in the cytoplasm of endothelial cells designed for a rapid exchange of molecules between blood and tissues. Fenestrated capillaries are found in endocrine tissues and glands, small intestine, and kidney glomeruli.

3- SINUSOIDAL CAPILLARIES :

are blood vessels that exhibit irregular,tortuous paths . Their much wider diameters slow down the flow of blood. Also, the cells may be separated by gaps and rest on a discontinuous basal lamina. A direct exchange of molecules occurs between blood contents and cells. Sinusoidal capillaries are found in the liver, spleen, and bone marrow

ARTERIOVENOUS ANASTOMOSES :

In addition to their capillary connections, arteries and veins may unite by shunts called arteriovenous anastomoses. *Generally these arise from side branches* of arterioles that pass directly to venules. They are thick-walled, muscular vessels of small caliber that usually are coiled and surrounded by a connective tissue sheath

They are plentiful in the plantar and palmar surfaces, fingertips, toes, lips, and nose and also occur in the thyroid. When open, the anastomoses shunt blood around the capillary bed and thus regulate the blood supply to many tissues. In the skin they function primarily in the regulation of body temperature.