Testis and scrotum

Objectives

- To recognise testicular maldescent and to appreciate the reasons for intervention
- To recognise and manage testicular torsion

EMBRYOLOGY AND ANATOMY OF THE TESTIS

It arises in the lumbar region from the mesodermal genital Ridge during the 5th - 6th week deriving its blood supply from the aorta and its nerve supply from T10 - T12 segments.

It migrates downwards, forwards and medially, passes through the inguinal canal carrying with it fold of peritoneum (processus vaginalis)

The average testicle measures about 4 ,3, 2.5 cm. It has a dense fascial covering called the tunica albuginea testis, which, posteriorly, is invaginated somewhat into the body of the testis to form the mediastinum testis. This fibrous mediastinum sends fibrous septa into the testis, thus separating it into about 250 lobules. Each lobule contains 1–4 markedly convoluted seminiferous tubules, each of which is about 60 cm long.

Blood Supply.

A. ARTERIAL

The arteries to the testes (internal spermatics) arise from the aorta just below the renal arteries and they anastomose with the arteries of the vasa deferentia that branch off from the internal iliac (hypogastric) artery.

B. VENOUS

The blood returns in the pampiniform plexus of the spermatic cord. At the internal inguinal ring, the pampiniform plexus forms the spermatic vein.

The right spermatic vein enters the vena cava just below the right renal vein;

The left spermatic vein empties into the left renal vein.

Lymphatics

The lymphatic vessels from the testes pass to the lumbar lymph nodes, which in turn are connected to the mediastinal nodes.

The testis reaches the following:

- It is retroperitoneal at the 12th week.
- the internal ring at the 6th month. (intrauterine)
- 2
- the bottom of scrotum at 9th month.(at birth)

Factors responsible for testicular descent:

1. Cranial segment of the body grows faster than caudal segment.

2. Maternal and pituitary gonadotrophs.
3. Gubernaculum: which is a fibromuscular band connecting the lower Pole of the testis to the bottom of the scrotum guiding the testis into the scrotum.

Origin of:
Testis and rete testis= genital mesoderm
Epididymis and vas= mesonephric duct.
Gubernaculum =fold of peritoneum.

Imperfect Descent of the testis

1. **Undescended testis or cryptorchism or incompletely descended testis:**
   A. Congenital B. Acquired
2. **Ectopic testis**
3. **Retractile testis**

INCOMPLETELY DESCENDED TESTIS

The testis is arrested at any site along the pathway of its normal descent to the scrotum. So it may be

- **Non palpable:**
  - Intraabdominal
  - Intracanalacular(in inguinal canal)
- **Palpable:**
  - At the external ring.
  - At the neck of scrotum.

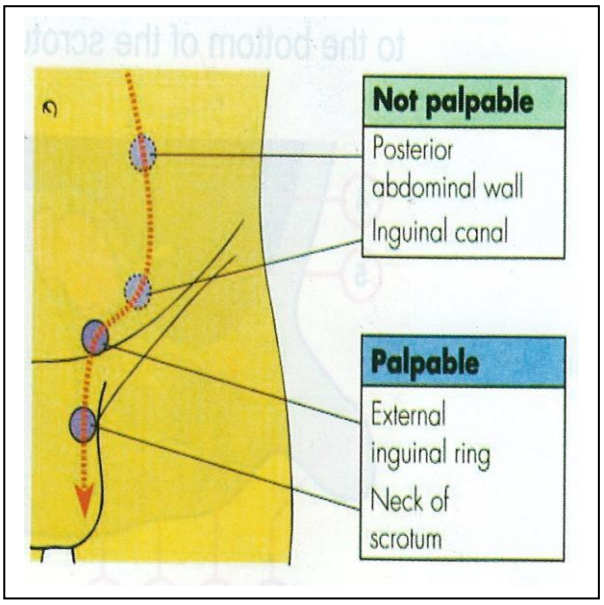

The incidence
More common in the prematures
Common on the right side.
20% are bilateral.

Premature -- 30%
Mature --3.4%

About two-thirds of these reach the scrotum during the first 3 months of life, but full descent after that is uncommon.

At 1year --0.8%
At Puberty -- 0.8%

Etiology
A- Hormonal deficiency
due to hCG hormone deficiency.

B- Mechanical factors
- large-sized testis and epididymis.

- shortness of the spermatic vessels of the vas deferens.
- adhesions fixing the testis in higher places
- Rapture of the gubernaculum.

Complications: Hazards of untreated cases include:

1. Psychological disturbance.
2. Pain due to trauma
3. Sterility: in bilateral cases due to failure of spermatogenesis due to higher abnormal temperature.
4. Atropy due to trauma and growth impairment
5. Assiociated Indirect inguinal hernia in 75 %, but around 90% of boys with an undescended testis have a patent processus vaginalis.
6. Torsion: may mimic acute appendicitis on the right side.
7. Infection—Epididomo-orchitis
8. Increase liability to malignant transformation:

   Seminoma – mostly

   -35-40 times than normal

   - 1/20 -- Abdominal

   - 1/80 -- Inguinal

   Orchiopexy *DOES NOT DECREASE* the liability to malignant trasformation

Clinical picture

- The ipsilateral scrotum is empty and underdeveloped.
- The testis may be palpable in abnormal place.
- An associated inguinal hernia may be present.

Investigations:

- Hormonal assay: as LH AND TESTOSTERONE in the blood to exclude cases of anorchia in bilateral undescended testes.
- Ultrasongraphy: to localize the site of the testis.
- Ct scan and MRI
- Laparoscopy: diagnostic and therapeutic for non-palpable testis.

Treatment:

Histological changes in the testis can be seen from 1 year of age including loss of Leydig cells, degeneration of Sertoli cells and decreased spermatogenesis. The higher the testis, the greater the degree of histological change.

Surgical treatment

Orchiopexy

It is usually performed before the boy reaches 12months of age (from 6-12 months) in an attempt to prevent the consequences described earlier.

Orchiectomy
It should be considered if the incompletely descended testis is atrophic, particularly in the postpubertal boy if the other testis is normal.

Hormonal treatment:
In bilateral cases with hypogenitalism
Course of HCG is used according to the age and never repeated.

Ectopic testis
In which the testis passed out the external ring of the inguinal canal but instead of reaching the scrotum it passes in abnormal ectopic position.
The site may be:
- Superficial Inguinal pouch.
- Perineal
- Pubo-penile (root of penis).
- Femoral triangle.
- Transverse ectopia—contralateral hemiscrotum.

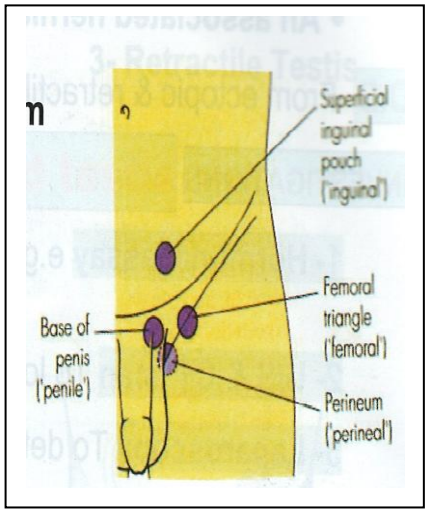

Treatment :
Surgery.

The Retractile testis
The condition occurs in young child between the ages of 3 and 7 years of age due to an overactive cremasteric reflex.
It can be differentiated from undescended testis by
- The scrotum is well developed.
- The testis can be pushed into the scrotum with squatting or chair test.

NO treatment just monitoring until puberty.

ABSENT TESTIS
'Vanishing' testis describes a condition in which a testis develops but disappears before birth. The most likely cause for this is prenatal torsion. True agenesis of the testis is rarer.
Laparoscopy is useful in distinguishing these causes of clinically absent testis from intra-abdominal maldescent.

INJURIES TO THE TESTIS
The testis can be damaged either by
- blunt or
- penetrating trauma.

Injuries can range from simple bruising, through significant intratesticular haematomas to rupture of the tunica albuginea, with very significant collections of blood within the tunica vaginalis (haematocoele)
Careful clinical assessment, together with the use of ultrasound examination, is central to the management of men with a scrotal injury.

Treatment:
- If there is testicular rupture, early surgical exploration, with debridement and repair of the tunica albuginea
- Scrotal wall haematomas and injuries without rupture can usually be treated conservatively.

Hamatocele:
Causes:
- after trauma
- After tapping of hydrocele—refilling of the scrotum with pain and tenderness and poor or absence transillumination

Treatment: drainage – if NOT, it will be ENDED with clotted hamatocele LEADING TO testicular atrophy

Testicular torsion (Torsion of spermatic cord)

It means twisting of the testis and the epididymis around the axis of the spermatic cord.
Predisposing factors:
1. Imperfect descent of the testis.
2. High investment of the tunica vaginalis causes the testis to hang within the tunica like a clapper in a bell. This is the most common cause in adolescents and is typically a bilateral abnormality.
3. Inversion of the testis. The testis is rotated so that it lies transversely or upside down.
4. Long mesorchium: Separation of the epididymis from the body of the testis permits torsion of the testis on the pedicle that connects the testis with the epididymis
5. Spirally arranged cremasteric muscle.

Exciting causes: sudden contraction of spirally attached cremastric muscle favour rotation around vertical axis. As in sudden contraction of abdominal wall due to Truma , straining at stool, lifting of heavy weight, coitus and sport. also it may occur **During sleep.**

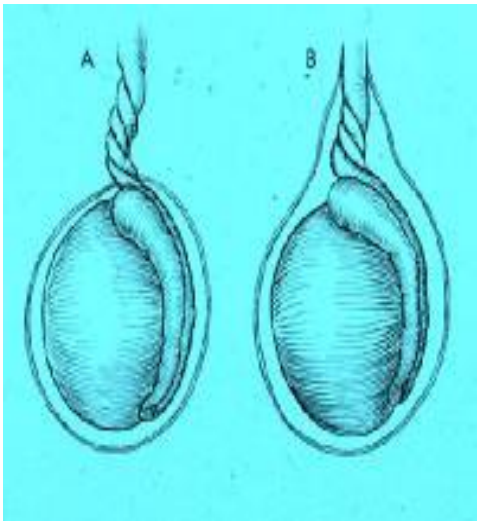

Types of Torsion

A. Extravaginal torsion 5%
- in the neonatal period
- proximal to the attachments of the tunica vaginalis

B. Intravaginal torsion
- Within the tunica vaginalis
- Peak incidence occurs in adolescents aged 13 years
- the left testis is more
- Bilateral in 2% .

Clinical features

Testicular torsion is most common between 10 and 25 years of age, in Intravaginal torsion And in infants in Extravaginal torsion.

Typically there is sudden agonising pain in the groin and the lower abdomen and the patient feels nauseated and may vomit.

On examination:

- The scrotum is swollen and tender, while the skin is usually not erythematous initially (although it may become so with a prolonged history) and
- the patient is apyrexial.
- The testis itself is swollen and tender and seems high within the scrotum, while the tender twisted cord can often be palpated above it.
- The contralateral testis is also transvers lie (Angle's sign),
- Elevation of the testis may incease the pain or has no effect in contrast to epedidymoorchitis.
- The cremasteric reflex is lost.

Investigation

-Colour Doppler ultrasound Examination: show deceased or absent blood flow.

-Radionuclutide study: The agent of choice for this purpose is technetium-99m pertechnetate

Factors that determine the damage to the testis are

- The extent of the twist: Twists of 720° cause more rapid ischaemia than twists of 360° or less
- The duration of the episode: if the testis can be untwisted within 6 hours of the torsion taking place there is nearly a 100% chance of testicular salvage compared with a 20% salvage rate if the surgery is delayed for 24 hours.

Differential diagnosis

A. **Torsion of testicular or epididymal appendages**
    1. aged 7-12 years
    2. Systemic symptoms are rare
    3. the blue dot sign is present in light-skinned boys
B. **Epididymitis, orchitis, epididymo-orchitis**
C. **Hydrocele (usually associated with patent processus vaginalis)**
    1. Painless swelling .
    2. Transilluminated .
D. Incarcerated hernia may be diagnosed by careful examination of the inguinal canal.
E. **Testis tumor**
    1. Rarely Painful.
    2. Rarely acute.
F. **Idiopathic scrotal edema**
    1. 4-12year of age, scrotal skin is thickened, edematous, and often inflamed.
    2. No pain or tenderness—it is ellergic phenomena

Treatment of torsion

It is a top surgical emergency and should be treated by urgent surgical exploration with

- Untwisting and fixation (orchioexy) for viable testis and contralateral orchiopexy.
- Orchiectomy for gangerenous testis and contralateral orchiopexy.

A trial of manual untwisting may be used by manually rotating the testicle in the opposite direction to the usual direction of torsion (i.e., outward, towards the thigh); if this is initially unsuccessful, a forced manual rotation in the other direction may correct the problem, but even after successful manual correction, urgent surgical fixation is still required.

Note: the common direction of torsion is inward, toward the midline of the body.