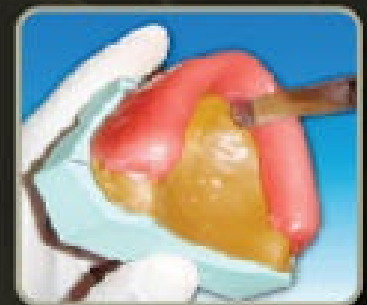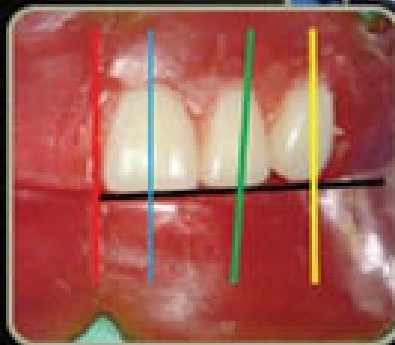

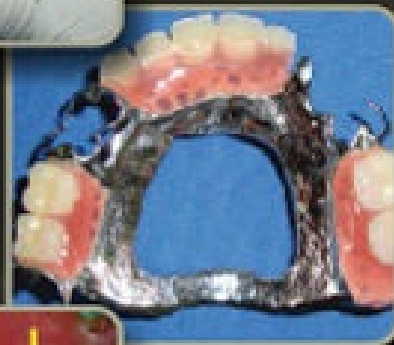
Preclinical Manual of Prosthodontics

**SECOND
Edition**

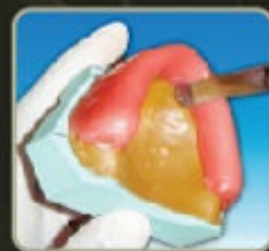
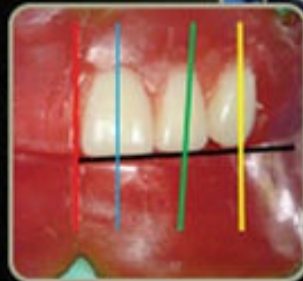
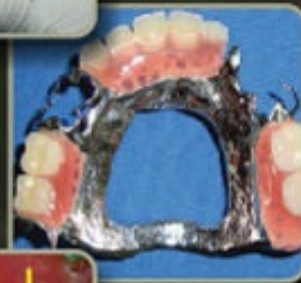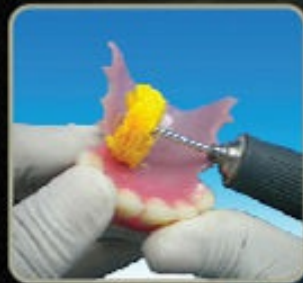S Lakshmi



Preclinical Manual of Prosthodontics

**SECOND
Edition**



S Lakshmi

Preclinical Manual of Prosthodontics

SECOND EDITION

S Lakshmi MDS

*Professor, Department of Prosthodontics and Implantology, Meenakshi
Ammal Dental College, Chennai, INDIA*



ELSEVIER
A division of
Reed Elsevier India Private Limited

Table of Contents

Cover image

Title page

Copyright

Dedication

Contributors

Preface to the second edition

Preface to the first edition

Acknowledgements

1. Synopsis of preclinical prosthodontics

 Complete denture

 Removable partial denture

2. Instruments and materials

Instruments

Materials

3. Preclinical exercise

Complete denture fabrication

Shellac baseplate adaptation

Fabrication of occlusion rims

Mounting of the casts in the articulator

Teeth setting

Wax-up

Processing of the waxed dentures

Finishing and polishing

Repair of fractured lower complete denture

Custom impression tray fabrication for upper and lower edentulous arches

Removable partial denture fabrication

Making of casts

Indexing of dental casts

Shellac baseplate adaptation for class IV

Fabrication of occlusion rims

Mounting of the casts in articulator

Teeth setting

Wax-up

Processing

Finishing and polishing

4. Common viva questions

What is prosthodontics?

What is complete denture prosthodontics?

What is a complete denture?

What are the anatomical landmarks of the maxilla?

What are the supporting structures of maxilla?

What are the peripheral or limiting structures of maxilla?

What are the stress-bearing areas of maxilla?

What are the relief areas of maxilla?

Why is relief given over the midpalatine raphe?

Why is relief given over the incisive papilla?

What is postpalatal seal?

What is posterior palatal seal area?

What are the boundaries of posterior palatal seal?

What are the functions of the posterior palatal seal?

Define vibrating lines.

What are the anatomical landmarks of the mandible?

What are the supporting structures of mandible?

What are the anatomical features influencing the supporting structures of mandible?

What are the peripheral or limiting structures of mandible?

Which is the primary stress bearing area of mandible and why?

What are the boundaries of buccal shelf area?

What are the relief areas of the mandibular arch?

Define an impression.

Define a dental impression.

What are the basic objectives of impression making?

What are the theories in impression making?

What are the techniques of impression making?

What is a preliminary impression?

Define an impression tray

What is a stock tray?

What is a custom tray?

What are the materials used to fabricate a custom tray?

What should be the position, size and shape of the tray handle?

What is the purpose of the tissue stops?

Define a cast.

What is a preliminary cast?

What is a diagnostic cast?

What is a master cast?

What are the requirements of a cast?

Define a die.

What is border seal?

What is border movement?

What is border tissue movements?

What is peripheral tracing/border moulding?

What are the materials used for border moulding?

What is a wash impression?

What are the materials used for making final impression?

What is a record base?

What are the requirements of a record base?

What are the requirements for record base material?

What are the permanent record base fabricating materials?

What are the temporary record base materials?

What is an occlusal rim?

What is an articulator?

What are the functions of an articulator?

What are the requirements of an articulator?

What are the theories of articulation?

What is bonwill's theory?

What is monson's spherical theory?

What is angle classification of malocclusion?

What is horizontal overlap or overjet?

What is vertical overlap or overbite?

What is compensating curve?

What is curve of occlusion?

What is curve of monson?

What is curve of pleasure?

What is anti-monson curve or reverse curve?

What is curve of spee?

What is curve of wilson?

What is christensen's phenomenon?

Define centric relation.

Define centric occlusion.

What is a transitional denture?

What is an interim prosthesis?

What is a treatment denture?

Define retention.

Define stability.

What is a removable partial denture?

What are the components of removable cast partial denture?

What is a major connector?

What are the functions of a major connector?

What are the types of maxillary major connector?

What are the types of mandibular major connector?

What is a minor connector?

What are the types of minor connector?

What are the types of minor connector that joins the denture base to the major connector?

What is a direct retainer?

What are the types of direct retainer?

What are the parts of the clasp?

What are the requirements of a clasp design?

What is the other name for reciprocal arm?

Which is the only component of the clasp which is placed below the height of contour?

What are the factors which influence the flexibility of the clasp arm?

What is a combination clasp?

What are the types of circumferential clasp?

What are the types of bar clasp?

What is an indirect retainer?

What are the functions of an indirect retainer?

In which classification of partially edentulous arch is mandatory to give an indirect retainer?

What are the factors which influence the effectiveness of an indirect retainer?

What are the forms of indirect retainer?

What is an occlusal rest?

What are the functions of occlusal rest?

What is a dental cast surveyor?

What are the parts of a surveyor?

What are the functions of a surveyor?

What is tripod marking?

What is an undercut?

What is a tooth supported removable partial denture?

What is a height of contour?

What are guiding planes?

What is a survey line?

What is a suprabulge?

What is an infrabulge?

What are the alloys used for the fabrication of cast partial denture?

What is a fixed partial denture?

What are the parts of a fixed partial denture?

Define abutment.

Define retainer.

Define connector.

Define pontic.

5. Glossary of terms

Copyright

Preclinical Manual of Prosthodontics, 2e
Lakshmi

© 2014 Reed Elsevier India Private Limited.

Second Edition 2014
First Edition 2010

All rights reserved. No part of this publication may be reproduced or transmitted in any form or by any means, electronic or mechanical, including photocopying, recording, or any information storage and retrieval system, without permission in writing from the Publisher.

This book and the individual contributions contained in it are protected under copyright by the Publisher (other than as may be noted herein).

ISBN: 978-81-312-3738-0
eISBN: 978-81-312-3866-0

Notices

Knowledge and best practice in this field are constantly changing. As new research and experience broaden our understanding, changes in research methods, professional practices, or medical treatment may become necessary.

Practitioners and researchers must always rely on their own

experience and knowledge in evaluating and using any information, methods, compounds, or experiments described herein. In using such information or methods they should be mindful of their own safety and the safety of others, including parties for whom they have a professional responsibility.

With respect to any drug or pharmaceutical products identified, readers are advised to check the most current information provided (i) on procedures featured or (ii) by the manufacturer of each product to be administered, to verify the recommended dose or formula, the method and duration of administration, and contraindications. It is the responsibility of practitioners, relying on their own experience and knowledge of their patients, to make diagnoses, to determine dosages and the best treatment for each individual patient, and to take all appropriate safety precautions.

To the fullest extent of the law, neither the Publisher nor the authors, contributors, or editors, assume any liability for any injury and/or damage to persons or property as a matter of products liability, negligence or otherwise, or from any use or operation of any methods, products, instructions, or ideas contained in the material herein.

Please consult full prescribing information before issuing prescription for any product mentioned in this publication.

The Publisher

Published by Reed Elsevier India Private Limited

Registered Office: 305, Rohit House, 3 Tolstoy Marg, New Delhi-110 001

Corporate Office: 14th Floor, Building No. 10B, DLF Cyber City, Phase II, Gurgaon-122 002, Haryana, India

Sr Content Strategist: Nimisha Goswami

Managing Editor: Anand K Jha

Sr Project Manager: Nayagi Athmanathan

Project Coordinator: Isha Bali

Manager - Publishing Operations: Sunil Kumar

Sr Production Executive: Ravinder Sharma

Sr Cover Designer: Milind Majgaonkar

Laser Typeset by GW India
Printed and bound at

Dedication

*Dedicated to my angels . . . Sanjana and Sidharth my beloved husband . . .
Gopi Krishna my parents . . . Ambuja and Shiva Subramanian and to the
Almighty . . .*

Contributors

S Lakshmi MDS, Professor, Department of Prosthodontics and Implantology, Meenakshi Ammal Dental College, Chennai

D Sendhilnathan MDS, DNB, Professor, Department of Prosthodontics and Implantology, SRM Dental College and Hospital, Kattankulathur, Chennai

CS Raj Mohan MDS, Course Leader—Fixed Prosthodontics, Adult Restorative Dentistry, Oman Dental College, Muscat, Oman

Preface to the second edition

S Lakshmi

The second edition of the **Preclinical Manual of Prosthodontics** maintains our commitment to guide dental students of preclinical and clinical years. We have ensured that the descriptions are precise, and well supported with illustrations. The preclinical students can use the book as a hand guide manual for their preclinical sessions. In this edition, we have introduced a section for the preclinical students to get an orientation of a clinical procedure in the rehabilitation of completely edentulous patients with a removable prosthesis. We have introduced newer dental materials and instruments in [Chapter 2: Instruments and Materials](#), for the preclinical students to be aware of the latest trends. A preclinical exercise of teeth preparation has been included in [Chapter 3](#) which is a practical exam exercise for the clinical students. We are confident that the students will be benefitted in understanding the basic concepts of prosthodontics.

Preface to the first edition

S Lakshmi

It is a privilege and an honour to have had an opportunity to bring out a manual of Preclinical Prosthodontics for the preclinical students of dental schools. The subject of Prosthodontics is introduced to the students of dentistry in the first year of the curriculum. The students appear for a preclinical Prosthodontics examination in the second year of BDS course before entering into the clinical prosthodontics in the third year.

During the first year and second year of the BDS course, students are required to do certain preclinical exercises so that they are trained to do these procedures which will be a part of the clinical sessions in the third and final year of the course. Although there are a lot of books prescribed for the final year clinical students, it has been my observation that the preclinical students find it difficult to read from a Prosthodontic book meant for a final year student. This was the motivation to bring out a manual on Preclinical Prosthodontics for the preclinical dental students.

The *Preclinical Manual of Prosthodontics* consists of 5 chapters. **Chapter 1:** Synopsis of the Preclinical Prosthodontics deals with a brief description on Prosthodontic subject with coloured photographs and illustrations for a basic understanding of the subject for the preclinical student (Complete denture prosthodontics, Removable partial prosthodontics, Fixed Prosthodontics). **Chapter 2:** Instruments and Materials contains the description of the dental instruments and materials used during the Preclinical Prosthodontic session. The coloured pictures of the instruments and materials are followed by a

brief description which will be useful for the students. In the preclinical examination, one of the exercises is to identify instruments and materials and this section would be of help in this regard. [Chapter 3](#): Preclinical Prosthodontic Exercise deals with preclinical exercises which the students are required to do during the preclinical Prosthodontic sessions. A step-by-step procedure with photographs and the description is given for all the preclinical exercises. [Chapter 4](#): Common Viva Question deals with frequently asked questions in the viva voce while [Chapter 5](#): Glossary of Terms gives a comprehensive glossary of prosthodontic terms which a student should be well versed with.

Acknowledgements

This book reflects a 'team effort'. I have been blessed to have an extraordinary support team of teachers, students, colleagues and family who have helped me in making every step of my dream into a reality.

First of all, I would like to express my gratitude and *Pranams* to my teacher *Dr E Munirathnam Naidu*, who was instrumental in making me choose Prosthodontics as my field of specialization and inspired me to be a teacher.

I would like to thank my entire team at Meenakshi Ammal Dental College. I thank *Dr Annapoorni*, my teacher and Head of the Department of Prosthodontics and Implantology for giving me all the freedom to work and execute this project in our department. She has always been an energetic supporter for me.

I thank *Dr Sendhilnathan*, a talented teacher for his dedication, support and his outstanding contribution in shaping the book. I also thank *Dr Raj Mohan*, an able co-ordinator for his contributions. He has been highly remarkable in executing the work during the progress of the book. I acknowledge and appreciate my postgraduate students, Dr Anoop, Dr Vignesh, Dr Gayathri, Dr Divya, Dr Durga Prasad, Dr Ravikiran, Dr Vinod, Dr Gaurav Gupta, Dr Karthikeyan who have been actively helping me throughout the writing of this manual. I thank Dr Sivapathasundharam, the Principal and my colleagues Dr Abby, Dr Valli, Mr Vivek for all their help and support.

I express my thanks to Vitallium lab for helping in the laboratory processing and Netway Babu for their professional inputs.

I am thankful to the Elsevier India team of Mr Vikas Kapoor, Ms Nimisha Goswami and Mr Anand K Jha for their faith in me and in their untiring efforts of giving the life and body to this manual.

I express my respect, love and gratitude for my parents-in-law Mrs Sulochana and Dr M Velayutham who have been supporting me by taking care of my children and without whom I could not have pursued my professional career.

One of my greatest blessings in life are my parents, my mother Ambuja and my father Shiva and my sister Latha who has been a pillar of strength to me.

Special hugs to my children Sanjana and Sidharth who bring enormous joy to me.

Words are not adequate to express my admiration and gratitude to my husband Dr Gopi Krishna for his continuous encouragement, support and bringing out my hidden potentials and for his bountiful love and affection on me and our children that has been *everything to me*.

CHAPTER 1

Synopsis of preclinical prosthodontics

S Lakshmi, CS Raj Mohan

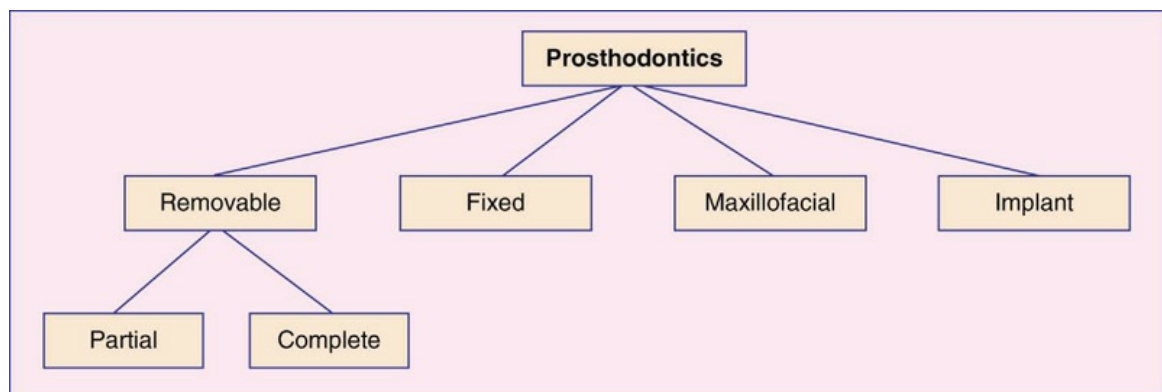
1.1. Complete denture

1.1.1. Introduction to prosthodontics

Prosthodontics

Prosthodontics is a branch of dentistry pertaining to the diagnosis, treatment planning, rehabilitation and maintenance of the oral function, comfort, appearance and health of the patients with clinical conditions associated with missing or deficient teeth and/or maxillofacial tissues using biocompatible substitutes.

Branches of prosthodontics



Removable prosthodontics

This branch of prosthodontics is concerned with the replacement of missing teeth and adjacent structures for edentulous and partially edentulous patients by artificial prosthesis that can be removed by the patient.

Fixed prosthodontics

The branch of prosthodontics pertaining to the replacement of missing teeth by artificial substitute that cannot be removed by the patient.

Maxillofacial prosthodontics

The branch of prosthodontics that deals with replacement of the stomatognathic and craniofacial structures.

Implant prosthodontics

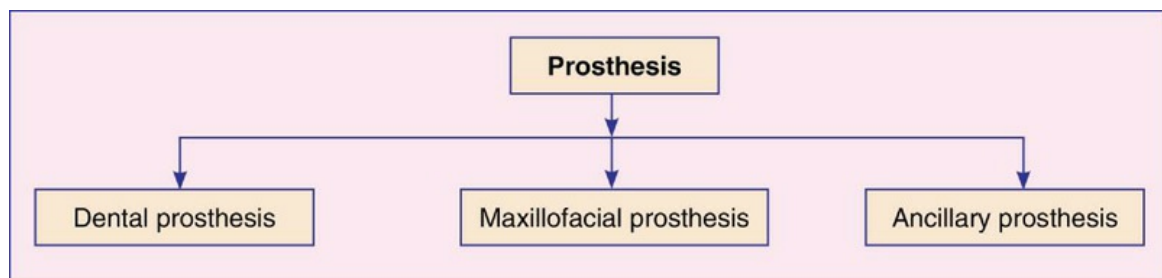
The branch of prosthodontics that deals with replacement of missing teeth and associated structures by restorations that are retained by the dental implants.

Prosthesis

Prosthesis may be defined as an artificial replacement of a missing part of the human body.

Types of prosthesis

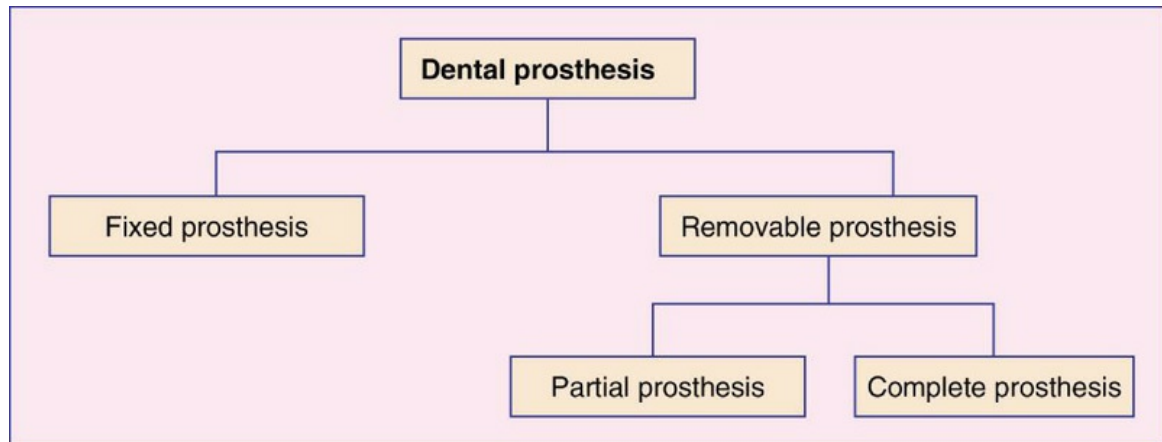
- i. Dental prosthesis
- ii. Maxillofacial prosthesis
- iii. Ancillary prosthesis



Dental prosthesis

An artificial replacement of one or more teeth and associated

dental/alveolar structures.



Fixed dental prosthesis

Any dental prosthesis that is cemented, screwed or attached to retained natural teeth or roots.

Cement retained dental prosthesis (Figs 1.1.1.1—1.1.1.3)

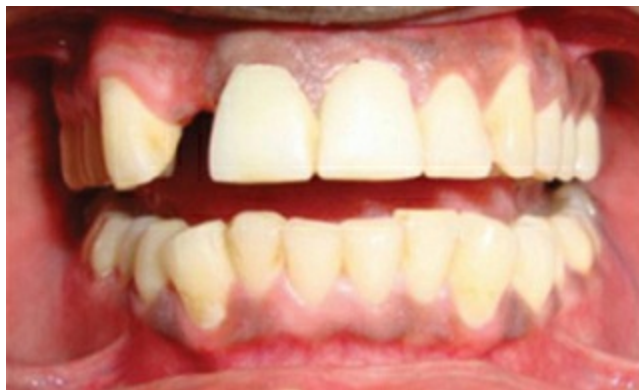

FIG 1.1.1.1 Missing upper lateral incisor

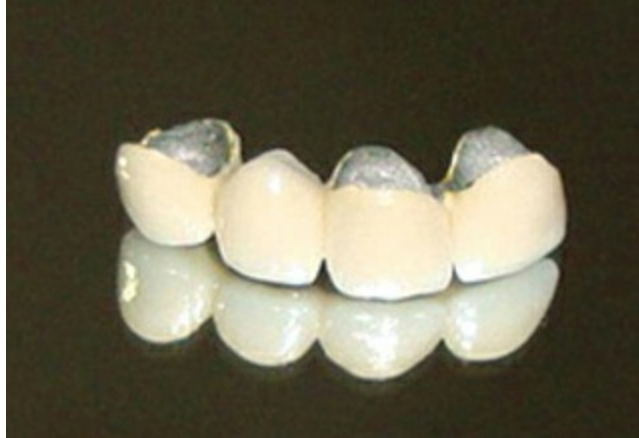

FIG 1.1.1.2 Fixed partial dental prosthesis

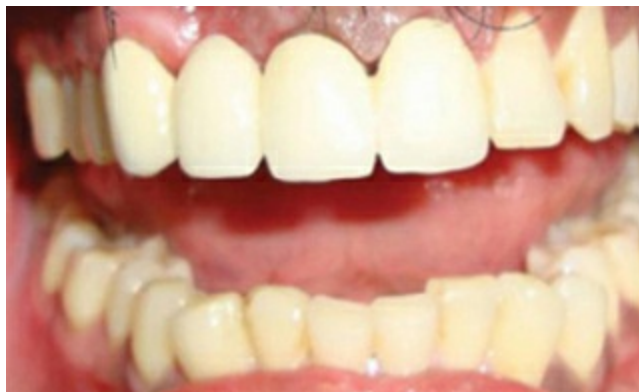

FIG 1.1.1.3 Fixed partial dental prosthesis cemented

Removable dental prosthesis

Any dental prosthesis that replaces some of missing teeth in a partially edentulous arch ([Figs 1.1.1.4](#) and [1.1.1.5](#)).

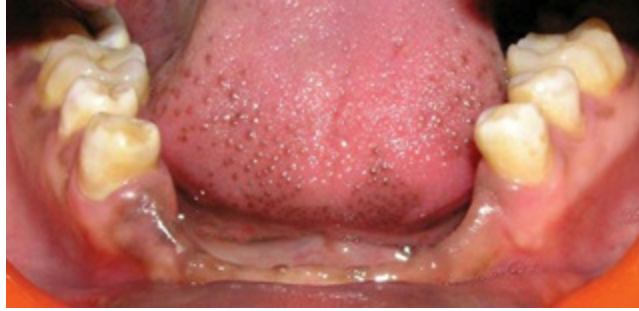

FIG 1.1.1.4 Missing lower anterior teeth

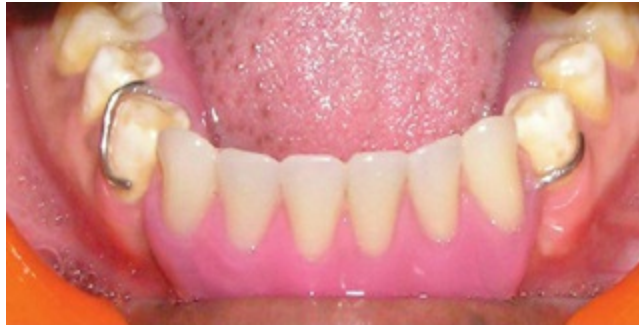

FIG 1.1.1.5 Patient wearing removable temporary prosthesis

Removable partial dental prosthesis (RPDP)

The prosthesis that replaces some teeth in a partially edentulous arch and that can be removed from the mouth by the patient. It can be a simple removable partial denture fabricated in acrylic resin called as temporary partial denture. A removable partial denture fabricated in cast metal alloy and acrylic resin is called cast partial denture ([Figs 1.1.1.6–1.1.1.8](#)).

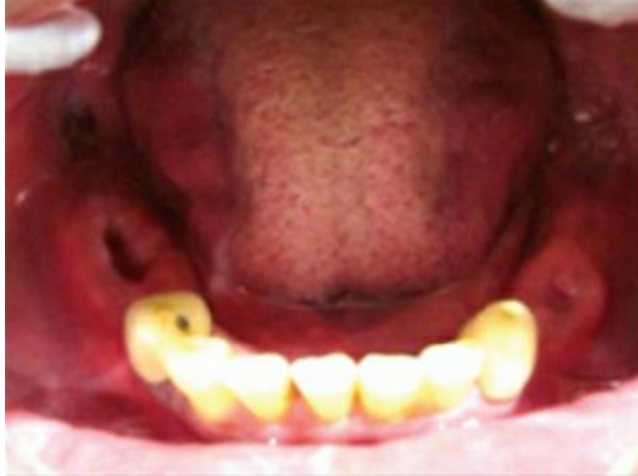

FIG 1.1.1.6 Partially edentulous arch denture

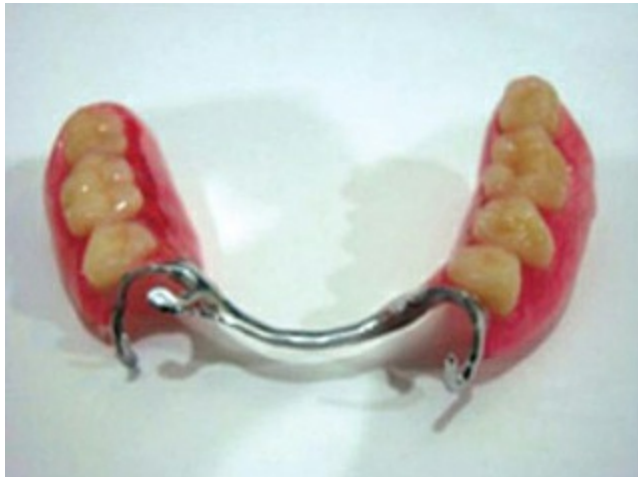

FIG 1.1.1.7 Cast partial denture

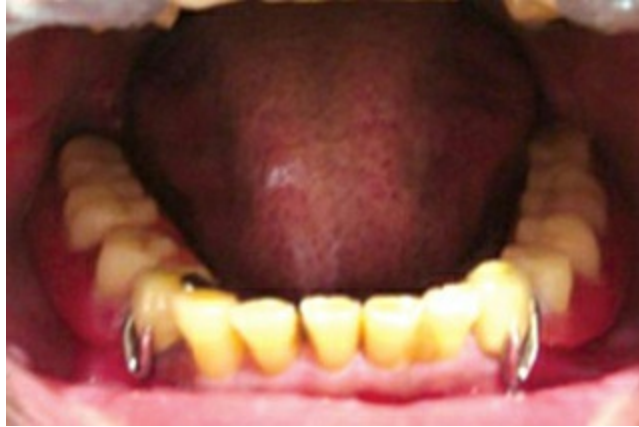

FIG 1.1.1.8 Patient wearing cast partial denture

Removable complete dental prosthesis

The prosthesis that replaces the entire dentition and associated structures of maxilla and mandible ([Figs 1.1.1.9–1.1.1.11](#)).

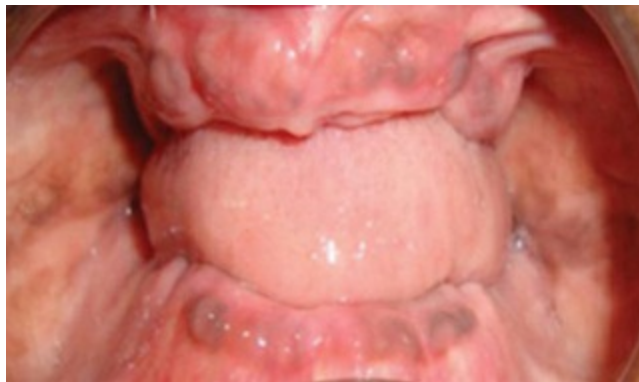

FIG 1.1.1.9 Completely edentulous arch

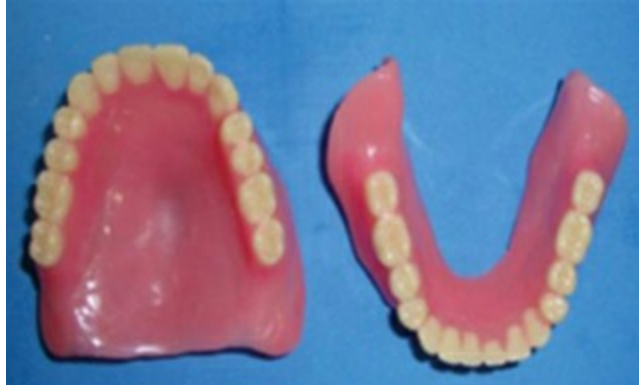

FIG 1.1.1.10 Complete denture

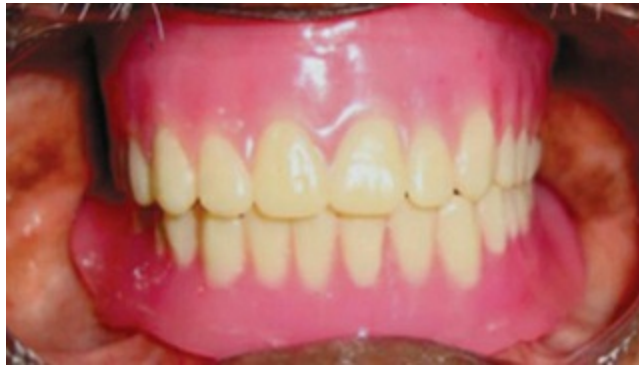

FIG 1.1.1.11 Patient wearing complete denture

Maxillofacial prosthesis

The prosthesis that is used to replace a part or all of any stomatognathic or craniofacial structures. Examples of maxillofacial prosthesis are auricular prosthesis, orbital prosthesis, nasal prosthesis, and facial prosthesis ([Figs 1.1.1.12–1.1.1.14](#)).

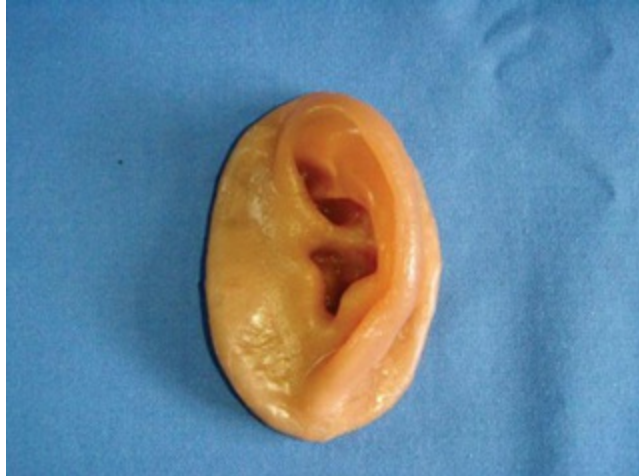

FIG 1.1.1.12 Auricular prosthesis



FIG 1.1.1.13 Finger prosthesis

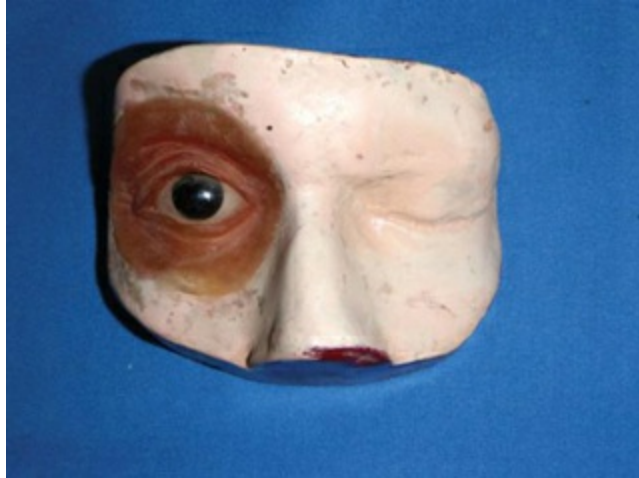

FIG 1.1.1.14 Orbital prosthesis

Implant supported prosthesis

A prosthesis that is used to replace missing teeth which is retained by dental implants ([Figs 1.1.1.15–1.1.1.18](#)).

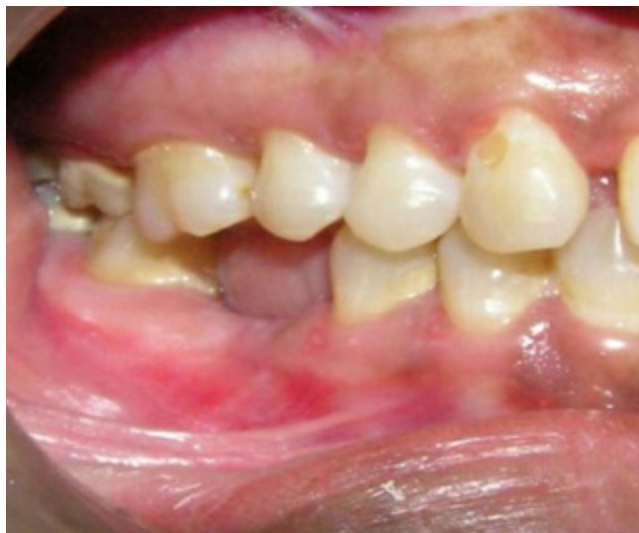

FIG 1.1.1.15 Missing tooth number 46

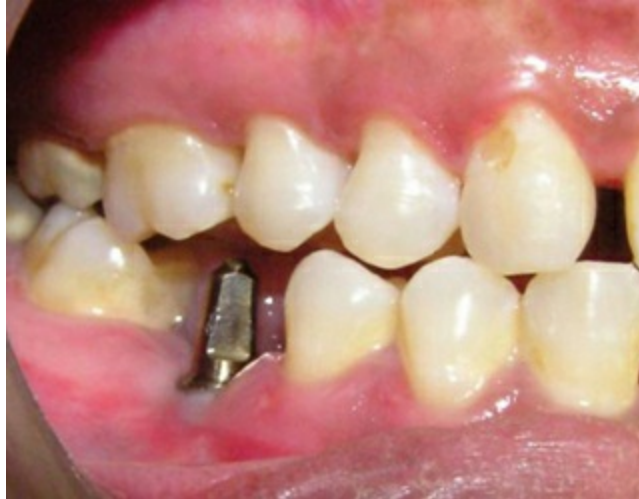

FIG 1.1.1.16 Dental implant placed in 46 region

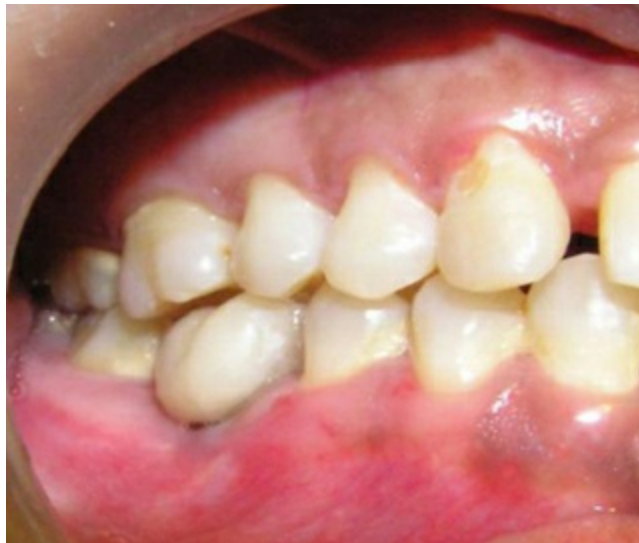

FIG 1.1.1.17 46 crown retained by implant

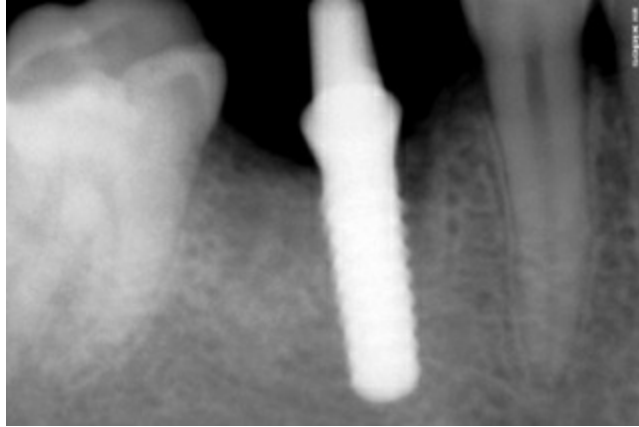

FIG 1.1.1.18 IOPA radiograph of implant placed in 46 region

Ancillary prosthesis

A type of dental prosthesis that is used in the field of prosthodontics which is used for a short term or special usage. Examples of such prosthesis are stents, splints, and guide (Fig. 1.1.1.19).

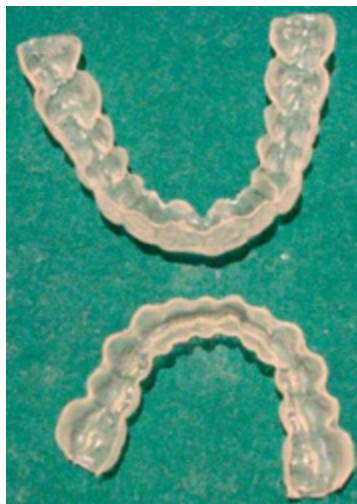

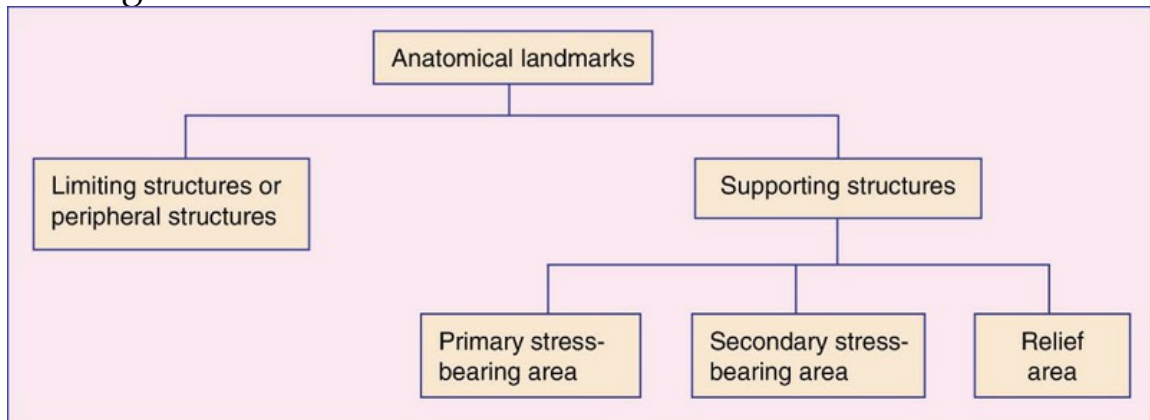
FIG 1.1.1.19 Upper and lower splints

1.1.2 Anatomical landmarks of maxillary arch and mandibular arch

Anatomical landmarks of maxillary and mandibular arch

1. Anatomy

2. Clinical significance



Anatomical landmarks of maxillary arch

Limiting structures or peripheral structures (Figs 1.1.2.1 a and b)

- Labial frenum
- Labial vestibule
- Buccal frenum
- Buccal vestibule
- Hamular notch
- Posterior palatal seal
- Fovea palatinae

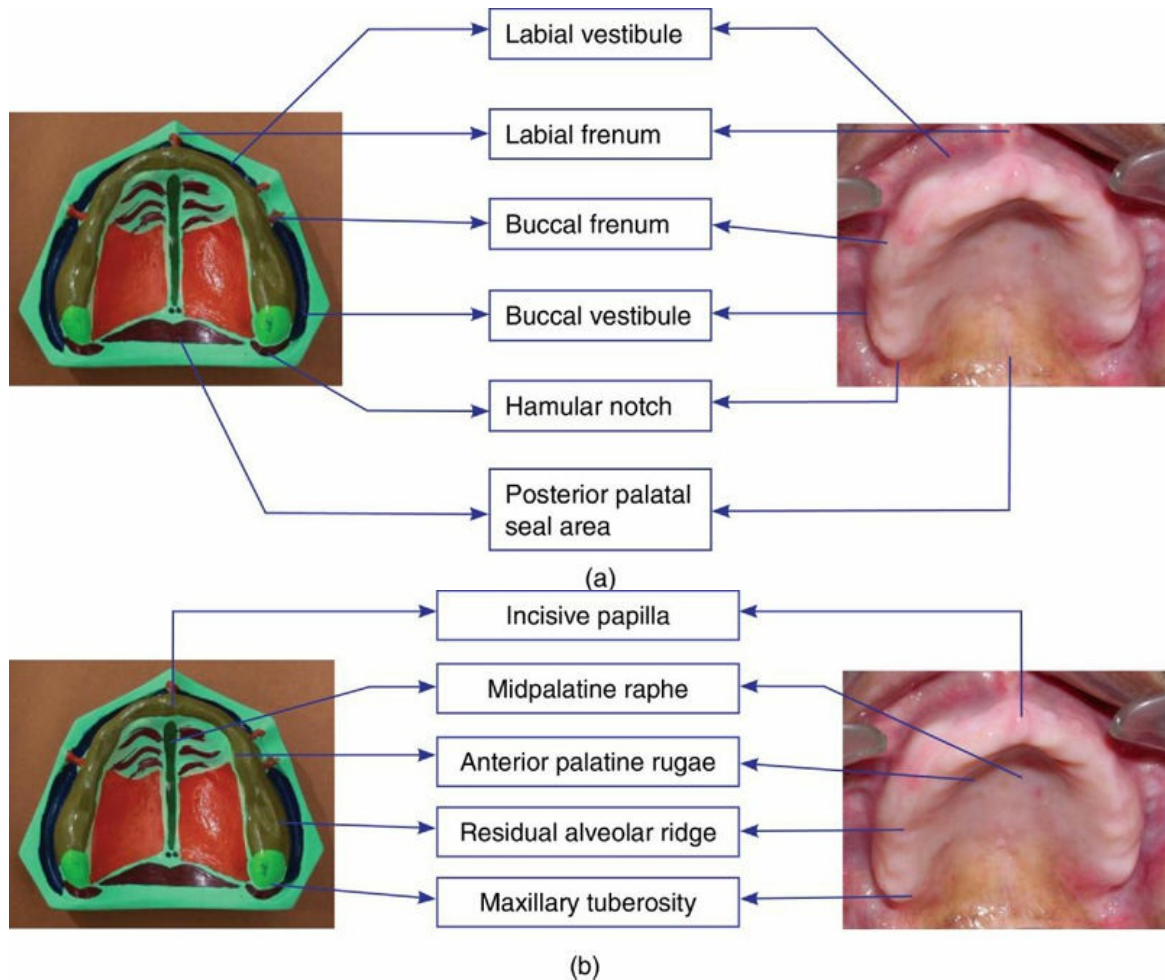


FIG 1.1.2.1A AND B Parts of the edentulous oral cavity

Supporting structures

Primary stress-bearing area

- Hard palate
- Posterior lateral slopes of the residual alveolar ridge

Secondary stress-bearing area

- Rugae

Relief area

- Incisive papilla
- Midpalatine raphe

Labial frenum

Anatomy

- Fibrous band covered by mucous membrane that extends from labial aspect of the residual alveolar ridge to the lip.
- It may be single or double and narrow or broad.
- It contains no muscle fibres.

Clinical significance

- Relief for the labial frenum must be given during final impression procedure.
- When relief is not given in the denture, it results in pain and it may cause dislodgement of the denture.

Labial vestibule

Anatomy

- Potential space bounded by the labial aspect of the residual alveolar ridge, mucolabial alveolar fold and orbicularis muscle.
- Area extends on both sides from labial frenum to the buccal frenum.
- The mucosa lining is thin with nonkeratinized epithelium.
- Submucosal layer is thick and contains large amount of loose areolar tissue and elastic fibres.

Clinical significance

- The labial flange of the denture provides the support for the upper lip.
- The labial flange of the denture will be in complete contact with labial vestibule to provide a peripheral seal in the denture.

Buccal frenum

Anatomy

- Band of tissue that overlies the levator anguli oris muscle.
- Orbicularis oris – pulls the frenum forward.
- Buccinator – pulls the frenum backward.
- Its reflection is in anteroposterior direction.

Clinical significance

- As there is muscle attachments in the buccal frenum, sufficient relief should be provided so that the denture will not dislodge during functions, like chewing, and smiling.

Buccal vestibule

Anatomy

- It extends from buccal frenum to the hamular notch.
- Bounded externally by cheek and internally by residual alveolar ridge.

Clinical significance

- The width and the height of the buccal flange of the upper denture is determined by the coronoid process of the mandible.
- When the patient moves the mandible side to side, the coronoid process affects the width of the buccal flange.
- The patient's mouth should be kept half open during the final impression procedure.
- When the mouth is kept wide open, the coronoid process of the mandible comes forward narrowing the buccal vestibule.

Hamular notch

Anatomy

- It forms distal limit of buccal vestibule and situated between hamulus of the medial pterygoid and tuberosity.
- The pterygomandibular ligament is attached to the hamular notch.

Clinical significance

- The denture border should extend till the hamular notch.
- If the denture border is short of the hamular notch, the denture will not have a posterior seal resulting in loss of retention of the denture.
- If the denture border is extended beyond the hamular notch, the pterygomandibular raphe is pulled forward when the patient opens the mouth wide open causing dislodgement of the denture.

Posterior palatal seal

Anatomy

Soft tissue along the junction of the hard and soft palates on which pressure within the physiological limits of the tissues can be applied by the denture to aid in the retention of the denture.

- It is not a straight line from hamular notch to hamular notch but follows the contour of the distal border of palatal bone.
- At the midline, it usually passes about 2 mm in front of fovea palatine.
- Posterior palatal seal is bounded anteriorly by the anterior vibrating line, posteriorly by posterior vibrating line and laterally by the hamular notch.
- Anterior vibrating line is at the junction between immovable tissues over the hard palate and slightly movable tissues of the soft palate.
- Posterior vibrating line is at the junction between aponeurosis of tensor veli palatine muscle and muscular portion of the soft palate.

Functions

- Aids in the retention of the denture by maintaining the constant contact with the soft palate during functional movements.
- Reduces the tendency for gag reflex.
- Prevents food accumulation between the posterior border of the denture and the soft palate.
- Compensates for polymerization shrinkage of the denture base resin.

Clinical significance

- Distal end of the maxillary denture should extend at least 1–2 mm beyond the vibrating line.
- Posterior palatal seal provides posterior seal for the maxillary denture.

Hard palate

Anatomy

- The main support for the maxillary denture is the bone of two maxilla and palatine bone.
- Covered by keratinized epithelium.
- Soft tissue covering the median palatal suture is nonresilient and may be relieved to avoid trauma.
- In the area of rugae, the palate is set at an angle to the residual alveolar ridge and is thinly covered by soft tissue which contributes to the secondary stress-bearing area.

Clinical significance

- Horizontal portion of the hard palate lateral to midline provides the primary support area for the maxillary denture.

Residual alveolar ridge

Anatomy

- Mucous membrane covering the crest of the ridge is firmly attached to the periosteum of the bone by the connective tissue of submucosa.
- Lined by thick stratified squamous epithelium.
- Crest of the alveolar ridge is the primary stress-bearing area.
- Even though the submucosa is thin, still sufficiently provides adequate resiliency to support the denture.

Clinical significance

- Residual alveolar ridge forms the main supporting area for the maxillary denture.

Maxillary tuberosity

Anatomy

- It is the bulbous extension of the residual alveolar ridge in the 2nd and 3rd molar region, terminating in the hamular notch.
- Hamular notch is a soft area of areolar tissue between the distal surface of the tuberosity and the hamulus; it houses the distolateral termination of the denture base.
- It is considered to be the secondary stress-bearing area of the maxillary arch.

Clinical significance

- Artificial teeth are not set on the tuberosity region.

Rugae

Anatomy

- These are mucosal folds located in the anterior region of the palatal mucosa.
- Folds of mucosa play an important role in speech.
- These are considered to be secondary stress-bearing areas.

Clinical significance

- While making final impression for the maxillary arch, one should make sure pressure is not applied on the rugae area which can cause distortion of the tissue.

Incisive papilla

Anatomy

- Incisive foramen is located beneath the incisive papilla on a line

immediately behind the central incisors.

- As resorption progresses, it comes to lie nearer to the crest of the ridge.
- Nasopalatine nerves and vessels pass through the foramen.

Clinical significance

- While making final impression of the maxillary arch, pressure should not be applied on the incisive papilla region.
- Compression of the incisive papilla region will cause compression of the blood vessels and nerves causing necrosis and paraesthesia of anterior palate.

Midpalatine raphe

Anatomy

- This is the median suture area covered by a thin submucosa.
- This soft tissue area is sensitive to pressure application.

Clinical significance

- As the submucosa is very thin, pressure cannot be applied over the midpalatine raphe region during making of final impression.
- If pressure is applied during impression making, the denture base will cause soreness over the midpalatine raphe region.

Anatomical landmarks of mandibular arch (Figs 1.1.2.3a-c)

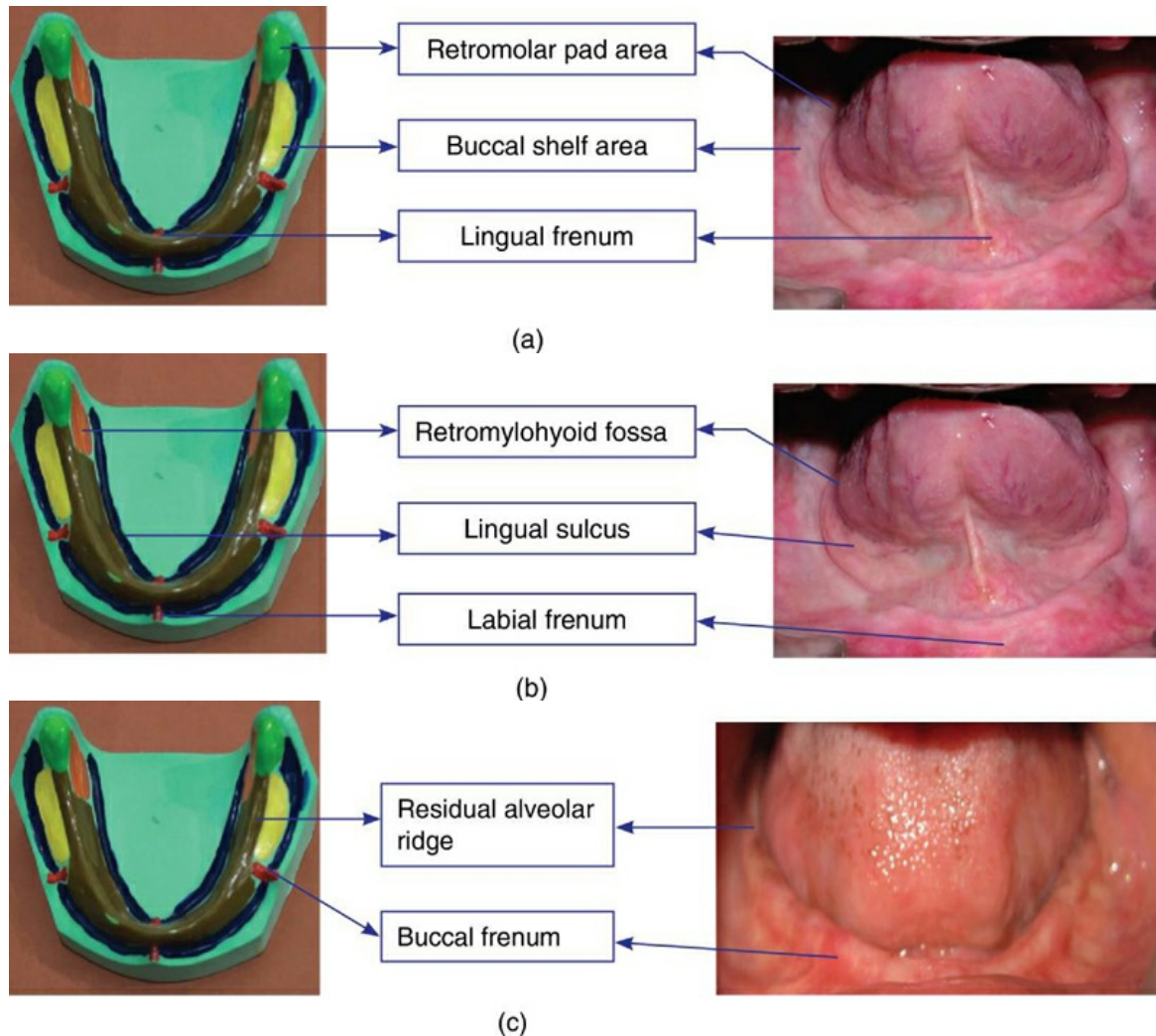


FIG 1.1.2.3A-C Parts of the mandibular edentulous ridge

Limiting structures

- Labial frenum
- Labial vestibule
- Buccal vestibule
- Buccal frenum
- Lingual frenum
- Alveololingual sulcus
- Retromolar pads
- Pterygomandibular raphe

Primary stress-bearing area

- Buccal shelf area
- Residual alveolar ridge

Relief area

- Mental foramen
- Genial tubercles

Labial frenum

Anatomy

- The mandibular labial frenum contains a band of fibrous connective tissue and helps to attach orbicularis oris muscle, therefore, the frenum is sensitive and active.

Clinical significance

- During final impression making, sufficient relief must be given for the labial frenum without compromising the peripheral seal.

Labial vestibule

Anatomy

- It runs from the labial frenum to buccal frenum.
- Fibres of orbicularis muscle, incisivus, and mentalis are inserted near the crest of the ridge. Mentalis muscle is particularly the active muscle.

Clinical significance

- Extent of the denture flange in this region is often limited because of muscles that are inserted close to the crest of the ridge. Thick denture flanges may cause dislodgement of dentures when patient opens the mouth wide open.
- Depth of the flange is determined by the mucolabial fold.

Buccal vestibule

Anatomy

- It extends from buccal frenum to the outside back corner of the retromolar pad.
- It is nearly at right angles to biting force.
- Extent of the vestibule is influenced by buccinators muscle, which extends from modiolus anteriorly to pterygomandibular raphe posteriorly and has its own fibres attached to buccal shelf and external oblique ridge.
- The masseter muscle contracts under heavy closing force and pushes inward against the buccinators muscle to produce a masseteric notch in the distobuccal border of the lower denture.

Clinical significance

- The distobuccal border of the lower denture should accommodate the contracting masseter muscle so that the denture does not dislodge during heavy closing force.

Buccal frenum

Anatomy

- It is a fold of mucous membrane extending from buccal mucous membrane reflection toward the slope or crest of the residual ridge in the region just distal to the cuspid eminence.
- May be single or double, broad U/V shape.
- It overlies depressor anguli oris muscle.

Clinical significance

- Relief for the buccal frenum is given in denture to avoid displacement of the denture.

Lingual frenum

Anatomy

- It is a fold of mucous membrane existing when the tip of the tongue is elevated.
- It overlies the genioglossus muscle which takes origin from the superior genial tubercle.

Clinical significance

- The relief for the lingual frenum should be registered during function.
- Relief for the lingual frenum should be provided in the denture.

Retromolar pad

Anatomy

- It is a triangular soft pear-shaped pad of tissue at the distal end of the lower ridge.
- Mucosa composed of thin, nonkeratinized epithelium and loose alveolar tissue.
- Submucosa contains glandular tissue, fibres of buccinators and superior constrictor muscle, pterygomandibular raphe and terminal part of the tendon of temporalis.

Clinical significance

- The distal end of the denture pad should cover two-thirds of the retromolar pad.
- The retromolar pad provides the peripheral posterior seal for the lower denture.

Alveololingual sulcus

Anatomy

- It is the space between residual ridge and tongue. It extends from lingual frenum to retromylohyoid curtain posteriorly.
- The borders are the following:

Anterior region

- Extends from lingual frenum to premylohyoid fossa where the mylohyoid ridge curves down below the level of the sulcus.

Middle region

- Extends from premylohyoid fossa to the distal end of the mylohyoid ridge curving medially from body of mandible.

Posterior region

- The flange passes into the retromylohyoid fossa. No longer influenced by mylohyoid muscle.

Clinical significance

- The lingual flange of the lower denture will be short anteriorly than posteriorly.
- The lingual flange in the middle region slopes medially towards the tongue and maintains the peripheral seal in the middle region.
- The lingual flange in the posterior region passes into the retromylohyoid fossa and turns laterally towards the ramus and forms the typical S-shaped form of the lower denture.

Retromylohyoid fossa

Anatomy

- It is the area posterior to the mylohyoid muscle and bounded by retromylohyoid curtain.
- Posterolateral portion of the retromylohyoid curtain overlies superior constrictor muscle, *posteromedial the palatoglossal muscle* and lateral surface of tongue and the inferior wall the submandibular gland.
- Protrusion of the tongue causes the retromylohyoid curtain to move forward.

Clinical significance

The over extension of the lingual flange in the retromylohyoid fossa area can cause soreness and dislodgement of denture during swallowing.

Pterygomandibular raphe

- It arises from the hamular process of the medial pterygoid plate and gets attached to the mylohyoid ridge.

Clinical significance

- It is very prominent in some patients where a notch-like relief may be required on the denture.
- A simple wide open visual and digital inspection is sufficient to determine the need for clearance.

Residual alveolar ridge

Anatomy

- Covered by fibrous connective tissue and underlying bone is cancellous without cortical bony plate covering it.
- Since it is cancellous (crest of the residual ridge), it may not be favourable as primary stress-bearing area.
- The slopes of the residual alveolar ridge have thin plate of cortical bone. The slopes of the ridge are at an acute angle to the occlusal forces. Hence, it is considered as a secondary stress-bearing area.

Clinical significance

- Any movable soft tissue overlying the residual alveolar ridge should not be compressed while making impression.

Buccal shelf area

Anatomy

- The area between the mandibular buccal frenum and anterior edge of the masseter muscle is known as buccal shelf area.
- Bounded medially by the crest of the alveolar ridge, laterally by the external oblique ridge, distally by the anterior aspect of the retromolar pad and anteriorly by the buccal frenum.
- Buccal shelf area is covered by a layer of dense and smooth cortical

bone.

- Buccal shelf area lies at right angles to the vertical occlusal forces; makes it suitable as primary stress-bearing area for the lower denture.

Mental foramen

Anatomy

- As resorption takes place, mental foramen will come to lie closer to the crest of the ridge.
- Mental nerves and vessels may be compressed by denture unless relieved.
- Pressure on the nerve will cause numbness of lower lip.

Genial tubercles

Anatomy

- These lie away from the crest of the ridge.
- With resorption, genial tubercles become increasingly prominent.

Torus mandibularis

Anatomy

- Bony prominences usually found bilaterally and lingually near the 1st and 2nd premolar midway between the soft tissues of the floor of the mouth and crest of the alveolar process.
- It should be removed surgically as it is difficult to provide relief within the denture.

1.1.3. Impression trays

- Definition
- Requirements of impression tray
- Types of impression trays

Definition

A receptacle or a device that is used to carry, control and confine the impression material while making an impression.

Requirements of impression tray

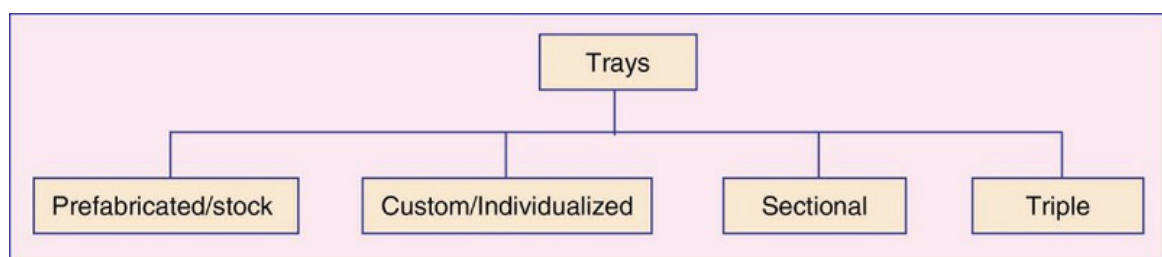
- i. The impression tray should be rigid.
- ii. It should be dimensionally stable.
- iii. It should provide space for impression material while making an impression.
- iv. The borders of the tray should be smooth so that it does not injure the oral tissues.
- v. The method of construction of the custom trays should be simple.
- vi. The borders of the tray should be easy to trim.

Types of impression trays

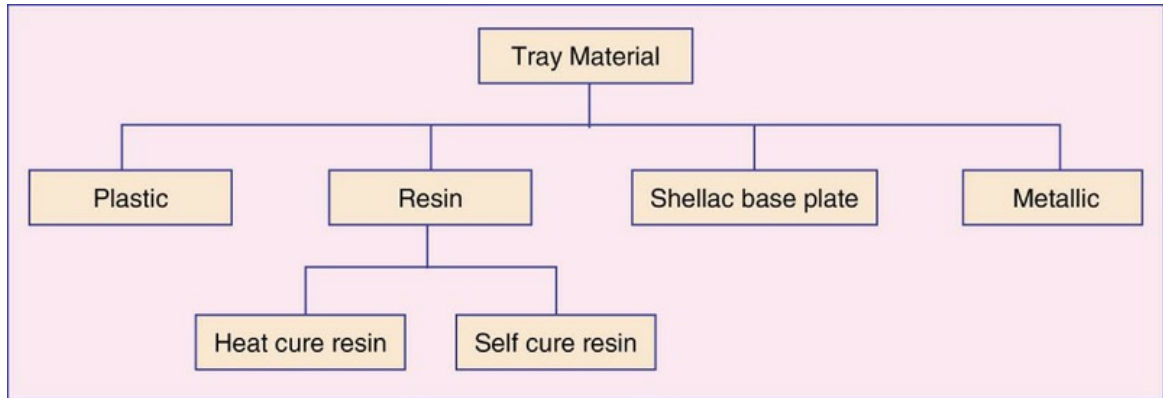
Impression trays can be classified as:

1. Based on purpose or use
2. Based on material

Based on purpose or use



Based on material



Stock trays or prefabricated trays (Figs 1.1.3.1—1.1.3.3)

- i. Stock trays are rigid.
- ii. They are dimensionally stable.
- iii. The trays can be used several times.
- iv. They are available in different sizes and specifically for upper and lower arches.
- v. The perforations in the trays help in retention of the set impression material while removing the impression from the patient's mouth.
- vi. Tray adhesives have to be applied for elastomeric impression material.
- vii. The flanges of the stock tray cannot be contoured.
- viii. The space for the impression material is not uniform.



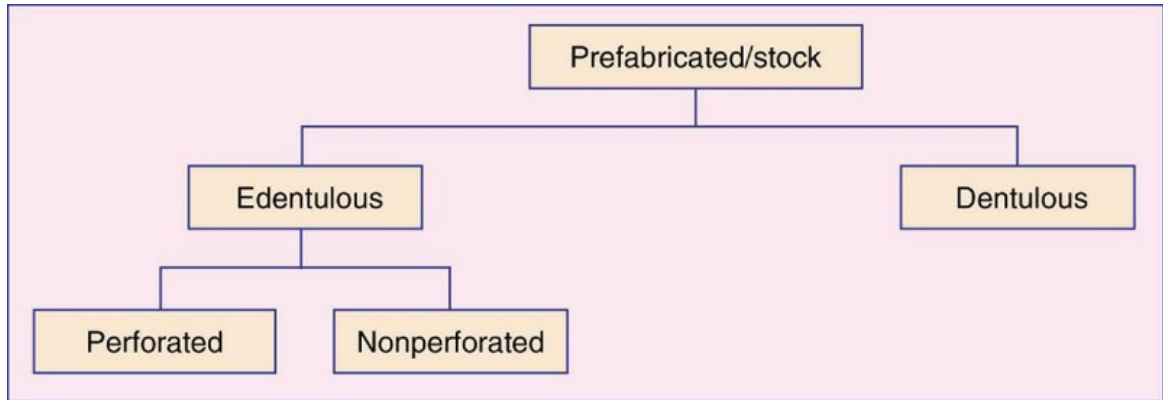
FIG 1.1.3.1 Dentulous prefabricated stainless steel perforated tray

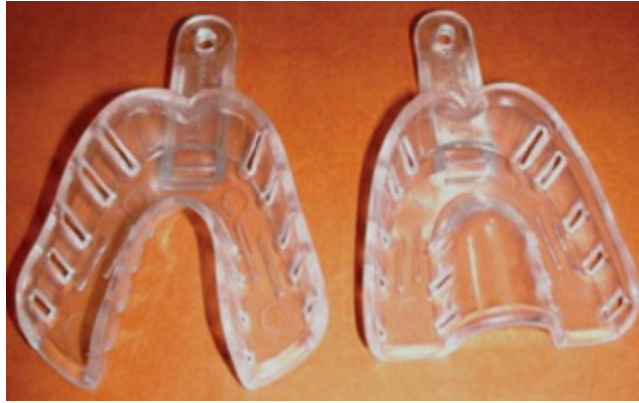

FIG 1.1.3.2 Dentulous prefabricated plastic tray (polycarbonate)



FIG 1.1.3.3 Edentulous prefabricated stainless steel nonperforated tray



Custom trays (Figs 1.1.3.4 and 1.1.3.5)

- Custom/individualized trays can be fabricated and used for the individual patients.
- Custom trays can be made for both dentulous and edentulous arches.
- The custom trays are fabricated on the preliminary casts.
- Custom trays can be made with self-cure resin and shellac baseplate.
- Custom trays provide uniform space for the impression material.
- The flanges of the tray can be modified according to the sulcular extension.
- The dimensional stability and the rigidity is less compared to the stock trays.
- The fabrication process is time consuming.

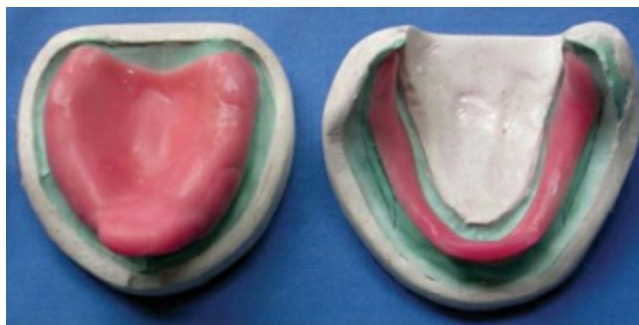

FIG 1.1.3.4 Edentulous custom tray made of self-cure resin

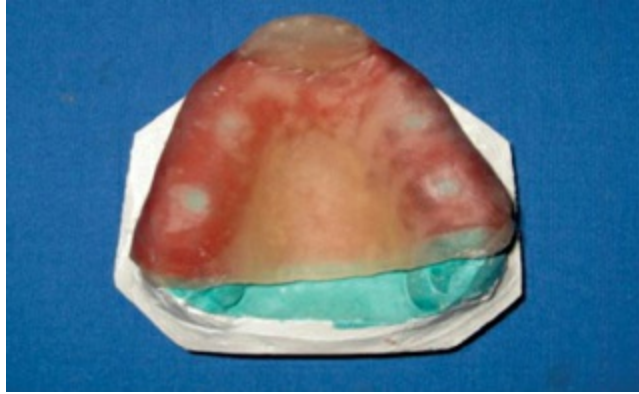
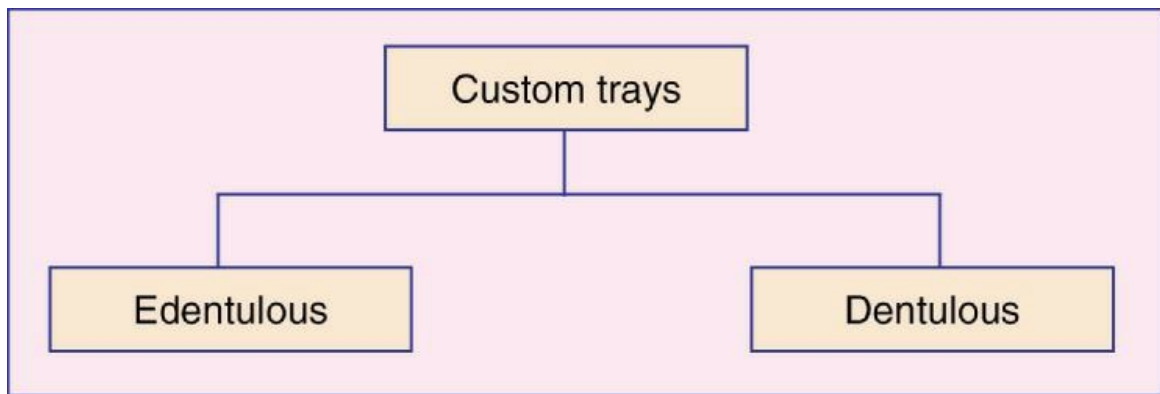


FIG 1.1.3.5 Dentulous custom tray made of self-cure resin

(Custom tray fabrication is dealt in detail in [Chapter 3](#).)



Sectional trays (Fig 1.1.3.6)

- Sectional trays are used for making impressions of dentulous arches in sections, like anterior and posterior sections.
- Sectional impressions are usually used for making provisional or temporary restorations in fixed prosthodontic procedures.
- Sectional trays are perforated trays made of plastic material.



FIG 1.1.3.6 Sectional trays

Triple trays (Figs 1.1.3.7 and 1.1.3.8)

- Triple trays are used for making impressions in fixed prosthodontics.
- While making impressions, registration of teeth to receive the prosthesis, opposing teeth and the interocclusal relationship between the teeth are registered at the same time.
- Triple trays are available in sections as for anterior and posterior quadrants.



FIG 1.1.3.7 Triple trays

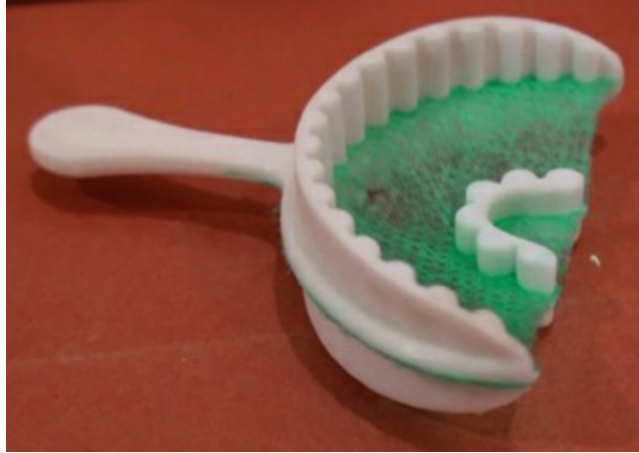

FIG 1.1.3.8 Triple tray

1.1.4. Impressions in complete denture

- Definition of impression
- Objectives of impression making
- Types of impressions
- Theories of impression making
- Materials used for impression making

Definition of impression

A complete denture impression is a negative registration of the entire denture bearing, stabilizing and border seal areas present in the edentulous mouth.

Objectives of impression making

The objectives of impression making in complete dentures are:

1. Preservation of residual alveolar ridge
2. Retention
3. Stability
4. Support
5. Aesthetics

Preservation of residual alveolar ridge

According to Devan, it is important to preserve what already exists than to replace what is missing. Hence, while making impressions, one should keep in mind to reduce soft tissue abuse, minimize bone resorption and to cover maximum support areas.

Retention

Retention of a denture is the resistance of the denture to the forces acting in a vertical direction. (Removal forces in a direction opposite to the denture insertion.) The factors responsible in denture retention are:

- Adhesion
- Cohesion
- Interfacial surface tension
- Peripheral seal
- Atmospheric pressure
- Oral and facial musculature

Atmospheric pressure and peripheral seal are dependent on the impression accuracy. Adhesion cohesion and interfacial surface tension depend on the patient's saliva and close adaptation between the impression and tissues.

Stability

Stability is the ability of the denture to be firm, steady and constant and the resistance of the denture to forces acting in a lateral or horizontal direction. The factors responsible in denture stability are:

- Proper contour and form of the polished surfaces of the denture
- Neuromuscular control of the patient
- Orientation of occlusal plane
- No interferences in denture occlusion with slopes of the ridges
- Adaptation of the labial and buccal flanges

Support

Support is the ability of the denture to resist vertical and other forces

in a direction towards the basal seat. The support of the denture is achieved by wider coverage of the maxillary and mandibular support areas, like:

- Anterior and posterior ridges and slopes within the limitations
- Horizontal surface of the hard palate
- Buccal shelf

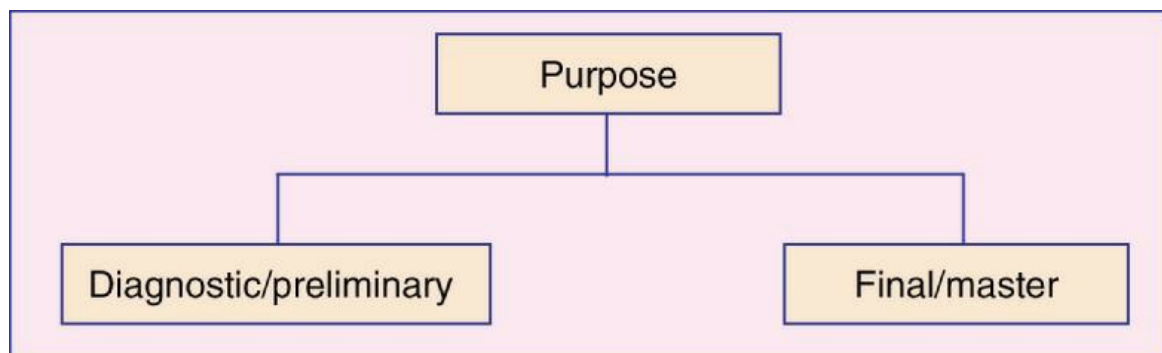
Aesthetics

During impression making, aesthetics is achieved by:

- Adequate support for the lips and cheeks during border moulding of labial and buccal borders.

Types of impression

1. Based on the purpose



Preliminary/diagnostic impression (Figs 1.1.4.1 and 1.1.4.2):

A negative likeness made for the purpose of diagnosis, treatment planning, or the fabrication of a tray. An impression of the edentulous arch used to make a cast for the fabrication of the custom tray or individualized tray. Alginate impression material or impression compound is used in a stock impression tray for making preliminary impressions.

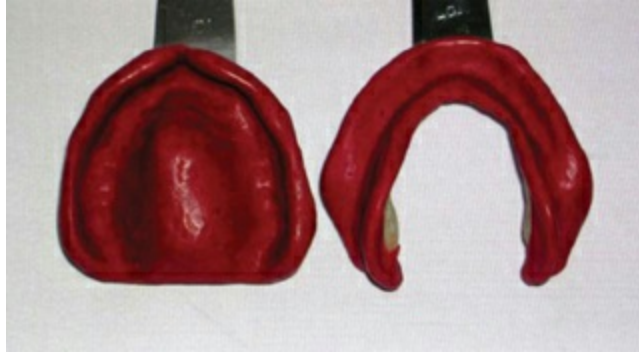

FIG 1.1.4.1 Preliminary edentulous impression made in impression compound

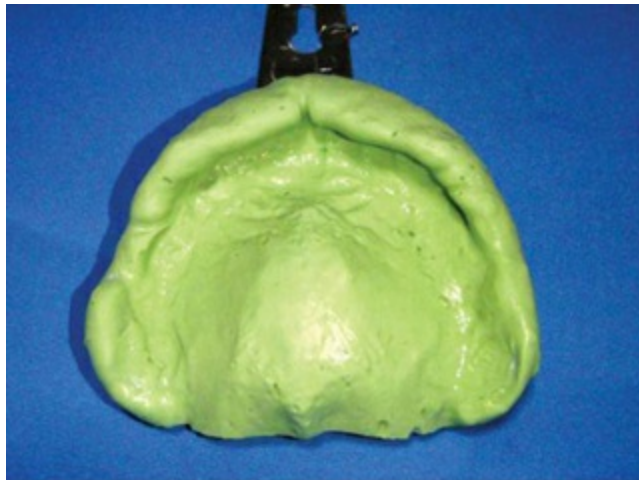

FIG 1.1.4.2 Preliminary edentulous impression made in alginate

Master/final impression:

A negative likeness made for the purpose of fabricating a prosthesis. An impression that represents the completion of the registration of the surface or object. Elastomeric impression material or zinc oxide eugenol impression material is used for making final impressions using a custom tray or individualized tray ([Fig 1.1.4.3](#)).

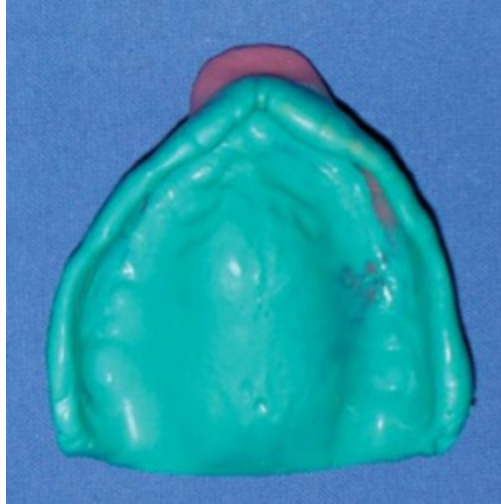
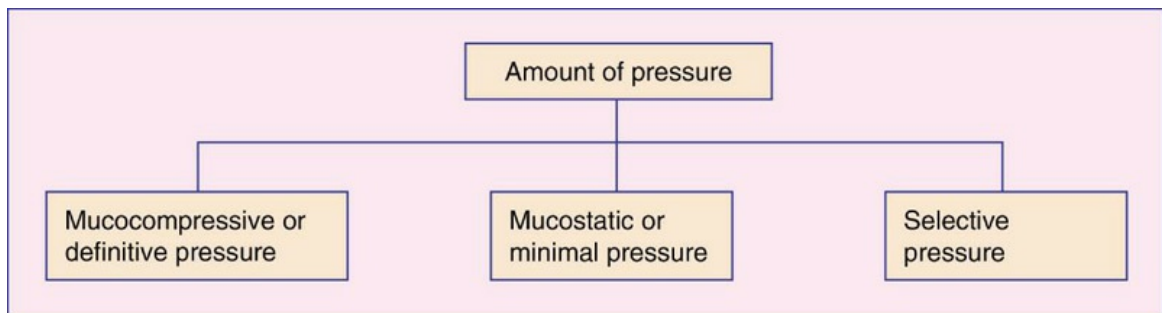


FIG 1.1.4.3 Final edentulous impression made in light body impression material

2. Based on theories of impression making



The impression techniques are based on the amount of pressure applied during making of impressions.

Mucocompressive theory

The tissues of the oral cavity are recorded in the functional position. The impression of the tissues are recorded when pressure is applied on the stress-bearing and nonstress-bearing areas causing maximum tissue displaceability. In this impression technique, impression material with high viscosity like impression compound and putty consistency of elastomeric impression material can be used.

Mucostatic impression theory

In mucostatic impression technique, the tissues are recorded in rest position. The pressure applied in this technique is very minimal. There is no displaceability of tissue. In this impression technique, impression material with low viscosity, like light body consistency of elastomeric impression material, impression plaster, and alginate can be used.

Selective pressure theory

Selective pressure technique employs both mucostatic and mucocompressive techniques. The pressure is applied on the stress-bearing areas and less pressure is applied on the nonstress-bearing areas. This is achieved using custom impression trays with spacer designs. Impression materials, like zinc oxide eugenol impression paste and light body consistency of elastomeric impression material are used. The spacer designs are done by adapting wax on the preliminary cast before making the custom tray. The spacer designs are based on the areas of relief where only minimal pressure is applied. Tissue stops are given in the full spacer design. Four tissue stops are given, two in the canine region and two in the molar region in the maxillary arch spacer design and in the mandibular arch, two tissue stops are placed in the anterior canine region and the buccal shelf area is relieved in the spacer design which acts as a tissue stop. The wax is cut in a square dimension of 4 mm by 4 mm. Tissue stops help in reseating of the tray while making final impression and prevent in the apical displacement of the impression while making an impression.

Spacer Design	Areas of Relief in the Maxillary Arch
Full spacer design (Fig 1.1.4.4)	Full coverage spacer with tissue stops in the canine and molar region
T-shaped spacer design (Fig 1.1.4.5)	Spacer covering anterior residual ridge, rugae region, incisive papilla and midpalatine raphe
I-shaped spacer design (Fig 1.1.4.6)	Spacer covering incisive papilla and midpalatine raphe

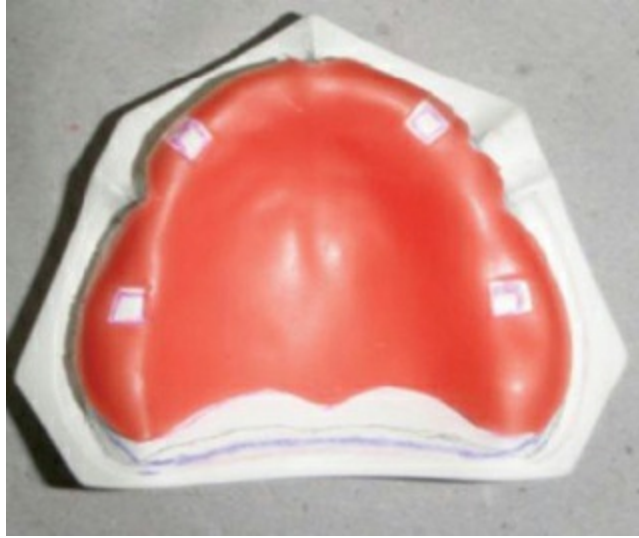

FIG 1.1.4.4 Full spacer design

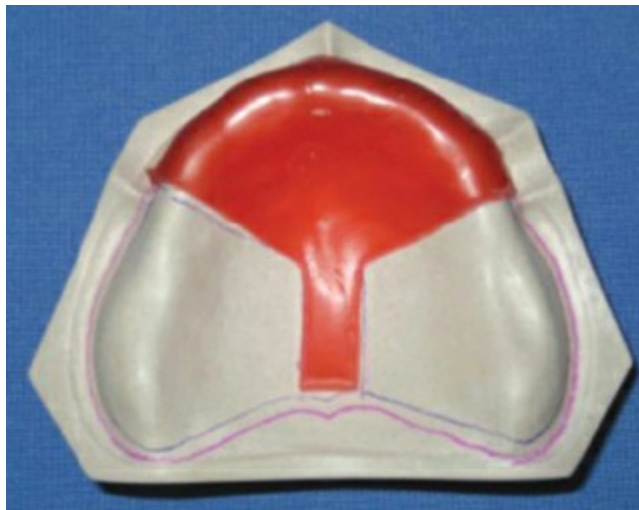

FIG 1.1.4.5 T-shaped spacer design

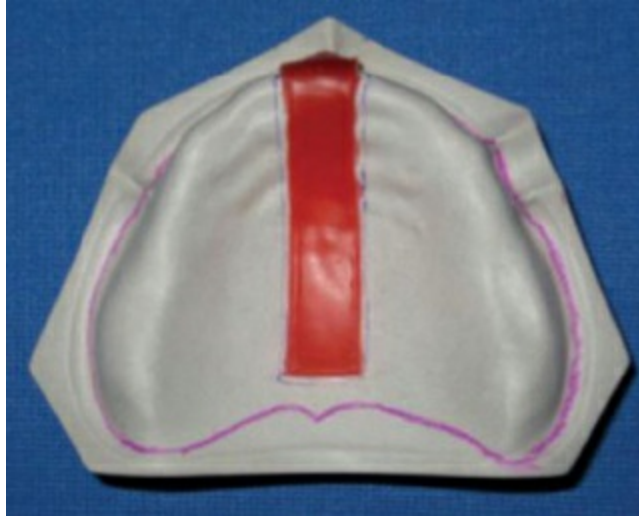

FIG 1.1.4.6 I-shaped spacer design

Areas of relief in the mandibular arch ([Fig 1.1.4.7](#)):

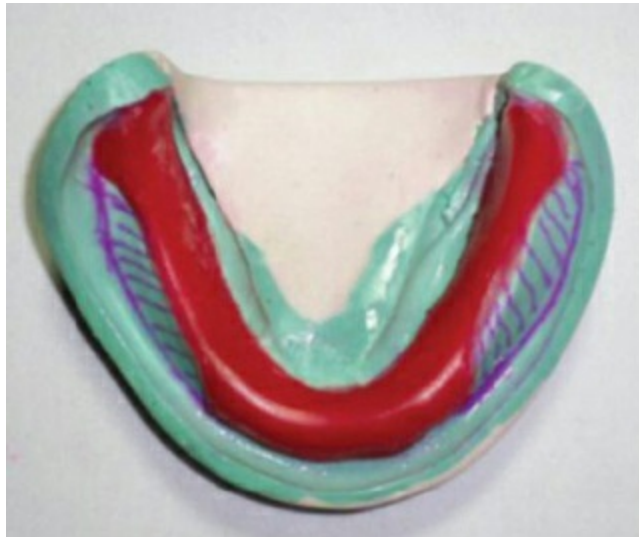

FIG 1.1.4.7 Spacer design in mandibular arch

- Crest of the alveolar ridge
- Mental foramen region
- Genial tubercle region

1.1.5. Dental casts

- Definition
- Requirements of a cast
- Parts of a cast
- Types of cast
- Materials used

Cast

A life-size likeness of some desired form.

Dental cast (Figs 1.1.5.1 and 1.1.5.2)

A positive life-size reproduction of the oral cavity.

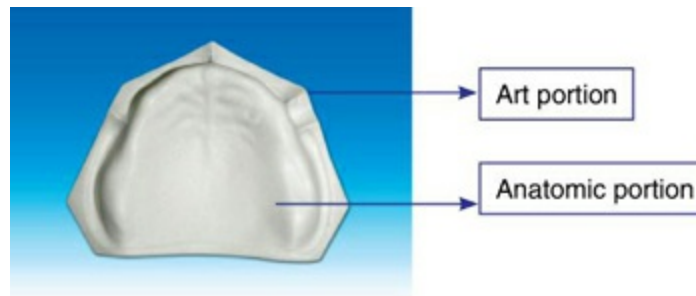


FIG 1.1.5.1 Parts of a dental cast

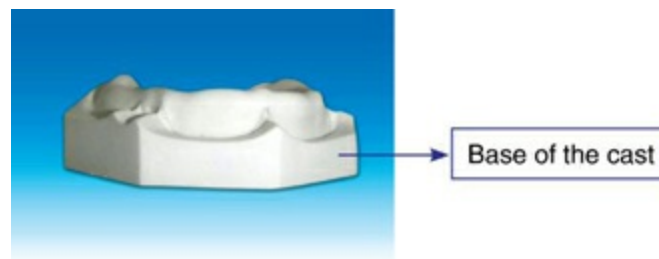
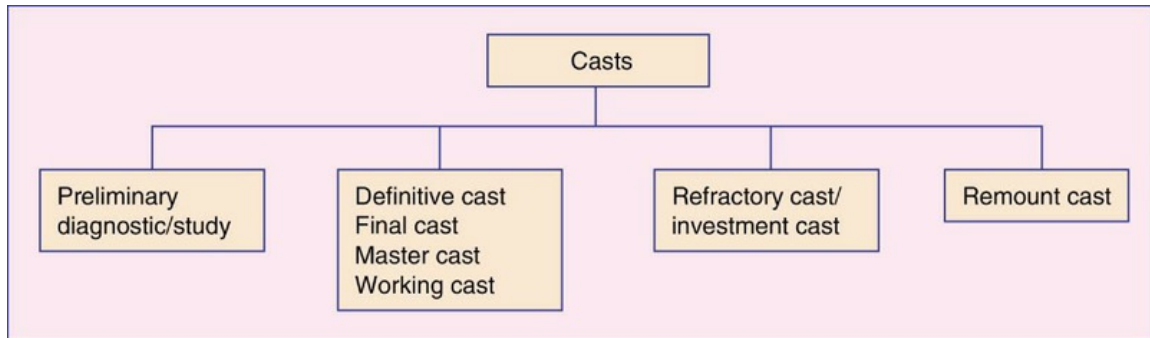


FIG 1.1.5.2 Base of the dental cast



Types of cast

i. Dental cast

- a. Preliminary cast or diagnostic cast, study cast
- b. Final/definitive/master/working cast
- c. Refractory cast
- d. Remount cast

Requirements of the cast

1. Include all anatomic surfaces of the final impression.
2. Show a full peripheral border with a depth of 2–3 mm.
3. Include a 2–3 mm of land area around the entire periphery of the master cast.
4. The land area should be slightly tapered outward.
5. The base of a cast should not be less than 10–12 mm at the thinnest point.
6. The cast contains no bubbles or flaws.

Parts of a cast

- i. Anatomic portion
- ii. Art portion

Anatomic portion

It is the part of the cast that represents the parts of the oral cavity.

Art portion

It is the portion of the cast which forms the base of the cast.

Study or diagnostic cast

A life size reproduction of a part or parts of the oral cavity and/or facial structures for the purpose of study and treatment planning ([Fig 1.1.5.3](#)). It is made from a preliminary impression. The casts are usually made of dental plaster and dental stone.



FIG 1.1.5.3 Diagnostic cast

Master cast or final cast or working cast

A positive replace of the tooth surface and other parts of the dental arch or facial structures which is used for the fabrication of dental restorations or prosthesis ([Figs 1.1.5.4](#) and [1.1.5.5](#)). Master casts are made in dental stone and die stone. Dental stone and die stone have better strength compared to dental plaster.

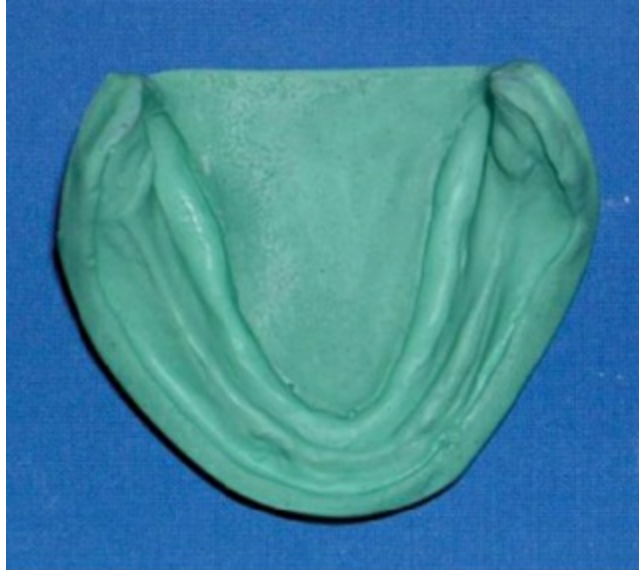

FIG 1.1.5.4 Lower edentulous master cast in dental stone

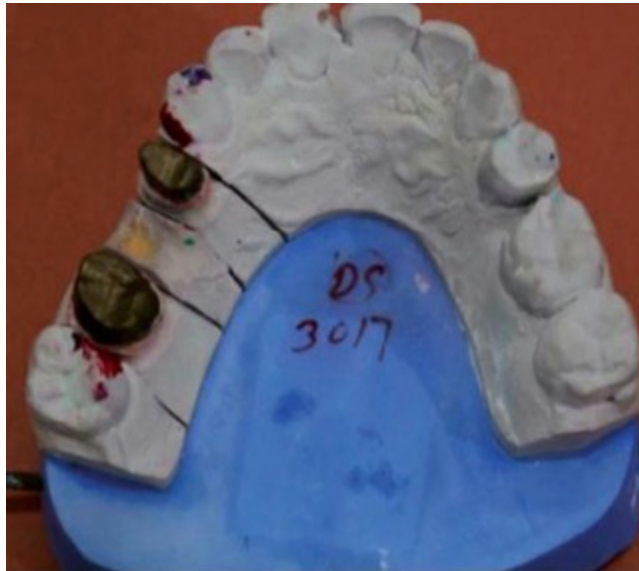

FIG 1.1.5.5 Maxillary dentulous working cast

Refractory cast

A positive replica of the tooth surface or other parts of the dental arch which can withstand high temperatures used in the fabrication of

dental prosthesis with metal denture bases and cast partial dentures (Fig 1.1.5.6). The master casts are duplicated into refractory casts. Type V gypsum-dental stone with high strength and high expansion (investment material) is used for making refractory casts.

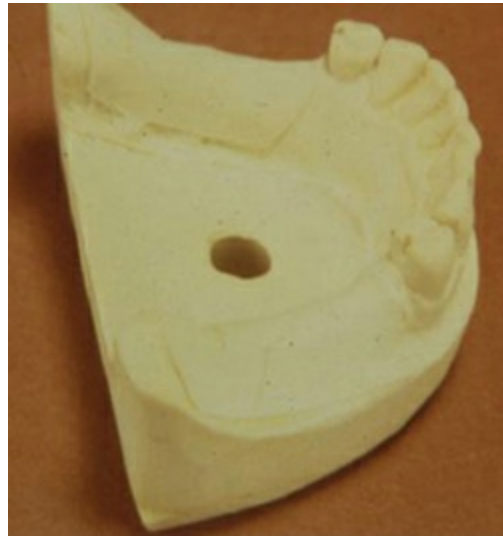

FIG 1.1.5.6 Refractory cast

Remount cast

Remount cast is used for the purpose of mounting of the prosthesis on an articulator (Fig 1.1.5.7). Remount casts are used in the articulator for the correction of processing errors of the complete denture by selective grinding of artificial teeth. The remount casts are made in dental plaster or dental stone.




FIG 1.1.5.7 Remount cast

1.1.6. Record bases

- Definition
- Requirements of a record base
- Types of record base
- Materials used for fabricating record base

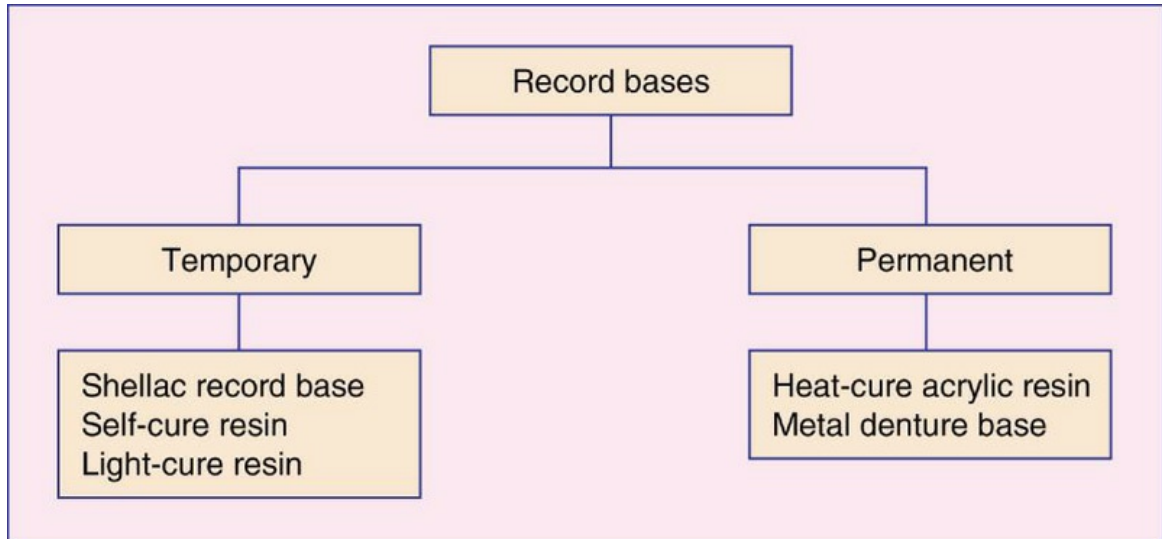
Definition

Record base is an interim denture base used to support the record rim material for recording maxillomandibular relations.

Requirements

- i. The record bases should be rigid.
- ii. The record bases should be dimensionally stable.
- iii. The borders of the record bases should be the same as the finished denture.
- iv. The record base should be closely adapted to the tissue surfaces of the cast.
- v. The record base constructed should permit its use as a base for setting the teeth.
- vi. It should be easy to construct and the material should be inexpensive.

Types of record base



Temporary record base

Shellac record base

Shellac record base is the most commonly used material for the fabrication of a record base (Figs 1.1.6.1 and 1.1.6.2). Shellac is obtained from the resinous exudate of an insect.

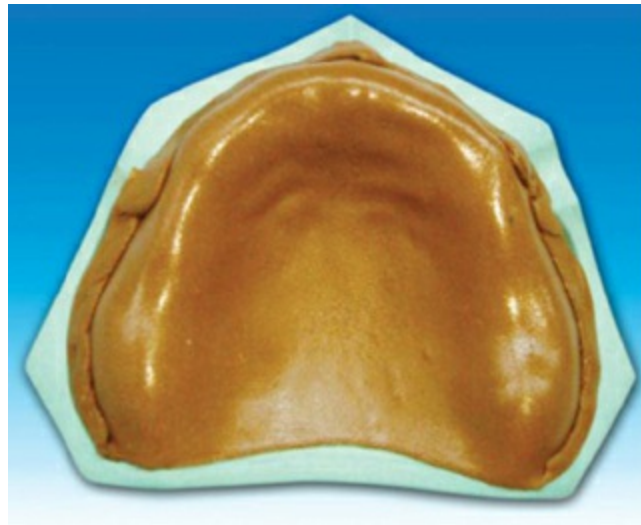

FIG 1.1.6.1 Shellac record base in an edentulous cast

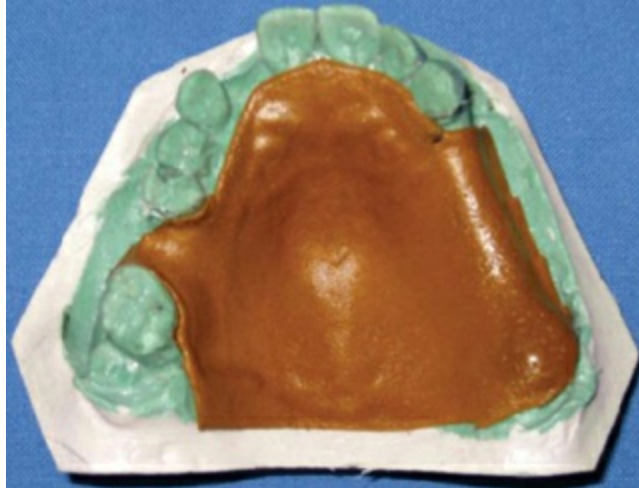

FIG 1.1.6.2 Shellac record base in a partially edentulous cast

Advantages

- Record bases can be easily fabricated – it is not time consuming.
- They are closely adapted to surface the master cast.
- They are inexpensive and easily available.
- Record bases with shellac baseplate can be easily corrected.
- Uniform thickness can be maintained.

Disadvantages

- Shellac baseplates have less strength.
- Shellac baseplates easily break.
- During setting of teeth or fabrication of rims, they tend to distort/wrap due to repeated changes in temperature.

Self-cure resin (Fig 1.1.6.3)

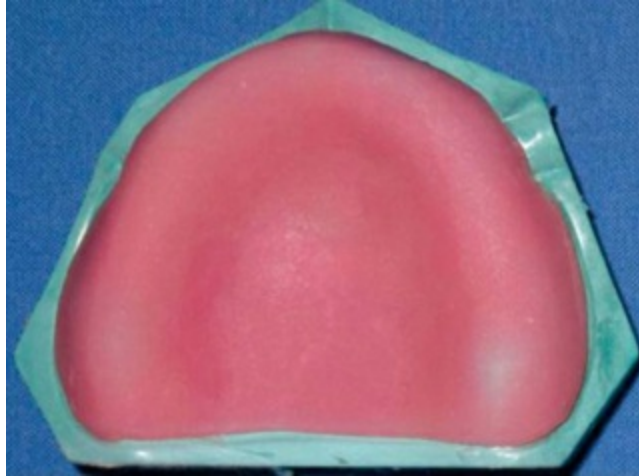

FIG 1.1.6.3 Self-cure resin record base on an edentulous cast

Advantages

- They have better strength.
- They are dimensionally stable.
- They have better stability and do not warp due to repeated changes in temperature.
- They are closely adapted to the tissue surface of the cast.
- They can be easily trimmed with the acrylic burs.

Disadvantages

- Fabrication process is time consuming.
- During fabrication, it is difficult to control the thickness.
- Residual monomer present in record bases can cause irritation to oral tissues.

Light-cure resin (Fig 1.1.6.4)

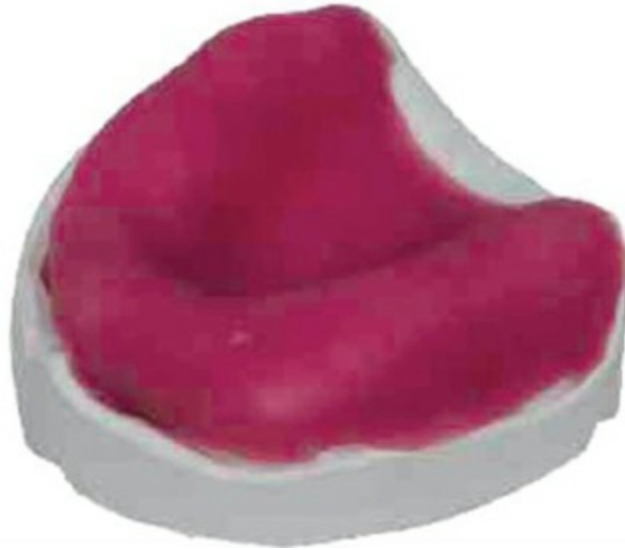

FIG 1.1.6.4 Light-cure record base

Advantages

- They are easy to fabricate.
- They have better stability.
- They are closely adapted to tissue surface of the cast.
- They can be easily trimmed with acrylic burs.
- Residual monomer content is less when compared to self-cure resin.

Disadvantages

- Fabrication process requires a special equipment for curing of the material.
- They have less strength when compared to heat-cure and self-cure resin.
- It is difficult to maintain uniform thickness of the record base.
- The denture base tends to warp after prolonged use.

Permanent record base

Heat-cure acrylic resin (Fig 1.1.6.5)

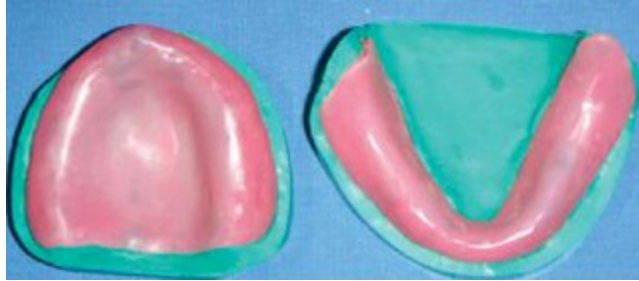

FIG 1.1.6.5 Heat-cure resin record base on an edentulous cast

Advantages

- They are rigid, accurate and dimensionally stable record bases.
- The record bases will become part of the completed prosthesis.
- The processing errors will be minimized.
- They require only minimal finishing and polishing.

Disadvantages

- It is a time consuming process and need to prepare a mounting cast for articulation.

Metal denture bases (**Figs 1.1.6.6 and 1.1.6.7**)

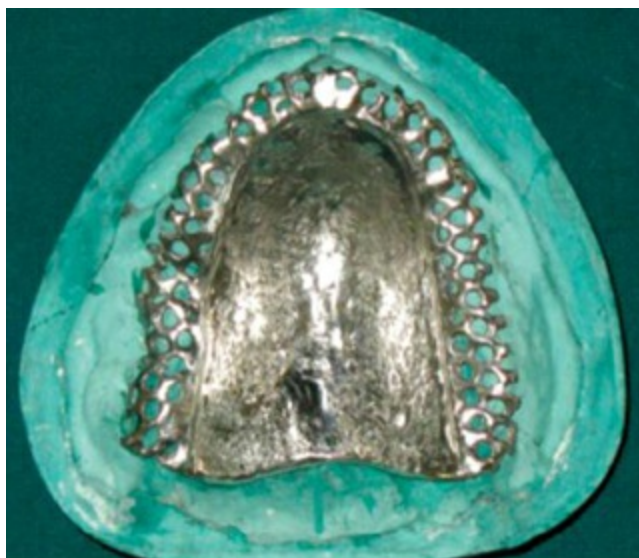

FIG 1.1.6.6 Cr-Co alloy metal denture base on the cast

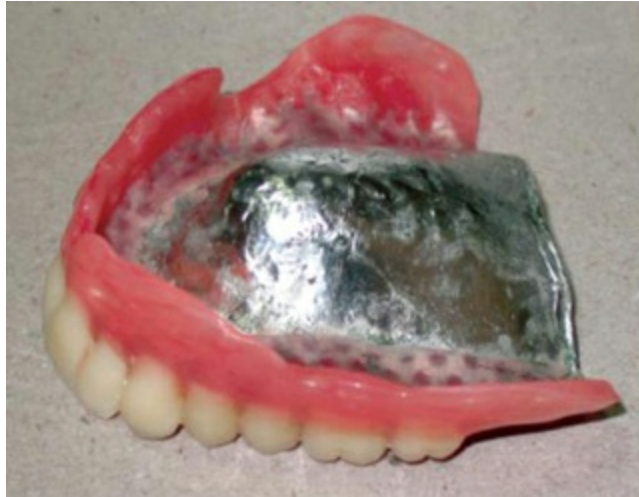

FIG 1.1.6.7 Upper complete denture with metal denture base

Advantages

- They form rigid, accurate, dimensionally stable record bases.
- They become part of the final denture.
- They are good conductors of heat and help in improving sensitivity to heat and cold.
- They are formally advised for patients with frequent breakage and high gag reflex patients.

Disadvantages

- The fabrication process is time consuming.

1.1.7. Occlusion rim

- Definition
- Uses of occlusion rim
- Dimensions of occlusion rim

Definition

Occluding surfaces fabricated on the interim or final denture bases for

the purpose of making maxillomandibular relationship records and arranging teeth.

Uses of occlusion rim

- Occlusion rims are used to establish the level of occlusal plane.
- Occlusion rims are used to establish maxillomandibular records, like vertical and horizontal jaw relations.
- The midline, canine line, high lip line and low lip line, and intercanine distance are recorded on the wax occlusion rims.
- Occlusion rims help to determine the length and width of the artificial teeth.
- Midline of the arch for the correct placement of the central incisors.
- Occlusion rims help to obtain proper lip support.

Dimension of occlusion rims

The occlusion rim should follow the archform of the residual alveolar ridge and should be placed on the ridge where the natural teeth were originally present. The position of the occlusion rim on the edentulous alveolar ridge is as follows:

Arch	Anterior	Premolar	Posterior
Maxillary	Labial to the ridge	On the ridge	Buccal to the ridge
Mandibular	Labial to the ridge	On the ridge	Lingual to the ridge

Dimensions of occlusion rims (Figs 1.1.7.3 and 1.1.7.4)

Arch	Anterior Region		Posterior Region	
	Width	Height (Fig 1.1.7.1)	Width	Height (Fig 1.1.7.2)
Maxillary	20–22 mm from the deepest part of the sulcus	3–5 mm	16–18 mm from deepest part of buccal sulcus in the molar region	6–8 mm
Mandibular	16–18 mm from the deepest part of the sulcus	3–5 mm	At a level of the junction roof, the anterior 2/3rd and posterior 1/3rd of the retromolar pad	6–8 mm

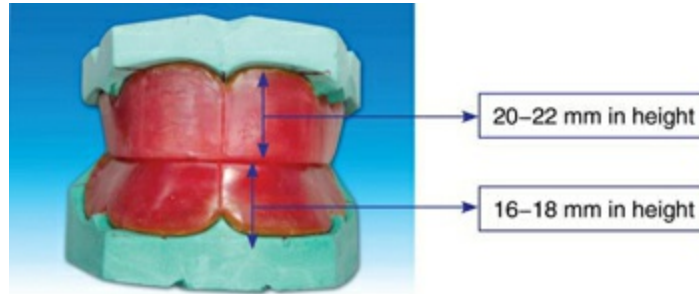


FIG 1.1.7.1 Height of occlusion rim in anterior region

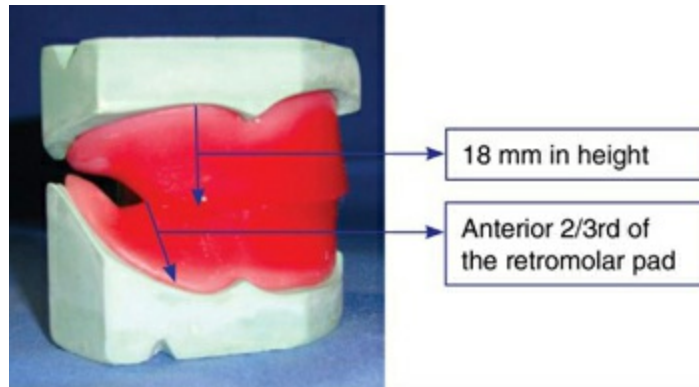


FIG 1.1.7.2 Height of the occlusion rim in the posterior region

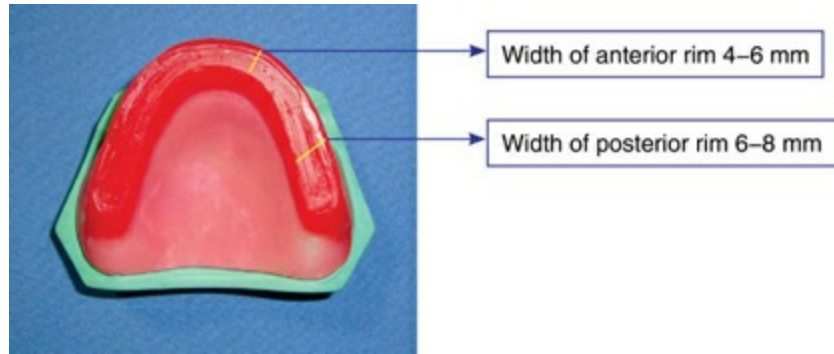


FIG 1.1.7.3 Width of the upper occlusion rim

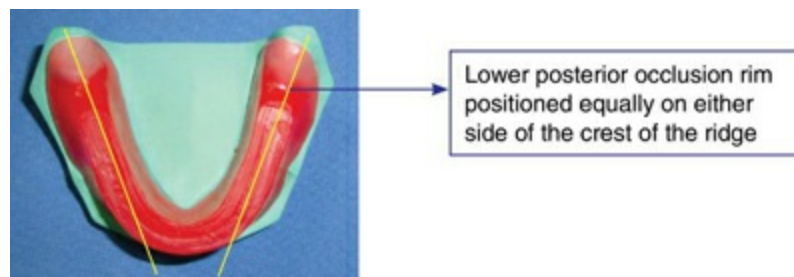


FIG 1.1.7.4 Lower posterior rim in relation to crest of the ridge

1.1.8. Articulators

- Definition
- Classification
- Parts of an articulator
- Requirements of an articulator
- Uses of an articulator
- Advantages of an articulator

Definition

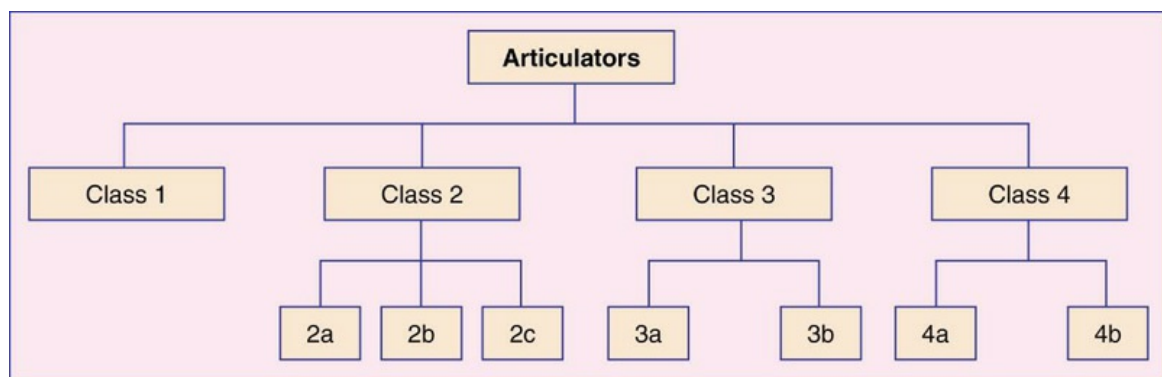
A mechanical device that represents the temporomandibular joints and the jaw members to which the maxillary and mandibular casts may be attached to simulate some or all mandibular movements.

Classification

Articulators are classified as:

- Based on University of Michigan workshop in 1972 (based on the capacity to accept registrations)
- Based on theory of occlusion
- Based on the adjustability of the articulators
- Bergstrom classification of articulators

Based on university of michigan workshop in 1972



Class 1:

Simple holding instruments capable of accepting single static registration, e.g. hinge joint articulator, Barn-Door hinge articulators.

Class 2:

Instruments which permit both horizontal and vertical motions. These are divided into three subclasses.

Class 2a:

Eccentric motion permitted is based on average or arbitrary values, e.g. Bonwill theory articulators, Simplex designed by Alfred Gysi.

Class 2b:

Eccentric motion permitted is based on theories of occlusion, e.g. Monson's articulator.

Class 2c:

Eccentric motion permitted is determined by the patient using engraving methods, e.g. the House articulator.

Class 3:

Instruments that simulate the condylar pathways by using average or mechanical equivalent values for all part of the motion. These are divided into two subclasses.

Class 3a:

They accept a static protrusive registration and use equivalents for other movements, e.g. Hanau model H, Hanau H2, Dentatus, Bergstrom articulator.

Class 3b:

They accept a static lateral registration and use equivalents for other movements, e.g. Trubyte articulator, Panadent, the Kinoscope, Stansberry (tripod-type) articulator, Ney articulator, Hanau 130-21, Teledyne articulator.

Class 4:

These are instruments which accept three-dimensional registration. These are divided into two subclasses.

Class 4a:

The condylar pathway is recorded by the patient through engraving methods and it cannot be modified, e.g. the TMJ articulator.

Class 4b:

This is similar to class 4a but it can be angled or customized, e.g. Gnathoscope, the Denar (D4A) fully adjustable articulator.

Based on theory of occlusion

1. Bonwill theory articulators:

It was designed by WGA Bonwill based on the theory of occlusion which says that "the distance between the condyles is equal to the distance between condyle and the midpoint of the mandibular incisors (Incisal point)". It is also known as the *Theory of Equilateral Triangle*. Theoretically the dimension of the triangle is 4 inches.

2. Conical theory articulators:

It was proposed by RE Hall. The conical theory says that the lower teeth move over the surfaces of the upper teeth as over the surface of the cone, generating an angle of 45° to the occlusal plane.

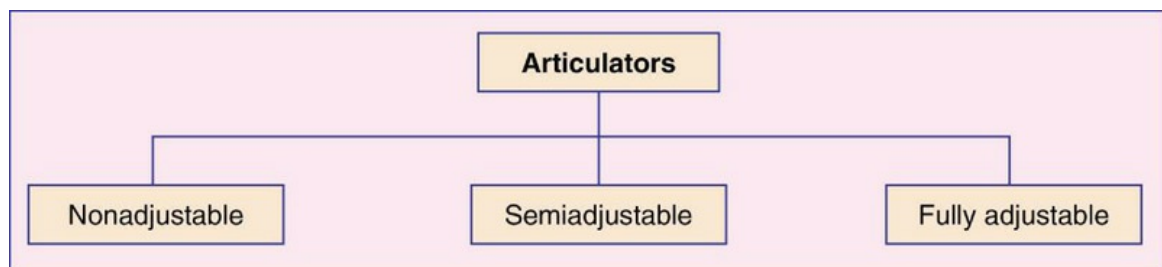
3. Spherical theory articulators:

This theory proposes that the lower teeth move over the upper teeth over a surface of sphere with a diameter of 8 inches. The centre of the sphere was located in the region of glabella. Monson's articulator is a good example based on spherical theory of occlusion.

Based on the adjustability of articulators

The articulators are classified based on the adjustability features like:

- Acceptance of centric relation records.
- Acceptance of face bow records.
- Acceptance of lateral records.
- Adjustable intercondylar distance.



Nonadjustable articulators:

They can open and close in a fixed horizontal axis. They have fixed horizontal path. The incisal guide tables are fixed. They can accept fixed centric relation record.

Semiadjustable articulators:

These articulators have adjustable horizontal condylar paths, lateral condylar paths, incisal guide tables and intercondylar distance. These articulators can be further divided as Arcon and non-Arcon articulators.

Bergstrom classification

Arcon articulators:

This term Arcon was derived by Bergstrom from the words articulating and condyle. The condylar element is attached to the lower member whereas the condylar guidance is attached to the upper member of the articulator (Figs 1.1.8.1 and 1.1.8.2). This articulator resembles the TMJ, e.g. Hanau series and Whip Mix articulator.

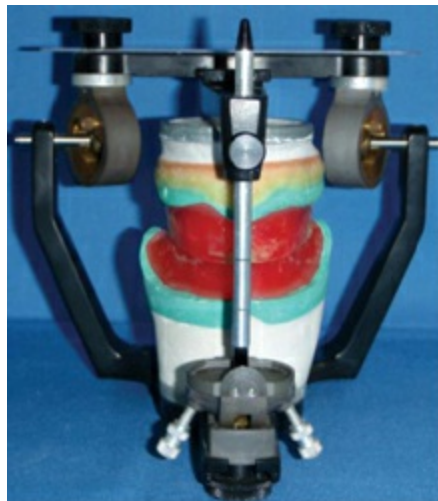


FIG 1.1.8.1 Arcon articulator



FIG 1.1.8.2 Condylar guidance in the upper member and condylar spheres in the lower member

Non-arcon articulators:

These articulators are vice versa to the Arcon type. In these articulators, the condylar elements are attached to the upper member and the condylar guidance is attached to the lower member (Figs 1.1.8.3 and 1.1.8.4), e.g. Hanau H series and Dentatus.



FIG 1.1.8.3 Non-Arcon articulator



FIG 1.1.8.4 Condylar sphere in the upper member and condylar track in the lower member

Requirements

1. It should hold the casts in the established horizontal and vertical relationship.
2. It should provide a correct anterior vertical stop.
3. The casts should be reattached accurately.
4. It should always open and close in the same hinge movement.
5. It should have enough space between the upper and lower segments.
6. The upper and the lower members should be always parallel.
7. It should be made of noncorrosive and rigid material and resist wear and tear.
8. The moveable parts should be nonrigid whereas the nonmovable parts should be rigid.

Parts of the mean value articulator

Mean value articulator: Mean value articulator has a fixed condylar guidance of 33 degrees and incisal guide table ([Fig 1.1.8.5](#)).



FIG 1.1.8.5 Mean value articulator

1. Upper member
2. Lower member
3. Incisal guide table
4. Vertical incisal rod
5. Central pin
6. Condylar guide
7. Stabilizing rod

Upper member:

The upper member is a triangular frame with base of the triangle placed posteriorly and two condylar elements seen projecting on either side of the base (Figs 1.1.8.6 and 1.1.8.7). The apex of the triangle is seen anteriorly and it has a provision to hold the incisal rod with a central pin. The vertical incisal rod can be locked with the help of a thumb screw. The maxillary cast is mounted to the upper member during articulation.




FIG 1.1.8.6 Upper member of the articulator (side view)



FIG 1.1.8.7 Upper member of the articulator (top view)

Lower member:

The lower member of the articulator consists of two components, the horizontal frame and the vertical frame (Figs 1.1.8.8 and 1.1.8.9). The horizontal frame is triangular in shape and corresponds to the lower member. In the centre, the lower mounting plate attached. The anterior aspect of the horizontal frame houses the incisal guide table. The upper part of vertical frame houses the condylar guide.



FIG 1.1.8.8 Lower member of the articulator (side view)



FIG 1.1.8.9 Lower member of the articulator (top view)

Mounting plates:

They are two in number, one for the upper member and other for the lower member (Fig 1.1.8.10). The mounting plates are attached with the help of thumb screw to the articulator. The upper and lower casts are attached to the articulator with the help of mounting plates.

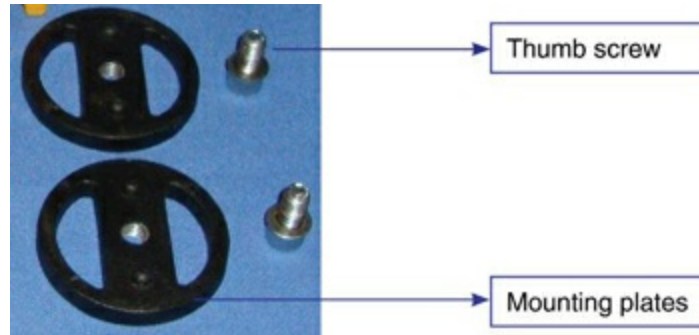


FIG 1.1.8.10 Mounting plates

Incisal guide table:

Incisal guide table determines the incisal guidance of the articulator (Fig 1.1.8.11). The upper surface of the incisal guide table is concave and the vertical incisal rod should be in centre during the articulation. The depth of the concavity is designed to have a slope equal to the average of 15 degree incisal guide angle.




FIG 1.1.8.11 Incisal guide table

Vertical incisal rod:

Vertical incisal rod helps to maintain a fixed distance between the upper and lower members (Figs 1.1.8.12 and 1.1.8.13). It has a pointed

tip which should rest in the centre of incisal table during articulation. The positioning of the incisal pin can be adjusted with the thumb screw attached to the upper member.




FIG 1.1.8.12 Incisal rod at the centre of the guide table




FIG 1.1.8.13 Incisal rod in contact with the incisal guide table

Central pin:

At the midpoint of the incisal rod, there is a hole provided to fix the central pin (Fig 1.1.8.14). The tip of the central pin corresponds to the anterior plane of occlusion during articulation. During teeth setting, the incisal edge of the maxillary incisors should be in contact with the central pin.




FIG 1.1.8.14 Central pin

Condylar guide:

Condylar guide guides the movement of the condyle. In a mean value articulator, the condyle guidance is in two parts, which are condylar track and the condylar element (Fig 1.1.8.15). The condylar track is located in the lower member, inclined at an angle which is average inclination of condylar guidance (33 degrees) of the population. The condylar element is seen projecting out from the base of the triangle of the upper member. A spring is placed within the track to hold the condylar element in its most posterior position.



FIG 1.1.8.15 Condylar guidance with condylar track

Stabilizing rod:

Some mean value articulators have the provision of attaching the stabilizing rod. It is of help to the dentist during his work. It helps to stabilize the upper member of the articulator, while it is kept open (Figs 1.1.8.16 and 1.1.8.17).



FIG 1.1.8.16 Stabilizing rod




FIG 1.1.8.17 Stabilizing rod attached to the upper member

Uses of an articulator

1. To simulate the patient's temporomandibular joint movements and mandibular movements.
2. Mounting the dental casts in a fixed relationship.
3. Mounting the dental casts for proper diagnosis, treatment planning and presentation to patient.
4. To help in the fabrication of fixed and removable restorations.
5. To arrange artificial teeth.
6. To correct and modify the existing restorations.

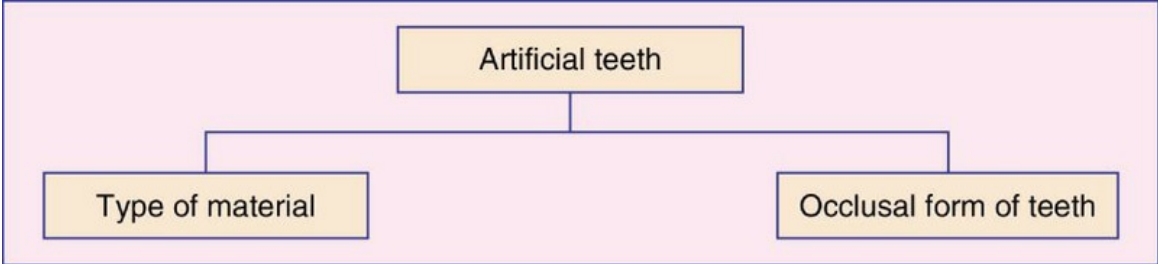
Advantages of an articulator

- It is helpful in visualizing the patient's occlusion with much more ease, especially the lingual occlusion.
- Patient cooperation is not needed while using the articulators because the articulator itself provides the necessary movements.
- It is more comfortable and there is refinement in the work, as there is no disturbance, like shifting of denture base or resiliency of the soft tissues.
- Reduced chair time with the patient.
- Role of patient's saliva, tongue, cheeks and posture is avoided.

1.1.9. Artificial teeth

- Definitions
- Types of artificial teeth

Artificial teeth can be classified based on the type of material and the occlusal form of teeth.

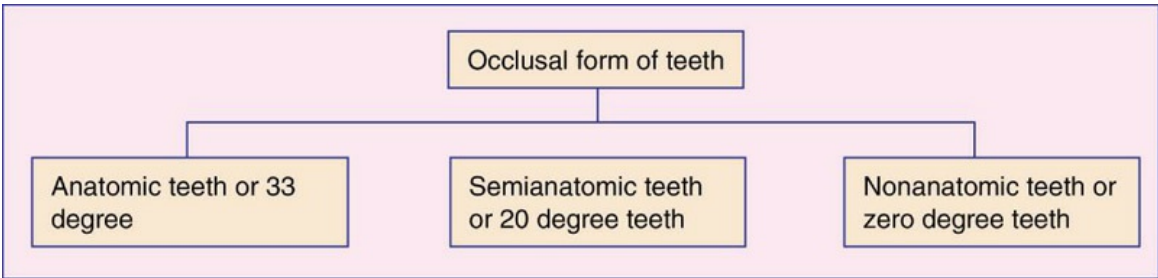


Based on the type of material used

1. Acrylic teeth
2. Porcelain teeth
3. Composite teeth

Based on the occlusal form of teeth

1. Anatomic teeth
2. Semianatomic teeth
3. Nonanatomic teeth



Anatomic teeth (Fig 1.1.9.1)

Indications	Advantages	Disadvantages
Used in high and well rounded residual alveolar ridges	<ul style="list-style-type: none"> • Better aesthetics • Chewing efficiency is better 	<ul style="list-style-type: none"> • Difficult to obtain balanced occlusion in complete dentures • Steep cuspal angulation will generate more horizontal forces during function

Indications	Advantages	Disadvantages
Used in high and well rounded residual alveolar ridges	<ul style="list-style-type: none"> • Better aesthetics • Chewing efficiency is better 	<ul style="list-style-type: none"> • Difficult to obtain balanced occlusion in complete dentures • Steep cuspal angulation will generate more horizontal forces during function

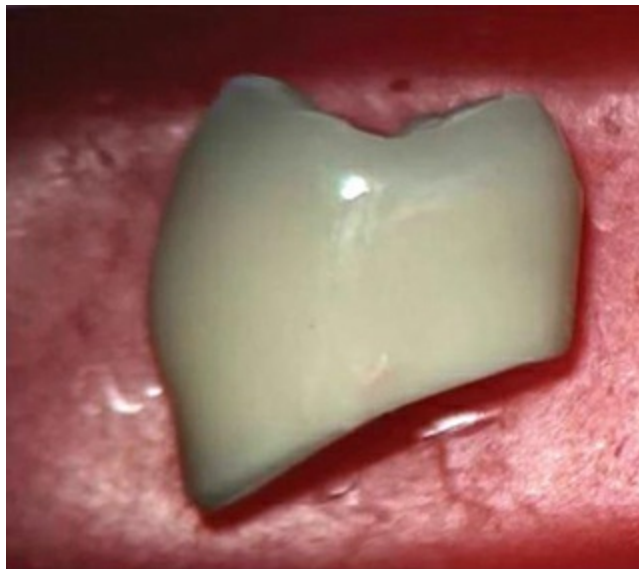


FIG 1.1.9.1 Anatomic teeth

Semianatomic teeth (Fig 1.1.9.2)

Indications	Advantages	Disadvantages
Used in well formed and low rounded residual alveolar ridges	<ul style="list-style-type: none"> • Easy to obtain balanced occlusion in complete dentures • Shallow cuspal inclination will generate 	<ul style="list-style-type: none"> • Aesthetics is less compared to anatomic teeth

	less horizontal forces compared to anatomic teeth	<ul style="list-style-type: none"> • Chewing efficiency is less compared to anatomic teeth
--	---	---

Indications	Advantages	Disadvantages
Used in well formed and low rounded residual alveolar ridges	<ul style="list-style-type: none"> • Easy to obtain balanced occlusion in complete dentures • Shallow cuspal inclination will generate less horizontal forces compared to anatomic teeth 	<ul style="list-style-type: none"> • Aesthetics is less compared to anatomic teeth • Chewing efficiency is less compared to anatomic teeth

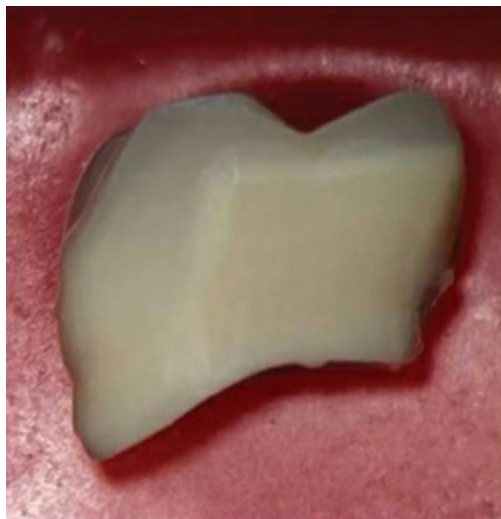

FIG 1.1.9.2 Semianatomic teeth

Nonanatomic teeth (Fig 1.1.9.3)

Indications	Advantages	Disadvantages
Used in patients with highly resorbed ridges Used in patients with poor neuromuscular control	<ul style="list-style-type: none"> • Horizontal forces are not generated • Less forces are transferred to residual alveolar ridges 	<ul style="list-style-type: none"> • Difficult to attain balanced occlusion • Poor aesthetics • Poor chewing efficiency

Indications	Advantages	Disadvantages
Used in patients with highly resorbed ridges Used in patients with poor neuromuscular control	<ul style="list-style-type: none"> • Horizontal forces are not generated • Less forces are transferred to residual alveolar ridges 	<ul style="list-style-type: none"> • Difficult to attain balanced occlusion • Poor aesthetics • Poor chewing efficiency

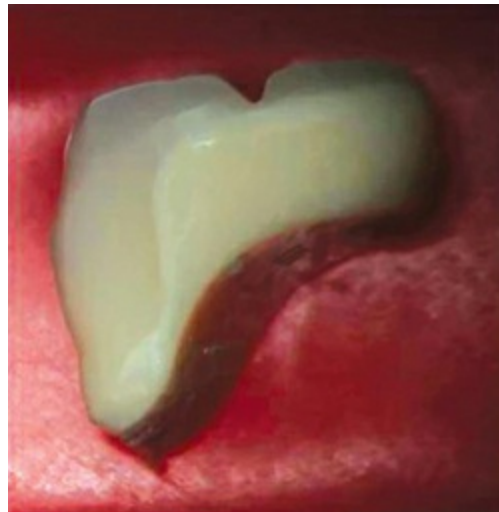


FIG 1.1.9.3 Nonanatomic teeth

Acrylic teeth

Indications	Advantages	Disadvantages
<ul style="list-style-type: none"> • Used in situations where opposing teeth are natural teeth • Used in situations where interarch space is less • Used in resorbed residual ridges 	<ul style="list-style-type: none"> • Acrylic teeth chemically bond to the acrylic denture base • Acrylic teeth prevent wearing of natural teeth when used in denture opposing natural teeth • Acrylic teeth can be easily trimmed • Acrylic teeth cause less trauma to the residual ridge 	<ul style="list-style-type: none"> • Acrylic teeth abrade faster • Stain and discolour faster • Acrylic teeth have to be replaced faster because of excessive wear

Indications	Advantages	Disadvantages
<ul style="list-style-type: none"> • Used in situations where opposing teeth are natural teeth • Used in situations where interarch space is less • Used in resorbed residual ridges 	<ul style="list-style-type: none"> • Acrylic teeth chemically bond to the acrylic denture base • Acrylic teeth prevent wearing of natural teeth when used in denture opposing natural teeth • Acrylic teeth can be easily trimmed • Acrylic teeth cause less trauma to the residual ridge 	<ul style="list-style-type: none"> • Acrylic teeth abrade faster • Stain and discolour faster • Acrylic teeth have to be replaced faster because of excessive wear

Porcelain teeth

Indications	Advantages	Disadvantages
<ul style="list-style-type: none"> • Used in situations where the interarch space is more • Used in situations with well-formed ridges 	<ul style="list-style-type: none"> • Resistant to stains and wear • Resistant to abrasion • Good aesthetics 	<ul style="list-style-type: none"> • Do not bond chemically with the acrylic denture base • Cannot be used in opposing natural dentition as it causes natural teeth wear • Porcelain teeth cannot be trimmed • Porcelain teeth cause more trauma to the underlying residual ridge • Porcelain is a brittle material hence it may fracture

Indications	Advantages	Disadvantages
<ul style="list-style-type: none"> • Used in situations where the interarch space is more • Used in situations with well-formed ridges 	<ul style="list-style-type: none"> • Resistant to stains and wear • Resistant to abrasion • Good aesthetics 	<ul style="list-style-type: none"> • Do not bond chemically with the acrylic denture base • Cannot be used in opposing natural dentition as it causes natural teeth wear • Porcelain teeth cannot be trimmed • Porcelain teeth cause more trauma to the underlying residual ridge • Porcelain is a brittle material hence it may fracture

1.1.10. Occlusion in complete denture

- Definition
- Objectives
- Occlusion in natural dentition
- Occlusion in artificial dentition
- Factors influencing balanced occlusion

Definition

Occlusion

The relationship between the occlusal surfaces of the maxillary and mandibular teeth when they are in contact.

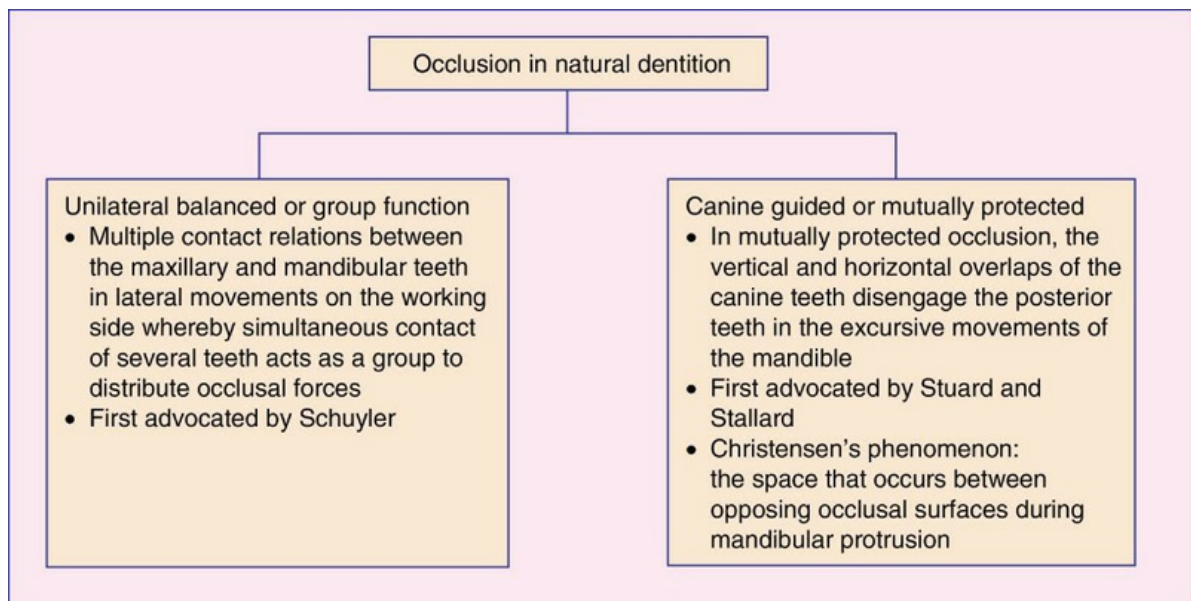
Articulation

Articulation is the dynamic movement of contacting teeth as the mandible moves to and fro from centric relation and eccentric relation.

Objectives

- Occlusion should provide maximum intercuspation of the maxillary and mandibular teeth in centric relation position.
- Occlusion should provide maximum chewing efficiency.
- Occlusion in complete dentures should minimize the stresses to the residual alveolar ridges.
- Occlusion should provide stability and retention to the dentures.
- Occlusion should not cause any trauma to the underlying soft tissue and bone.

Occlusion in natural dentition



Occlusion in artificial dentition

Bilateral balanced occlusion

Bilateral balanced occlusion is the bilateral simultaneous anterior and posterior occlusal contact of teeth in centric and eccentric positions.

Objective

In natural dentition, space occurs between the occlusal surfaces posteriorly during mandibular protrusion is called Christensen's phenomenon.

The concept of Christensen's phenomenon occurring in natural dentition cannot be incorporated in complete dentures because during protrusion the maxillary denture will be displaced downwards resulting in instability of dentures. Hence simultaneous contact of all teeth should be provided in complete dentures during lateral movements of the mandible.

Factors influencing balanced occlusion

- Condylar guidance
- Incisal guidance
- Plane of occlusion
- Cuspal inclination
- Compensating curves

Condylar guidance

- It is the mandibular guidance generated by condyle and the articular disc traversing the contour of the glenoid fossa.

Incisal guidance

- The influence of the contacting surfaces of mandibular and maxillary anterior teeth during mandibular movements.

Plane of occlusion

- It is the average plane established by the incisal and occlusal

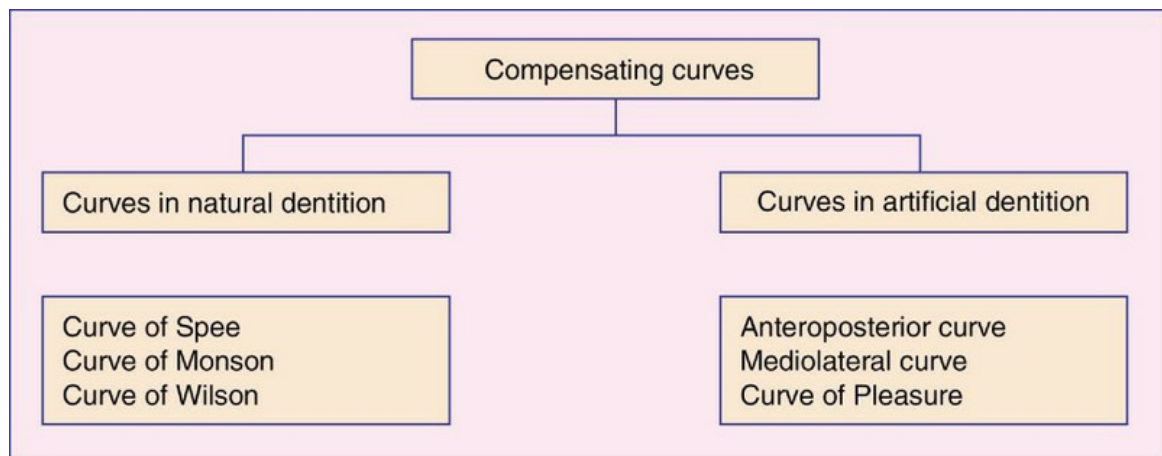
surfaces of the teeth.

Cuspal inclination

- Cuspal inclination is the angle by the average slope of a cusp with the occlusal plane.

Compensating curves

- It is the anteroposterior curvature and the mediolateral curvature in the alignment of the occluding surfaces and incisal edges of the artificial teeth that are used to develop balanced occlusion.



- **Anteroposterior curve:** The anatomic curve established by the occlusal alignment of the teeth, as projected onto the median plane, beginning with the cusp tip of the mandibular canine and following the buccal cusp tips of the premolar and molar teeth, continuing through the anterior border of the mandibular ramus, ending with the anterior most portion of the mandibular condyle. It was first described by Ferdinand Graf Spee, German anatomist, in 1890.
- **Curve of Monson:** Eponym for a proposed ideal curve of occlusion in which each cusp and incisal edge touches or conforms to a segment of the surface of a sphere 8 inches in diameter with its

centre in the region of the glabella.

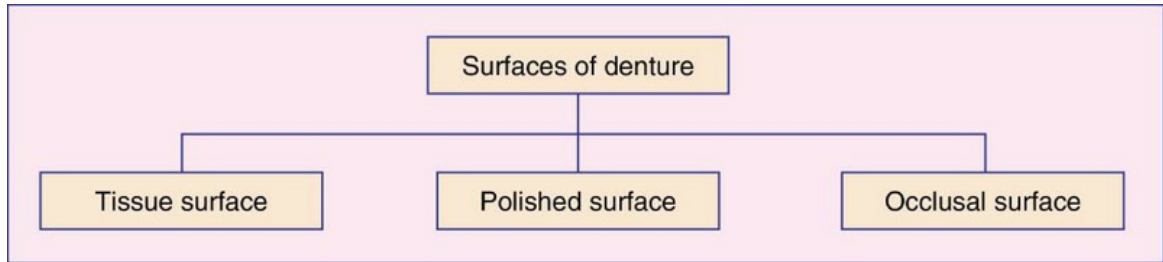
- **Curve of Pleasure:** Eponym for a helicoid curve of occlusion that, when viewed in the frontal plane, conforms to a curve that is convex from the superior view, except for the last molars which reverse that pattern. In excessive wear of the teeth, the obliteration of the cusps and formation of either flat or cupped-out occlusal surfaces, associated with reversal of the occlusal plane of the premolar, first and second molar teeth (the third molars being generally unaffected), whereby the occlusal surfaces of the mandibular teeth slope facially instead of lingually and those of the maxillary teeth incline lingually.
- **Curve of Wilson:** Eponym for the mediolateral curve: In the theory that occlusion should be spherical, the curvature of the cusps as projected on the frontal plane expressed in both arches; the curve in the lower arch being concave and the one in the upper arch being convex. The curvature in the lower arch is affected by an equal lingual inclination of the right and left molars so that the tip points of the corresponding cross-aligned cusps can be placed into the circumferences of a circle. The transverse cuspal curvature of the upper teeth is affected by the equal buccal inclinations of their long axes.

1.1.11. Parts and surfaces of a complete denture

- Parts of the denture
- Surfaces of the denture

Surfaces of the denture

There are three surfaces of the denture.



Tissue surface

Tissue surface is that part of the denture which is in contact with the patient's tissue (Fig 1.1.11.1). It should always be free of voids and nodules to avoid irritation to the tissue.




FIG 1.1.11.1 Tissue surface of the denture

Polished surface

Polished surface is that part of the denture which refers to the labial, lingual and buccal flanges and the palatal surface (Fig 1.1.11.2). This surface of the denture should be well polished.

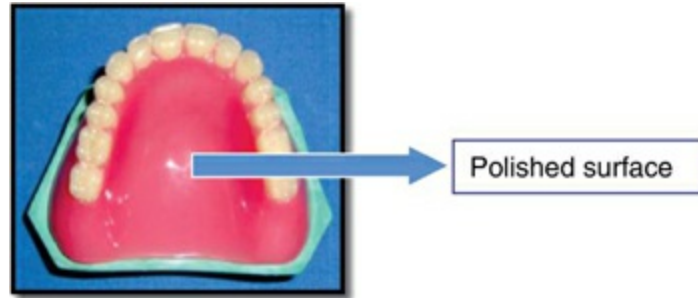


FIG 1.1.11.2 Polished surface of the denture

Occlusal surface

Occlusal surface is that part of the denture which refers to the occlusal surfaces of the artificial denture teeth (Fig 1.1.11.3). It usually contains the cusps of the teeth and sluice ways which aids in mastication.

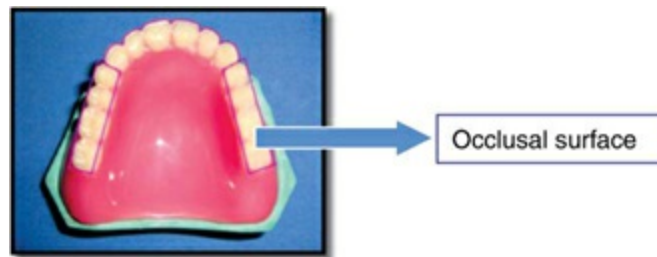
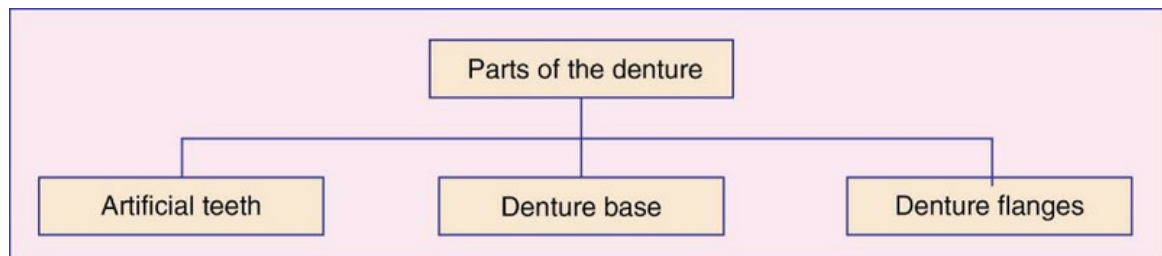


FIG 1.1.11.3 Occlusal surface of the denture

Parts of the denture



Artificial teeth

Artificial teeth are the most important part of the denture according to both patient and the dentist as they are responsible for patient's aesthetics, mastication and speech (Fig 1.1.11.4).

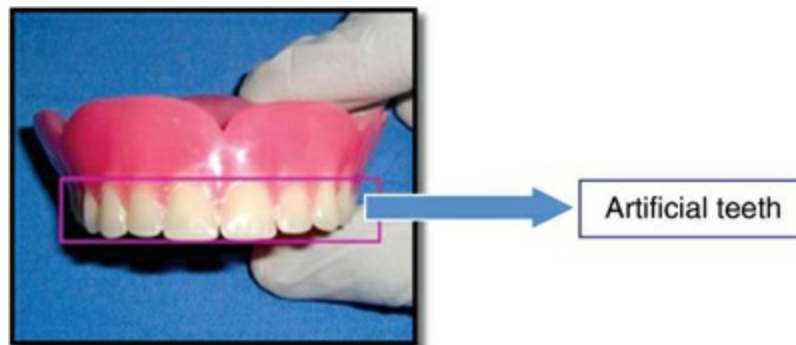


FIG 1.1.11.4 Artificial teeth of the denture

Denture base

Denture base is that part of the denture to which the artificial teeth are attached (Fig 1.1.11.5). It is usually made of acrylic resin but metals, like gold, silver, nickel, and chromium alloys, can be used.

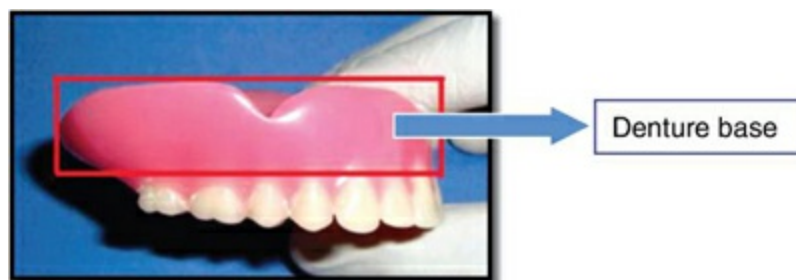
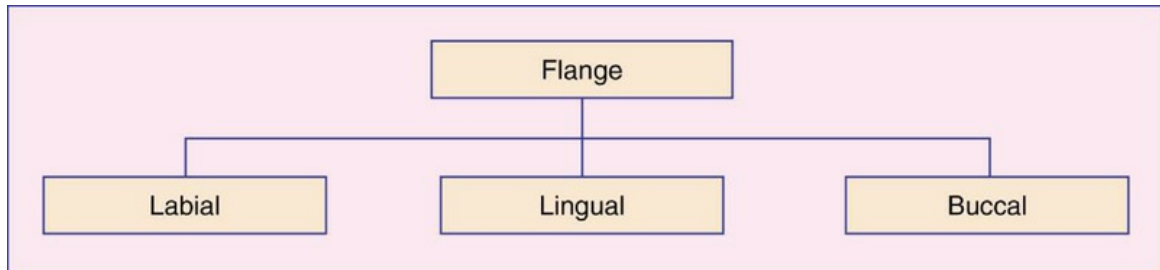


FIG 1.1.11.5 Denture base of the denture

Denture flanges

There are three different flanges. They are labial, lingual and the buccal flanges.



Labial flange

The portion of the flange which occupies the labial vestibule is the labial flange and usually has "V" shaped notch to accommodate the labial frenum (Fig 1.1.11.6).

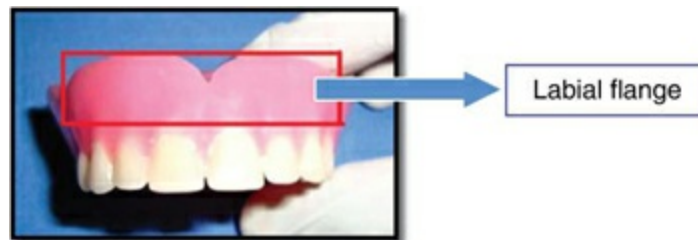


FIG 1.1.11.6 Labial flange of the upper denture

Lingual flange

Lingual flange is that part of the mandibular denture which occupies the space between the tongue and ridge of the mandible; it should be in contact with the floor of the mouth to provide peripheral seal (Fig 1.1.11.7).



FIG 1.1.11.7 Lingual flange of the lower denture

Buccal flange

The portion of the denture which occupies the buccal vestibule is the buccal flange (Fig 1.1.11.8). It provides fullness to cheeks in the maxillary denture and has a relief or a wide notch to accommodate the buccal frenum. The buccal flange helps to transfer the occlusal force to the buccal shelf area in the mandibular denture.

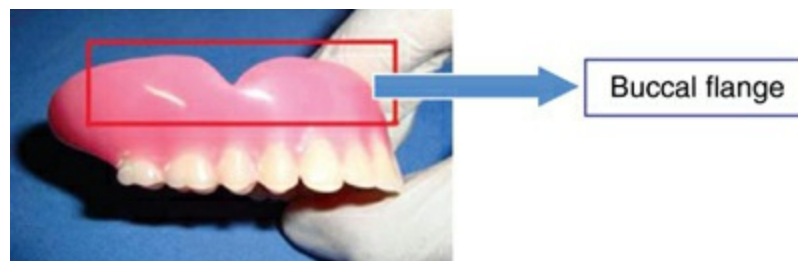


FIG 1.1.11.8 Buccal flange of the upper denture

1.1.12 Clinical steps in the fabrication of removable complete denture prosthesis

The fabrication of the removable complete denture prosthesis involves a series of clinical and laboratory steps. The clinical visits and laboratory steps include:

Clinical Visits	Laboratory Steps
1. Primary impression	1. Fabrication of custom trays
2. Border moulding and secondary impression	2. Fabrication of record bases and occlusion rims
3. Recording of maxillomandibular relations	3. Setting of artificial teeth in the articulator

4. Try in of wax dentures	4. Waxing of the dentures
5. Final denture insertion	5. Processing of waxed dentures
6. Post-insertion denture problems and management	

Clinical Visits	Laboratory Steps
1. Primary impression	1. Fabrication of custom trays
2. Border moulding and secondary impression	2. Fabrication of record bases and occlusion rims
3. Recording of maxillomandibular relations	3. Setting of artificial teeth in the articulator
4. Try in of wax dentures	4. Waxing of the dentures
5. Final denture insertion	5. Processing of waxed dentures
6. Post-insertion denture problems and management	

Primary impression

A negative likeness or impressions of the maxillary and mandibular edentulous arches are made for the purpose of diagnosis, treatment planning or the fabrication of the custom tray. The preliminary impressions are made with impression compound, alginate or putty consistency of elastomeric impression material (Figs 1.1.12.1 to 1.1.12.7b).

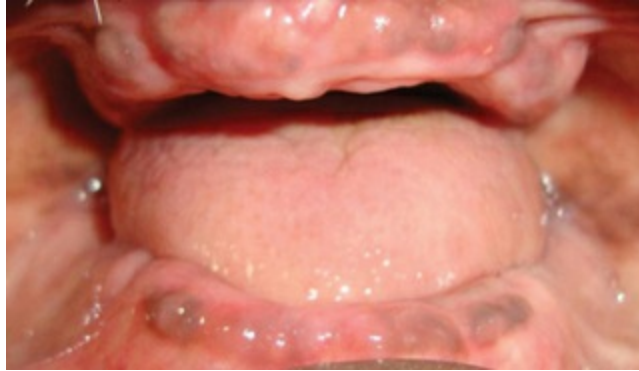

FIG 1.1.12.1 Edentulous maxillary and mandibular arches




FIG 1.1.12.2 Primary impression is made with inelastic reversible material like impression compound

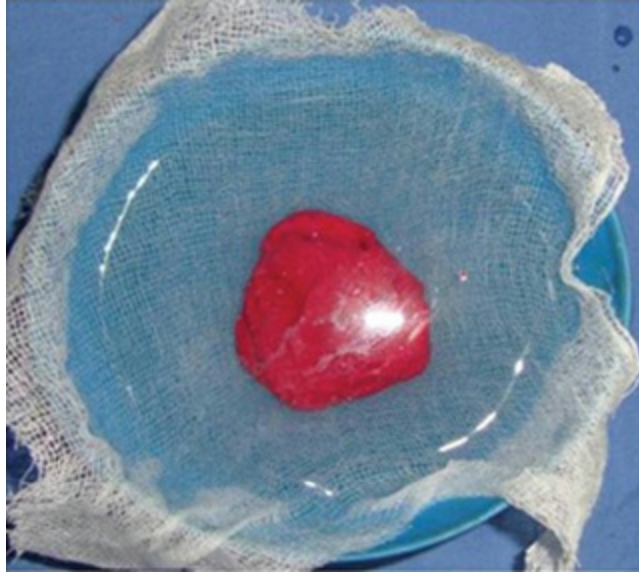

FIG 1.1.12.3 Impression compound is softened in hot water

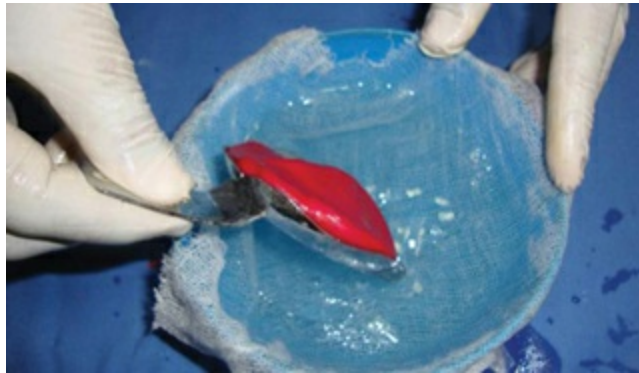


FIG 1.1.12.4 Softened impression compound placed in the edentulous stock tray

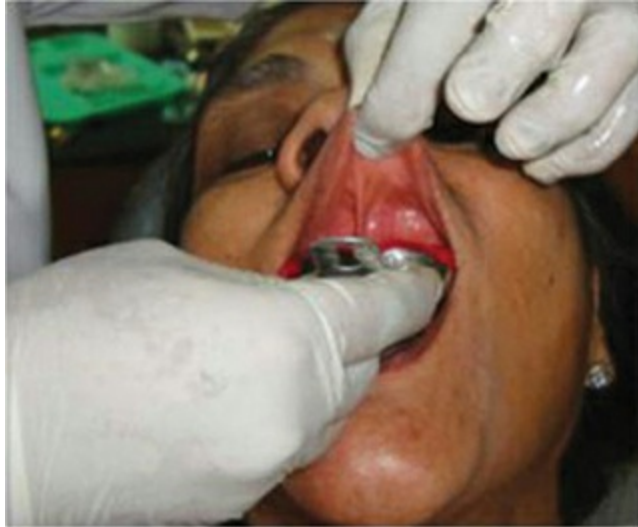

FIG 1.1.12.5 The impression tray with the softened impression compound positioned in the patient's oral cavity and the impression is made

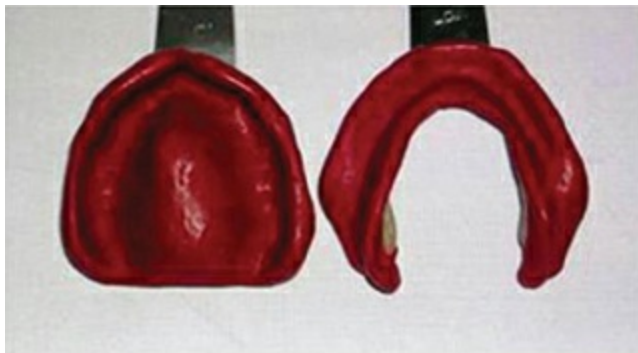

FIG 1.1.12.6 Maxillary and mandibular edentulous impression made with impression compound

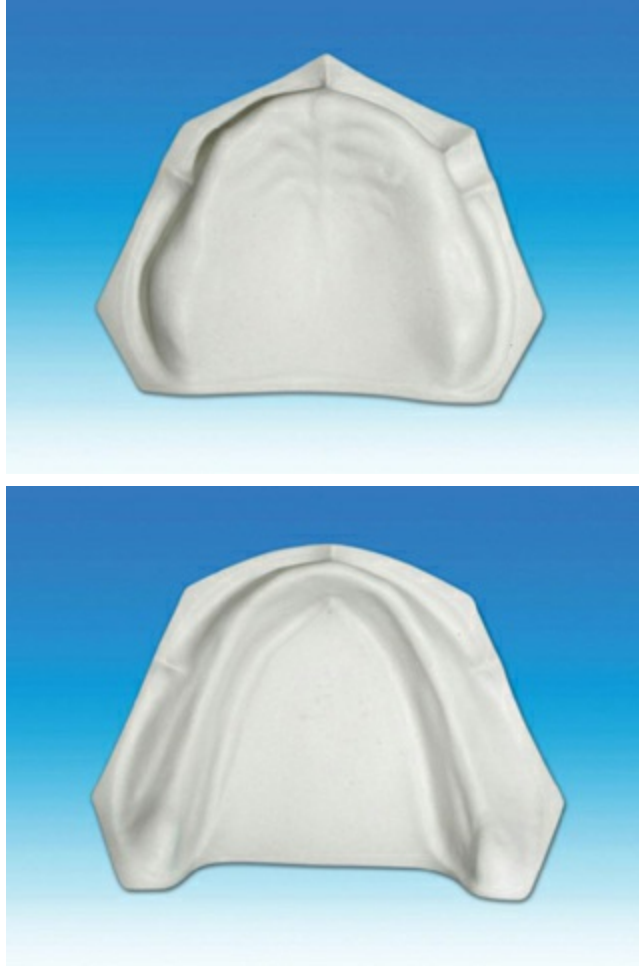

FIG 1.1.12.7A, B Maxillary and mandibular edentulous primary casts in dental plaster

Border moulding and secondary impression

The borders of the custom tray are shaped or contoured to the sulcular extension of edentulous maxillary and mandibular arches with the help of tracing compound or heavy body elastomeric impression material to obtain a peripheral seal in the custom tray. Master or final impression is then made with zinc oxide eugenol impression paste or light body elastomeric impression material (Figs 1.1.12.8a to 1.1.12.15).

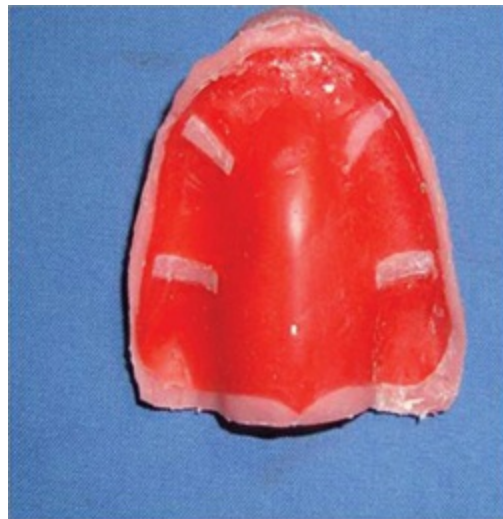
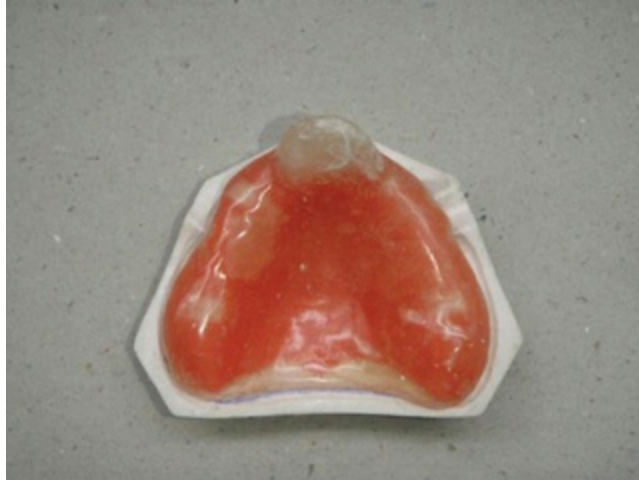
FIG 1.1.12.8A, B Maxillary and mandibular custom trays



FIG 1.1.12.9 Tracing compound for border moulding



FIG 1.1.12.10 Tracing compound softened over a flame

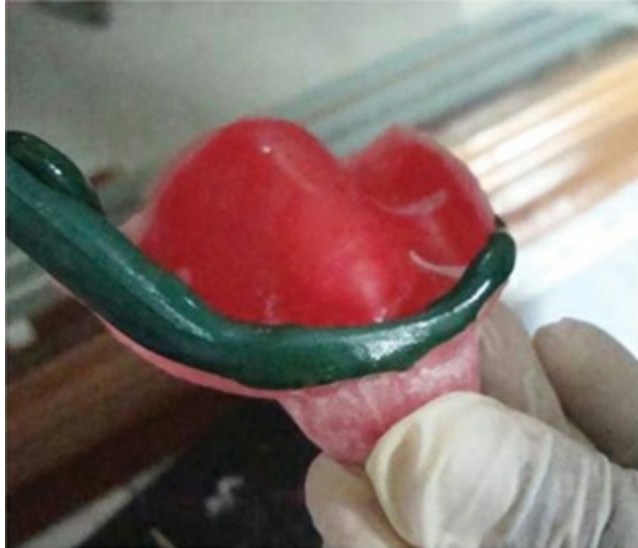

FIG 1.1.12.11 Softened tracing compound placed on the borders of the custom tray

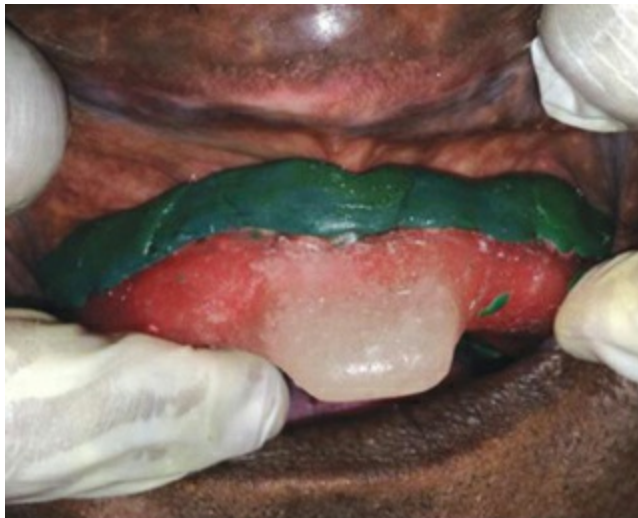

FIG 1.1.12.12 Custom tray with the tracing compound positioned in the patient's oral cavity and the sulcular extensions are moulded

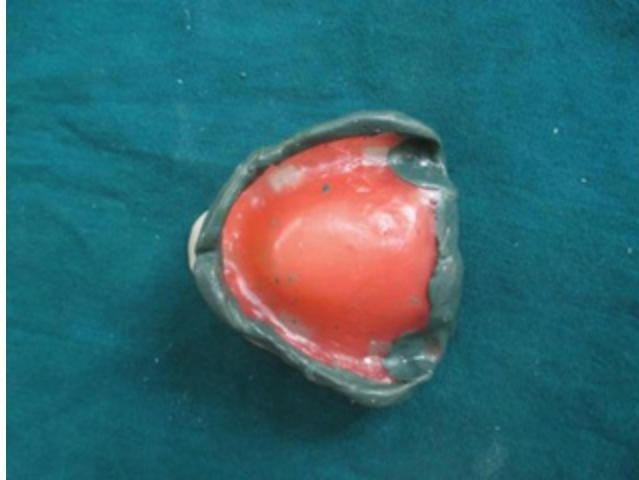

FIG 1.1.12.13 Complete border moulded custom trays



FIG 1.1.12.14 Zinc oxide eugenol impression paste for making final impressions

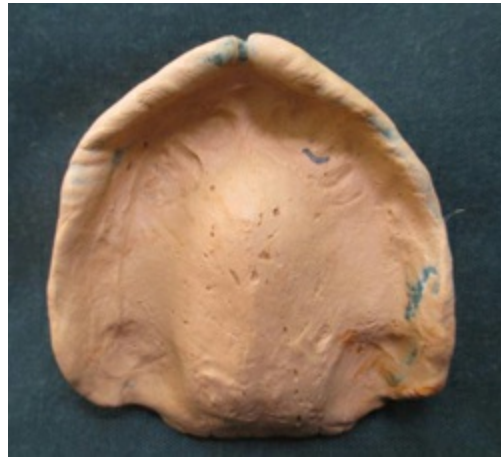

FIG 1.1.12.15 Final impression of maxillary and mandibular edentulous arches

Recording of maxillomandibular relations

Once the final impressions of the edentulous maxillary and mandibular arches are made, the final casts are poured. The record bases and occlusion rims are fabricated for the next clinical procedure of registering the maxillomandibular relations. The vertical and horizontal jaw relations are registered in the patient's mouth and transferred to an articulator which simulates the jaw movements same as in the patient's mouth. The artificial teeth are set in the occlusion rims which are mounted in the articulator ([Figs 1.1.12.16 to 1.1.12.18](#)).



FIG 1.1.12.16 Final casts with record bases and occlusion rim

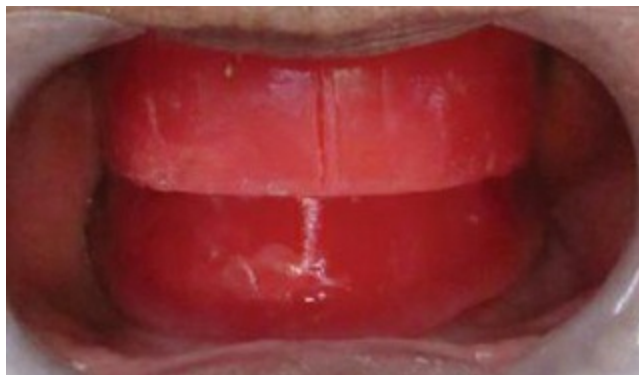

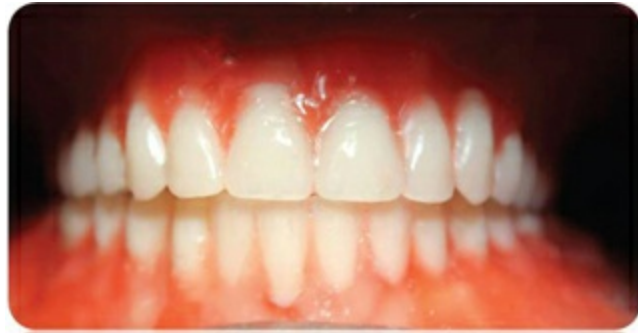FIG 1.1.12.17 Registration of maxillomandibular relations in the patient's mouth



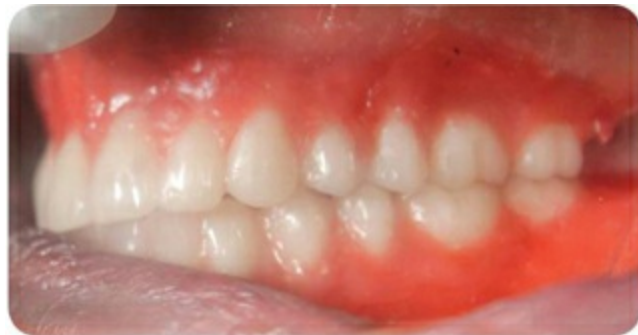
FIG 1.1.12.18 Final casts with occlusion rims are transferred to an articulator

Try in of waxed denture

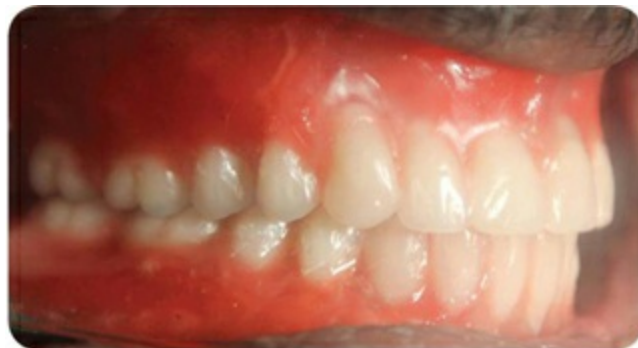After the registration of the maxillomandibular relations in the patient's mouth, the registration is transferred to an articulator. The artificial teeth set is selected based on the patient's anatomical guidelines. The artificial teeth are then set in the mounted maxillary and mandibular occlusion rims. The waxed denture is then tried in the patient's mouth. The registration of vertical, horizontal jaw relations is verified in the patient's mouth. Aesthetics and phonation is also verified during the try in of the waxed denture ([Figs 1.1.12.19a to 19c](#)).



(a)



(b)

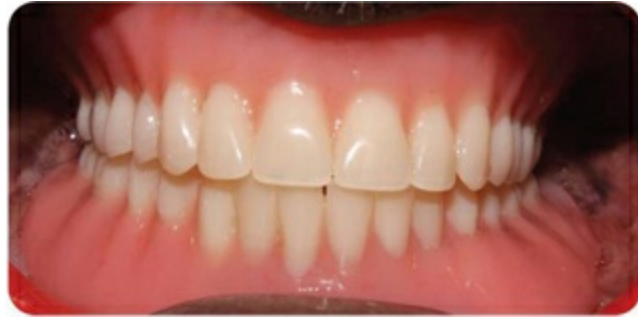

(c)

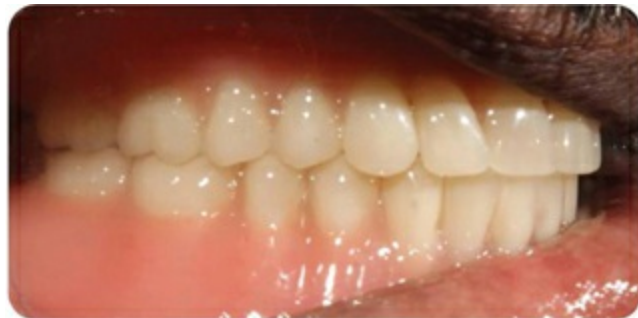FIGS 1.1.12.19A TO C Try in procedure of the waxed denture in the patient's mouth

Final denture insertion

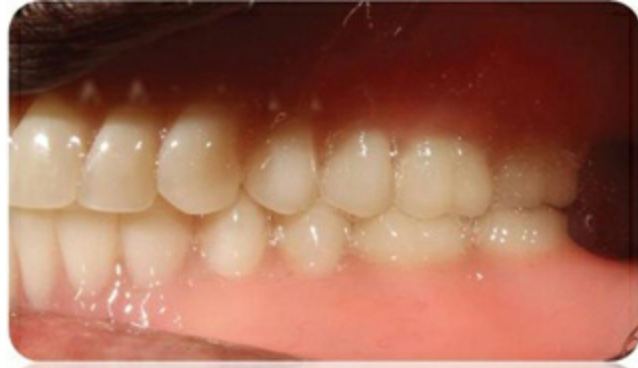After the try in procedure of the waxed denture, the waxed dentures are processed in heat-cure acrylic resin. The processed denture is finished and polished. The finished denture is inserted into the patient's mouth. The dentures are checked for border extension, occlusion and aesthetics (Figs 1.1.12.20a to 20c).



(a)



(b)



(c)

FIGS 1.1.12.20A TO C Final dentures in the patient's mouth

1.2. Removable partial denture

1.2.1. Classification of partially edentulous arch and Applegate's rules

Removable partial denture (Figs 1.2.1.1 and 1.2.1.2)

- Definition
- Components
- Kennedy's classification
- Applegate's rules

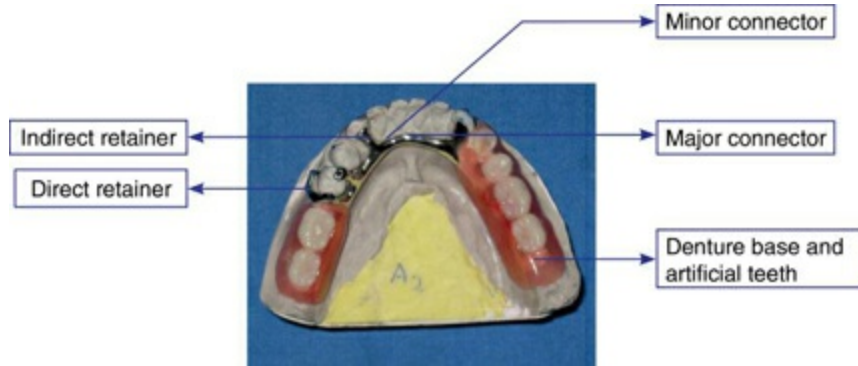


FIG 1.2.1.1 Mandibular cast partial denture

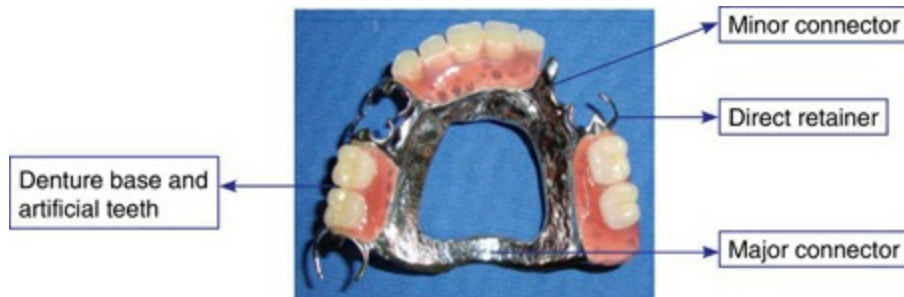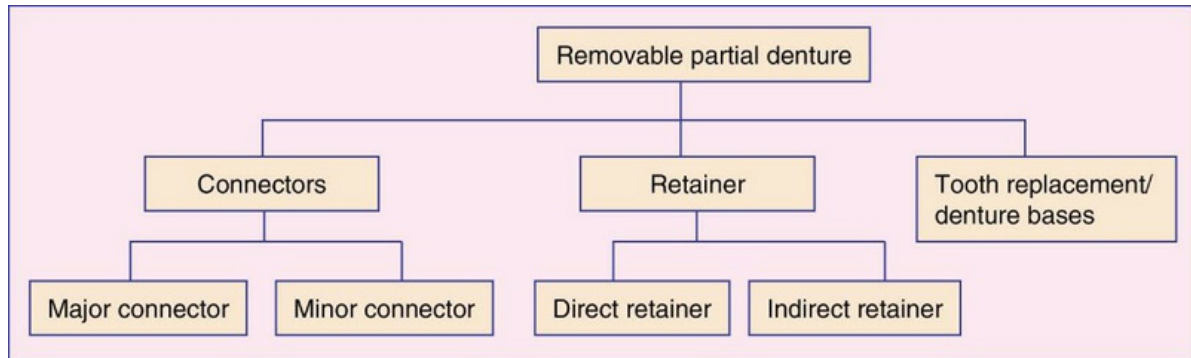


FIG 1.2.1.2 Maxillary cast partial denture

Definition

Any prosthesis that replaces some teeth in a partially dentate arch. It can be removed from the mouth and replaced at will, also called partial removable dental prosthesis.

Components



Kennedy's classification

Edward Kennedy in 1925 proposed the classification of partially edentulous arches. Kennedy's classification is the most widely accepted classification.

Requirements of a method of classification:

1. The classification should permit easy visualization of the type of partially edentulous arch.
2. It should differentiate between tooth supported and tissue supported partial denture.
3. The classification should help the clinician to design the partial denture.
4. It should be universally acceptable.

Class I

Bilateral edentulous areas located posterior to the remaining natural teeth (Fig 1.2.1.3).

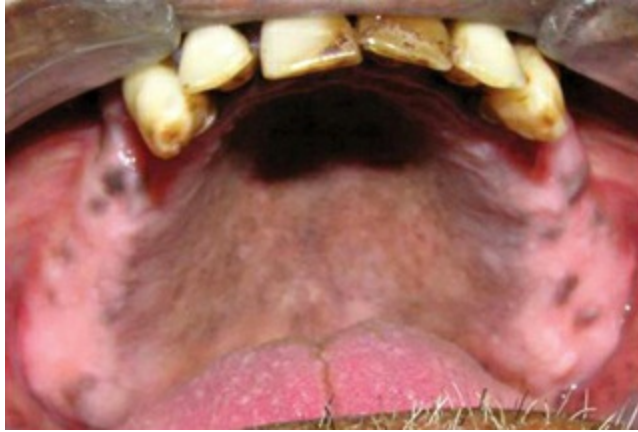

FIG 1.2.1.3 Kennedy's class I situation

Class II

Unilateral edentulous area located posterior to the remaining natural teeth ([Fig 1.2.1.4](#)).

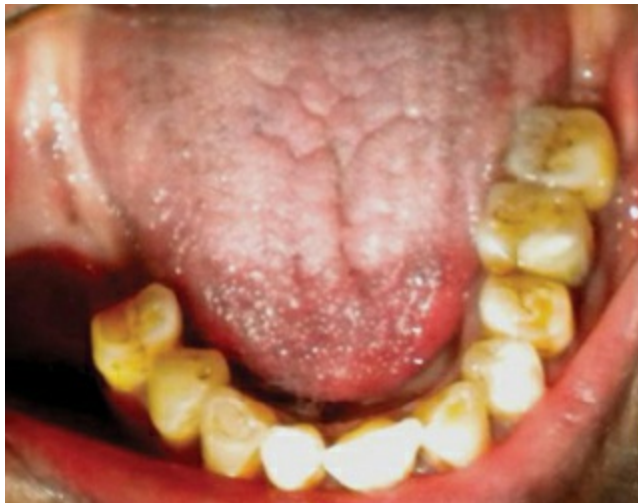

FIG 1.2.1.4 Kennedy's class II situation

Class III

Unilateral edentulous area with natural teeth both anterior and posterior to it ([Fig 1.2.1.5](#)).

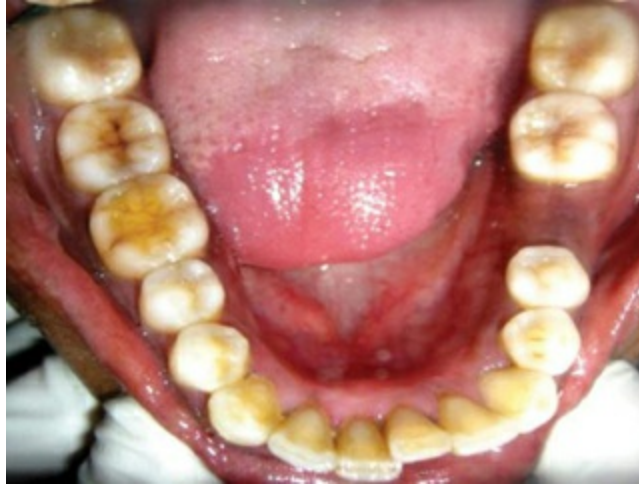

FIG 1.2.1.5 Kennedy's class III situation

Class IV

Single bilateral edentulous area located anterior to the remaining natural teeth and crossing the midline (Fig 1.2.1.6).

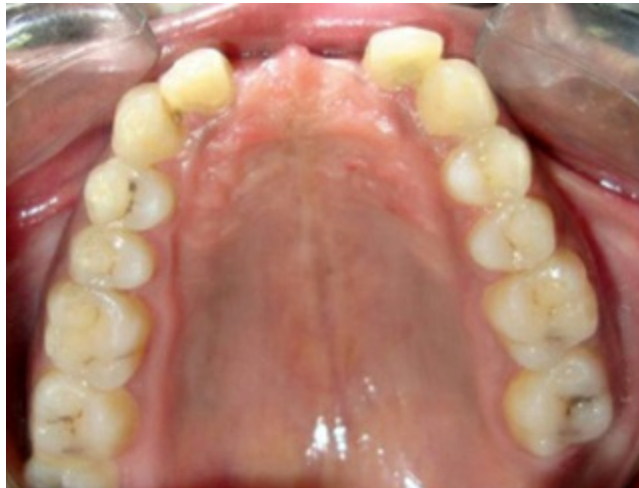

FIG 1.2.1.6 Kennedy's class IV situation

Advantages

- It permits easy visualization of the partially edentulous state.
- It gives a clear distinction between tooth supported partial denture

- and tissue supported partial denture.
- It gives a logical approach to the partial denture design.

Disadvantages

- The classification does not give a clear idea of the amount of available support for the design of the prosthesis.

Applegate's rules

Kennedy's classification will be difficult to apply in every clinical situation. Hence OC Applegate put forth eight rules for application of Kennedy's classification of partially edentulous arches. The rules are:

Rule 1:

Classification should follow rather than precede extraction that might alter the original classification.

Rule 2:

If the third molar is missing and not to be replaced, it is not considered in the classification.

Rule 3:

If a third molar is present and is to be used as an abutment, it is considered in the classification.

Rule 4:

If a second molar is missing and is not to be replaced, it is not considered in the classification.

Rule 5:

The most posterior edentulous area or areas always determine the classification.

Rule 6:

Edentulous areas other than those determining the classification are

referred to as modification spaces and are designated by their number.

Rule 7:

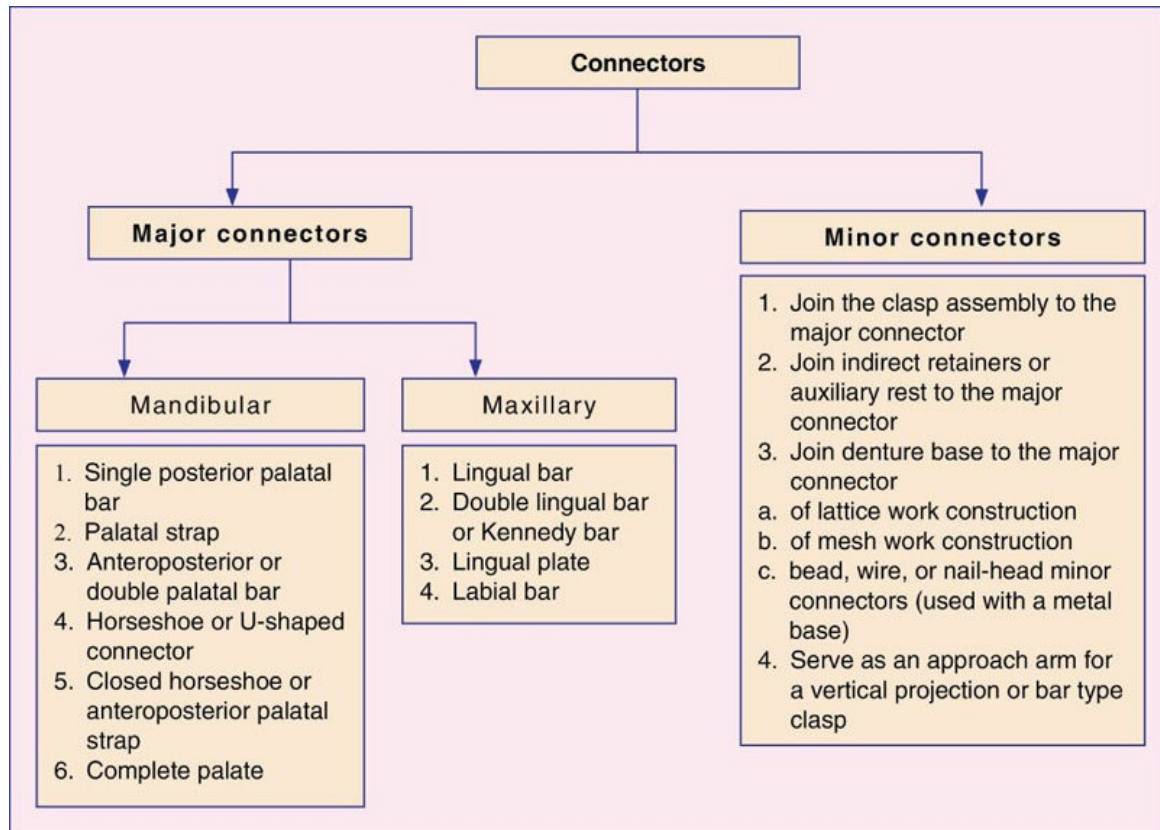
The extent of the modification is not considered, only the number of additional edentulous areas.

Rule 8:

There can be no modification areas in class IV arches. Any edentulous area lying posterior to the single bilateral area determines the classification.

1.2.2. Components of cast partial denture

- Classification
- Major connectors
- Minor connectors
- Definition
- Requirements
- Indication
- Types



Definition of major connector

It is that component that connects the parts of the prosthesis located on one side of the arch with those on the opposite side.

Requirements

1. Be rigid
2. Provide vertical support and protect the soft tissue
3. Provide a means of obtaining indirect retention where indicated
4. Provide an opportunity of positioning denture bases where needed
5. Maintain patient comfort

Classification of maxillary major connectors

There are six types of maxillary major connectors:

1. Single posterior palatal bar

2. Anterior and posterior palatal strap
3. Palatal plate connector
4. U-shaped palatal connector
5. Single palatal strap
6. Anterior posterior palatal bar

Classification of mandibular major connectors

There are four types of mandibular major connector:

1. Mandibular labial bar
2. Double lingual bar
3. Linguoplate
4. Labial bar

Single posterior palatal bar major connector (Fig 1.2.2.1)

Indications	Advantages	Disadvantages
<ul style="list-style-type: none"> • Class I partially edentulous arches with the residual ridges that have undergone little vertical resorption • V or U shape palates • Strong abutments • Noninterfering tori 	<ul style="list-style-type: none"> • Can be used as an interim partial denture till the more definite treatment is planned 	<ul style="list-style-type: none"> • Too thick • Limited to replace one or two teeth on each side of the arch • Should not be placed anteriorly to second premolar as it interferes with the tongue movements

Indications	Advantages	Disadvantages
<ul style="list-style-type: none"> • Class I partially edentulous arches with the residual ridges that have undergone little vertical resorption • V or U shape palates • Strong abutments • Noninterfering tori 	<ul style="list-style-type: none"> • Can be used as an interim partial denture till the more definite treatment is planned 	<ul style="list-style-type: none"> • Too thick • Limited to replace one or two teeth on each side of the arch • Should not be placed anteriorly to second premolar as it interferes with the tongue movements

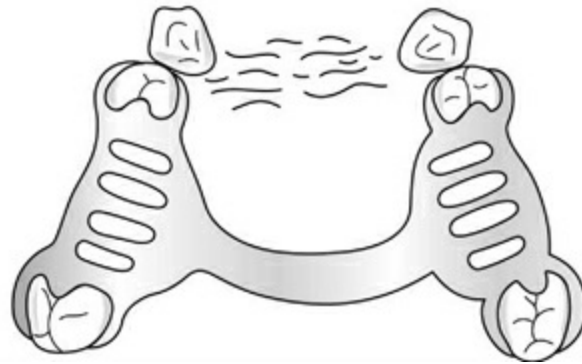
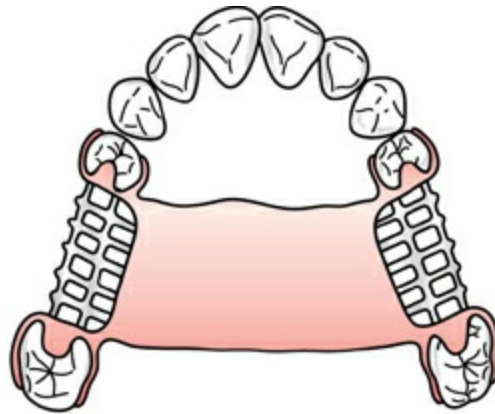

FIG 1.2.2.1 Single palatal bar major connector

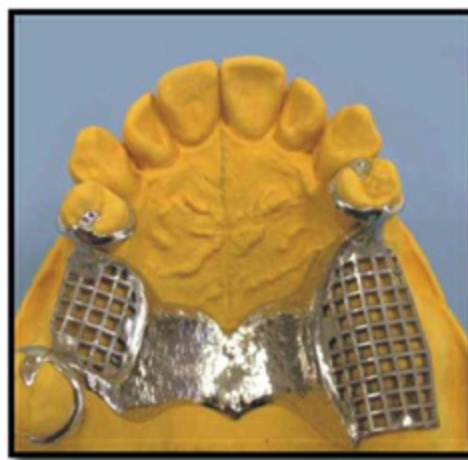
Single palatal strap major connector (Fig 1.2.2.2a, b)

Indications	Advantages	Disadvantages
<ul style="list-style-type: none"> • Bilateral edentulous space • Short span tooth supported prosthesis 	<ul style="list-style-type: none"> • Offers great degree of resistance • Offers little interference with the tongue movements • Helps to distribute the load evenly • Retention attained through the adhesion and cohesion • Helps in indirect retention 	<ul style="list-style-type: none"> • Excessive palatal coverage • Excessive tissue reaction

Indications	Advantages	Disadvantages
<ul style="list-style-type: none"> • Bilateral edentulous space • Short span tooth supported prosthesis 	<ul style="list-style-type: none"> • Offers great degree of resistance • Offers little interference with the tongue movements • Helps to distribute the load evenly • Retention attained through the adhesion and cohesion • Helps in indirect retention 	<ul style="list-style-type: none"> • Excessive palatal coverage • Excessive tissue reaction



(a)



(b)

FIG 1.2.2.A, B Single palatal strap major connector

Anteroposterior or double palatal bar major connector (Fig 1.2.2.3)

Indications	Advantages	Disadvantages
<ul style="list-style-type: none"> • Class I partially edentulous arches with the residual ridges that have undergone little vertical resorption • V or U shape palates • Strong abutments • Noninterfering tori 	<ul style="list-style-type: none"> • It offers excellent rigidity • It offers less palatal coverage 	<ul style="list-style-type: none"> • It offers little support • The extra bulk of metal causes tongue interference • Not indicated in high vault palate

Indications	Advantages	Disadvantages
<ul style="list-style-type: none"> • Class I partially edentulous arches with the residual ridges that have undergone little vertical resorption • V or U shape palates • Strong abutments • Noninterfering tori 	<ul style="list-style-type: none"> • It offers excellent rigidity • It offers less palatal coverage 	<ul style="list-style-type: none"> • It offers little support • The extra bulk of metal causes tongue interference • Not indicated in high vault palate

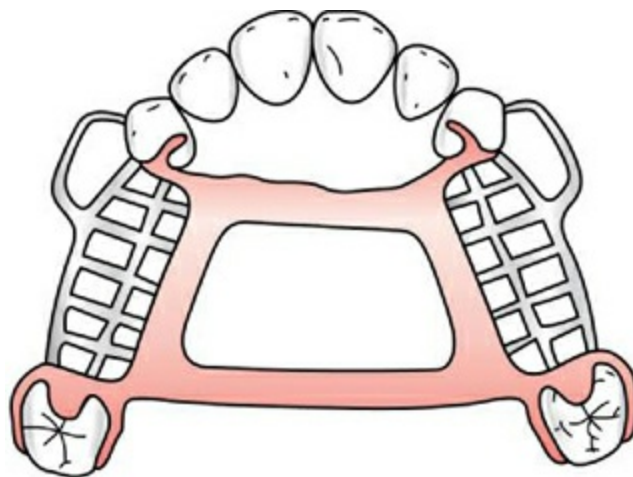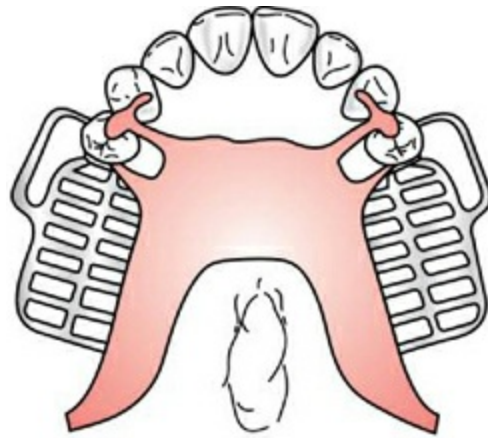


FIG 1.2.2.3 Anteroposterior double palatal bar

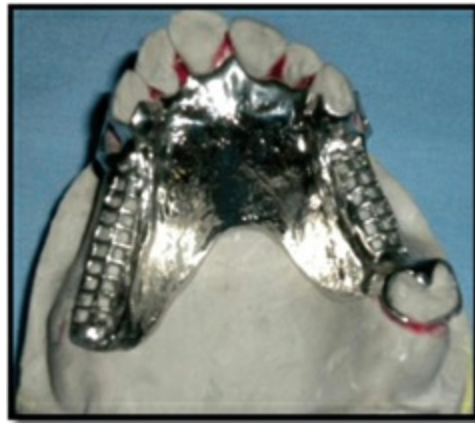U-shaped palatal major connector (Fig 1.2.2.4a, b)

Indications	Advantages	Disadvantages
<ul style="list-style-type: none"> • In case of inoperable tori that extends to the posterior limit of the hard palate • Used in Kennedy's class I and class IV situation 	<ul style="list-style-type: none"> • Used when several anterior teeth are being replaced • Derive some vertical support and indirect retention from the palate 	<ul style="list-style-type: none"> • Great bulk of metal in the tongue area • Problem in phonetics

Indications	Advantages	Disadvantages
<ul style="list-style-type: none"> • In case of inoperable tori that extends to the posterior limit of the hard palate • Used in Kennedy's class I and class IV situation 	<ul style="list-style-type: none"> • Used when several anterior teeth are being replaced • Derive some vertical support and indirect retention from the palate 	<ul style="list-style-type: none"> • Great bulk of metal in the tongue area • Problem in phonetics



(a)



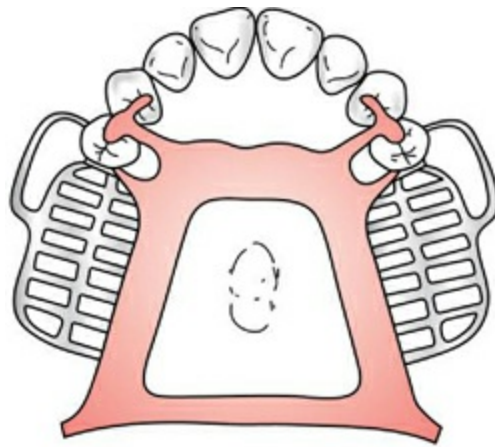
(b)

FIG 1.2.2.4A, B U-shaped palatal major connector

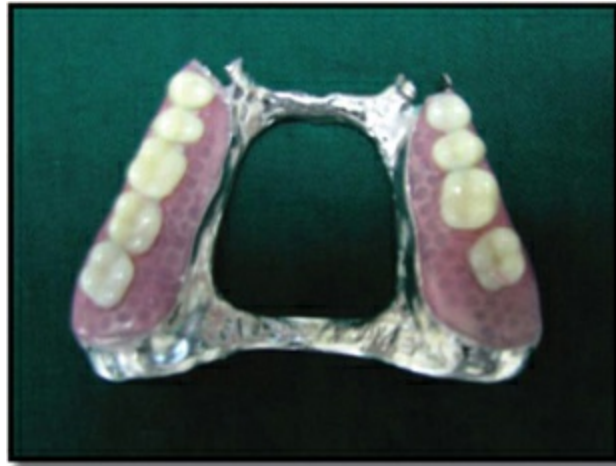Anteroposterior strap type major connector (Fig 1.2.2.5a, b)

Indications	Advantages	Disadvantages
<ul style="list-style-type: none"> • Class I and II arches in which excellent abutment and residual ridges resorption support exist • Long edentulous span in class II modification 1 arch • Class IV arches in which anterior teeth must be replaced with RPD • Inoperable palatal tori that do not extend posteriorly till the junction of hard and soft palates 	<ul style="list-style-type: none"> • The corrugated contour provides more support • The circle effect by the anterior and posterior strap contribute to rigidity 	<ul style="list-style-type: none"> • Contraindicated in case of teeth with reduced periodontal support • High narrow vault cases • Interfere with the phonetics

Indications	Advantages	Disadvantages
<ul style="list-style-type: none"> • Class I and II arches in which excellent abutment and residual ridges resorption support exist • Long edentulous span in class II modification 1 arch • Class IV arches in which anterior teeth must be replaced with RPD • Inoperable palatal tori that do not extent posteriorly till the junction of hard and soft palates 	<ul style="list-style-type: none"> • The corrugated contour provides more support • The circle effect by the anterior and posterior strap contribute to rigidity 	<ul style="list-style-type: none"> • Contraindicated in case of teeth with reduced periodontal support • High narrow vault cases • Interfere with the phonetics



(a)



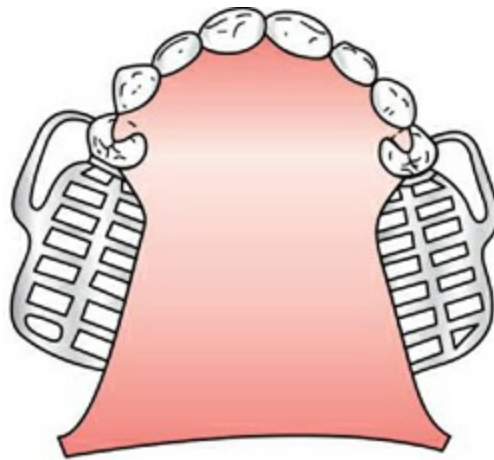
(b)

FIG 1.2.2.5A, B Anteroposterior palatal strap major connector

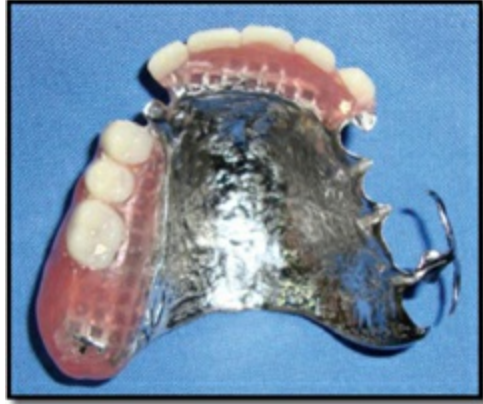Complete palatal coverage major connector (Fig 1.2.2.6a, b)

Indications	Advantages	Disadvantages
<ul style="list-style-type: none"> • Only if some anterior teeth remain • Class II arch with large posterior modification space • Class I arch with one to four premolars and some or all anterior teeth remaining with the poor abutment support • In patients with palatal cleft 	<ul style="list-style-type: none"> • In individual with the well developed muscles of mastication and full complement of mandibular teeth • Good 	<ul style="list-style-type: none"> • Adverse tissue reaction • Problem in phonetics

Indications	Advantages	Disadvantages
<ul style="list-style-type: none"> • Only if some anterior teeth remain • Class II arch with large posterior modification space • Class I arch with one to four premolars and some or all anterior teeth remaining with the poor abutment support • In patients with palatal cleft 	<ul style="list-style-type: none"> • In individual with the well developed muscles of mastication and full complement of mandibular teeth • Good 	<ul style="list-style-type: none"> • Adverse tissue reaction • Problem in phonetics



(a)



(b)

FIG 1.2.2.6A, B Complete palatal major connector

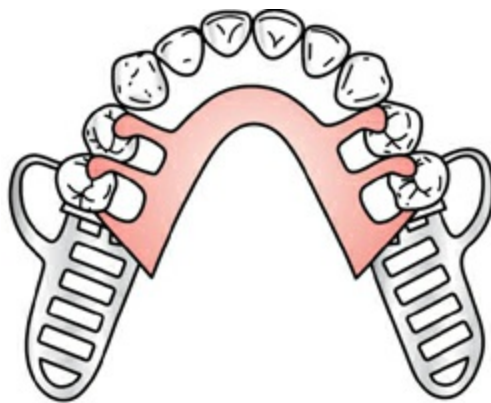Review of indications for maxillary major connectors

1. If the periodontal support of remaining teeth is weak, more of the palate should be covered thus a wide palatal strap or a complete palate is indicated.
2. If the remaining teeth have adequate periodontal support and little additional support is needed, a palatal strap and double palatal bar can be used.
3. For long-span distal extension bases where rigidity is critical, a closed horseshoe or complete palate is indicated.
4. When anterior teeth must be replaced, a horseshoe, closed horseshoe or a complete palate may be used. The final selection be based on modifying factors such as number and location of posterior teeth missing, support of remaining teeth and type opposing occlusion.
5. If torus is present and is not removed, a horseshoe, a closed horseshoe, or an anterior posterior palatal bar may be used.
6. A single palatal bar is rarely indicated.

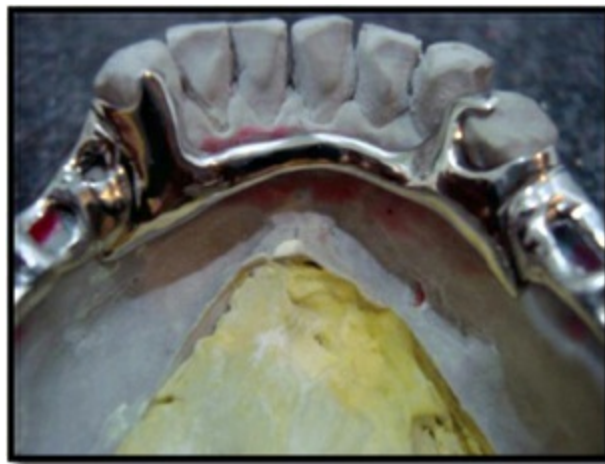Mandibular lingual bar major connector (Fig 1.2.2.7a, b)

Indications	Advantages	Disadvantages
<ul style="list-style-type: none"> • When 8 mm space exists between the slightly elevated alveolar lingual sulcus and the lingual gingival tissue • In Kennedy's class I and class II situation 	<ul style="list-style-type: none"> • Minimal contact to tissue • Simple to construct 	<ul style="list-style-type: none"> • Proper care should be taken in the laboratory not to make it thin

Indications	Advantages	Disadvantages
<ul style="list-style-type: none"> • When 8 mm space exists between the slightly elevated alveolar lingual sulcus and the lingual gingival tissue • In Kennedy's class I and class II situation 	<ul style="list-style-type: none"> • Minimal contact to tissue • Simple to construct 	<ul style="list-style-type: none"> • Proper care should be taken in the laboratory not to make it thin



(a)



(b)

FIG 1.2.2.7A, B Mandibular lingual bar major connector

Double lingual bar/kennedy bar (Fig 1.2.2.8)

Indications	Advantages	Disadvantages
<ul style="list-style-type: none"> • When indirect retention is needed • When periodontal disease resulted in interproximal embrasure • In class I and class II situation 	<ul style="list-style-type: none"> • Contribute horizontal stabilization • Since gingival and interproximal space not covered free flowing of saliva is permitted • Marginal gingiva receives natural stimulation 	<ul style="list-style-type: none"> • More tongue interference • Food entrapment

Indications	Advantages	Disadvantages
<ul style="list-style-type: none"> • When indirect retention is needed • When periodontal disease resulted in interproximal embrasure • In class I and class II situation 	<ul style="list-style-type: none"> • Contribute horizontal stabilization • Since gingival and interproximal space not covered free flowing of saliva is permitted • Marginal gingiva receives natural stimulation 	<ul style="list-style-type: none"> • More tongue interference • Food entrapment

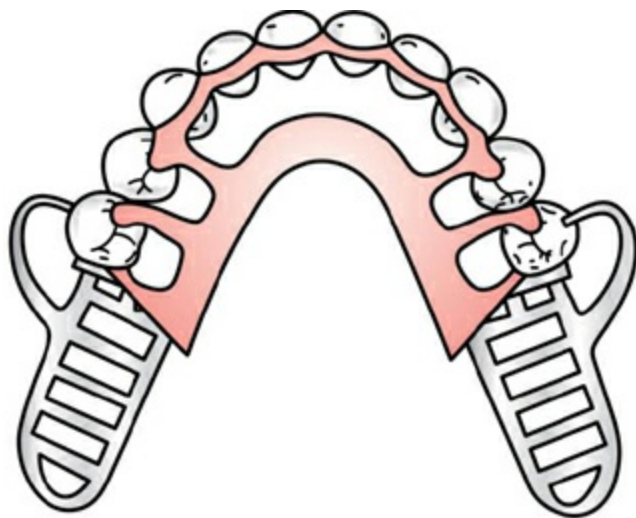
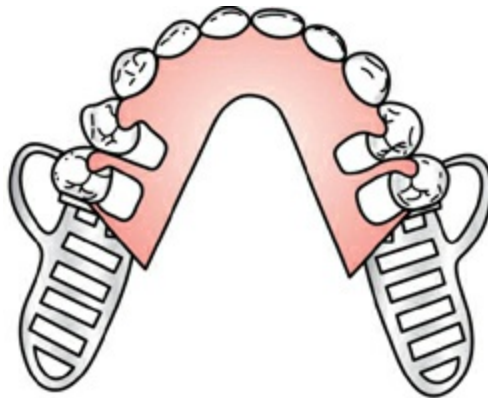

FIG 1.2.2.8 Double lingual bar

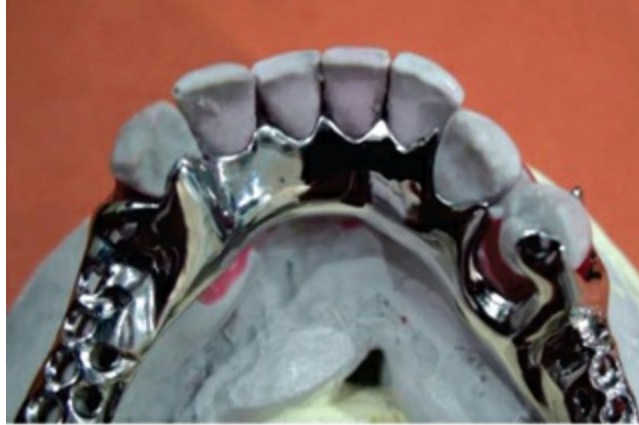Mandibular lingual plate major connector (Fig 1.2.2.9a, b)

Indications	Advantages	Disadvantages
<ul style="list-style-type: none"> • When class I arch has a slight vertical resorption • For periodontally weakened teeth • When future addition of teeth is needed in existing RPD (when less than 8 mm space exists between the active lingual sulcus floor and the lingual gingival floor) 	<ul style="list-style-type: none"> • Provides indirect retention • Provides more support and stabilization • Provides more tongue comfort and ease in phonetics 	<ul style="list-style-type: none"> • Decalcification of enamel surface • Irritation of soft tissue

Indications	Advantages	Disadvantages
<ul style="list-style-type: none"> • When class I arch has a slight vertical resorption • For periodontally weakened teeth • When future addition of teeth is needed in existing RPD (when less than 8 mm space exists between the active lingual sulcus floor and the lingual gingival floor) 	<ul style="list-style-type: none"> • Provides indirect retention • Provides more support and stabilization • Provides more tongue comfort and ease in phonetics 	<ul style="list-style-type: none"> • Decalcification of enamel surface • Irritation of soft tissue



(a)



(b)

FIG 1.2.2.9A, B Mandibular lingual plate major connector

Mandibular labial bar (Fig 1.2.2.10)

Indications	Advantage	Disadvantage
<ul style="list-style-type: none"> • Lingual inclined remaining teeth • When severe lingual tori cannot be removed • When there is severe abrupt lingual tissue undercut • In Kennedy's class IV situation 	<ul style="list-style-type: none"> • When the lower anterior and premolars are tilted lingually that a conventional lingual major connectors cannot be used 	<ul style="list-style-type: none"> • The bulk of the connector distorts the lower lip

Indications	Advantage	Disadvantage
<ul style="list-style-type: none"> • Lingual inclined remaining teeth • When severe lingual tori cannot be removed • When there is severe abrupt lingual tissue undercut • In Kennedy's class IV situation 	<ul style="list-style-type: none"> • When the lower anterior and premolars are tilted lingually that a conventional lingual major connectors cannot be used 	<ul style="list-style-type: none"> • The bulk of the connector distorts the lower lip

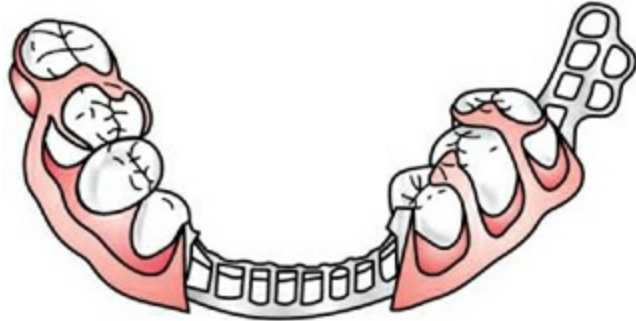

FIG 1.2.2.10 Mandibular labial bar

Minor connector

- Definition
- Functions
- Types

Definition

The connecting link between the major connector or base of a removable partial denture and the other units of the prosthesis, such as the class assembly, indirect retainers, occlusal rests or cingulum rests ([Fig 1.2.2.11](#)).

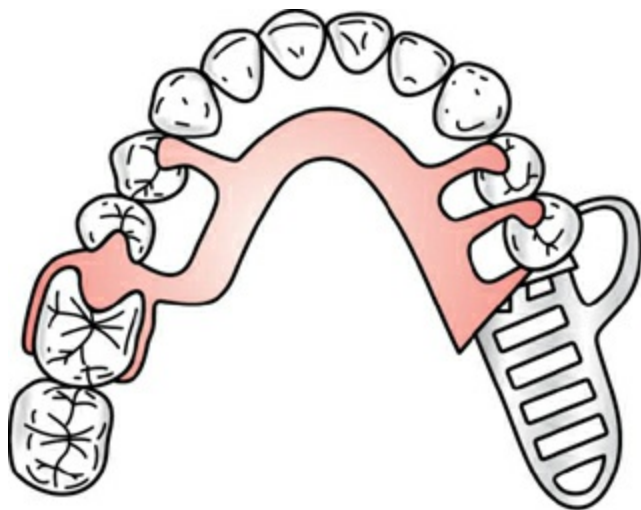


FIG 1.2.2.11 Minor connectors

Functions

- The primary function is to join other units of the prosthesis, such as clasps, rests, indirect retainers and denture bases to the major connector.
- It distributes the stresses that occur against certain components of the partial denture to other components.

Types

There are four types. Those that:

- Join the clasp assembly to the major connector
- Join indirect retainers or auxiliary rests to the major connector
- Join the denture base to the major connector
 - Lattice work construction
 - Mesh construction
 - Beads, wire or nail-head minor connectors
- Serve as an approach arm for a vertical projection or bar-type clasp

Types of minor connector joining the denture base

I. Lattice work construction (Fig 1.2.2.12)

Lattice work construction consists of two struts of metal 12–16 gauge thick extending longitudinally along the edentulous mandibular arch, positioned buccal and lingual to the ridge crest (not on the ridge to avoid interference with artificial teeth placement). It is commonly used in Kennedy's classification class I and class II.

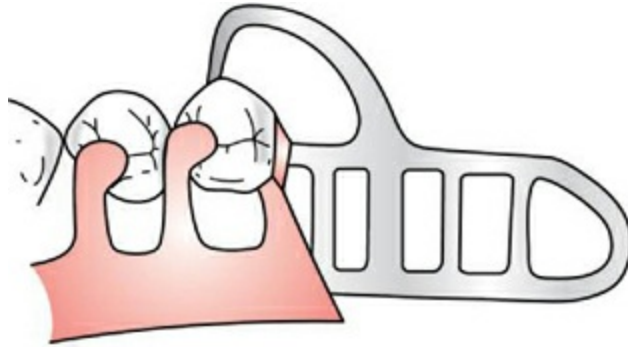

FIG 1.2.2.12 Lattice type minor connector

Advantages

- It is used when multiple teeth are to be replaced.
- It provides the strongest attachment.
- Easy to reline.
- It gives more space for placement of artificial teeth.

II. Mesh construction (Fig 1.2.2.13)

- It is a thin sheet of metal with multiple small holes that extend over the crest of the residual ridge.
- Used when multiple teeth are used.
- Used only when abundant inter-ridge space is available (as it is bulkier).
- It is commonly used in Kennedy's class I and class II.

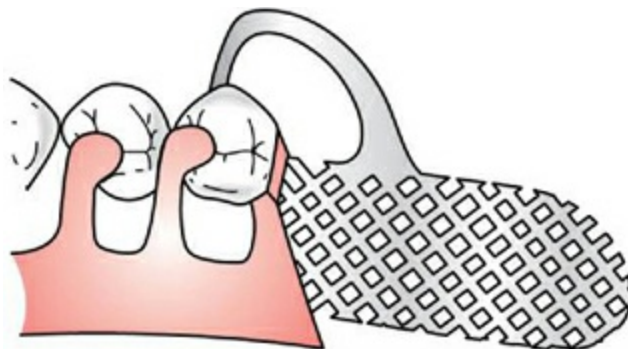

FIG 1.2.2.13 Meshwork type of minor connector

Disadvantages

- It does not provide strong attachment (smaller the openings weaker the attachment).
- It needs more pressure while packing the resin.

III. Bead, wire, nail head retention minor connectors (Fig 1.2.2.14)

It is used with a metal denture base that fits directly to the ridge without relief.

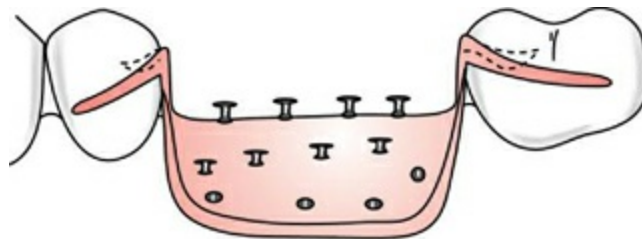


FIG 1.2.2.14 Nail head type of minor connector

The denture base is attached only on the outer or superior surface and the retention is gained by beads (acrylic beads were waxed, invested, burned casting done) wire projecting from metal base or nail heads. It is commonly used in Kennedy's class III partially edentulous arches.

Advantage

- Hygienic—due to better soft tissue response.

Disadvantages

- Difficult to reline.
- Weakest attachment between metal base and the acrylic resin.

1.2.3. Rests

- Definition

- Function
- Classification
- Forms of rest

Definition

The components of a removable partial denture that serve primarily to transfer forces occurring against the prosthesis down the long axis of the abutment teeth are called rests and a rest seat is the prepared surface of the tooth or fixed restoration into which a rest fits (Fig 1.2.3.1).

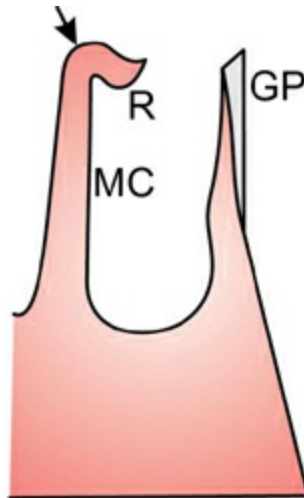


FIG 1.2.3.1 Rest (R—rest, MC—minor connector, GP—proximal guiding plate)

When rest is used, stress can be absorbed by the fibres of the periodontal ligament without damaging the ligament, or the supporting bone.

Functions of rest

1. It helps in transferring occlusal load to the abutment teeth.
2. It provides vertical support to the partial denture and resists movement towards the tissue.

3. It prevents impingement of soft tissue.
4. It also maintains the retentive clasp in its proper position.

Classification of rest (Fig 1.2.3.2)

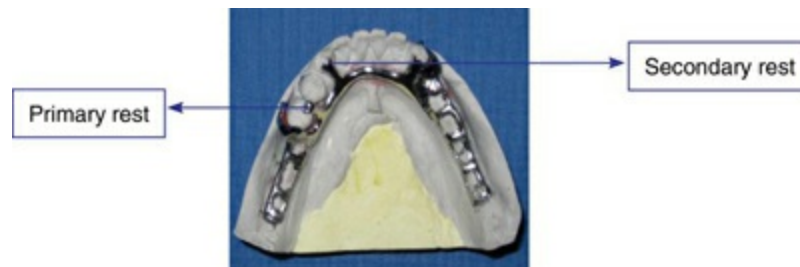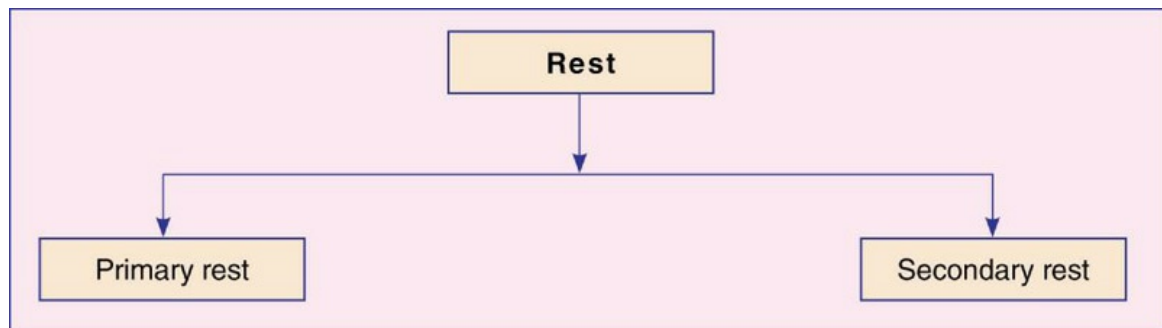


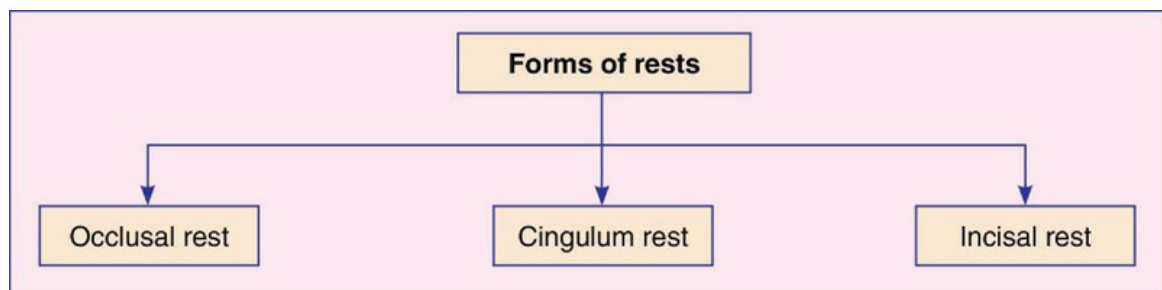
FIG 1.2.3.2 Classification of rest

Primary rest

- It is a part of a direct retainer unit.
- It prevents vertical movement of the prosthesis towards the tissue and also helps transmit lateral or horizontal forces applied to the partial denture during function to supporting teeth.
- For a distal extension partial denture, the rest seat should be shallow or saucer-shaped so that the rest can move slightly, like a ball and socket joint.

Secondary rest

- It is used for indirect retention or extra support in Kennedy's classification of class I and class II partially edentulous arches.
- It is also called as auxiliary rest
- These rests are placed anterior or posterior to the axis of rotation to prevent the unsupported distal extension denture base from lifting away from the edentulous ridge.



1. Occlusal rest (Fig 1.2.3.3)

- The outline form should be triangular.
- The base of the triangle resting on the marginal ridge and rounded apex directed towards the centre of the teeth.
- The floor of the occlusal rests must be towards the centre of the tooth.
- The floor of the rest seat must be less than 90 degrees so that the transmitted occlusal forces can be directed along the vertical axis of the tooth.
- It must be 0.5 mm thick at its thinnest point and should be between 1.0 and 1.5 mm thick when it crosses the marginal ridge.
- Occlusal rest will fail when there is insufficient reduction of the marginal ridge.

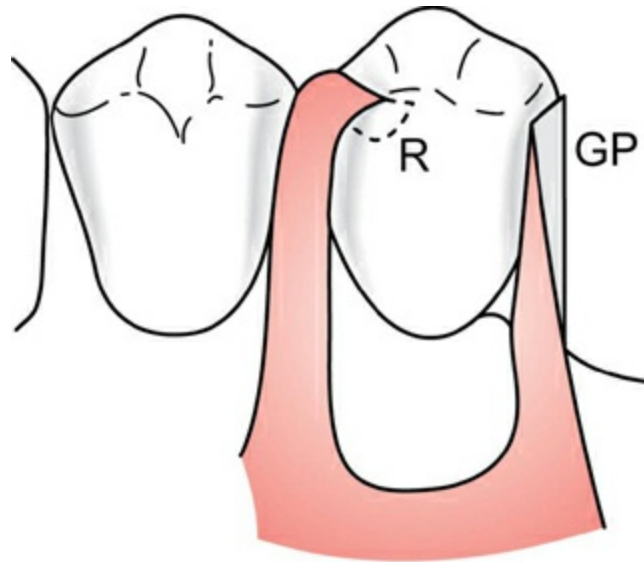


FIG 1.2.3.3 Occlusal rest

2. Lingual or cingulum rest (Fig 1.2.3.4)

- It is used primarily on maxillary canines.
- Lingual rests on incisor teeth are used when canines are missing. In this instance, multiple incisor teeth must receive lingual rest to distribute the stresses over a number of teeth because a single incisor tooth seldom offers adequate support.
- Lingual rests are preferred over incisal rests because:
 1. Lingual rest is close to the centre of rotation of the supporting tooth, so it does not tend to tip the tooth.
 2. The lingual rest is confined to the lingual surface of the anterior tooth.
 3. It is more acceptable aesthetically.
 4. It is less subjected to breakage and distortion.

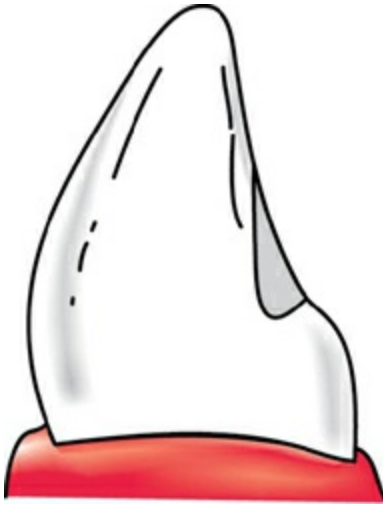


FIG 1.2.3.4 Lingual rest

3. Incisal rest (Fig 1.2.3.5)

- It is most frequently used on mandibular canines.
- It is positioned near the incisal angles of the abutment teeth.
- It is designed for the mesio-incisal or disto-incisal angle, depending on the type of clasp planned for the teeth.
- If the tooth is not to be clasped, the rest is placed on the disto-incisal surface for aesthetic reasons.

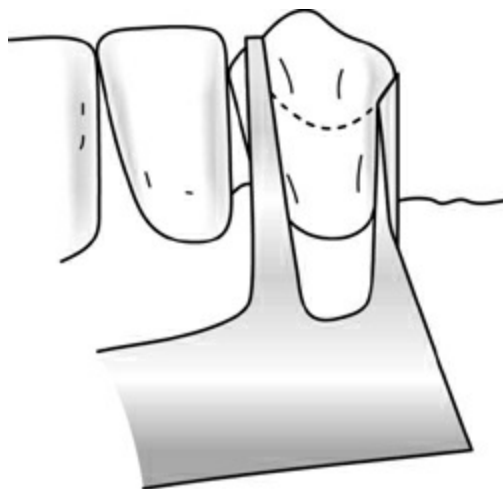


FIG 1.2.3.5 Incisal rest

1.2.4. Direct retainers

- Definition
- Types
- Requirements
- Parts

Definition

Direct retainer is a component of removable partial prosthesis, which is used to retain and prevent dislodgement, consisting of a clasp assembly or precision attachment.

Parts of a clasp (Figs 1.2.4.1, 1.2.4.2)

1. Rest
2. Body
3. Shoulder
4. Reciprocal arm
5. Retentive arm
6. Minor connector
7. Approach arm

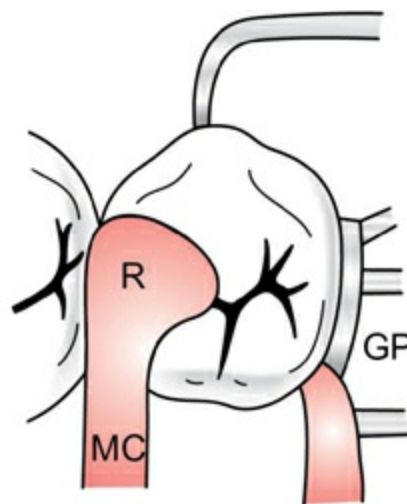


FIG 1.2.4.1A Bar clasp (R—rest, MC—minor connector, RA—approach arm, GP—guiding proximal plate)

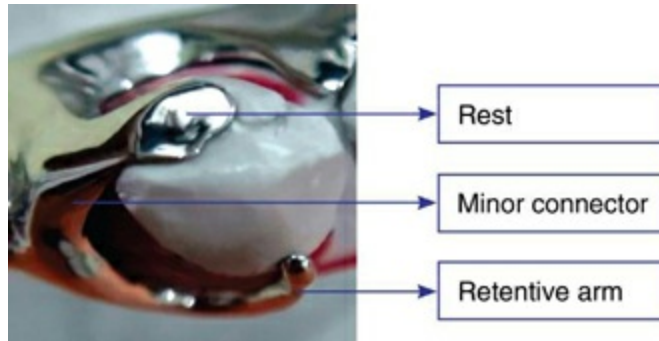


FIG 1.2.4.1B Bar clasp

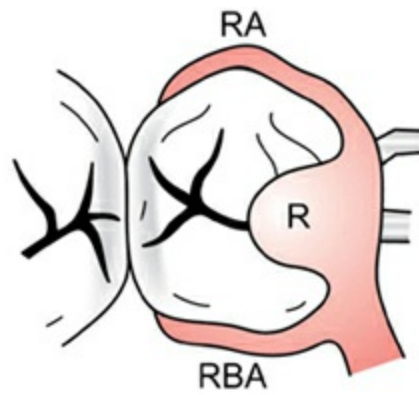


FIG 1.2.4.2A Circumferential clasp (RA—retentive arm, R—rest, RBA—reciprocal arm)

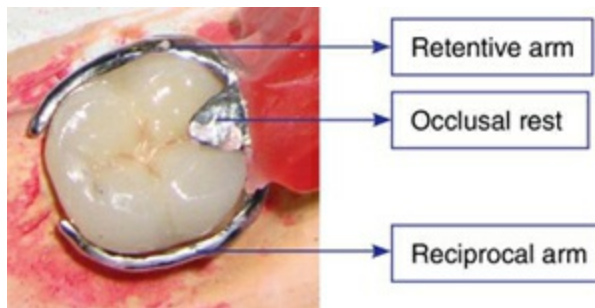


FIG 1.2.4.2B Circumferential clasp

Requirements of a clasp design

1. Retention

- a. The resistance in the movement of a denture away from its tissue foundation especially in a vertical direction.
- b. A quality of a denture that holds it to the tissue foundation and/or abutment teeth. Retention is inversely proportional to flexibility of the clasp arm. It is provided by the retentive clasp terminal by engaging the specified undercut.

2. Support

- a. The foundation area on which a dental prosthesis rests. With respect to dental prostheses, the resistance to displacement away from the basal tissue or underlying structures.
- b. Support is provided by the rest.

3. Stability

- a. The resistance of a denture to movement on its tissue foundation, especially to lateral (horizontal) forces as opposed to vertical displacement.
- b. A quality of a denture that permits it to maintain a state of equilibrium in relation to its tissue foundation and/or abutment teeth. Rigid components of the clasp assembly offers the stability.

4. Reciprocation

- a. The mechanism by which lateral forces generated by a retentive clasp passing over a height of contour are counterbalanced by a reciprocal clasp passing along a reciprocal guiding plane.

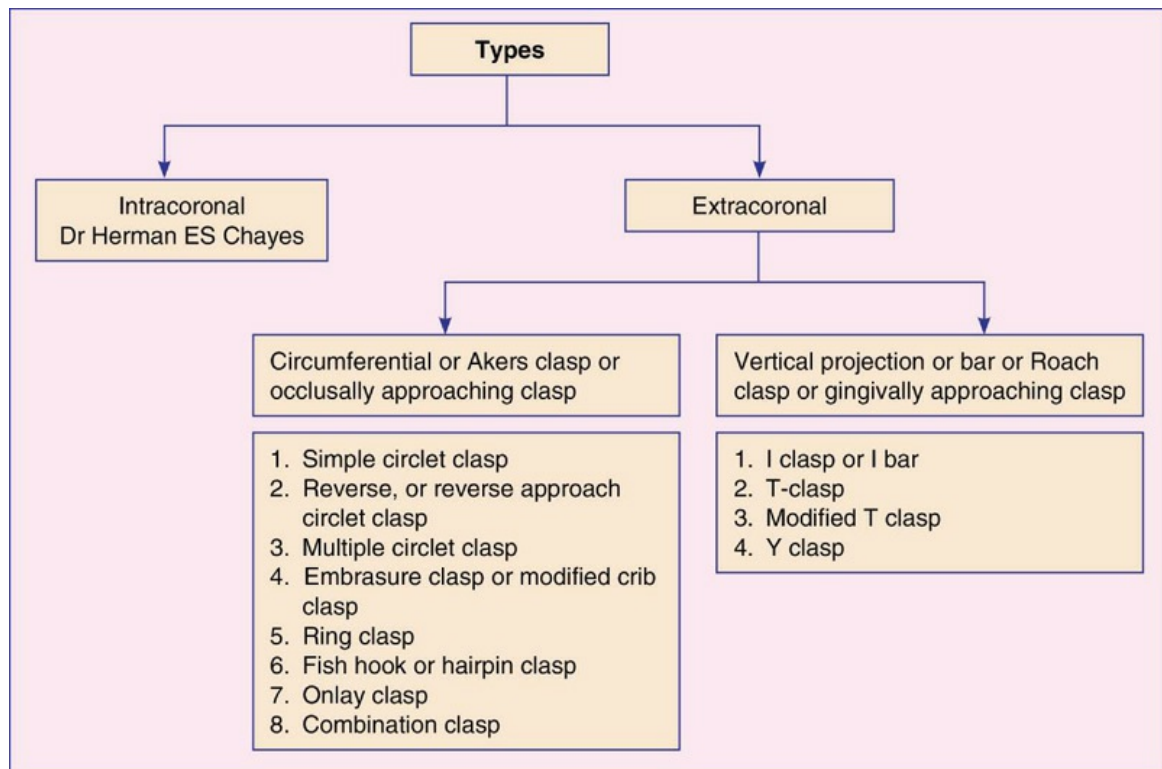
5. Encirclement

- a. Each clasp must be designed to encircle more than 180 degrees of

the abutment tooth.

6. Passivity

- a. The quality or condition of inactivity or rest assumed by the teeth, tissues, and denture when a removable dental prosthesis is in place but not under masticatory pressure.



Circumferential or akers clasp or occlusally approaching clasp

1. Simple circlet clasp (Fig 1.2.4.3)
2. Reverse circlet clasp (Fig 1.2.4.4)
3. Embrasure clasp or modified crib clasp (Fig 1.2.4.5)
4. Ring clasp (Fig 1.2.4.6)
5. Fish hook or hairpin clasp (Fig 1.2.4.7)
6. Onlay clasp (Fig 1.2.4.8)

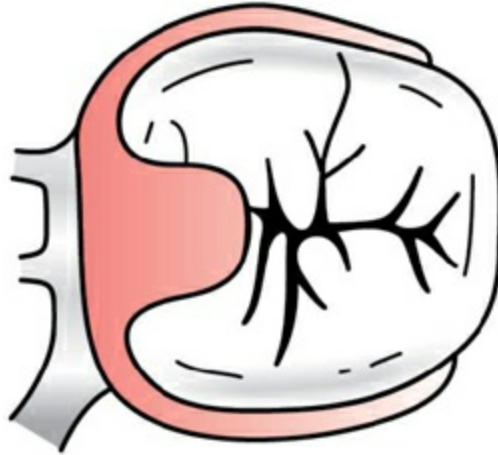


FIG 1.2.4.3 Simple circle clasp

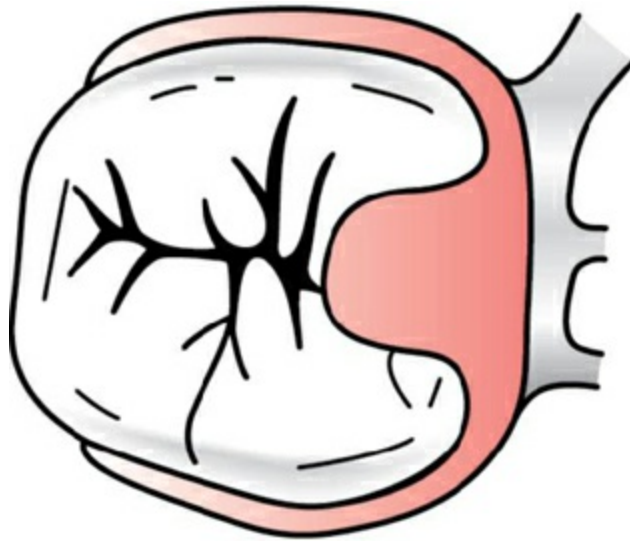


FIG 1.2.4.4 Reverse approach clasp

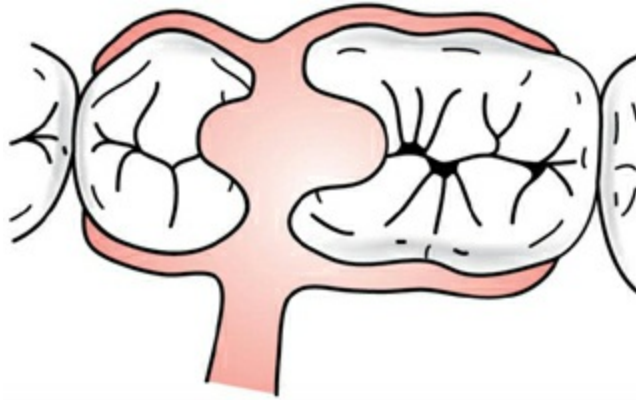


FIG 1.2.4.5 Embrasure clasp

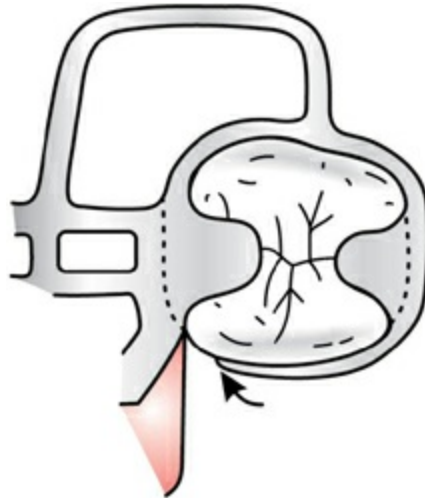


FIG 1.2.4.6 Ring clasp

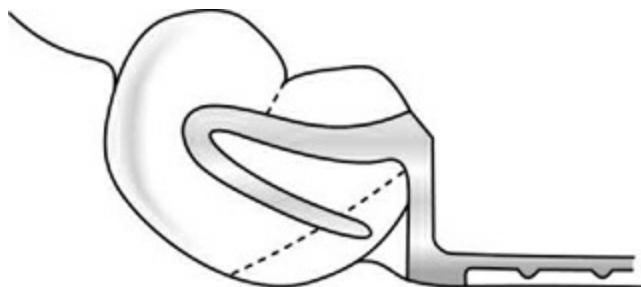


FIG 1.2.4.7 Fish hook clasp

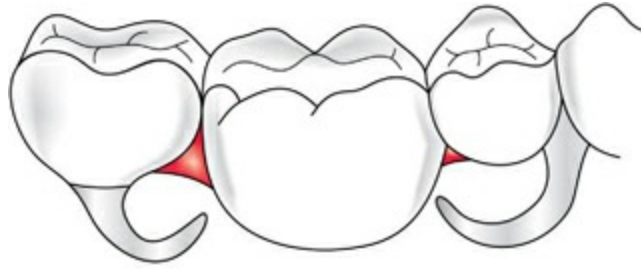


FIG 1.2.4.8 Onlay clasp

Circumferential clasp

Types of Clasp	Indications	Advantages	Disadvantages
Simple circlet clasp	Tooth supported partial denture	<ul style="list-style-type: none"> • Easy to construct • Simple to repair • Most versatile clasp 	<ul style="list-style-type: none"> • More tooth surface area is covered, changes the morphology of the crown • Not accepted in the anterior tooth due to aesthetics • Clasp cannot be adjusted in the occlusogingival direction
Multiple circlet clasp	Sharing of retention among several abutment teeth	Acts as a form of splinting among weakened teeth	<ul style="list-style-type: none"> • More tooth surface area is covered, changes the morphology of the crown • Not accepted in the anterior tooth due to aesthetics • Clasp cannot be adjusted in the occlusogingival direction • Need for two embrasures rather than a single common embrasure
Ring clasp	Tipped molars	Occlusal rest of the clasp prevents further movement of the teeth	<ul style="list-style-type: none"> • Large amount of tooth surface is covered by metal • Aesthetically objectionable
Embrasure clasp	Class II and class III situation, used on side of the arch where there is no edentulous space	Single embrasure for two clasps	High rate of fracture
Fish hook or hair pin clasp	Lingual undercuts		<ol style="list-style-type: none"> 1. Exposure of too much of metal, aesthetically objectionable 2. Cannot be used on smaller crowns or teeth
Onlay clasp	Occlusal surface of the primary abutment teeth below the occlusal plane	Increases the height of the crown	<ol style="list-style-type: none"> 1. Teeth should be highly resistant to caries 2. Chrome alloy onlays causes higher wear in opposing natural teeth
Combination clasp	On abutment teeth adjacent to the edentulous space	<ol style="list-style-type: none"> 1. Wrought wire acts stress equalizer and helps to dissipate torquing forces, due to the greater flexibility it can be used in greater or deeper undercuts 2. Minimal surface contact 	Tedious lab procedure, breakage of clasp, distortion can happen due to the patient itself easily

Vertical projection or bar or roach clasp or gingivally approaching clasp

1. I-clasp or I bar (Fig 1.2.4.9)
2. T-clasp (Fig 1.2.4.10)

- 3. Y-clasp (Fig 1.2.4.11)
- 4. Modified T-clasp (Fig 1.2.4.12)

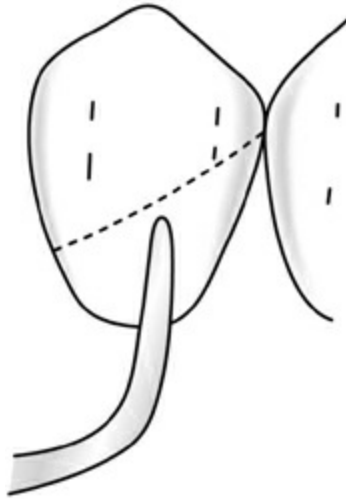


FIG 1.2.4.9 I-clasp

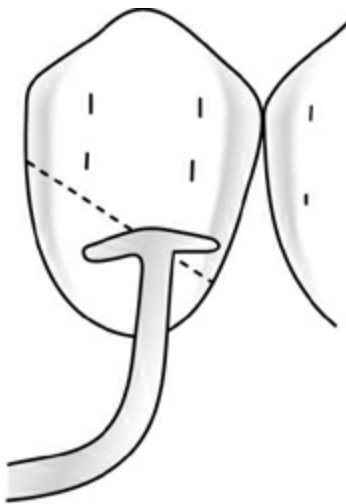


FIG 1.2.4.10 T-clasp

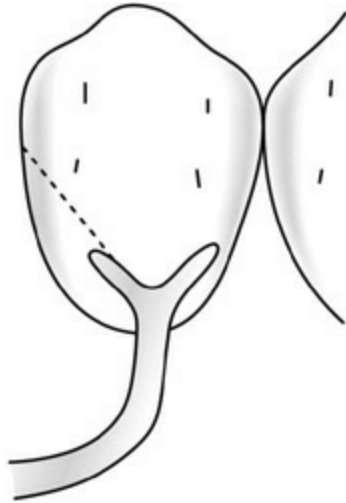

FIG 1.2.4.11 Y-clasp

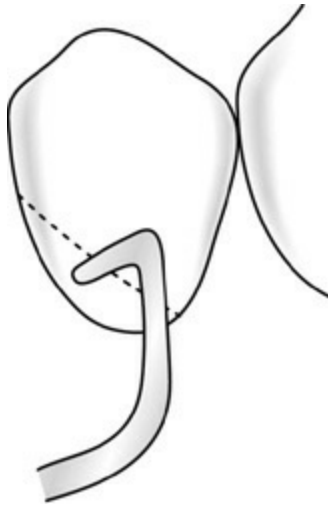


FIG 1.2.4.12 Modified T-clasp

Bar clasps

Types of Clasp	Indications	Advantages	Disadvantages
I bar	<ol style="list-style-type: none"> 1. Aesthetic regions 2. In distal extension partial denture 	Minimal tooth coverage	Encirclement and horizontal stabilization is compromised
T bar	<ol style="list-style-type: none"> 1. Undercut on the distobuccal surface of abutment tooth 2. Used in tooth supported denture where the undercut is located adjacent to the edentulous space 	<ol style="list-style-type: none"> 1. Minimal tooth coverage 2. Reduces the torquing stresses 3. Aesthetically superior to the circumferential clasp group 	<ol style="list-style-type: none"> 1. Cannot be used on terminal abutment, if the undercut is mesial to the edentulous space 2. Cannot be used over a soft tissue undercut
Y bar	Height of contour on the facial surface is higher on the mesial and distal outlines and lower on the centre of facial surface	<ol style="list-style-type: none"> 1. Minimal tooth coverage 2. Reduces the torquing stresses 3. Aesthetically superior to the circumferential clasp group 	<ol style="list-style-type: none"> 1. Cannot be used on terminal abutment, if the undercut is mesial to the edentulous space 2. Cannot be used over a soft tissue undercut
Modified T bar	Aesthetics	Least tooth coverage	Compromising encirclement for aesthetics

Factors influencing the flexibility of clasp design

There are four factors which influence the flexibility of the clasp arm. They are:

1. Length of the clasp arm
2. Diameter of the arm
3. Cross-sectional form of the clasp arm
4. Material used

Factors	Flexibility
Length of the clasp arm	$F \propto L$ flexibility is directly proportional to the length of the clasp arm
Diameter of the clasp arm	$F \propto 1/D$ flexibility is inversely proportional to the diameter of the clasp arm
Cross-sectional form	Flexibility increases in round form, flexibility decreases in $\frac{1}{2}$ round form
Material used	<ol style="list-style-type: none"> 1. Cast gold alloys are more flexible than cast chromium-cobalt base alloys 2. Wrought alloys are more flexible than cast alloys

Factors	Flexibility
Length of the clasp arm	F _o L flexibility is directly proportional to the length of the clasp arm
Diameter of the clasp arm	F _o l/D flexibility is inversely proportional to the diameter of the clasp arm
Cross-sectional form	Flexibility increases in round form, flexibility decreases in ½ round form
Material used	<ol style="list-style-type: none"> 1. Cast gold alloys are more flexible than cast chromium-cobalt base alloys 2. Wrought alloys are more flexible than cast alloys

1.2.5. Indirect retainers

- Definition
- Factors influencing indirect retainers
- Forms of indirect retainers

Definition

The effect achieved by one or more indirect retainers of a partial removable denture prosthesis that reduces the tendency for a denture base to move in an occlusal direction or rotate about the fulcrum line.

Factors influencing the effectiveness of indirect retainers

1. The principal occlusal rests on the primary abutment teeth must be reasonably held in their seats by the retentive arms of the direct retainers.
2. Distance from the fulcrum line. The following three areas must be considered:
 - a. Length of the distal extension base
 - b. Location of the fulcrum line
 - c. How far beyond the fulcrum line the indirect retainer is placed
3. Connectors supporting the indirect retainers should be rigid.
4. Tooth inclines and weak teeth should never be used to support indirect retainers

Forms of indirect retainer (Figs 1.2.5.1a to c)

- a. Auxiliary occlusal rest
- b. Canine rest
- c. Canine extension from occlusal rests
- d. Cingulum bars (continuous bars) and linguoplates
- e. Rugae support

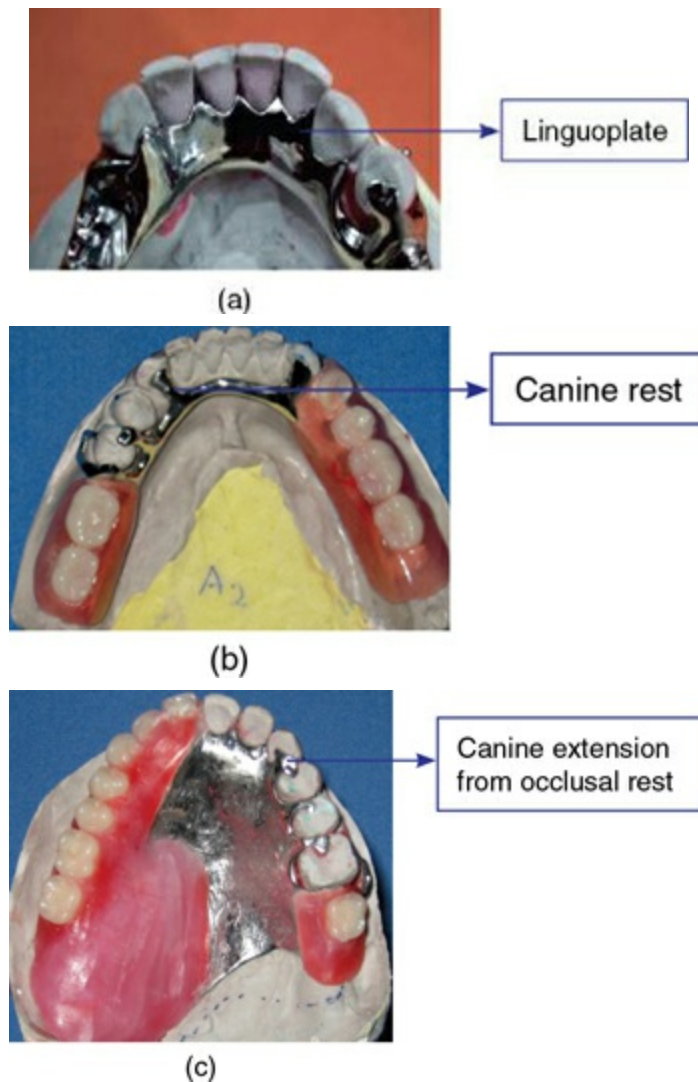


FIG 1.2.5.1A TO C Forms of indirect retainer

Tooth replacement

Types

1. Porcelain or plastic denture teeth on denture base
2. Facing
3. Tube teeth
4. Reinforced acrylic pontics

1.2.6. Surveyors

- Definition
- Types of surveyor
- Uses of surveyor

Definition

The surveyor is essentially a parallelometer, an instrument used to determine the relative parallelism of the surfaces of the teeth or other areas on the cast.

Types

1. 1918 – A.J. Fortunati – Parallelometer
2. 1923 – Ney – surveyor
3. Wills surveyor

Parts of the surveyor (Fig 1.2.6.1a, b)

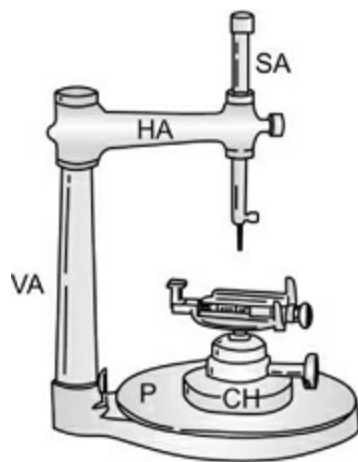
- Platform (P)
- Vertical arm (VA)
- Horizontal arm (HA)
- Surveying arm (SA)
- Cast holder (CH)
- Surveying tools
 1. A level platform that is parallel to the bench top and on which the cast holder is moved (Fig 1.2.6.2).
 2. A vertical arm that supports the superstructure (Fig 1.2.6.3).
 3. A horizontal arm that extends at a right angle from the

vertical column from which extends the other part of the superstructure, the surveying arm (Fig 1.2.6.4). (In the Ney surveyor, the horizontal arm is fixed, whereas in the Wills instrument it may move horizontally around the vertical column.)

4. A surveying arm that drops vertically from the horizontal arm. The surveying arm is capable of movement in a vertical direction (Fig 1.2.6.5). (In the Wills surveyor, the surveying arm is spring loaded. When the arm is not in use, it is held at its most vertical position by spring tension. In the Ney instrument, the arm is completely passive, dropping to its lowest position unless secured at another height by a locking device). The lower end of the surveying arm contains a mandrel, in which the special tools used in the surveying procedure may be locked.
5. A cast holder, or surveying table, to which the cast to be studied is attached (Fig 1.2.6.6). The table, equipped with a clamp to lock the cast in place, is mounted on a ball-and-socket joint that permits the cast to be oriented in various horizontal planes so that the axial surfaces of the teeth as well as other areas of the cast can be analyzed in relation to the vertical plane.
6. An analyzing rod or paralleling tool (Fig 1.2.6.7a, b). This tool contacts the convex surface of the object being studied in the same way a tangent contacts a curve. In this way, the parallelism of one surface to another may be determined. If a carbon rod or marker is substituted for the analyzing rod and the objects being studied are rotated in contact with the marker, as the horizontal plane of the cast is maintained by the cast holder, a survey line indicating the height of contour will be transferred to those surfaces.
7. Additional tools that may be attached to the vertical surveying arm and used in conjunction with the surveyor.
 - a. **Undercut gauges:** These gauges are used to identify the specific amount and location of desired retentive

undercut on the surface of an abutment tooth.

- b. **Wax knife:** This instrument is used in late stages of removable partial denture construction to eliminate or block out areas of undesirable undercuts with wax on the cast before the framework is made (Fig 1.2.6.8).
- c. **Carbon marker:** The marker may be used to scribe the survey line and to delineate an undercut area of the soft tissue or ridge.



(a)



(b)

FIG 1.2.6.1A, B Parts of surveyor



FIG 1.2.6.2 Platform of the surveyor



FIG 1.2.6.3 Vertical arm of the surveyor



FIG 1.2.6.4 Horizontal arm of the surveyor



FIG 1.2.6.5 Surveying arm of the surveyor



FIG 1.2.6.6 Holder of the surveyor

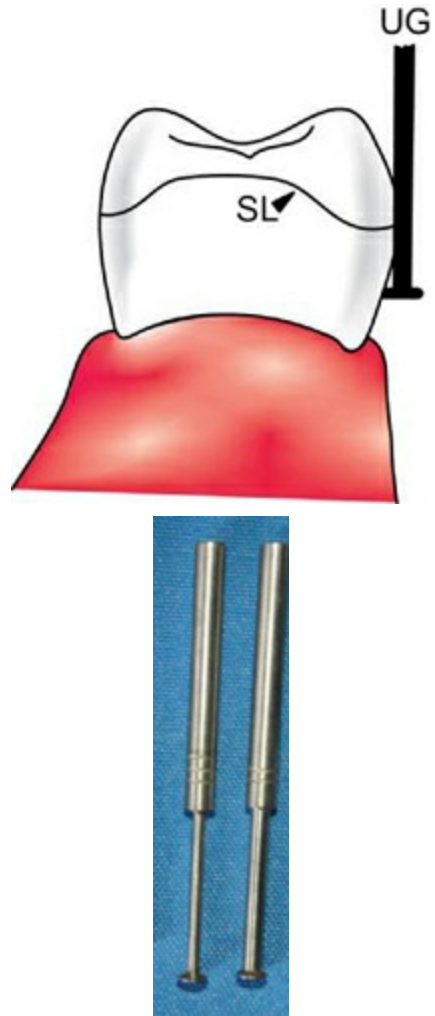


FIG 1.2.6.7A Undercut gauge




FIG 1.2.6.7B Analyzing rod in contact with the tooth surface



FIG 1.2.6.8 Wax knife

Uses

1. Surveying diagnostic cast
2. Tripoding the cast
3. Transferring tripod marks to another cast
4. Contouring wax patterns
5. Contouring crowns and cast restorations
6. Placing internal attachments and rests
7. Surveying the master cast

1.3. Fixed partial denture

- Definition
- Parts of a fixed partial dental prosthesis

Fixed prosthodontics

The branch of prosthodontics pertaining to the replacement of teeth by artificial substitutes that are not removed by the patient.

Crown

An artificial replacement that restores missing tooth structure by

surrounding part or all of the tooth structure with a material, such as cast metal, or a combination of materials, such as metal and porcelain.

Fixed partial denture prosthesis or a fixed bridge

A partial denture that is cemented or otherwise securely retained to natural teeth, tooth roots or dental implant abutments that provide primary support for the prosthesis (Fig 1.3.1.1).

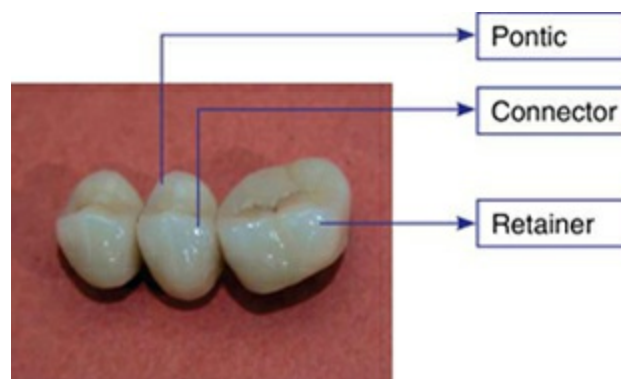
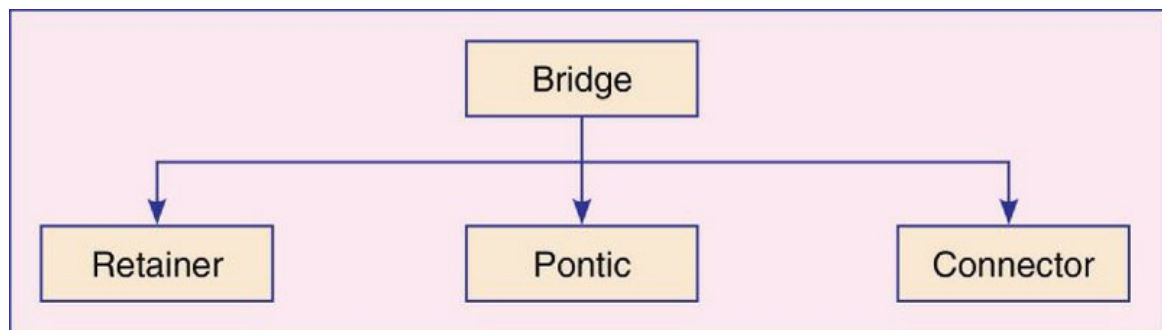


FIG 1.3.1.1 Fixed partial dental prosthesis

1.3.1. Parts of a bridge or fixed partial dental prosthesis

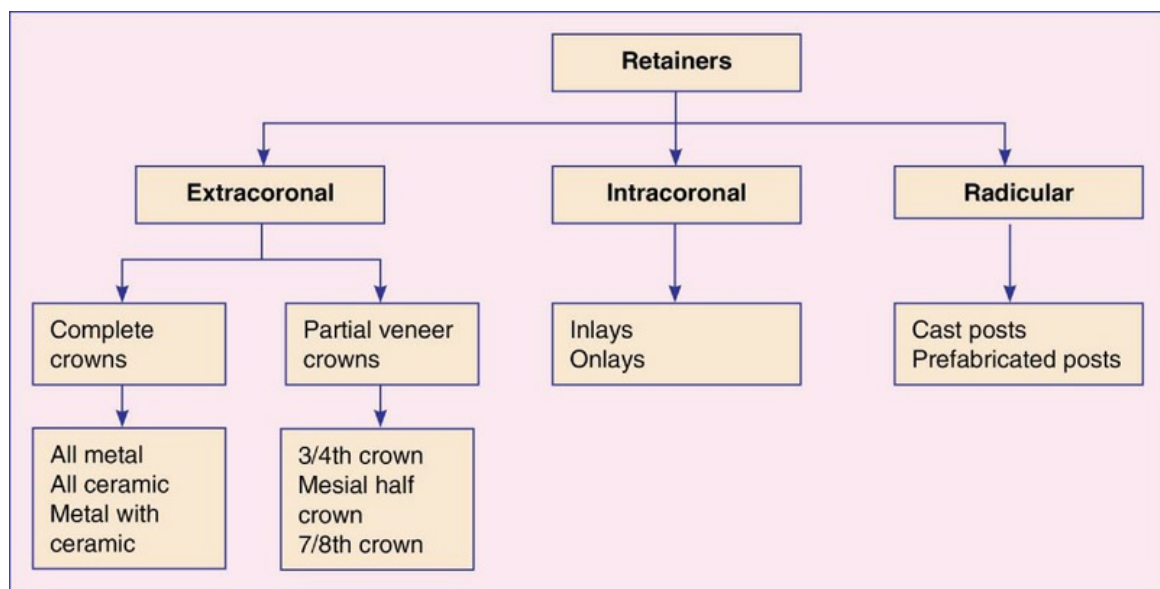


Retainer

Definition

Retainer is a component of a fixed partial dental prosthesis which supports and fixes the prosthesis to the abutment and restores form, function and aesthetics.

Types of retainers



Extracoronaral retainers

That part of a dental prosthesis which is outside or external to the crown portion of a natural tooth.

Complete crown

A restoration that covers all coronal surfaces of the tooth (mesial, distal, facial, lingual and occlusal). The complete crown can be made in cast metal, all ceramic and a combination of metal and ceramic depending on the clinical situation and economic factors.

1. All metal crown

A metal fixed dental prosthesis that restores a clinical crown with the help of a supporting metal framework (Fig 1.3.1.2).

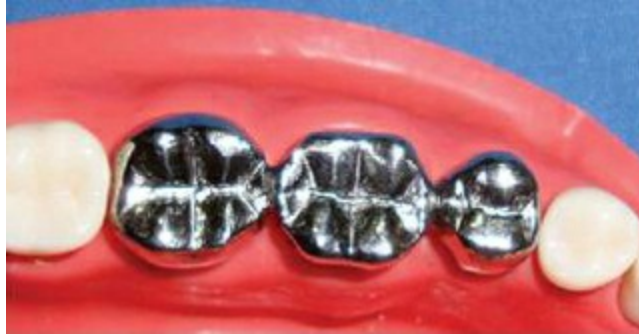

FIG 1.3.1.2 Cast metal crown

2. All ceramic crown

A ceramic fixed dental prosthesis that restores a clinical crown without a supporting metal framework (Fig 1.3.1.3)

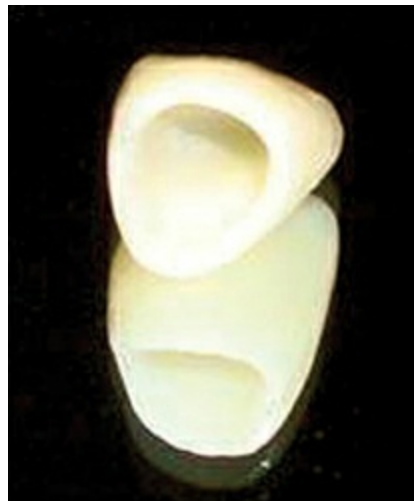

FIG 1.3.1.3 All ceramic crown

3. Metal with ceramic

A fixed dental prosthesis that uses a metal substructure upon which a ceramic veneer is fused (Fig 1.3.1.4).

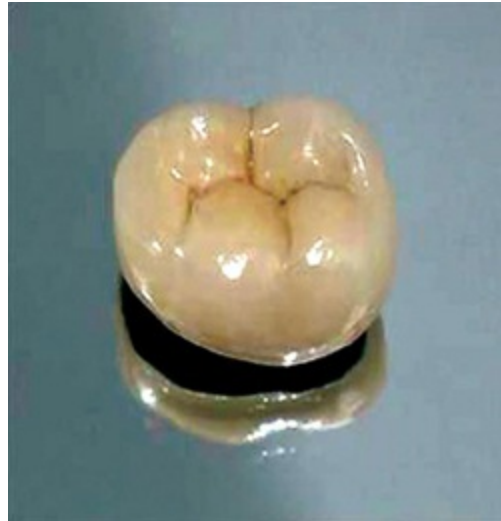

FIG 1.3.1.4 Metal-ceramic crown

Partial veneer crowns

An extracoronal metal restoration that covers only part of the clinical crown is considered to be a partial veneer crown or partial coverage restoration.

1. Anterior 3/4th crown

A restoration that restores all but one coronal surface of a tooth or dental implant abutment, usually not covering the facial surface.

2. Posterior 7/8th crown

It is a three quarter crown whose vertical distobuccal margin is positioned slightly mesial to the middle of the buccal surface (Fig 1.3.1.5).

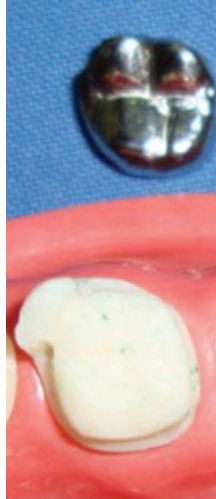

FIG 1.3.1.5 Posterior 7/8th crown

3. Posterior mesial half crown

It is a three quarter crown which has been rotated 90° so that a proximal surface, rather than the facial, is left unveneered ([Fig 1.3.1.6](#)).

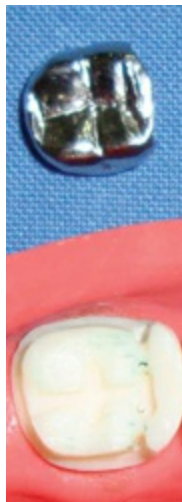

FIG 1.3.1.6 Posterior mesial half crown

Intracoronary retainers

1. Inlays

A fixed intracoronal restoration; a dental restoration made outside of a tooth to correspond to the form of the prepared cavity, which is then luted into the tooth (Fig 1.3.1.7).

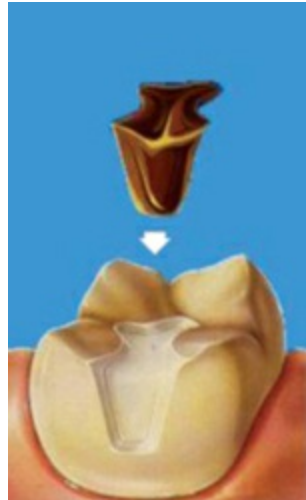


FIG 1.3.1.7 Inlay

2. Onlays

A restoration that restores one or more cusps and adjoining occlusal surfaces or the entire occlusal surface and is retained by mechanically or using adhesive cements.

Radicular retainers

1. Cast posts

A one-piece foundation restoration for an endodontically treated tooth that comprises a post within the root canal and a core replacing missing coronal structure to form the tooth preparation (Fig 1.3.1.8).

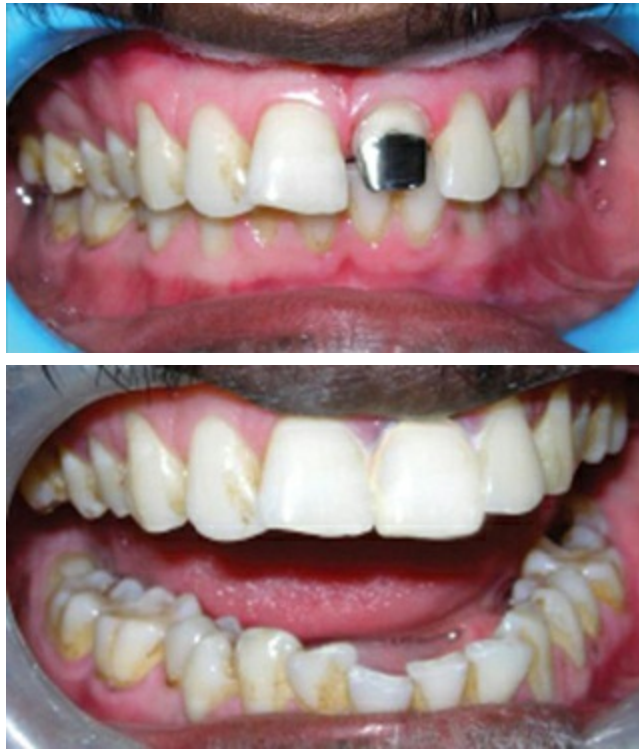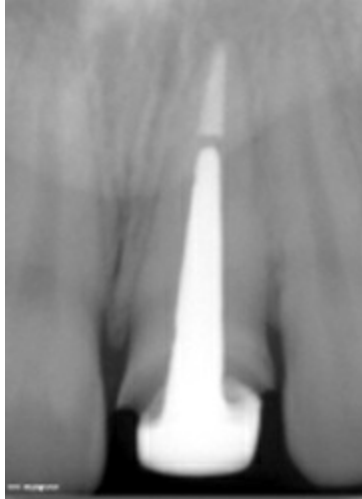


FIG 1.3.1.8 Cast post

2. Prefabricated posts

Prefabricated post and cores consist of two separate entities, each composed out of its material, that are joined by the dentist at the time of the procedure (Fig 1.3.1.9). A universal metal post, sized for the particular diameter of the root canal, is placed as far down as possible

into the post space and cemented with permanent cement, such as zinc phosphate or other luting agents.

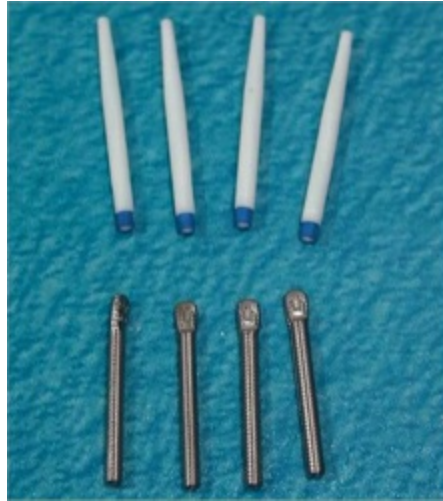

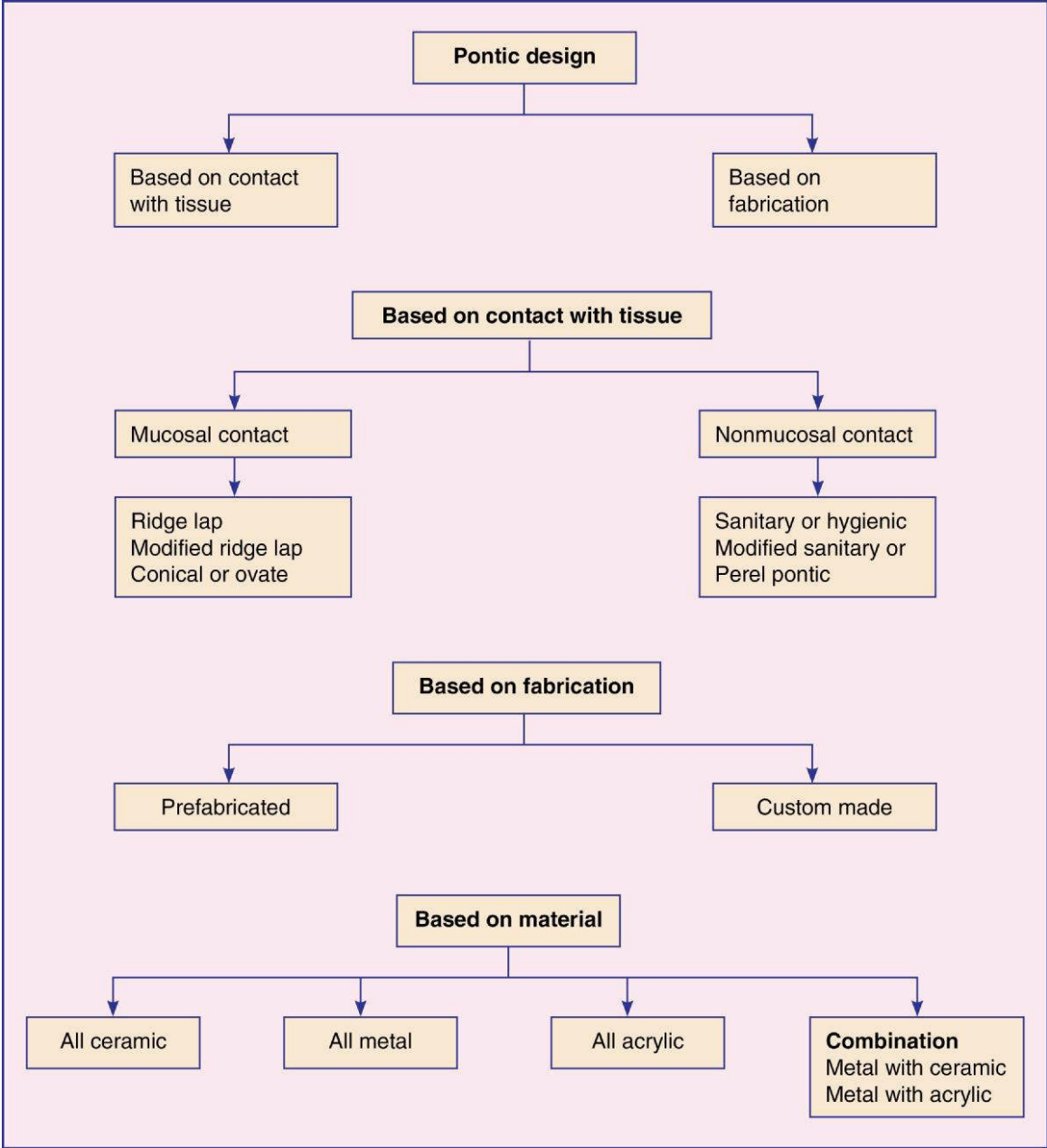
FIG 1.3.1.9 Prefabricated posts

Pontics

Definition

An artificial tooth on a fixed dental prosthesis that replaces a missing natural tooth, restores its function, and usually fills the space previously occupied by the clinical crown.

Types of pontics



CHAPTER 2

Instruments and materials

CS Raj Mohan, S Lakshmi

2.1. Instruments

Rubber bowl (Fig 2.1.1)

- Rubber bowl is used for the manipulation of plaster, stone, and alginate.
- It is available in different sizes.
- It is made of stiff and flexible rubber.



FIG 2.1.1 Rubber bowl

Straight mixing spatula (Fig 2.1.2)

- Straight mixing spatula is used for mixing dental plaster and dental stone.
- The blade of the metallic spatula is straight with a rounded end.
- The handle is made of plastic.

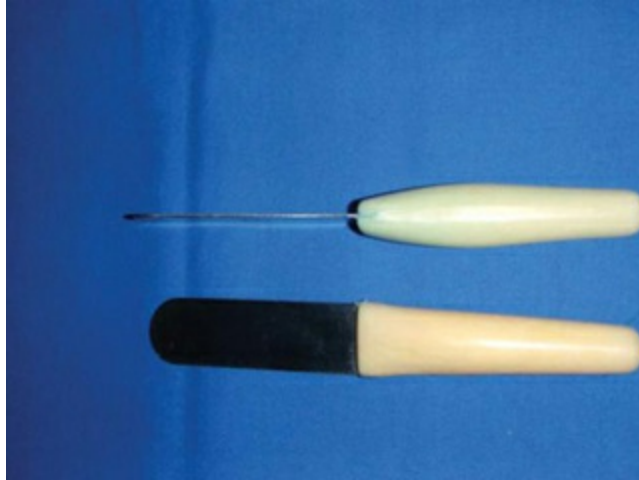


FIG 2.1.2 Straight spatula

Curved mixing spatula (Fig 2.1.3)

- Curved mixing spatula is used for mixing alginate.
- The blade of the metallic spatula is curved with a rounded end.
- The curved end helps in the mixing of the alginate material.

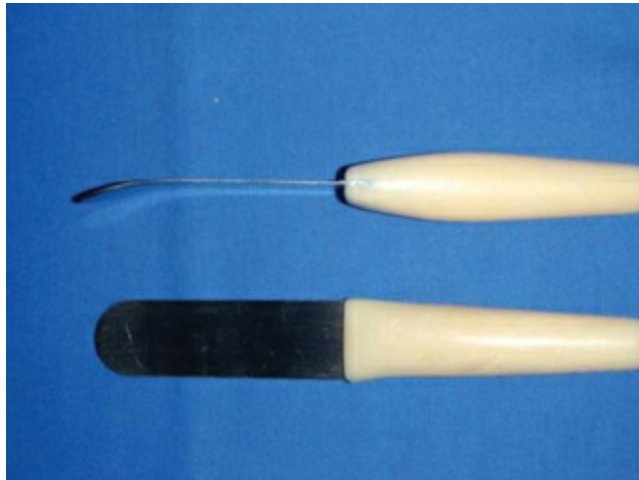


FIG 2.1.3 Curved mixing spatula

Plaster knife (Fig 2.1.4)

- Plaster knife is used in trimming of plaster models.

- The blade of the plaster knife is metallic and is sharp.
- The handle is made of plastic.
- It can also be used during the manipulation of other gypsum products.

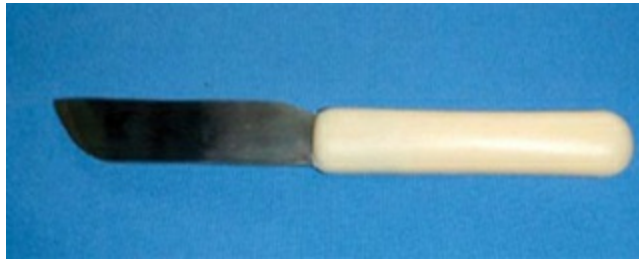

FIG 2.1.4 Plaster knife

Wax knife (Fig 2.1.5)

- Wax knife is used commonly during fabrication of wax occlusion rims, teeth arrangement, wax up procedures and for finner manipulation of dental plaster during procedures, like mounting and flasking.
- It has a knife-like end on one side for cutting wax and the other end has a scoop used for carrying the molten wax and manipulating curved wax surfaces.

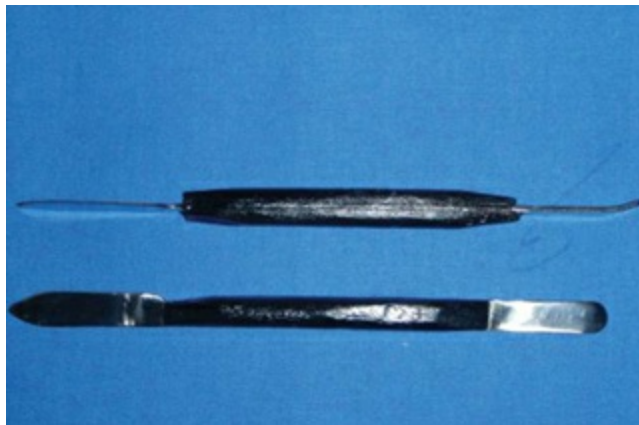


FIG 2.1.5 Wax knife

Wax carver (Fig 2.1.6)

- Wax carver is an instrument used for carving the wax patterns of the tooth.
- The carver has two ends, one end is a scoop used for scooping out wax and the other end has a sharp blade end for carving the pattern in wax.
- Frequent heating of the wax carver may cause bluntness of the carving tip.
- Wax carver is also used in finer manipulation of gypsum products.

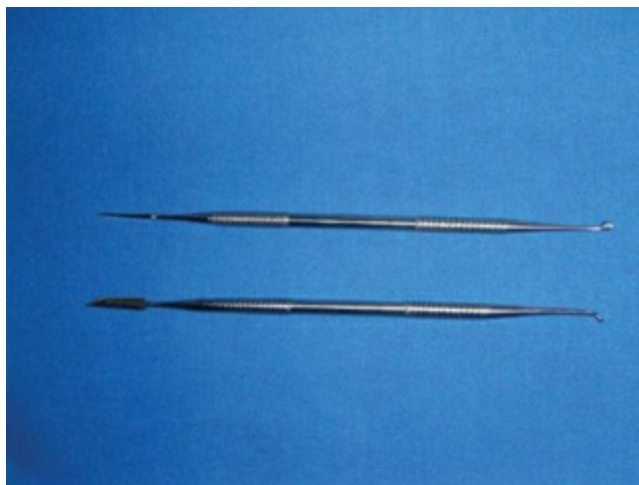


FIG 2.1.6 Wax carver

Wax spatula (Fig 2.1.7)

- Wax spatula is an instrument used for carrying the molten wax during the wax up procedures.
- Wax spatula has two ends, one end has a broad scoop to take molten wax and the other end has a pointed end for carving purpose.



FIG 2.1.7 Wax spatula

Curved scissors (Fig 2.1.8)

- Curved scissors are used for cutting of shellac baseplate during the fabrication of temporary record base.
- The curved scissors have a curved beak.

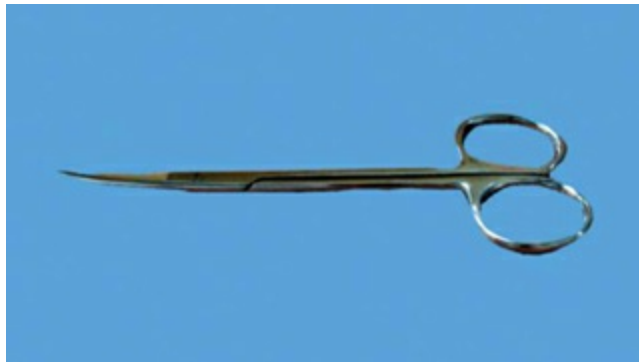

FIG 2.1.8 Curved scissors

Straight scissors (Fig 2.1.9)

- Straight scissors are used for manipulation of temporary record base materials.
- The straight scissors have a straight beak.



FIG 2.1.9 Straight scissors

Dappen dish (Fig 2.1.10)

- Dappen dish is used for mixing small amounts of self-cured acrylic resin.
- It is also used for dispensing small amounts of separating medium, like sodium alginate.



FIG 2.1.10 Dappen dish

Spirit lamp (Fig 2.1.11)

- Spirit lamp has metallic container with a provision for placing the wick and a metallic cap to close the wick.
- Spirit is poured into the container and a cotton wick is inserted into it.

- It gives a continuous noncarbon flame.
- It is used during the chairside clinical procedures for heating of instruments, like wax carver, wax knife, etc.



FIG 2.1.11 Spirit lamp

Chip blower (Fig 2.1.12)

- Chip blower is used commonly in wax up procedures to direct the flame in the area of the wax that needs to be softened and polished.
- It is a mechanical hand-held blower.



FIG 2.1.12 Chip blower

Hot plate (Fig 2.1.13)

- Hot plate is used for uniform reduction of occlusion rims.
- It has a broad metal plate with a plastic handle.



FIG 2.1.13 Hot plate

Edentulous stainless steel stock tray (Fig 2.1.14)

- Edentulous stainless steel stock tray is used for making

- impressions of edentulous patients with impression compound.
- It is a prefabricated nonperforated impression tray made of stainless steel.
 - The impression tray has a carrier for carrying the impression material and a handle for positioning and handling the impression.
 - The lower tray is U-shaped to accommodate the tongue whereas the upper tray is shaped to accommodate the palate and alveolar ridge.



FIG 2.1.14 Edentulous stainless steel stock tray

Dentulous metallic stainless steel stock tray (Fig 2.1.15)

- Dentulous metallic stainless steel stock tray is used for making impressions of dentulous patients.
- It is a prefabricated impression trays made of stainless steel with perforations which aids in the retention of impression material, such as alginate.



FIG 2.1.15 Perforated dentulous stock tray

Porcelain cup with lid (Fig 2.1.16)

- A porcelain cup is used for mixing heat-cure and self-cure acrylic resin material.
- When the polymer and monomer material is sifted into the porcelain cup, the cup is closed with the lid to prevent evaporation of monomer.

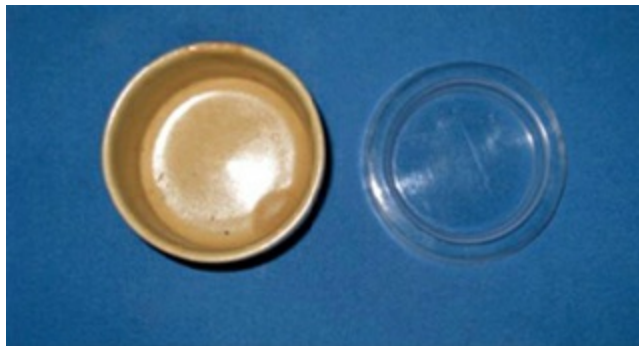

FIG 2.1.16 Porcelain cup with lid

Dental flask (Fig 2.1.17a, b)

Dental flask is used for investing the waxed denture in dental plaster for processing into acrylic denture.




FIG 2.1.17A Dental flask



FIG 2.1.17B Upper and lower dental flasks

The dental flask consists of three components namely the base, the body and the lid.

There are orienting prongs in the base and corresponding notches in the base which will help in assembling the base and the body.

Glass slab and mixing spatula (Fig 2.1.18)

- Glass slab and mixing spatula are used for mixing zinc oxide eugenol impression material and light body elastomeric impression material.
- The blade of the mixing spatula is about 5 cm in length and flexible.

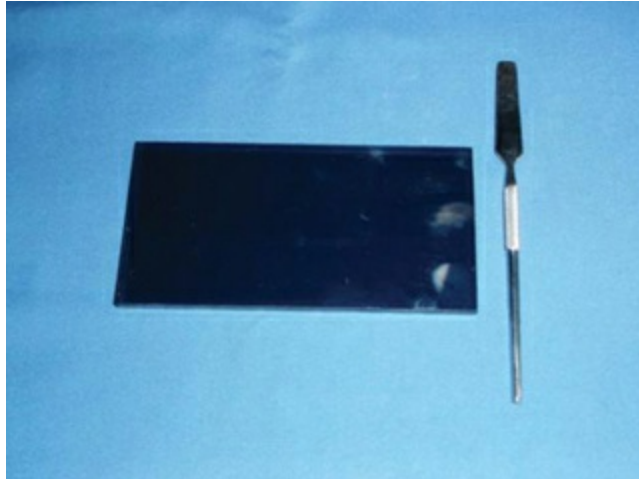


FIG 2.1.18 Glass slab and mixing spatula

Glass plate (Fig 2.1.19)

- A square glass plate is used as a template during the setting of artificial teeth.




FIG 2.1.19 Glass slab and mixing spatula

Mixing pad and mixing spatula (Fig 2.1.20)

- The mixing pad and mixing spatula are used for mixing light body elastomeric impression material and zinc oxide eugenol impression material.
- The mixing pad is made of oil impervious paper.
- The mixing pad has two distinct lines marked with numbers marked for taking equal length of the base paste and reactor paste.
- The mixing spatula has a long stiff broad blade and a plastic handle.




FIG 2.1.20 Mixing pad and mixing spatula

Acrylic trimmer-tungsten carbide (Fig 2.1.21)

- Acrylic trimmer is a motor driven tool used for trimming the acrylic resin.
- It is available in various forms and sizes.
- It is used during the gross trimming of the acrylic dentures after processing of the dentures.



FIG 2.1.21 Acrylic tungsten carbide trimmer

Sandpaper mandrel (Fig 2.1.22)

- Sandpaper mandrel is a motor driven tool used for holding the sandpaper during the finishing procedures involving denture base resins.



FIG 2.1.22 Sandpaper mandrel

Bard – parker blade and handle (Fig 2.1.23)

- Bard – Parker blade is a sharp sterile blade and can be fixed into a handle.
- It is used for trimming excess material during manipulation, like impression compound and self-cure acrylic resin.



FIG 2.1.23 Bard – Parker blade and handle

Acrylic trimmer-mounted stones (Fig 2.1.24)

- Acrylic trimmer is a motor driven tool used for trimming and smoothing the surface of acrylic dentures.
- It is available in various forms and sizes.




FIG 2.1.24 Acrylic trimmer-mounted stones

Rag wheel (Fig 2.1.25)

- Rag wheel is made of crocus cloth which is attached to a lathe machine.
- Rag wheel is a medium for impregnating, polishing or finishing materials, like rouge, tin oxide, pumice.
- It is used for polishing acrylic partial and complete dentures.



FIG 2.1.25 Rag wheel

Gas torch (Fig 2.1.26)

- Gas torch is a self-igniting hand-held flame torch. Gas torch gives a continuous noncarbon flame. The gas torch is filled with butane gas which is commercially available.
- Gas torch is used during fabrication of shellac record bases, fabrication of wax occlusion rims and for chairside heating of instruments, like wax carver and wax knife.



FIG 2.1.26 Gas torch

Automixer or dispenser with spiral tips for light body elastomeric impression material (Fig 2.1.27).

- The automixer is used for uniform mixing and dispensing of light body elastomeric impression material.
- The spiral dispensing tip varies in diameter and length.
- The number of spirals in the unit should be 13.
- The base and the catalyst paste are mixed homogenously with this automixer.

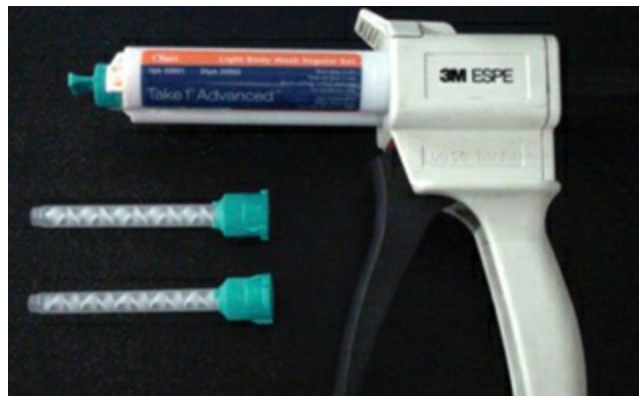

FIG 2.1.27 Automixer or dispenser with spiral tips for light body elastomeric impression material

Diamond abrasive points (Fig 2.1.28)

- The diamond abrasive burs are used to grind the tooth surface for dental procedures.
- The diamond abrasive particles or grits are bonded to the bur blanks.
- The diamond abrasive grits are classified as coarse, medium coarse, medium fine and super fine and are colour coded as red, green, blue, and yellow, respectively.
- The grit size varies from 120 microns to 5 microns in size.



FIG 2.1.28 Diamond abrasive points

Articulating paper (Fig 2.1.29)

- Articulating paper is used for assessing and determining the occlusal contacts between the upper and lower teeth.
- Articulating paper comes in varying thickness, like 90 microns, 40 microns, 20 microns, and 12 microns.
- It comes in colours, like red, blue, and green for differentiating the marks on surfaces, like gold, enamel, and ceramic surfaces.



FIG 2.1.29 Articulating paper

2.2. Materials

A. Gypsum products

Dental plaster (Fig 2.2.1)

- Dental plaster is used for making casts, for mounting casts in the articulator and as an investment material for denture construction.
- Type II gypsum product consists of irregular, porous β -hemihydrate particles of calcium sulphate.
- W:P ratio is 0.45–0.50.
- Setting time is 12 ± 4 minutes.



FIG 2.2.1 Dental plaster

Dental stone (Fig 2.2.2)

- Dental stone is used for the fabrication of master casts for removable prosthesis.
- Type III gypsum product consists of regular, crystalline α -hemihydrate particles of calcium sulphate.

- It is formed by the calcination of gypsum under steam pressure.
- W:P ratio is 0.28–0.30.
- It is intended for construction of casts with good strength and surface details.



FIG 2.2.2 Dental stone

Die stone (Fig 2.2.3)

- Die stone is used as die material for inlay, crown and bridge prostheses.
- Type IV gypsum product with high strength and low expansion.
- W:P ratio is 0.22–0.24.
- The surface of the dies is resistant to abrasion.



FIG 2.2.3 Die stone

Phosphate bonded investment material (Fig 2.2.4)

- Phosphate bonded investment is used for casting high fusing, noble metal alloys, metal ceramic and base metal alloys, like Ni-Cr, and Co-Cr.
- It consists of investment powder and colloidal silica suspensions.
- W:P ratio to be followed as per the manufacturers instructions.
- It gives greater thermal expansion to the investment.



FIG 2.2.4 Phosphate bonded investment material

B. Impression materials

Impression compound (Fig 2.2.5)

- Impression compound is used for making primary impressions of edentulous arches.
- It is an inelastic thermoplastic impression material.
- It consists of waxes, resins, filler and a colouring agent.
- Its ADA specification number is 3.




FIG 2.2.5 Impression compound

Tracing stick compound (Greenstick compound) (Fig 2.2.6)

- Tracing stick compound is used for border moulding of an acrylic custom tray for final edentulous impressions.
- It is a form of impression compound in the form of stick.
- It consists of waxes, thermoplastic resins, filler and a colouring agent.
- Its ADA specification number is 3.



FIG 2.2.6 Tracing stick compound

Zinc oxide eugenol impression pastes (Fig 2.2.7)

- Zinc oxide eugenol impression paste is used for making final impression of edentulous patients, bite registrations.
- It is an inelastic impression material of ADA specification number 16.
- It is supplied in paste form as base paste and reactor paste.
- It is formed by the zinc oxide hydrolysis and a subsequent reaction between zinc hydroxide and eugenol to form a chelate (zinc eugenolate).
- Its chief disadvantage is the burning sensation caused by eugenol and it is replaced by non-eugenol pastes.

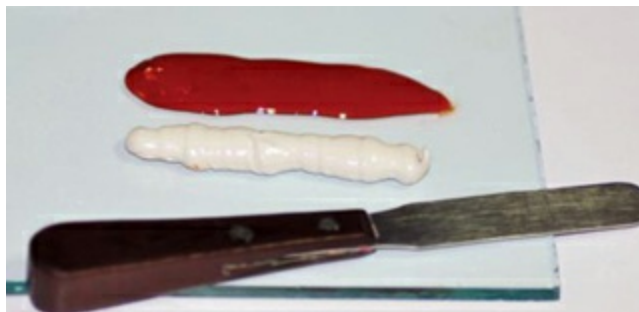

FIG 2.2.7 Zinc oxide eugenol impression paste

Agar (Fig 2.2.8)

- Agar is used for making impressions of dentulous and partially dentulous arches.
- It is the first elastic impression material used in dentistry.
- It is a reversible hydrocolloid.
- The impression is made with a tray called, rim-locked water-cooled tray.
- It needs separate equipment called as a 'conditioning unit' for manipulation of the impression material.



FIG 2.2.8 Agar impression material

Alginate (Fig 2.2.9a, b)

- Alginate is an elastic material used for partially and completely edentulous and dentulous impressions.
- It is an irreversible hydrocolloid with ADA specification number 18.
- It is a natural substance yielded from a peculiar mucous extraction of brown seaweed (algae).

- The chief active ingredient is soluble alginates, such as sodium or potassium (triethanolamine alginates).
- W:P ratio is 15 gm:40 ml of water.
- The material is mixed in the rubber bowl with the mixing spatula.



FIG 2.2.9A Alginate impression material



FIG 2.2.9B Alginate supplied in packets

Elastomeric impression material—addition

silicone light body viscosity (Fig 2.2.10)

- Also known as polyvinylsiloxane elastomeric impression material with ADA specification number 19.
- It is supplied in tubes as paste form.
- It has a reactor paste and base paste.
- Equal length of base and reactor paste are used during manipulation.
- Reacts by addition reaction, so no by-product and therefore, good dimensional stability.
- It is mixed on the mixing pad with the mixing spatula.
- It is also mixed in an automixing gun with which material is directly applied on the tooth surface.
- It gives most accurate surface detail reproduction.
- It has less filler particles and good flow.

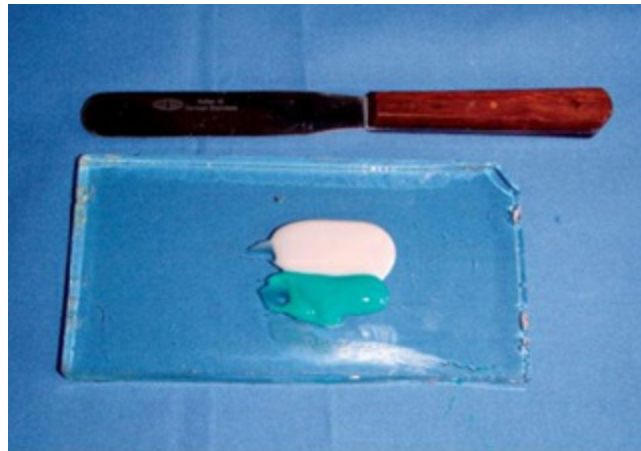

FIG 2.2.10 Addition silicone —light body consistency

Elastomeric impression material—addition silicone of putty consistency (Fig 2.2.11)

- Putty material is used as the tray material in conjunction with a light body silicone to make impressions.
- It is classified as non-aqueous elastomeric impression material with

ADA specification number 19.

- It is supplied in jars as base and reactor separately.
- Equal amount of base and reactor are taken with the scoop during manipulation.
- It reacts by addition reaction, without by-product and therefore, good dimensional stability.
- It has more filler particles and less flow.



FIG 2.2.11 Addition silicone —putty consistency

C. Dental waxes

Modelling wax (**Fig 2.2.12**)

- Modelling wax is used to make occlusal rims, trial denture and bite registration.
- It is also called as baseplate wax.
- It consists of paraffin, beeswax, carnauba wax and resins.
- Its ADA specification number is 24 and classified as Type I soft, Type II medium and Type III hard.



FIG 2.2.12 Modelling wax

Sticky wax (Fig 2.2.13)

- Sticky waxes are used to join fragments of broken denture during repair and temporarily stabilize the components of a bridge before soldering.
- These waxes are quite tacky when they are melted, but firm and brittle when they are cooled.



FIG 2.2.13 Sticky wax

Prefabricated wax patterns (Fig 2.2.14a, b)

- Casting waxes are available as patterns for metallic framework of cast partial dentures.
- They are available in different clasp designs as circumferential clasp and bar clasp design.




FIG 2.2.14A Prefabricated wax for circumferential clasp




FIG 2.2.14B Prefabricated wax for bar clasp

Inlay wax (Fig 2.2.15)

- The essential ingredients of inlay wax are paraffin wax, gum dammar, carnauba wax and colouring agent.
- Its ADA specification number is 4.
- It is of two types

Type I—medium wax

Type II—soft wax

- Medium wax is employed in direct techniques.
- Soft wax is employed in indirect techniques.
- One of its desirable properties is its flow other than thermal properties.



FIG 2.2.15 Inlay wax

Pattern wax (Fig 2.2.16)

- Pattern wax is used in wax up of tooth in fixed partial dentures.
- This wax is later replaced with the permanent restorative material.



FIG 2.2.16 Pattern wax for tooth carving

D. Denture base resins

Heat-cure acrylic resin (Fig 2.2.17)

- Heat-cure acrylic resin is mainly used for making denture bases for complete denture, removable partial denture.
- It is heat-activated denture base resin.
- It is available as powder and liquid.
- The powder is the polymer that may be transparent or pink in colour to simulate the gums.
- The liquid is the monomer supplied in tightly sealed amber-coloured bottles (to prevent premature polymerization by light).



FIG 2.2.17 Heat-cure acrylic resin

Self-cure acrylic resin (Fig 2.2.18)

- Self-cure acrylic resin is used for the construction of special trays, temporary crowns and bridges, for denture repair, relining and rebasing and for making removable orthodontic appliances.
- They are chemically activated resins often referred to as cold-curing, self-curing or auto-polymerizing resins.
- The fundamental difference between heat and chemically activated resin is the presence of a tertiary amine (dimethyl-paratoluidine) as an activator.
- It is inferior to heat-activated resin in strength and colour stability.

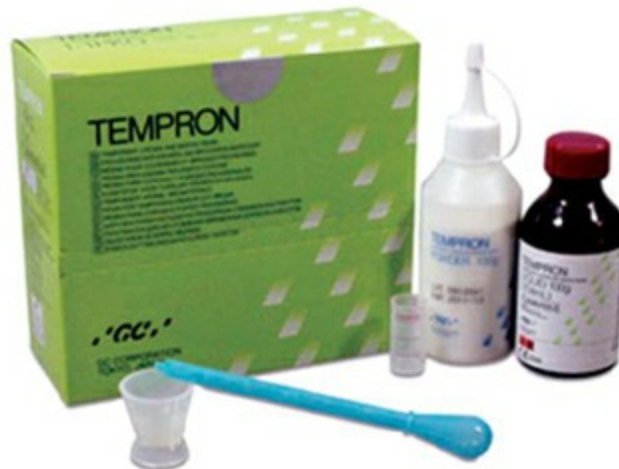

FIG 2.2.18 Self-cure resin

Separating medium (Fig 2.2.19)

- Separating medium is a medium which prevents direct contact between the denture base resin and the model or cast surface.
- It is a soluble solution of sodium alginate.
- It produces thin relatively insoluble calcium alginate films when applied to dental stone or plaster surface.
- It is applied with the brush in a unidirectional stroke on the model

- or cast surface.
- Other separating media used are tinfoil, cellulose lacquers, soft soaps, sodium silicate, etc.



FIG 2.2.19 Separating medium

Acrylic anterior teeth (Fig 2.2.20)

- Acrylic anterior teeth are used for anterior teeth replacement in complete or partial denture.
- They are made of cross-linked acrylic resin.

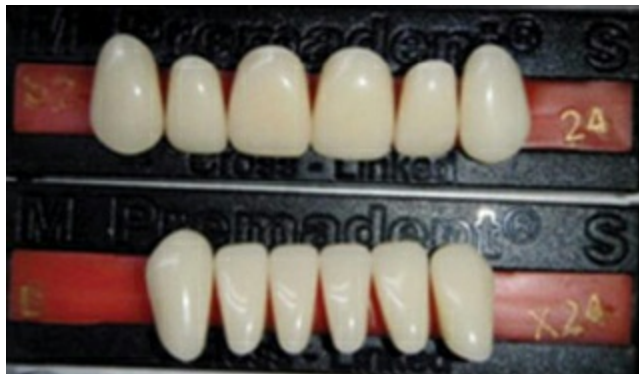

FIG 2.2.20 Acrylic anterior teeth

Acrylic posterior teeth (Fig 2.2.21)

- Acrylic posterior teeth are used for posterior teeth replacement in complete or partial.
- They are made of cross-linked acrylic resin.

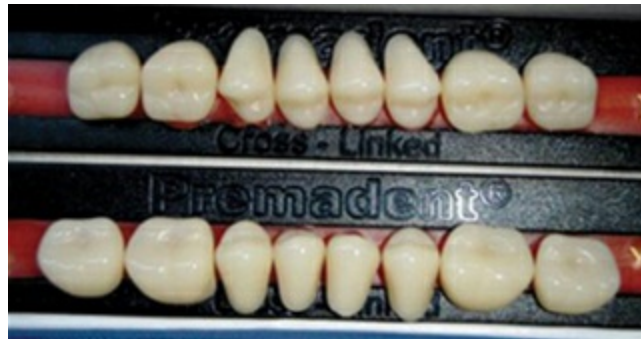

FIG 2.2.21 Acrylic posterior teeth

Light-cure denture base resin (Fig 2.2.22)

- Visible light-activated denture base resin consists of a matrix of urethane dimethacrylate, microfine silica, high molecular weight acrylic resin monomers.
- Visible light is the activator and camphorquinone is the initiator for polymerization.
- These are supplied in sheet and rope forms and packed in light-proof packets to prevent polymerization.
- These are used in the fabrication of denture bases, record bases and custom impression trays.



FIG 2.2.22 Light-cure denture base resin

Soft relining materials for dentures (Fig 2.2.23)

- Denture relining materials are plasticized acrylic resins which may be chemically activated or heat-activated.
- The principal component is polymethyl or ethylmethacrylate with 60 – 70% of plasticizer like dibutyl pthalate.
- The soft reliners act as a shock absorber between the occlusal surfaces of a denture and the underlying oral tissues.
- The short- term reliners are called as tissue conditioners.

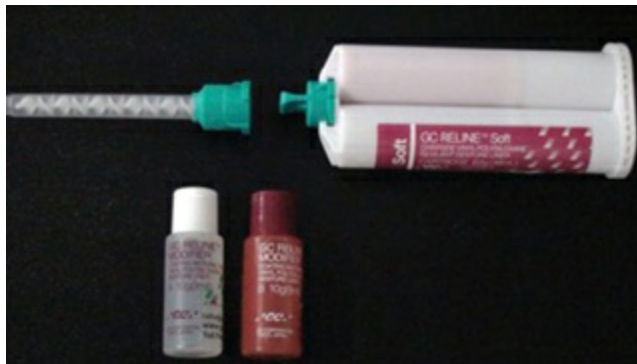

FIG 2.2.23 Soft relining materials for dentures

Temporary light-cure resin materials for crowns and bridge (Fig 2.2.24)

The temporary resin material is used for the fabrication of temporary crowns and bridges. The temporary resin material is polymerized by chemical cure and light cure. The main chemical component of resin material is bis-acryl composite material. The resin material is available as base and reactor paste.

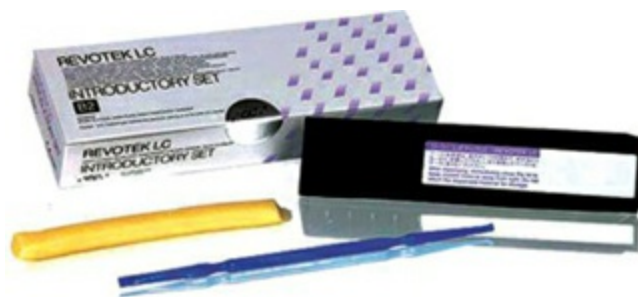

FIG 2.2.24 Temporary light-cure resin materials for crowns and bridge

E. Base metal alloys

Base metal alloy pellets (Fig 2.2.25)

- Base metal alloys are commonly used for casting procedures during the fabrication of indirect restorations, like crowns, inlays, onlays, and bridges.
- They are available commercially in the form of pellets.




FIG 2.2.25 Base metal alloy pellets

F. Ceramics

Ceramic powder (Fig 2.2.26)

- Ceramic powder is used for crowns and bridges, veneers, inlays, onlays, artificial teeth, etc.
- Dental ceramics is the most durable aesthetic material which is chemically inert.
- It mainly consists of silica network and potash feldspar or soda feldspar with pigments, opacifiers and glassmodifiers.
- The other attributes of ceramics are their insulating properties (low thermal conductivity, thermal diffusivity, and electrical conductivity).



FIG 2.2.26 Dental ceramic powder

G. Abrasives and polishing agents

Sandpaper (Fig 2.2.27)

- Sandpaper is used for smoothening surfaces of metal alloys or acrylic materials.
- It is available in a variety of grit sizes.



FIG 2.2.27 Sandpaper

Sandpaper (Emery) (Fig 2.2.28)

- Emery is used for smoothening surfaces of metal alloys or plastic materials that have been roughened by finishing abrasives.
- It is an abrasive which is a greyish black corundum that is prepared in a fine grain form.
- It is available in a variety of grit sizes.



FIG 2.2.28 Emery paper

Rouge (Fig 2.2.29)

- Rouge is used to polish high noble metal alloys.
- It is a fine, red abrasive that contains iron oxide.
- It is blended with Tripoli and other soft binders to form a cake.



FIG 2.2.29 Rouge

Pumice (Fig 2.2.30)

- Pumice is used in polishing tooth enamel, gold foil, dental amalgam, and acrylic resins.
- It is light grey, highly siliceous material.
- It is used mainly in grit form but can be found in some rubber-bonded abrasives.



FIG 2.2.30 Pumice powder

H. Dental luting cements

Zinc phosphate cement (Fig 2.2.31)

- Zinc phosphate is permanent luting cement for crowns and bridges.
- It is supplied as powder and liquid.
- The powder contains zinc oxide and the liquid contains phosphoric acid, aluminium phosphate and water.
- The setting time is 5–9 min.

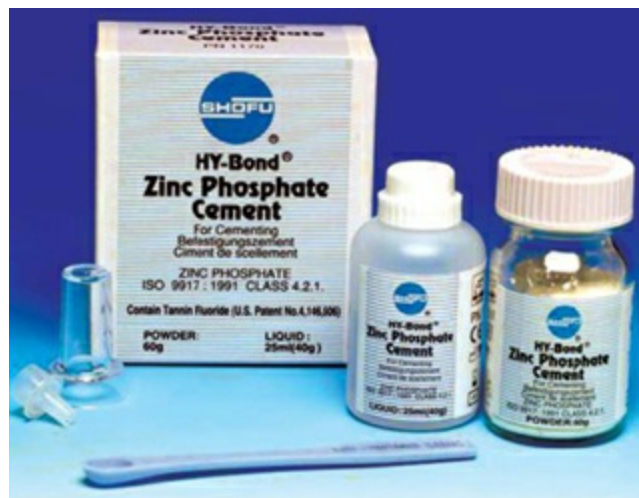

FIG 2.2.31 Zinc phosphate cement

Type 1 glass ionomer cement (Fig 2.2.32)

- Type 1 glass ionomer cement is used for luting permanent indirect restorations, like crowns and bridges to the tooth structure.
- The cement consists of powder and liquid.
- The powder contains silica, alumina, calcium fluoride, aluminium phosphate and the liquid contains polyacrylic acid, and water.
- The cement bonds chemically to the tooth surface involving an ionic interaction with calcium and phosphate ions from the surface of enamel and dentin.



FIG 2.2.32 Type 1 glass ionomer cement

Resin modified glass ionomer cement (Fig 2.2.33)

- Resin modified glass ionomer cement is basically a glass ionomer with a little composite resin integrated into it.
- It has better aesthetics and increased bond strength.
- It is used for luting permanent restorations, like crowns and bridge.

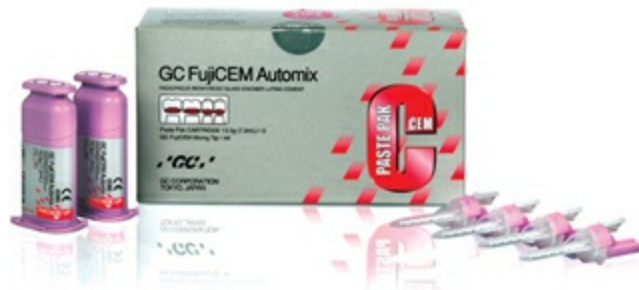

FIG 2.2.33 Resin-modified glass ionomer cement

Zinc oxide eugenol temporary luting cement (Fig

2.2.34)

- Zinc oxide eugenol temporary luting cement is used for temporary cementation of crowns and bridges and provisional restorations.
- It has powder and liquid component.
- The powder contains zinc oxide and white resin and the liquid contains eugenol.
- The setting reaction is a chelation reaction where in zinc eugenolate is the chelate formed.
- The setting time of the cement is 4–10 minutes.

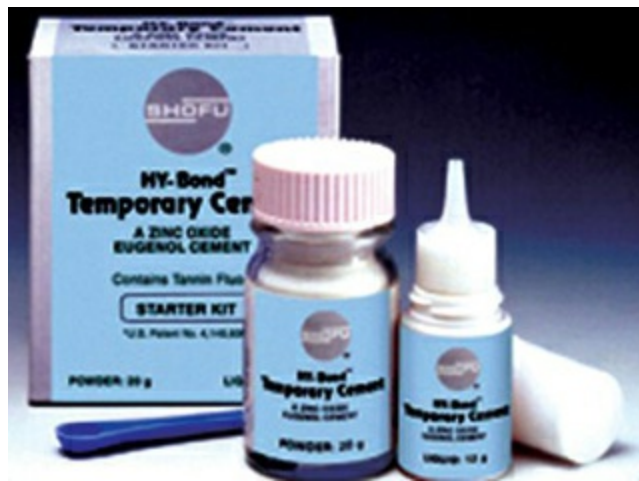

FIG 2.2.34 Zinc oxide eugenol temporary luting cement

Eugenol free temporary luting cement (Fig 2.2.35)

- Eugenol free temporary luting cement is used for temporary cementation of all ceramic crowns and bridges and provisional restorations.
- It is supplied as base and catalyst paste.
- Two equal amounts of the base and the catalyst paste are taken for a homogenous mix of the cement.



FIG 2.2.35 Eugenol free temporary luting agent

CHAPTER 3

Preclinical exercise

D Sendhilnathan, S Lakshmi, CS Raj Mohan

3.1. Complete denture fabrication

3.1.1 Indexing of dental casts

Indexing of the master casts is essential because the casts after processing of the waxed dentures can be remounted in the articulator in the same position. This helps us to do selective grinding procedures to reduce processing errors.

Indexing can be done by two methods:

- i. Groove indexing
- ii. Notch indexing

Armamentarium (Fig 3.1.1.1)

- Dental casts
- Metallic scale
- Pencil or marker pen
- BP handle with blade no:15



FIG 3.1.1.1 Armamentarium for indexing

Groove indexing

On the base of mandibular cast, 2 lines are drawn on the base of the cast from anterior to posterior aspect of the cast as shown in [Figure 3.1.1.2](#).

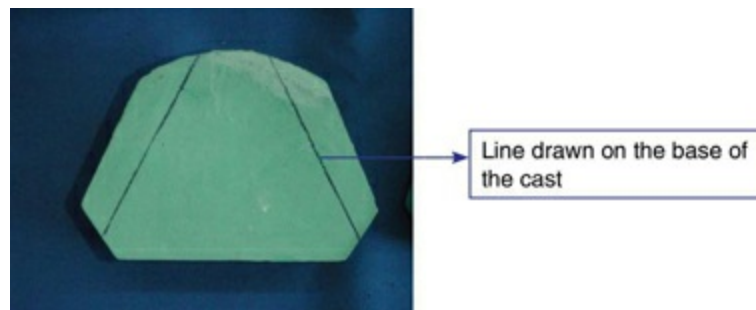


FIG 3.1.1.2 Two lines drawn on the base of mandibular cast

Grooves are cut along the line drawn on the base of the mandibular cast with a no. 15 BP blades of 3mm deep and 5mm width as shown in [Figure 3.1.1.3](#).




FIG 3.1.1.3 Grooves cut at the base of the cast

On the base of the maxillary cast, 2 lines are drawn, one vertical line and one horizontal line perpendicular to each other. The lines should approximately intersect in the centre of the base of the cast as shown in [Figure 3.1.1.4](#).

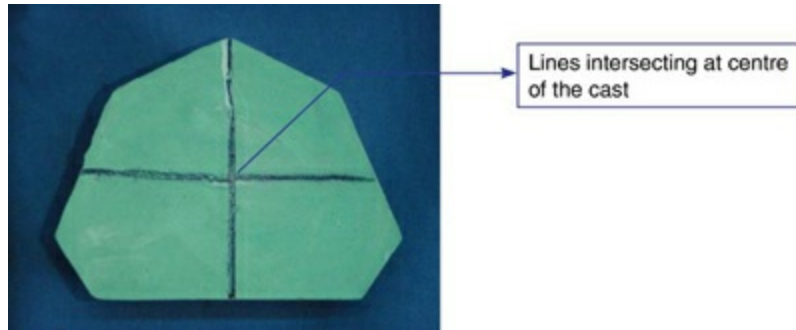


FIG 3.1.1.4 Perpendicular lines at the base of the maxillary cast

The V-shaped grooves are made with the no. 15 BP blade on the base of the maxillary cast as shown in [Figure 3.1.1.5](#).




FIG 3.1.1.5 The V-shaped groove at the base of the cast

Notch indexing

In notch indexing, 3 V-shaped notches are marked on the base of the mandibular cast (one in anterior and 2 in posterior) and 4 V-shaped notches are marked (one in the anterior, one in posterior and one on either side of the maxillary cast) as shown in [Figure 3.1.1.6](#). The notch should be 3mm deep and 5mm wide.


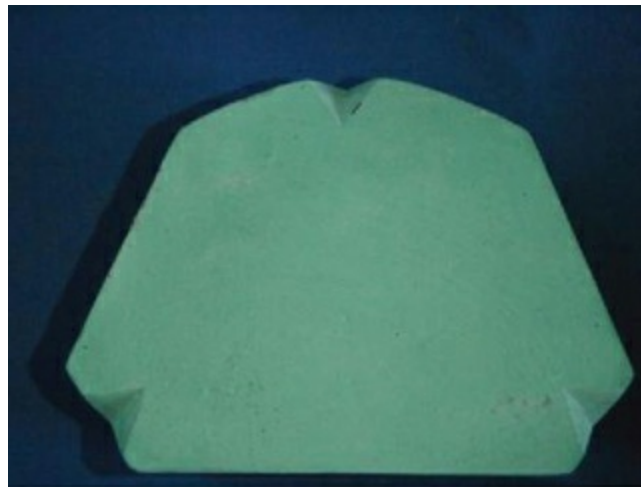


FIG 3.1.1.6 Notches marked on the base of the maxillary and mandibular casts

The 'V'-shaped notches are cut with a no. 15 BP blade along the V-shaped notches marked on the base of the cast: 3 notches on the base of the mandibular cast and 4 notches on the base of the maxillary cast as shown in [Figure 3.1.1.7a, b](#).



(a)




FIG 3.1.1.7A, B Notches cut at the base of the maxillary and mandibular casts

Groove indexing is preferred over notch indexing because sometimes it is necessary to reduce the cast size to fit in a dental flask during flasking procedure. When reducing the size of the cast, the peripheral notches will be trimmed which can result in the loss of the index. Before mounting the casts, the grooves or notches should be lubricated with a separating medium. This will ensure easy removal of the casts from the plaster mountings in the articulator.

3.1.2 Shellac baseplate adaptation

i. Armamentarium (Fig 3.1.2.1)

- Shellac baseplate
 - Maxillary
 - Mandibular
- Maxillary and mandibular cast
- Bunsen burner (or) gas torch
- Curved scissors
- Wax spatula
- Chip blower
- Sandpaper
- Marker pen



FIG 3.1.2.1 Armamentarium

The maxillary record base is placed over the maxillary edentulous cast in such a way that shellac record baseplate covers the entire surface of the cast (Fig 3.1.2.2). The baseplate should not be placed either too anteriorly or posteriorly. In the posterior aspect, it should

cover the tuberosity and posterior palatal seal area of the edentulous cast.




FIG 3.1.2.2 Maxillary shellac baseplate on the maxillary cast

The flame from a Bunsen burner or a gas torch is moved slowly over the surface of the shellac baseplate wax till it appears shiny and slumps onto the cast ([Fig 3.1.2.3](#)).

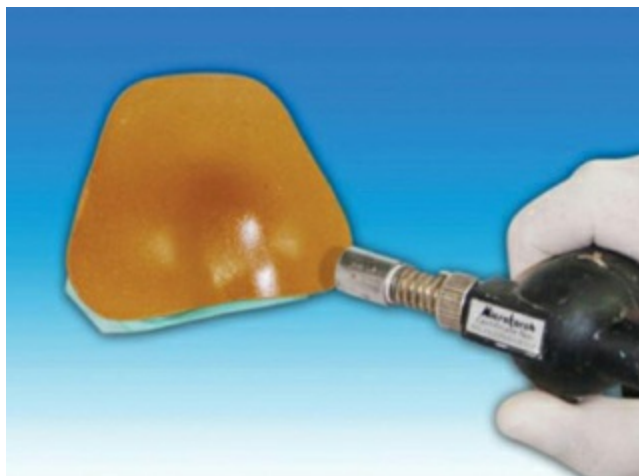


FIG 3.1.2.3 Shellac baseplate softened with torch flame

Pressure is applied with the fingers from the mid-palatal portion of the maxillary cast to the crest of the residual alveolar ridge and to

labial and buccal surfaces of the residual alveolar ridge (Fig 3.1.2.4). This is done to prevent air entrapment between the shellac baseplate wax and tissue surface of the cast.

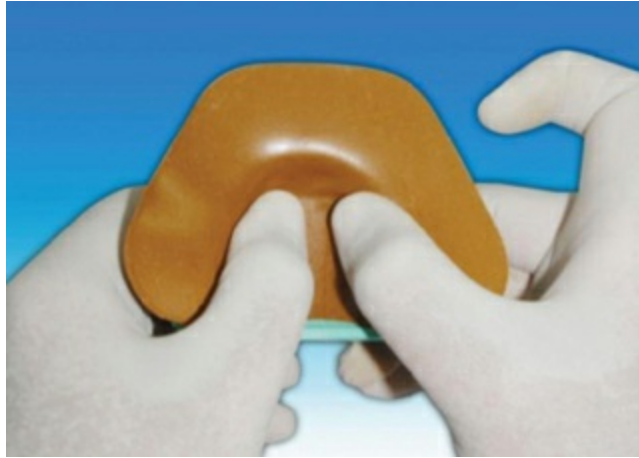

FIG 3.1.2.4 Adaptation of baseplate

An outline is drawn approximately 5 mm beyond the edge of the cast with a marker pen (Fig 3.1.2.5).

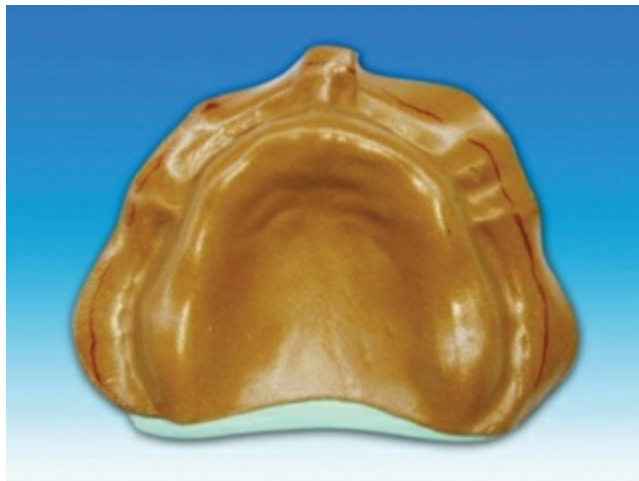

FIG 3.1.2.5 Outline of the record base

The shellac is softened and the excess of the shellac baseplate is cut with a curved scissors along the marked outline (Fig 3.1.2.6).



FIG 3.1.2.6 Excess is cut with the scissors

The trimmed edges are heated using the gas torch. The softened trimmed edges are elevated from the cast and folded back on the shellac baseplate and are burnished with the wax spatula to form a smooth and rounded border. The borders must reproduce both the contours and dimensions of the reflections of the final cast ([Fig 3.1.2.7](#)).

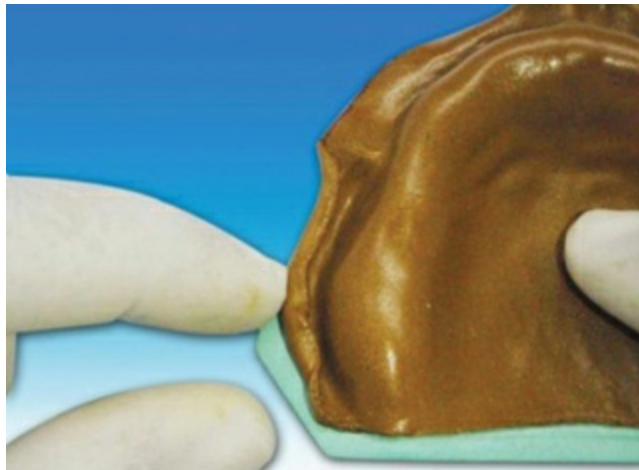


FIG 3.1.2.7 Borders are rolled

The border should be continuous and smooth and should cover the width and the depth of the sulcus ([Fig 3.1.2.8](#)).

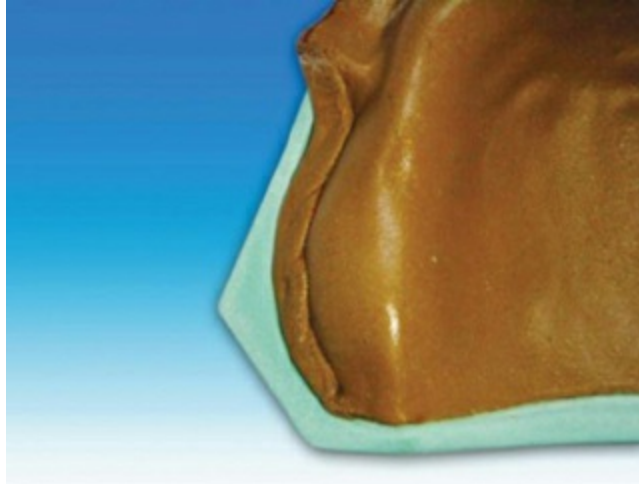

FIG 3.1.2.8 Rolled border covering the width and depth of the sulcus

The borders are folded in labial and buccal aspect except in the posterior palatal seal area (Fig 3.1.2.9).

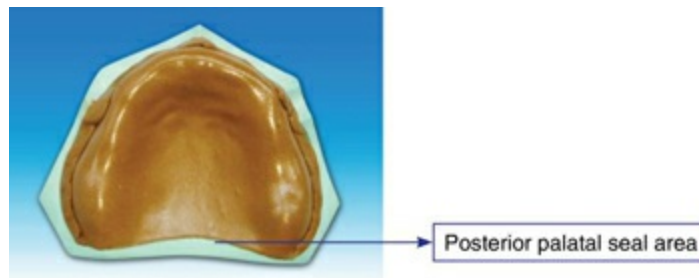


FIG 3.1.2.9 Posterior palatal seal area not rolled

The adapted record base is removed the master cast and examined. The borders should be smooth and rounded (Fig 3.1.2.10). The relief given for the labial frenum and buccal frenum should be adequate.




FIG 3.1.2.10 Tissue surface of the record base with smooth and rounded borders

Irregular and rough areas should be smoothed with a sandpaper (Fig 3.1.2.11).

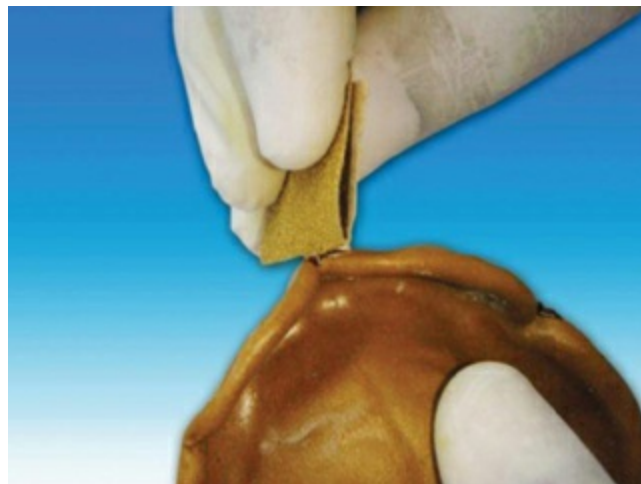


FIG 3.1.2.11 Rough areas smoothed

The tissue surface of the finished shellac record base appears with smooth and rounded borders (Fig 3.1.2.12).



FIG 3.1.2.12 Tissue surface of the finished record base

Adaptation of mandibular record base

The mandibular shellac record base is placed over the mandibular edentulous master cast (Fig 3.1.2.13). Posteriorly, the record base should cover the retromolar pad area of the cast.



FIG 3.1.2.13 Mandibular shellac baseplate on the cast

The flame from a Bunsen burner or a gas torch is moved slowly over the surface of the shellac baseplate till it appears shiny and slumps onto the cast. Firm pressure is applied with wet fingers to the

lingual surface of the mandibular cast (Fig 3.1.2.14). The record base is reheated and adaptation is done over the crest of the ridge and then into the sulcular areas to prevent entrapment of air between the tissue surface of the cast and the shellac record base.

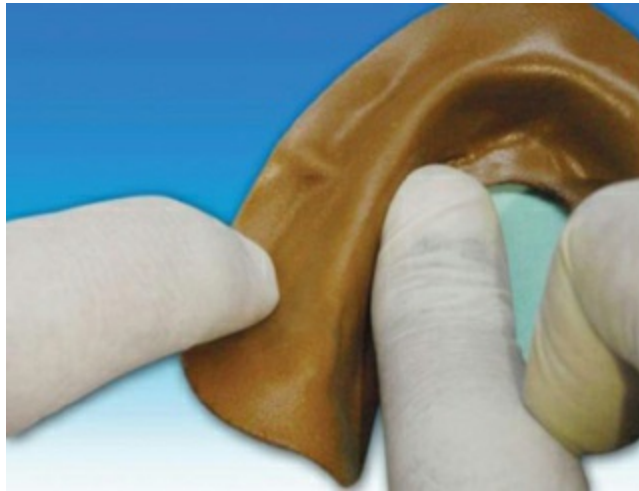

FIG 3.1.2.14 Adaptation of the record base from the lingual side

The shellac is reheated and adapted over the crest of the ridge and into the labial and buccal reflections. The excess in the labial, buccal and lingual and posterior is marked with a marker pen (Fig 3.1.2.15).



FIG 3.1.2.15 Excess is marked

The shellac is softened again and the borders on the lingual, labial and buccal sides are rolled to cover the width and depth of the sulcus ([Fig 3.1.2.16](#)).

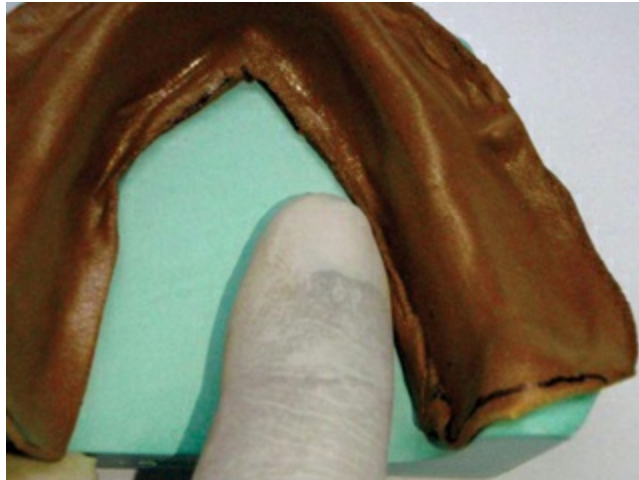


FIG 3.1.2.16 Borders are rolled

The borders of the tissue surface of the record base should be smooth and rounded. The relief for the labial, buccal and lingual frenum should be adequate. The posterior aspect of the retromolar pad area is marked on the record base and the excess is cut with the scissors ([Fig 3.1.2.17](#)).



FIG 3.1.2.17 Excess is marked at the posterior aspect of the record base

The rough surfaces are smoothed with a sandpaper ([Fig 3.1.2.18](#)).

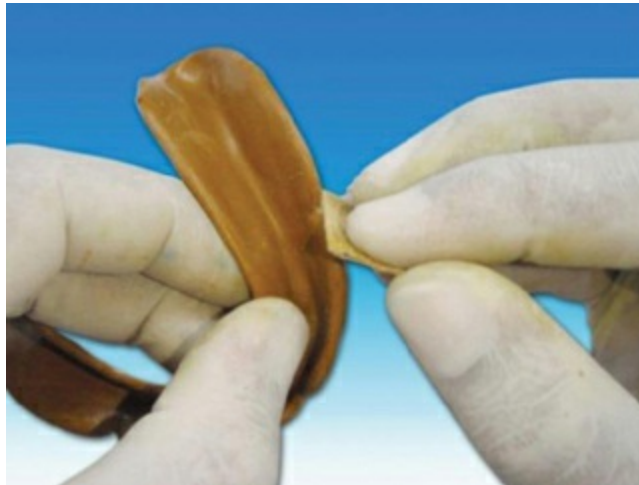

FIG 3.1.2.18 Rough areas are smoothed

The tissue surface of the finished lower shellac record base is smooth and rounded borders with adequate relief in the labial frenum and buccal frenum ([Fig 3.1.2.19](#)).



FIG 3.1.2.19 Tissue surface of the finished record base with smooth and rounded borders

The finished shellac record base on the mandibular master cast is prepared (Fig 3.1.2.20).



FIG 3.1.2.20 Finished shellac record base on the cast

3.1.3. Fabrication of occlusion rims

Armamentarium (Fig 3.1.3.1)

- Maxillary and mandibular cast with the shellac record base
- Modelling wax sheet
- Wax knife
- Wax carver
- Hot plate
- Bunsen burner or gas torch
- Metallic scale
- Marker pen




FIG 3.1.3.1 Armamentarium

Three guidelines on the mandibular edentulous cast are marked (Fig 3.1.3.2). These are:

1. The retromolar pad area is marked and is divided into 3 parts as anterior one-third, middle one-third and posterior one-third. The height of mandibular posterior occlusion rim should be at the level of the junction of anterior two-thirds and posterior one-third.
2. The posterior extent of the mandibular rim should be limited to the anterior aspect of the retromolar pad.

3. The crest of the alveolar ridge is marked and is extended posteriorly and anteriorly which serves as a guideline for fabrication of the occlusion rim. The width of the posterior occlusion rim should be equidistant or equal on either side of the crest of the ridge.

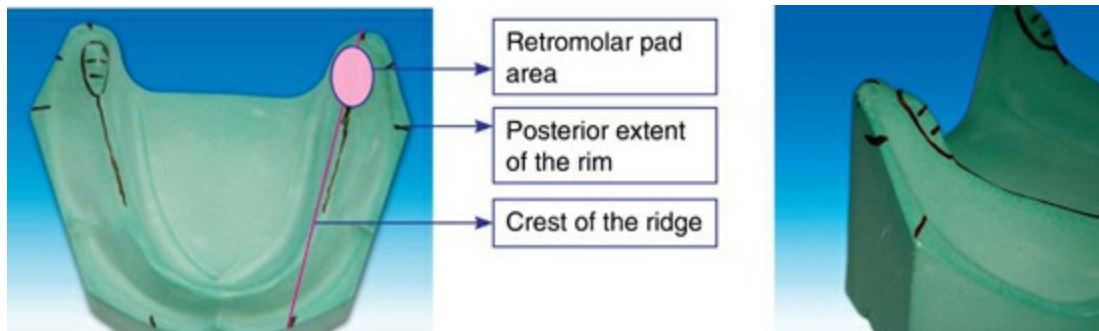


FIG 3.1.3.2 Mandibular cast with guidelines marked

Guidelines are marked on the maxillary cast for fabrication of the occlusion rim ([Fig 3.1.3.3](#)).

1. Mark the maxillary tuberosity of the cast.
2. Mark the anterior border of the tuberosity on the land area of the cast.
3. Mark the incisive papilla.
4. Mark the midline of the cast by connecting midpalatine raphe, incisive papilla and the labial frenum. Extend this line to the land area of the cast.
5. Draw a perpendicular line to the midline through the centre of the incisive papillae and extend it to the land area and this line is called canine-papilla-canine (CPC) line ([Fig 3.1.3.4](#)).

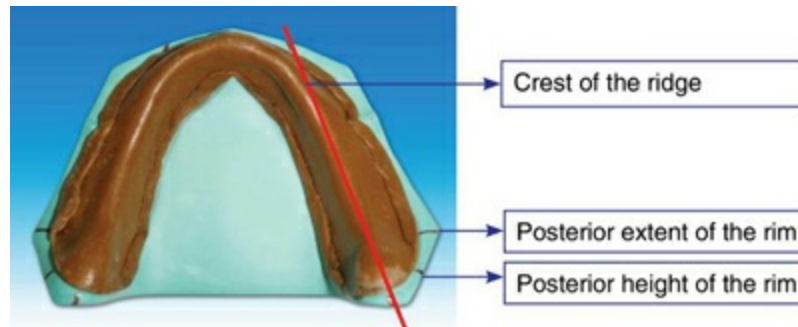


FIG 3.1.3.3 Corresponding guidelines in the land area of the mandibular cast

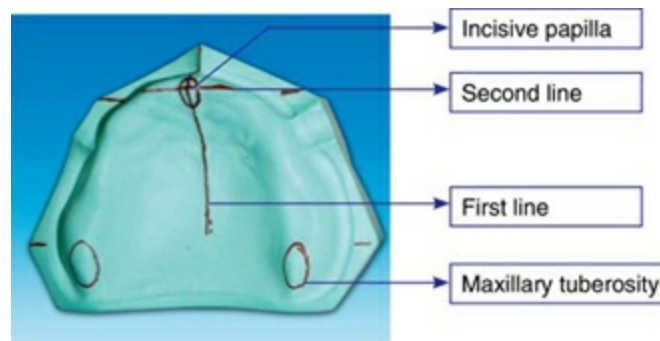


FIG 3.1.3.4 Maxillary cast with guidelines marked

The midline, CPC line and limiting of the posterior extent of maxillary occlusion rim are visible on the land area following placement of adapted shellac baseplate.

1. The posterior extent of the mandibular guideline for occlusion rim is marked on the land area (Fig 3.1.3.5).
2. The guideline for the height of posterior occlusion rim is marked on the land area.
3. Two markings are done: one in the anterior and another one in the posterior aspect in the land area of the cast for depicting the crest of the ridge.

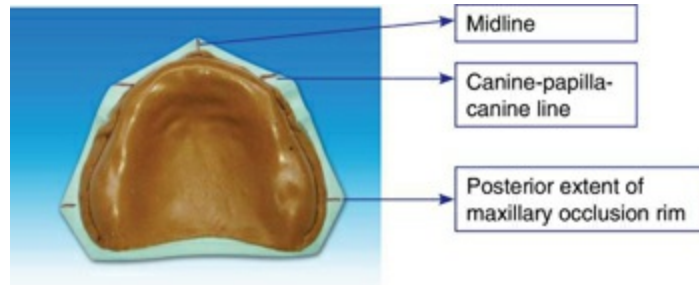


FIG 3.1.3.5 Corresponding guidelines in the land area of the maxillary cast

Fabrication of maxillary occlusal rim

Modelling wax sheet is softened over the Bunsen burner (Fig 3.1.3.6).



FIG 3.1.3.6 Softening of wax

The softened modelling wax sheet is rolled breadth-wise (Fig 3.1.3.7).

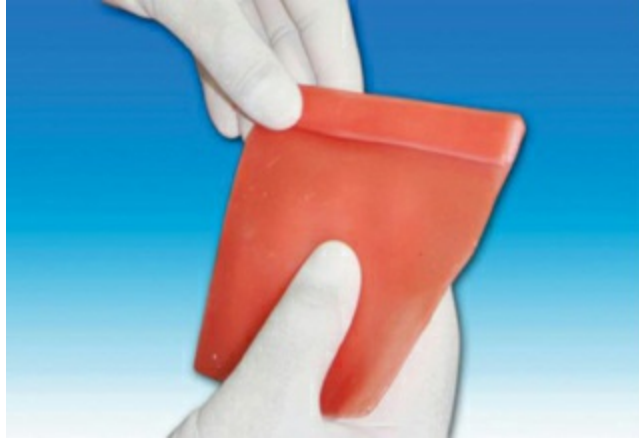

FIG 3.1.3.7 Folding of wax

The softened modelling wax sheet should be rolled uniformly without trapping air between the layers (Fig 3.1.3.8).

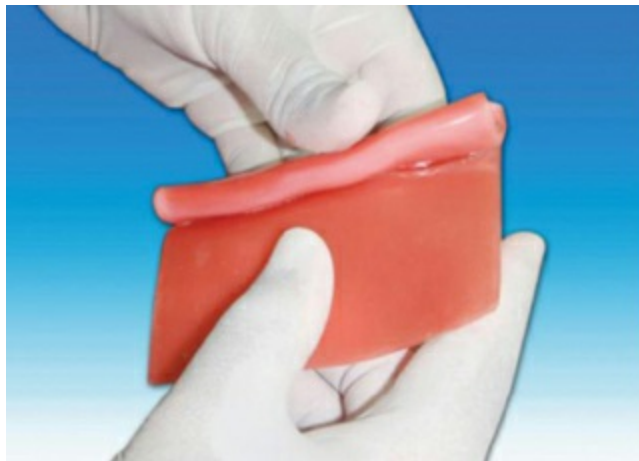

FIG 3.1.3.8 Rolling the wax

The softened rolled wax sheet is cut with a wax carver according to desired length of the rolled wax rim (Fig 3.1.3.9).



FIG 3.1.3.9 Rolled wax is cut

The softened rolled modelling wax is positioned on the maxillary cast from one posterior end along the maxillary archform to the other posterior end of the cast (Fig 3.1.3.10). While adapting the softened wax, care should be taken to accomplish the following.

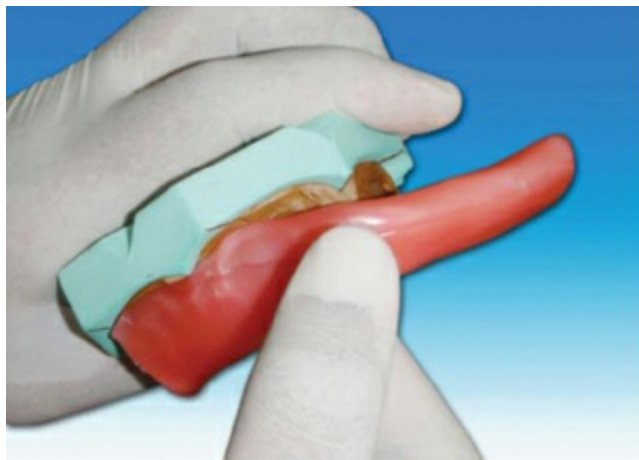


FIG 3.1.3.10 Positioning the wax rim

Adapt from the labial sulcus to create desired height both anteriorly and posteriorly. The occlusion rim should be wider posteriorly compared to anteriorly. This is done by thinning the anterior portion of the occlusion rim.

After positioning the softened rolled wax on the arch, a thrust is given from the palatal aspect of the anterior rim to give a labial

inclination of 15 degrees to the rim and this makes anterior rim thinner (Fig 3.1.3.11).

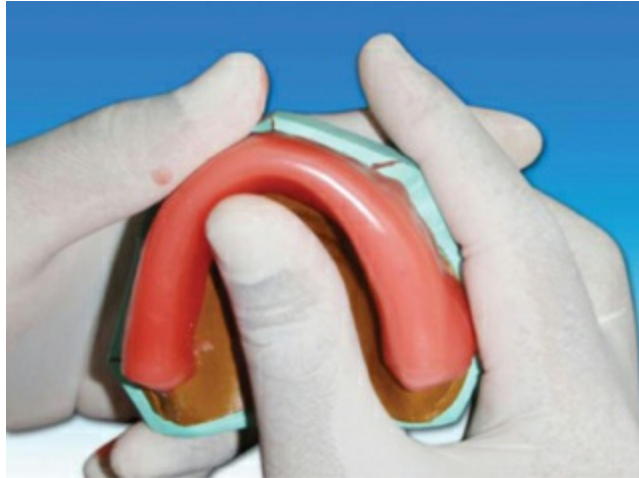

FIG 3.1.3.11 Labial inclination of the rim

The maxillary occlusion rim should replicate the archform of the maxillary edentulous ridge on the cast (Fig 3.1.3.12). The posterior extent of the maxillary occlusion rim should be short of the maxillary tuberosity.

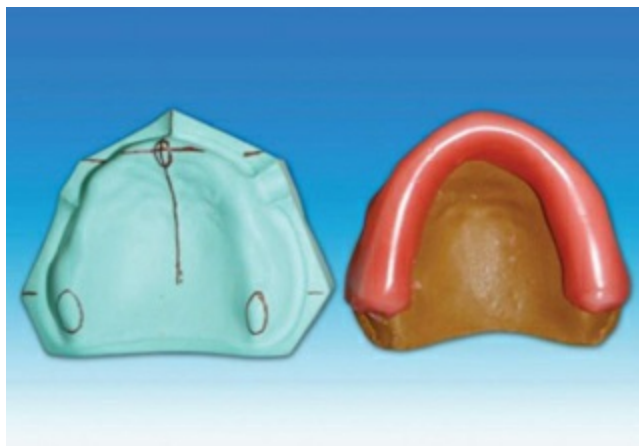

FIG 3.1.3.12 Replication of the archform

The maxillary occlusion rim shows the labial inclination (red line)

and the posterior extent of the wax occlusion rim short of maxillary tuberosity (Fig 3.1.3.13).

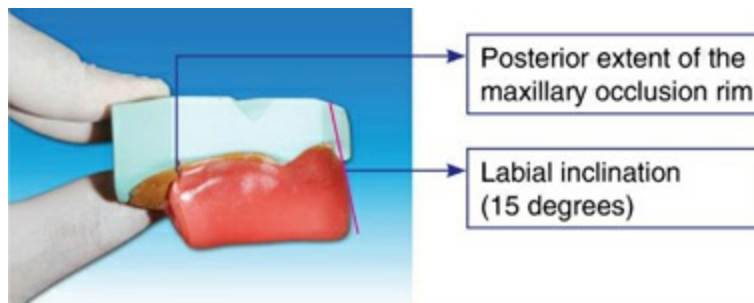


FIG 3.1.3.13 Labial inclination of the rim

The wax knife is heated and the occlusion rim is sealed to the record base on the palatal side of the rim (Fig 3.1.3.14).

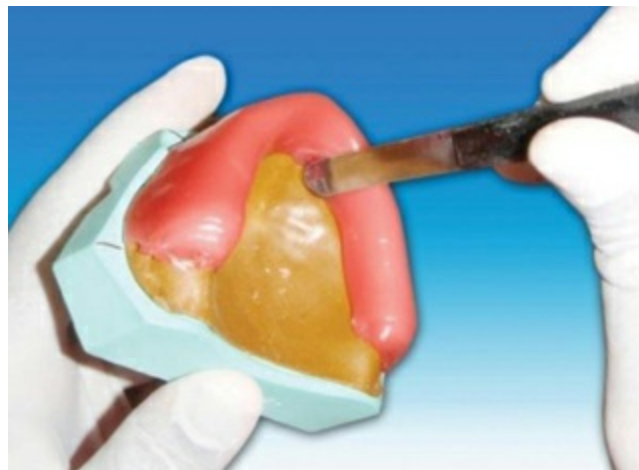

FIG 3.1.3.14 Sealing of wax rim

The labial and buccal surface of the rim is smoothed with a heated wax knife which was adapted earlier (Fig 3.1.3.15).

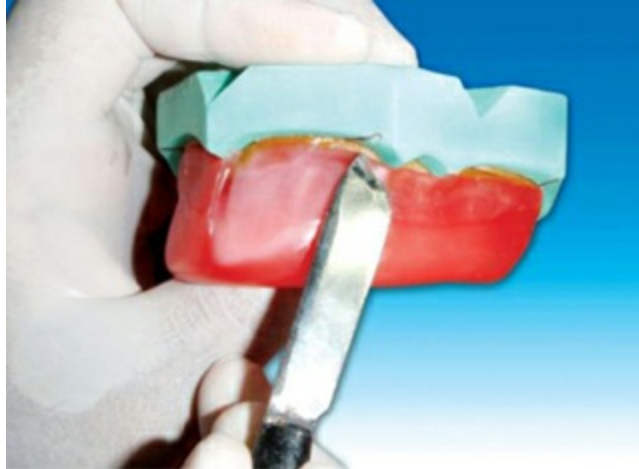

FIG 3.1.3.15 Smoothing the wax rim

The posterior extent of the maxillary occlusion rim is cut with a wax knife to give a slope (Fig 3.1.3.16).

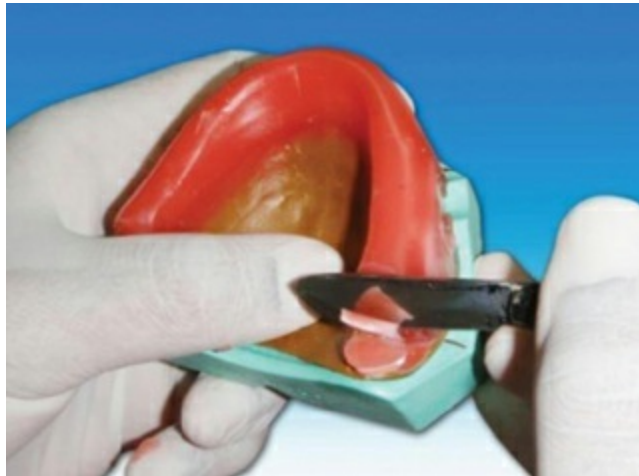


FIG 3.1.3.16 Posterior extent of the rim

The anterior height of the maxillary occlusion rim is measured at the canine region (Fig 3.1.3.17). The anterior height of maxillary occlusion rim should be 20–22 mm. Here the measurement is about 23 mm (which has to be reduced to the desired height).

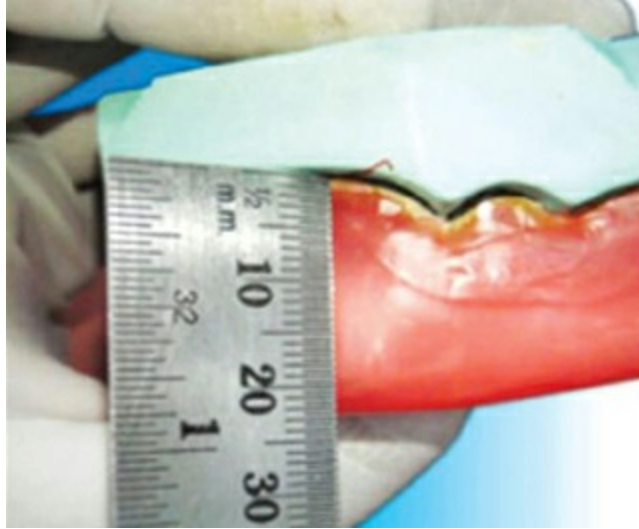

FIG 3.1.3.17 Measuring anterior height of the rim

The posterior height of the maxillary occlusion rim is measured at the molar region (Fig 3.1.3.18). The posterior height should be 16–18 mm in height. Here the measurement is about 19 mm.

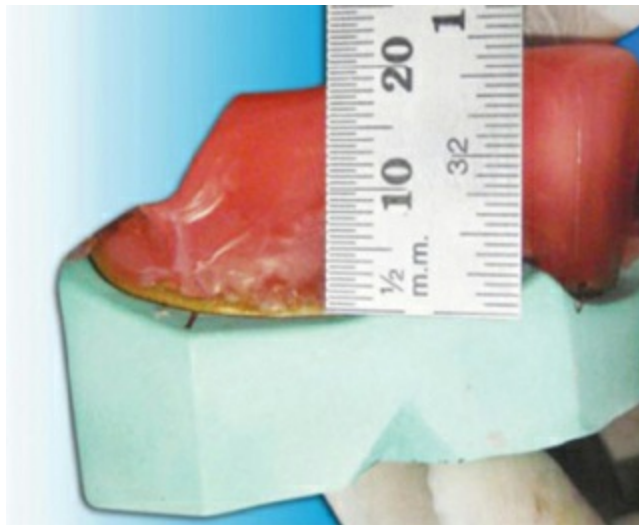

FIG 3.1.3.18 Measuring posterior height of the rim

The height of the maxillary occlusion rim is reduced with a heated hot plate instrument. The reduction should be uniform (Fig 3.1.3.19).

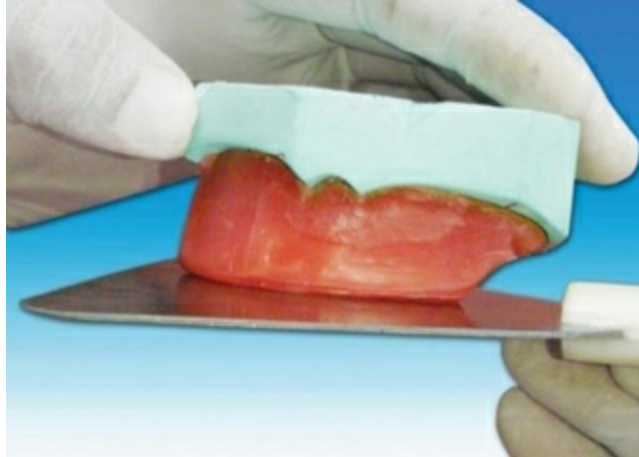

FIG 3.1.3.19 Uniform reduction of rim using hot plate

The corrected anterior occlusion rim height is about 21 mm ([Fig 3.1.3.20](#)).

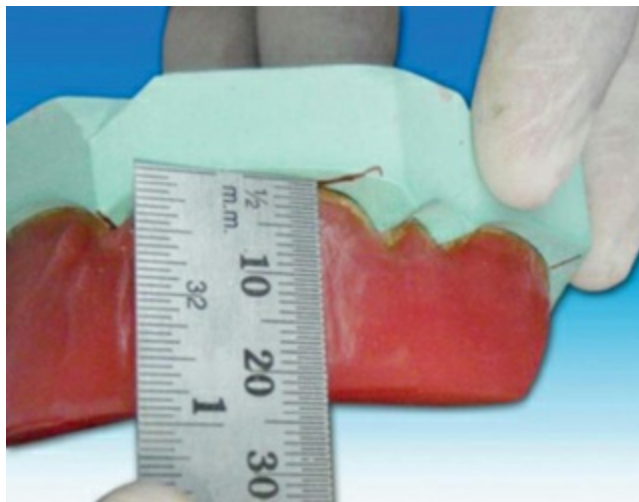

FIG 3.1.3.20 Corrected anterior height of the wax rim

The corrected posterior occlusion rim height is 18 mm ([Fig 3.1.3.21](#)).

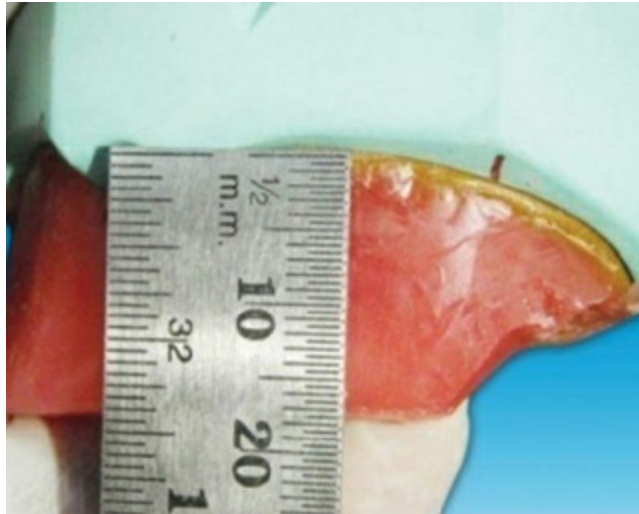


FIG 3.1.3.21 Corrected posterior height of the rim

The maxillary occlusion rim shows the corrected occlusal plane and the labial inclination of anterior occlusion rim ([Fig 3.1.3.22](#)).

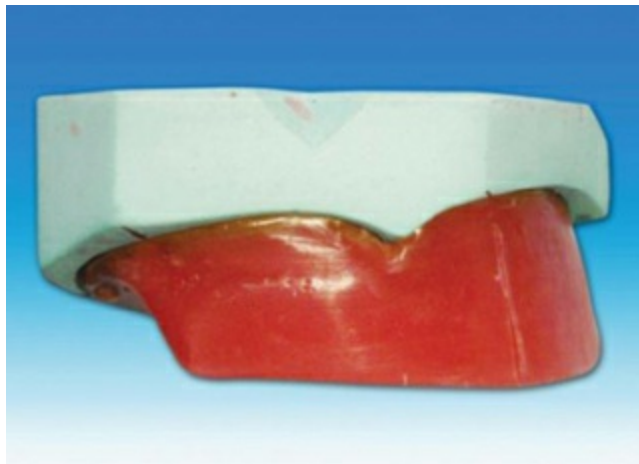


FIG 3.1.3.22 Corrected occlusal plane of the rim

The width of the anterior occlusion rim should be 4–6 mm ([Fig 3.1.3.23](#)).



FIG 3.1.3.23 Width of the maxillary anterior occlusion rim

The width of the posterior occlusion rim should be 6–8 mm ([Fig 3.1.3.24](#)).



FIG 3.1.3.24 Width of the posterior occlusion rim

Fabrication of mandibular occlusal rim

The modelling wax sheet is softened over a Bunsen burner and is rolled uniformly without entrapping air and the desired length is cut with wax carver ([Fig 3.1.3.25](#)).




FIG 3.1.3.25 Softened wax sheet rolled and cut

The required length of the rolled wax rim is cut with a wax carver and is placed on the mandibular cast from one posterior end of the cast (Fig 3.1.3.26). The rim is placed short of the retromolar pad region on both the sides.

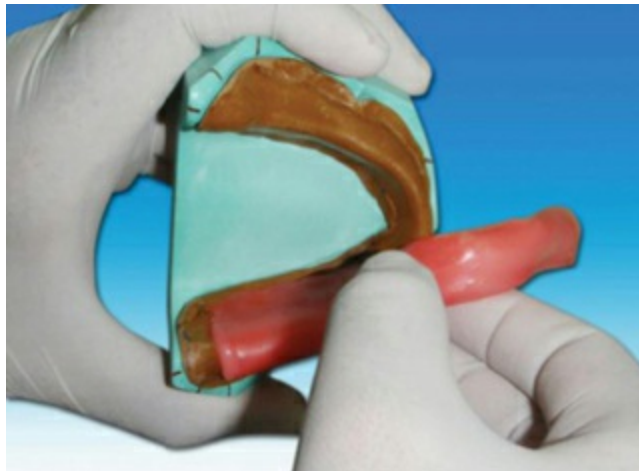


FIG 3.1.3.26 Positioning the wax rim on the cast

The mandibular occlusion rim should follow the archform of the mandibular residual alveolar ridge (Fig 3.1.3.27).

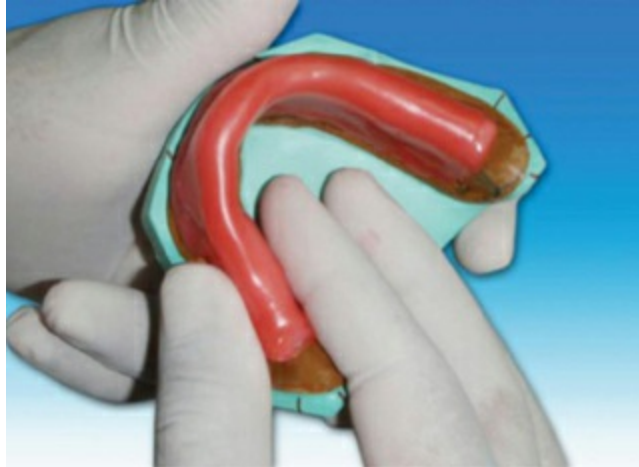

FIG 3.1.3.27 Replication of archform

The softened wax rim is positioned on the lower cast according to the guidelines marked. The posterior extent of the rim is limited to the anterior aspect of retromolar pad. The posterior occlusion rim is positioned equally on the buccal and lingual aspect of the crest of the ridge according to the guideline drawn as shown in the [Figure 3.1.3.28](#).

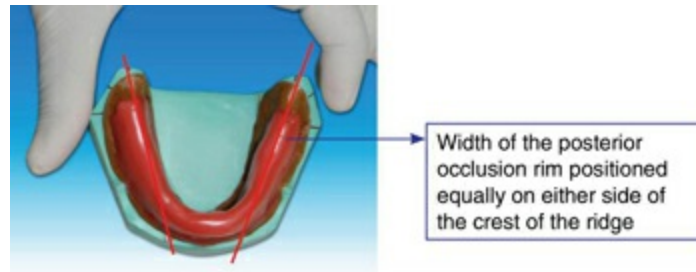


FIG 3.1.3.28 Mandibular occlusion rim in relation to crest of the ridge

The additional wax is added along the lingual side of the wax occlusion rim ([Fig 3.1.3.29](#)).

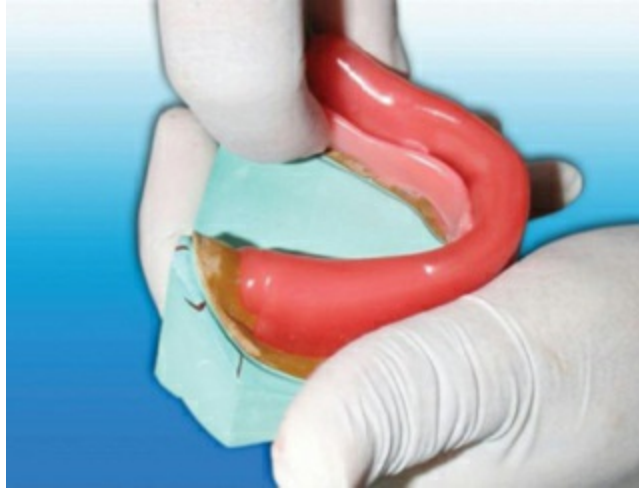

FIG 3.1.3.29 Additional wax on the lingual side

The posterior height of the mandibular rim is at the level of the junction of anterior two-thirds and posterior one-third of the retromolar pad according to the guideline marked as shown in the [Figure 3.1.3.30](#).

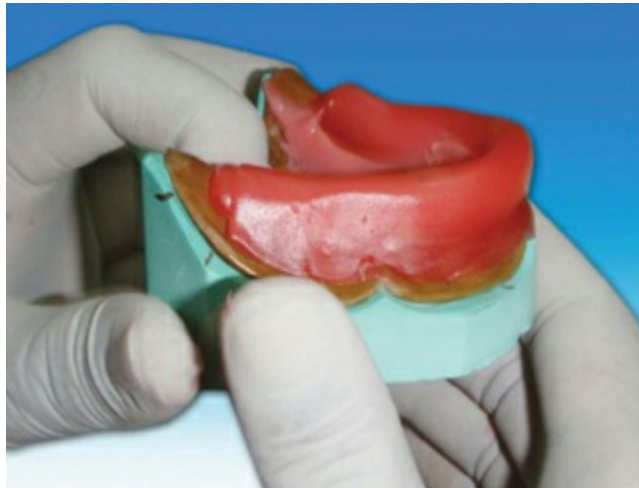

FIG 3.1.3.30 Posterior height of the mandibular rim

The posterior extent of the wax rim is cut at an angle of 45 degrees with a wax carver ([Fig 3.1.3.31](#)).

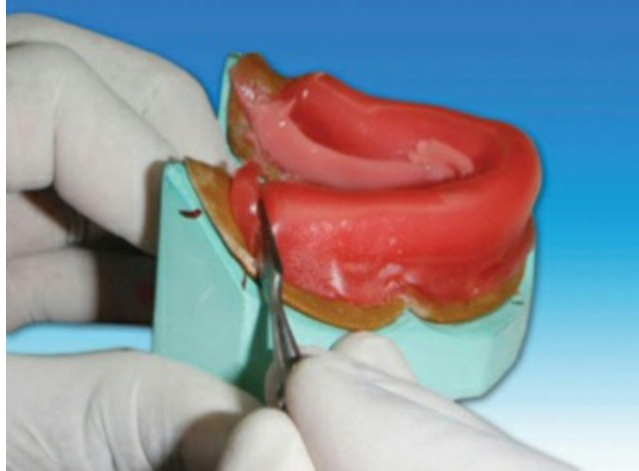

FIG 3.1.3.31 Posterior extent short of retromolar pad

The height of anterior mandibular rim should be 16 mm in the canine region. [Figure 3.1.3.32](#) shows excess height of the occlusion rim which has to be reduced.

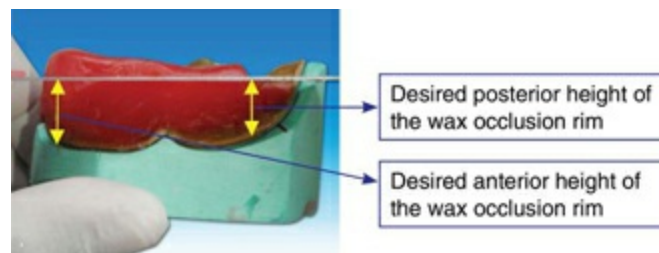


FIG 3.1.3.32 Excess height of the occlusion rim

The excess height of the mandibular occlusion rim is reduced with the heated hot plate. The reduction should be done uniformly both on the left and right sides ([Fig 3.1.3.33](#)).




FIG 3.1.3.33 Reduction of occlusion rim

The anterior height of the mandibular occlusion rim is about 16 mm (Fig 3.1.3.34).




FIG 3.1.3.34 Anterior height of the occlusion rim

The width of the anterior occlusion rim should be 4–6 mm (Fig 3.1.3.35).

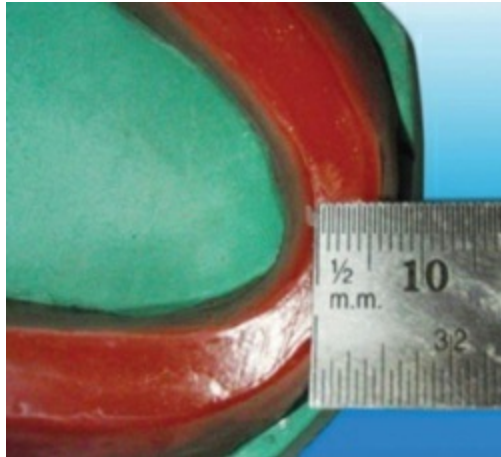


FIG 3.1.3.35 Width of the anterior occlusion rim

The width of the posterior occlusion rim should be 6–8 mm ([Fig 3.1.3.36](#)).



FIG 3.1.3.36 Width of the posterior occlusion rim

When the finished maxillary and mandibular occlusion rims are placed together the maxillary rim should overlap the mandibular rim labially and buccally ([Fig 3.1.3.37](#)). The midline of the cast is transferred to the maxillary and mandibular occlusion rims.



FIG 3.1.3.37 Finished maxillary and mandibular occlusion rims

3.1.4. Mounting of the casts in the articulator

Armamentarium (Fig 3.1.4.1)

- Maxillary occlusion rim with the cast
- Mandibular occlusion rim with the cast
- Mean value articulator
- Dental plaster
- Rubber bowl
- Mixing spatula
- Wax knife
- Wax carver
- Modelling clay
- Long thread
- Vaseline
- Brush



FIG 3.1.4.1 Armamentarium

The upper and the lower casts with the finished occlusal rims are sealed together. Two small strips of wax are luted to the upper and

lower bases of the casts as shown in [Figure 3.1.4.2](#). This is done for the easy removal of the casts from the articulator for processing the waxed denture.



FIG 3.1.4.2 Upper and lower casts with rims on the base of the casts

The plane of the articulator is formed by central pin anteriorly and reference rod posteriorly. Our objective of articulation is to make the plane of the occlusion rim coincide with the plane of the articulator. The sealed upper and lower cast with occlusion rim are positioned in the articulator with the help of modelling clay ([Fig 3.1.4.3](#)). The central pin should point the midline of the upper and lower occlusion rims.




FIG 3.1.4.3 Mean value articulator showing the reference plane

A thread is used to check whether the anterior and posterior planes of occlusion are oriented to the plane of the articulator. The anterior plane should be at the level of the central pin and the posterior plane should be in line with the posterior reference rod as shown in [Figure 3.1.4.4](#).




FIG 3.1.4.4 Thread used for verifying the position of the occlusion rims in the articulator

A thin coat of separating medium, like Vaseline or Petroleum jelly is applied in the "V"-shaped notches in the upper cast with the help of a

brush (Fig 3.1.4.5).

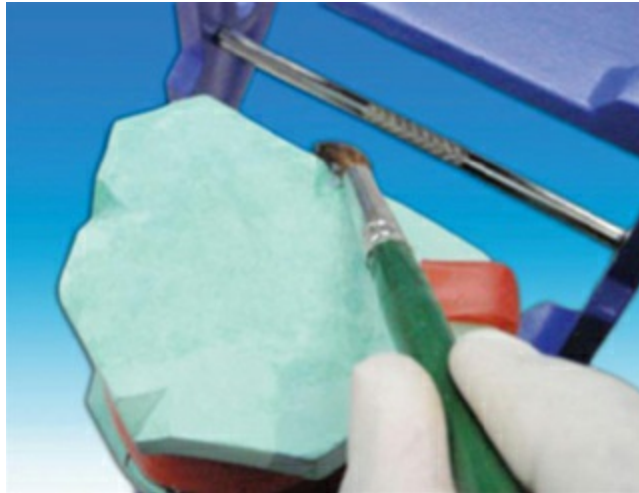

FIG 3.1.4.5 Application of separating medium

Dental plaster is mixed in appropriate proportion with the rubber bowl and mixing spatula. A portion of the mixed plaster is poured on the base of the upper cast. The mixed plaster is first made to flow into the "V"-shaped notch with the help of a wax knife (Fig 3.1.4.6).

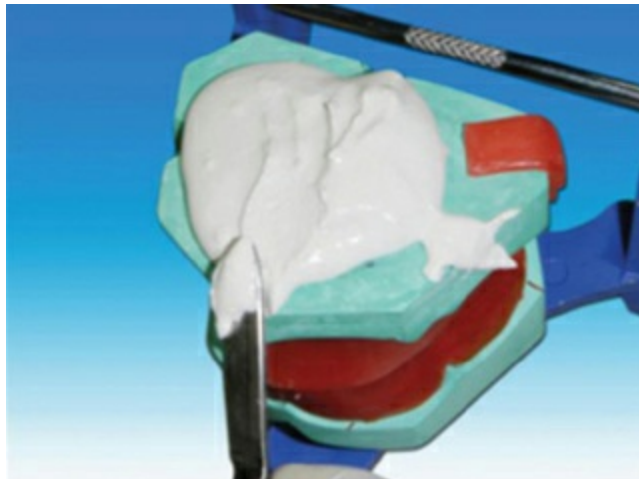

FIG 3.1.4.6 Mixed dental plaster applied on the V-shaped notches

V-shaped notches or the grooves should be filled first as shown in Figure 3.1.4.7.



FIG 3.1.4.7 V-shaped notches filled with the dental plaster

The remaining mixed dental plaster is poured on the base of the upper cast and the upper member of the articulator is closed. The plaster should flow into the spaces provided in the upper mounting plate (Fig 3.1.4.8).



FIG 3.1.4.8 Upper cast is mounted

The mixed plaster should be contoured according to the sides of the cast with the wax knife (Fig 3.1.4.9).

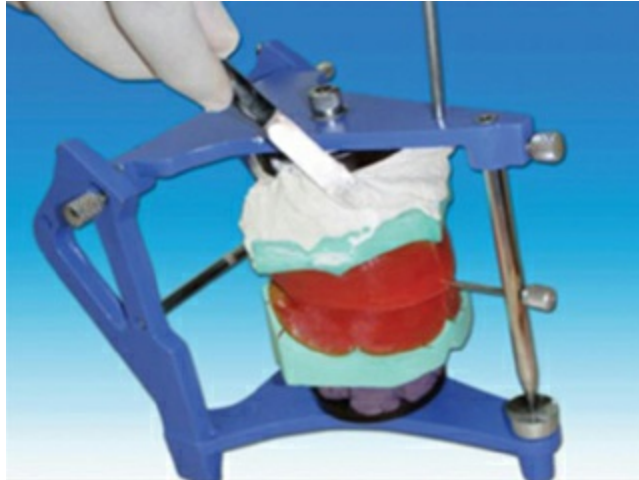


FIG 3.1.4.9 Wax knife is used to contour the mounting plaster

The mounting plaster of the upper cast shows clearly the pattern of the "V"-shaped notches (Fig 3.1.4.10).




FIG 3.1.4.10 V-shaped notches in the mounting plaster

When upper mounting is done, the articulator is inverted for mounting the lower cast (Fig 3.1.4.11).




FIG 3.1.4.11 Articulator is inverted for mounting the lower cast

Application of thin layer of separating medium, like Vaseline is done on the base of the cast and the V-shaped notches (Fig 3.1.4.12).



FIG 3.1.4.12 Separating medium is applied on the base of the lower cast

Dental plaster is mixed and is placed into the "V"-shaped notches with the wax knife (Fig 3.1.4.13).



FIG 3.1.4.13 Mixed dental plaster is placed on the V-shaped notches

The remaining mixed dental plaster is poured on the base of the cast (Fig 3.1.4.14).

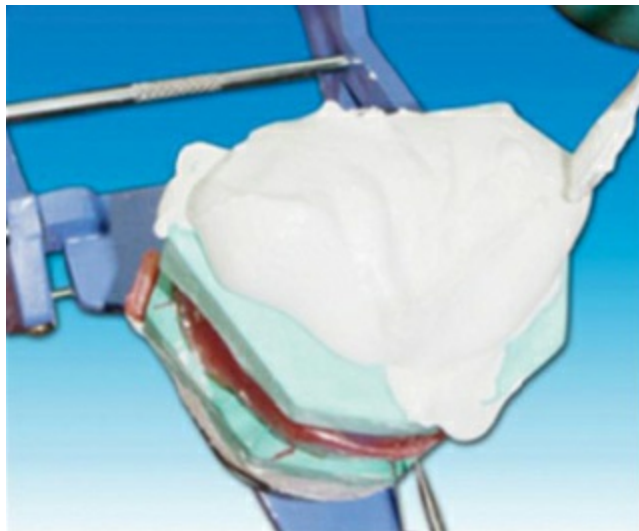

FIG 3.1.4.14 Mixed dental plaster on the base of the lower cast

The mixed dental plaster is applied on to the mounting plates (Fig 3.1.4.15).



FIG 3.1.4.15 Mixed dental plaster on the mounting plate

The lower member of the articulator is closed and the articulator is inverted again ([Fig 3.1.4.16](#)).




FIG 3.1.4.16 Lower cast mounted in the articulator

The upper and lower casts are mounted in the articulator ([Fig 3.1.4.17](#)). The posterior occlusal plane is in line with the posterior reference rod. The central pin is pointing the midline of the casts and the anterior plane of occlusion.




FIG 3.1.4.17 Upper and lower casts mounted in the articulator

3.1.5. Teeth setting

Armamentarium (Fig 3.1.5.1)

- Maxillary occlusal rim with cast
- Mandibular occlusal rim with cast
- Mean value articulator
- Teeth shade
- Measurement scale
- Wax knife
- Roach carver
- Wax spatula
- Wax sheet
- Gas torch
- Cotton
- Rubber bowl with cold water
- Marking pencil



FIG 3.1.5.1 Armamentarium

Guidelines for anterior teeth setting are marked on the cast and the

land area of the cast.

- I. The centre of the incisive papilla (marked in red)
- II. A line is drawn along the midline of the cast through the centre of the incisive papilla (marked in black).
- III. A perpendicular line is drawn to the above line through the centre of incisive papilla till the land area (marked in blue). [Canine-papillary-canine line]
- IV. During setting of maxillary canine, the cuspid tip of the canine should be placed in line with this point (Fig 3.1.5.2).

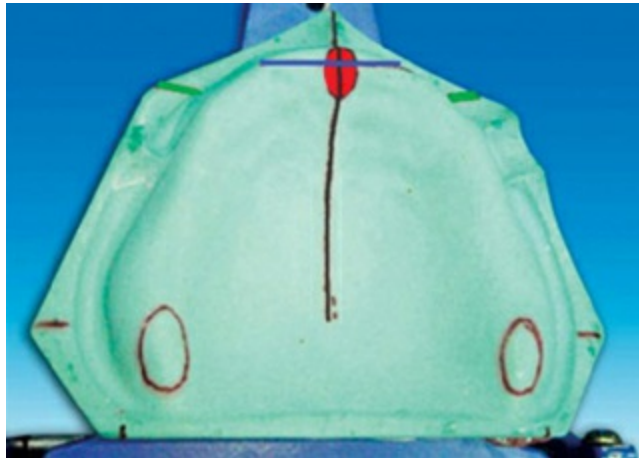

FIG 3.1.5.2 Guidelines marked on the upper cast

The crest of the lower residual alveolar ridge is marked in red colour along the posterior aspect of the lower cast. A corresponding line is marked on the upper cast in blue (Fig 3.1.5.3).




FIG 3.1.5.3 Guidelines marked on the upper and lower casts

Setting of maxillary anterior teeth

Steps in placement of maxillary central incisor

Step 1:

Measure the maxillary central incisor in width and length

Step 2:

Transfer the measurements into the occlusal rim

Step 3:

Scoop out the wax

Step 4:

Placement of the maxillary central incisor in relation to all three planes

Measure the mesiodistal width and cervicoincisal height of the maxillary central incisor tooth with a scale ([Fig 3.1.5.4](#)).

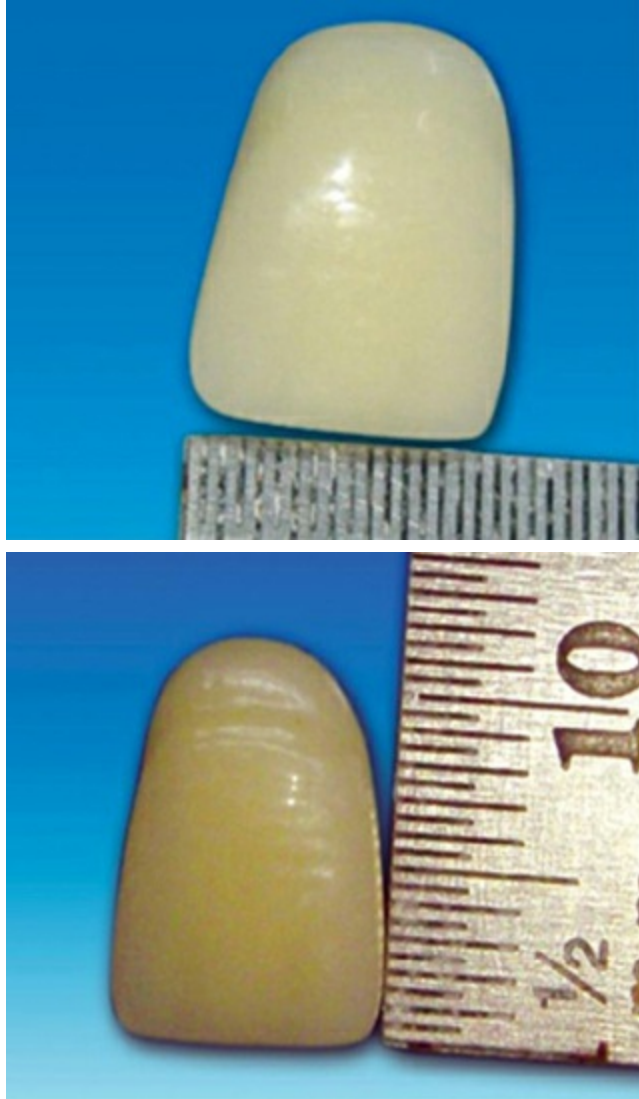


FIG 3.1.5.4A, B Measure the maxillary central incisor in width and length

The mesiodistal width and the cervicoincisal height of the maxillary central incisor are marked on the upper occlusal rim with the scale as shown in [Figure 3.1.5.5a](#) and an outline is marked on the occlusal rim with a heated wax carver as shown in [Figure 3.1.5.5b](#).

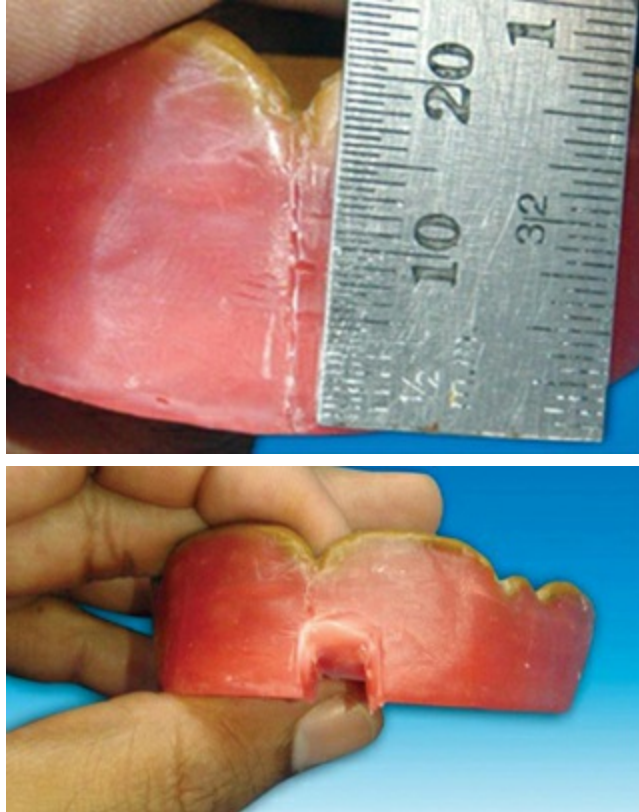
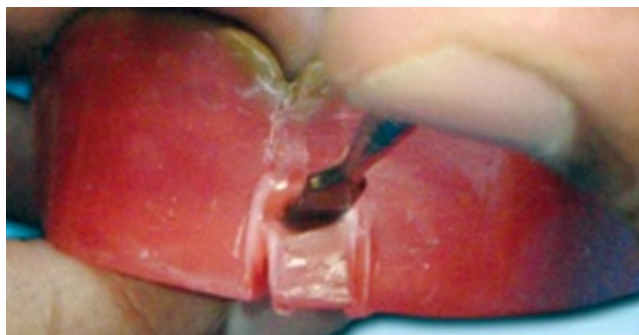


FIG 3.1.5.5A, B Transfer the measurements into the occlusal rim

The required amount [slightly more of marked outline] of softened wax is removed/scooped out with heated wax carver (Fig 3.1.5.6a, b). The cervical portion of the cut portion is softened with a heated wax knife. Over heated instrument will remove excess wax in the area of tooth placement. Under heated instrument will not soften the wax adequately for proper placement of the tooth.



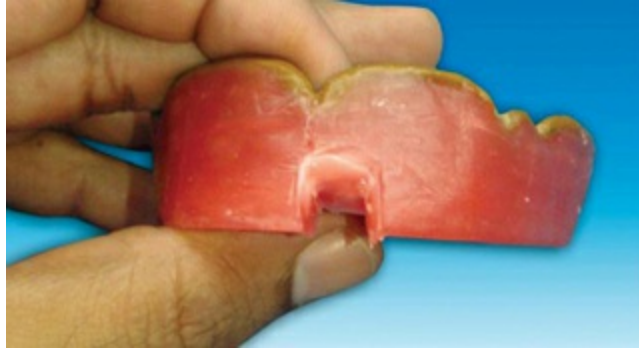


FIG 3.1.5.6A, B Scooping out the outlined wax

The long axis of the central incisor (the blue line) is positioned parallel to the vertical axis (the red line) when viewed from the front as shown in [Figure 3.1.5.7](#).

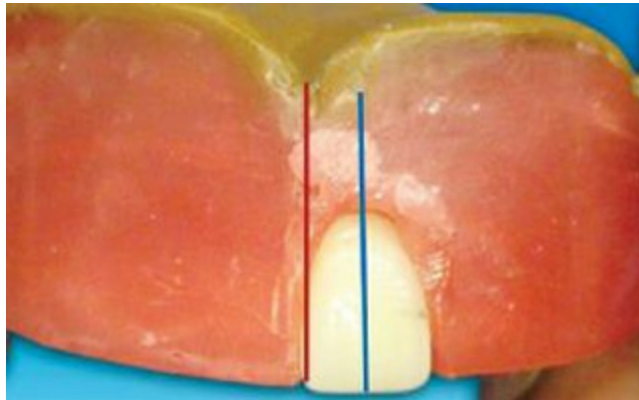


FIG 3.1.5.7 Position of maxillary central incisor in relation to vertical axis—front view

The incisal edge of the maxillary central incisor is positioned in line with the anterior occlusal plane ([Fig 3.1.5.8](#)). The central pin of the articulator will point the mesioincisal line edge of the central incisor.

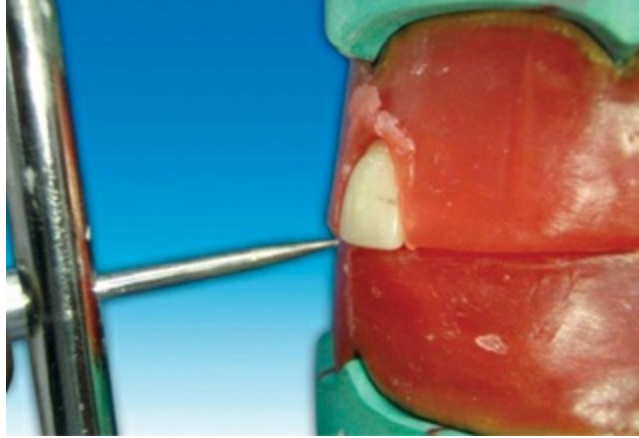


FIG 3.1.5.8 Position of maxillary central incisor in relation to occlusal plane

The outline of the incisal edge of the maxillary central incisor should follow the outline of the maxillary occlusion rim when viewed occlusally. The position adjustments should be carried out when wax is soft ([Fig 3.1.5.9](#)).

When viewed from:

Front: Long axis parallel towards the vertical axis.

Side: Slopes labially about 15°

Occlusal plane: Incisal edge is in contact with occlusal plane ([Fig 3.1.5.10](#)).

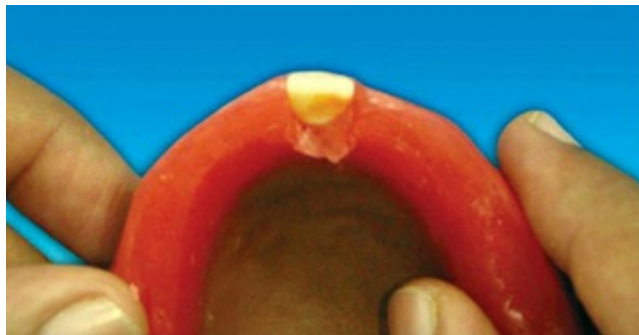

FIG 3.1.5.9 Placement of maxillary central incisor in relation to outline of occlusion rim

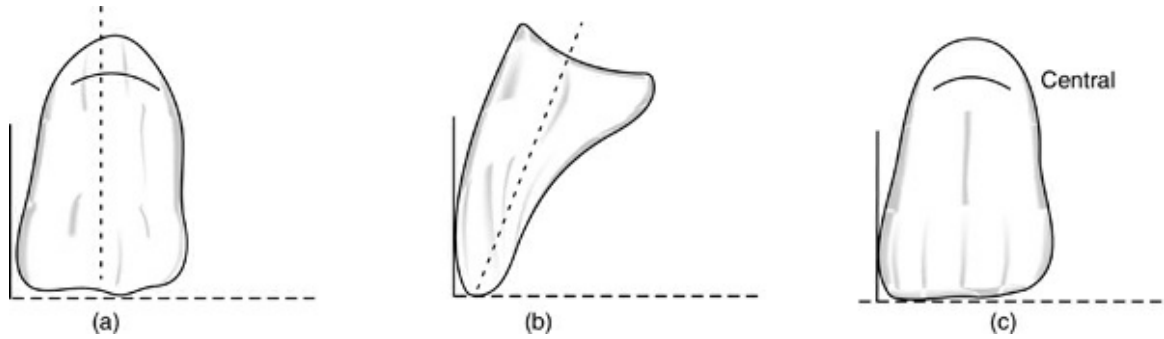


FIG 3.1.5.10 Illustration of maxillary central incisor in all three planes

Steps in placement of maxillary lateral incisor

Step 1:

Measure the dimension of the teeth.

Step 2:

Mark the desired outline.

Step 3:

Scoop out the wax ([Fig 3.1.5.11](#)).

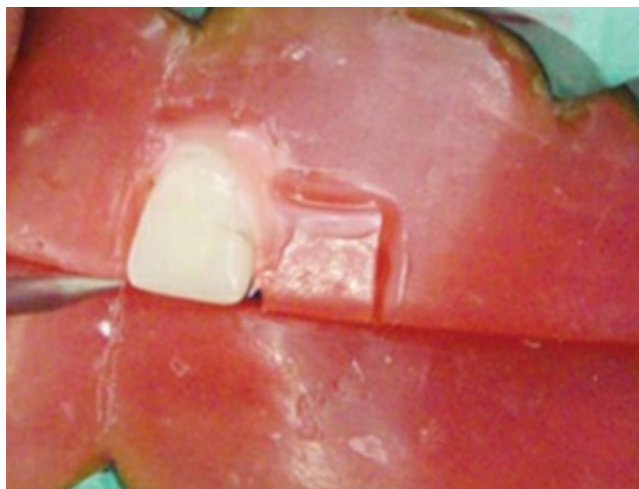


FIG 3.1.5.11 Scoop out the wax

Step 4:

Placement of the maxillary lateral incisor in relation to all three planes.

The cervicoincisal height and the mesiodistal width of the lateral incisor is measured and the outline is marked on the maxillary occlusal rim. The required amount of softened wax is removed/scooped out with the heated wax carver from the occlusal rim.

The long axis of the lateral incisor (green line) is placed slightly inclined to the vertical axis (red line). The incisal aspect of the tooth is inclined towards the vertical axis when viewed from the front (Fig 3.1.5.12).

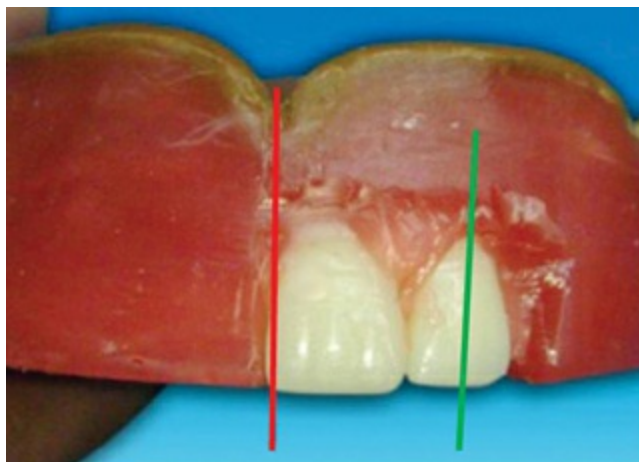


FIG 3.1.5.12 Maxillary lateral incisor in relation to vertical axis—front view

The incisal edge of the maxillary lateral incisor is placed slightly short of the occlusal plane (marked as yellow line). The incisal edge of the maxillary central incisor is placed in line with the occlusal plane (yellow line) (Fig 3.1.5.13).

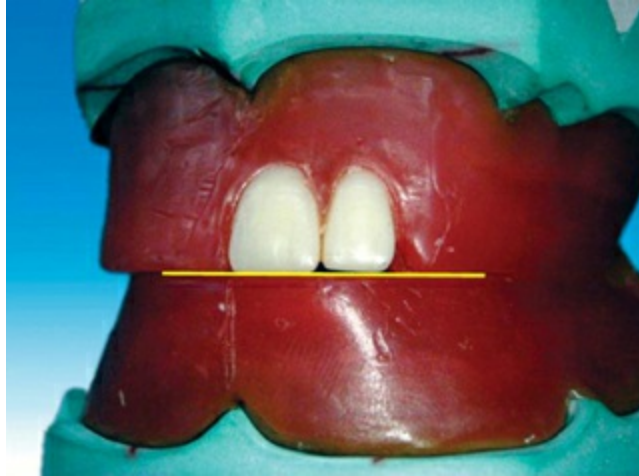


FIG 3.1.5.13 Maxillary lateral incisor in relation to occlusal plane

The incisal edge of the maxillary lateral incisor should follow the outline of the occlusal rim when viewed occlusally ([Fig 3.1.5.14](#)).

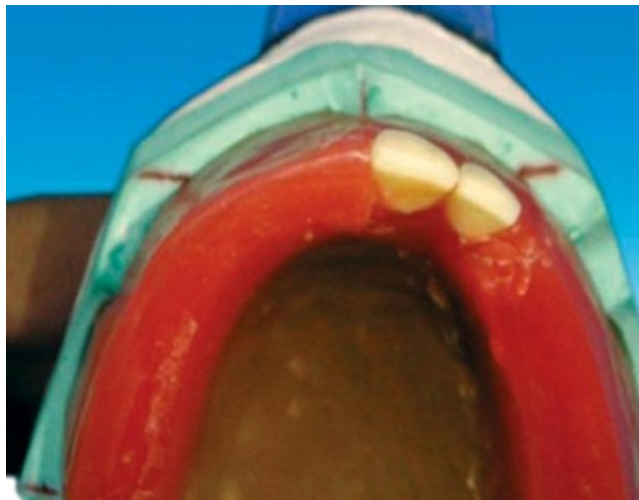


FIG 3.1.5.14 Placement of maxillary lateral incisor in relation to the outline of occlusion rim

When viewed from:
Front: Long axis slopes towards midline at incisal edge.
Side: Slopes labially about 20° .
Occlusal plane: Incisal edge is 1 mm short of occlusal plane ([Fig 3.1.5.15](#)).

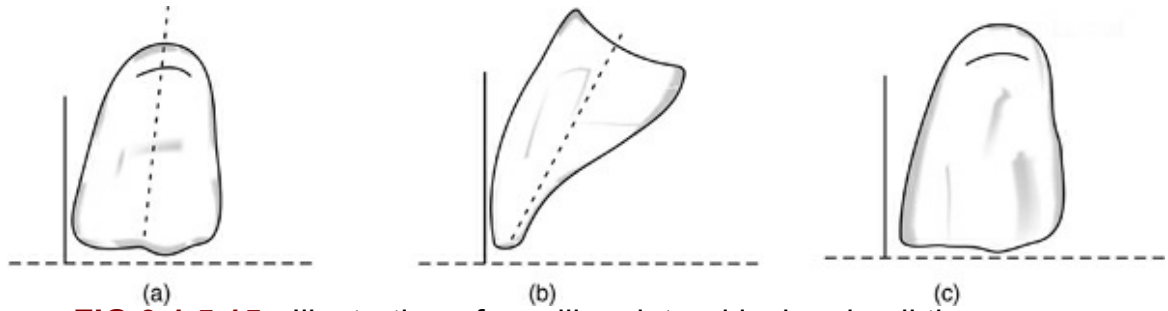


FIG 3.1.5.15 Illustration of maxillary lateral incisor in all three planes

Steps in placement of maxillary canine

Step 1:

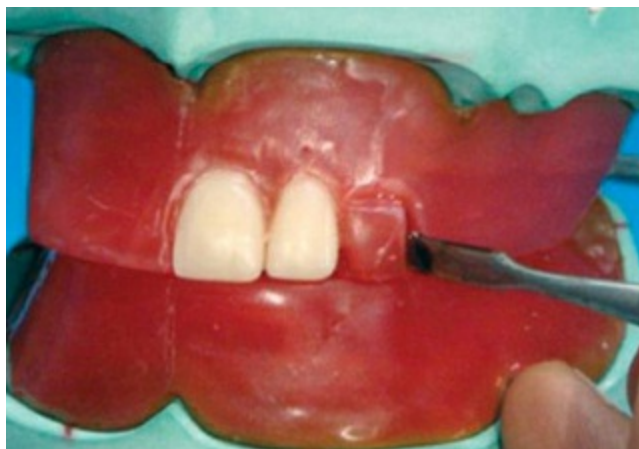Measure the dimension of the tooth.

Step 2:

Mark the desired outline on the occlusal rim.

Step 3:

Scoop out the wax ([Fig 3.1.5.16](#)).



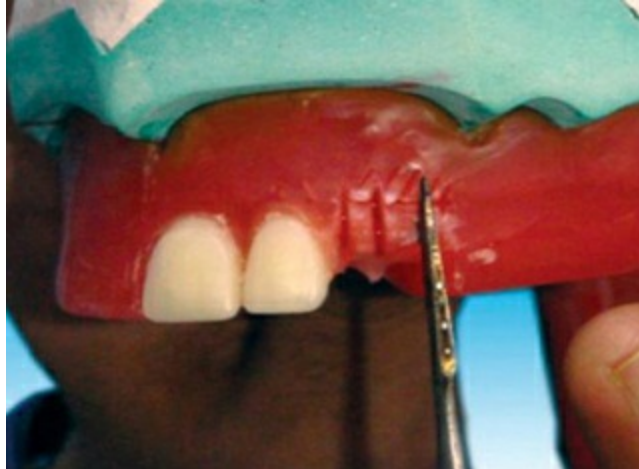

FIG 3.1.5.16A, B Scoop out the wax

Step 4:

Placement of the maxillary canine.

The outline of the maxillary canine is marked on the maxillary occlusal rim with a heated wax carver and the required amount of the wax is scooped out.

The long axis of the maxillary canine (yellow line) should be parallel to the vertical axis (red line) when viewed from the front. The cervical part of the maxillary canine is placed more prominent when compared to the incisal aspect when viewed from the front ([Fig 3.1.5.17](#)).

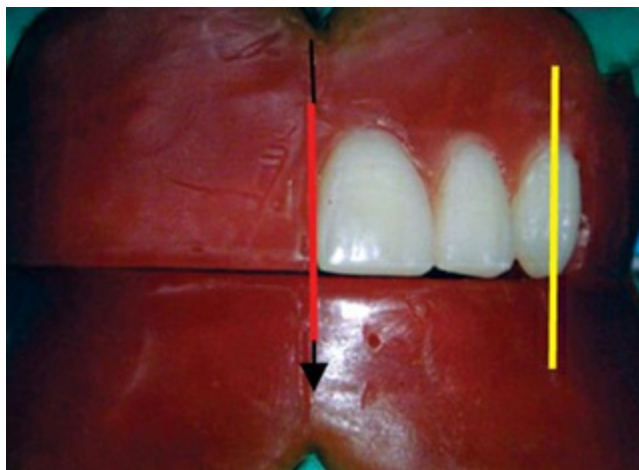


FIG 3.1.5.17 Positioning maxillary canine in relation to vertical axis—front view

The long axis of the maxillary canine (yellow line) should be parallel to the vertical axis (red line) when viewed from the side (Fig 3.1.5.18).

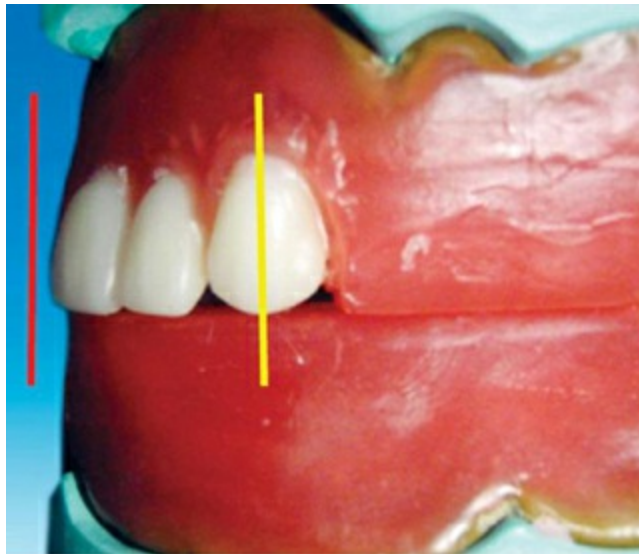


FIG 3.1.5.18 Positioning of maxillary canine in relation to vertical axis—side view

The cuspid tip of maxillary canine is placed in contact with the occlusal plane—yellow line (Fig 3.1.5.19).

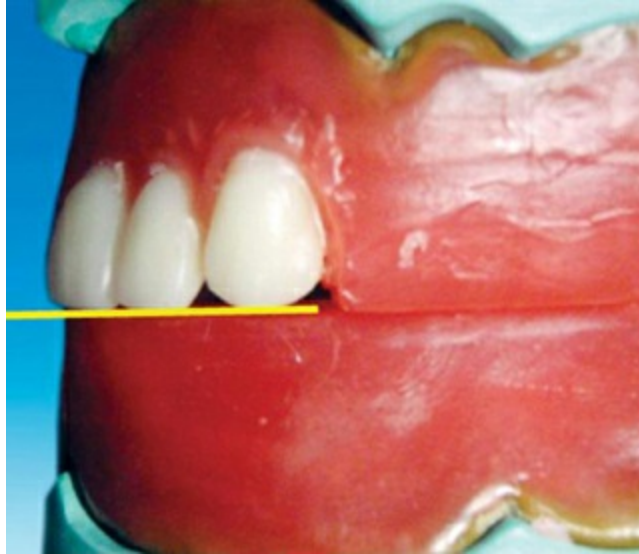

FIG 3.1.5.19 Positioning of cuspid tip in relation to occlusal plane

Maxillary canine follows the outline of occlusal rim and the tip of the canine corresponds to the canine papillary line ([Fig 3.1.5.20](#)).

When viewed from:

Front: Long axis parallel towards the vertical axis.

Side: Long axis parallel towards the vertical axis.

Occlusal plane: Cuspid tip is in contact with occlusal plane ([Fig 3.1.5.21](#)).

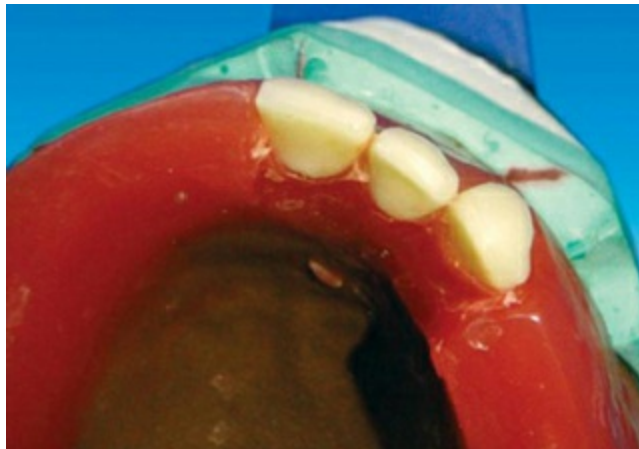


FIG 3.1.5.20 Placement of the maxillary canine in relation to occlusal rim

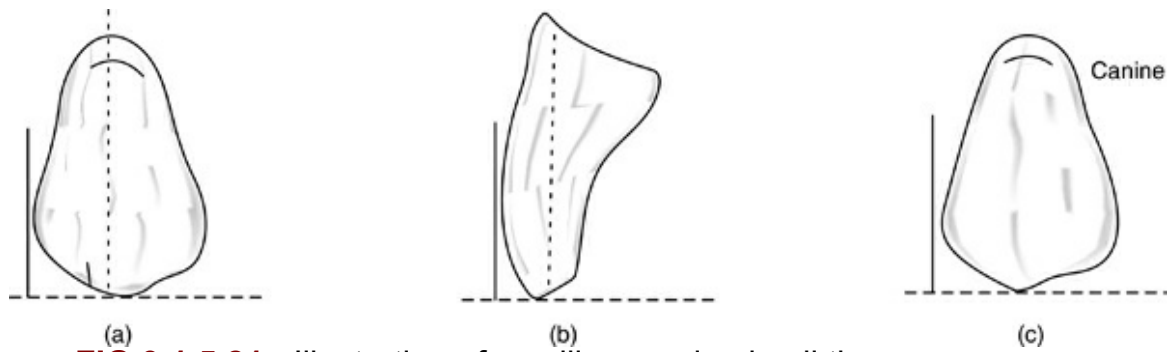


FIG 3.1.5.21 Illustration of maxillary canine in all three planes

Completed setting of maxillary anterior teeth—front view (Fig 3.1.5.22)

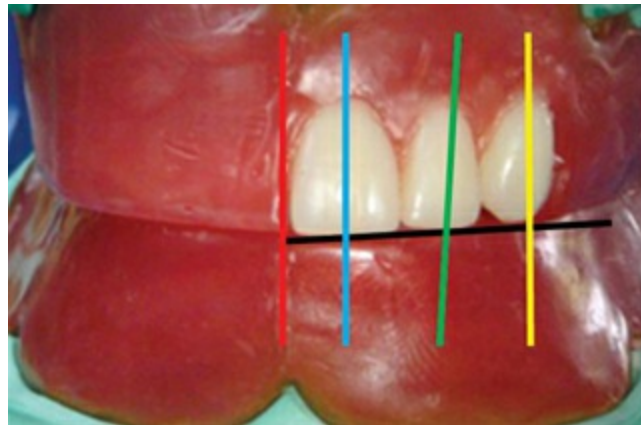


FIG 3.1.5.22 Completed maxillary anterior teeth—front view

Completed setting of maxillary anterior teeth—side view (Fig 3.1.5.23)

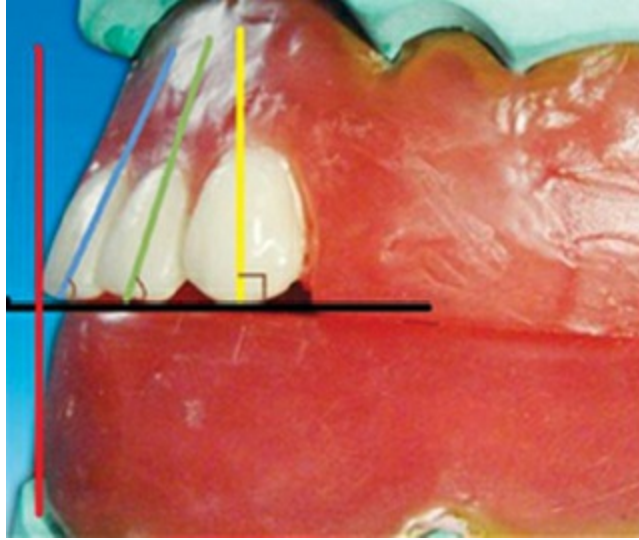


FIG 3.1.5.23 Completed setting of maxillary anterior teeth
-side view

Setting of mandibular anterior teeth

Steps in placement of mandibular central incisor

Step 1:

Measure the tooth dimension.

Step 2:

Mark the desired outline.

Step 3:

Scoop out the wax.

Step 4:

Placement of the mandibular central incisor.

The long axis of the tooth (blue line) is placed parallel to the vertical axis (red line). The incisal edge of the teeth is placed 0.5 mm above the occlusal plane (black line) when viewed from the front ([Fig 3.1.5.24](#)).

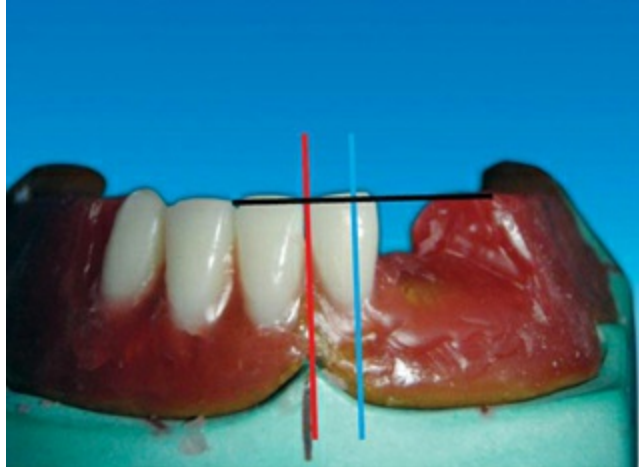


FIG 3.1.5.24 Placement of mandibular central incisor—front view

The incisal edge of the mandibular lateral incisor is placed slightly labially when viewed from the side ([Fig 3.1.5.25](#)).



FIG 3.1.5.25 Placement of mandibular central incisor—side view

The incisal edge of the mandibular central incisor should follow the outline of the occlusal rim, and the incisal edge of the mandibular central incisor tooth should not cross over the land area when viewed occlusally ([Fig 3.1.5.26](#)).

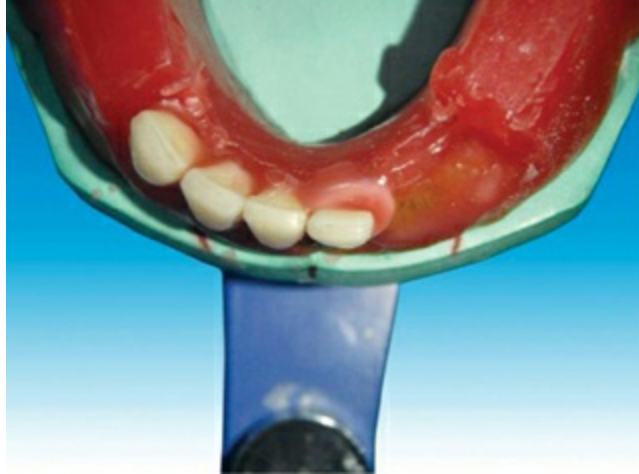

FIG 3.1.5.26 Placement of the mandibular central incisor—
occlusal view

When viewed from:

Front: Long axis inclines slightly towards the vertical axis.

Side: Slopes labially.

Occlusal plane: Incisal edge is 0.5–1 mm above the occlusal plane
([Fig 3.1.5.27](#)).

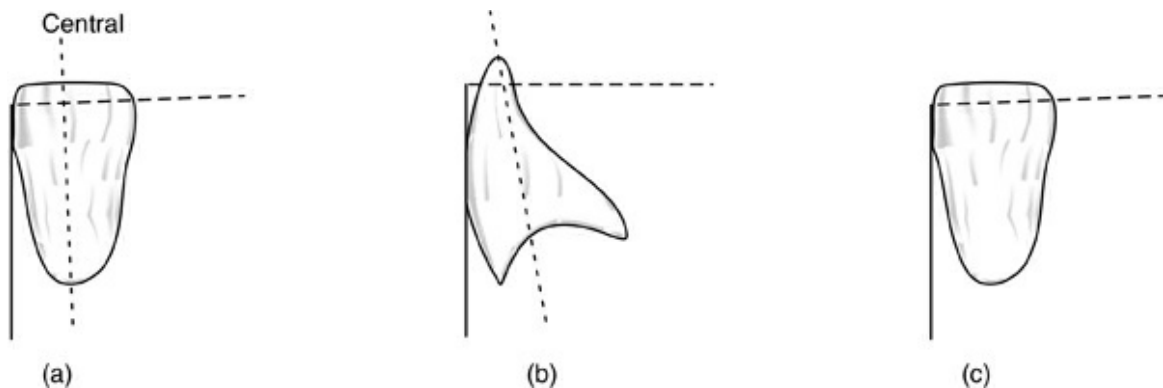


FIG 3.1.5.27 Illustration of mandibular central incisor in all
three planes

Steps in placement of mandibular lateral incisor

Step 1: Measure the dimension of the mandibular lateral incisor.

Step 2 : Mark the desired outline with the heated wax carver.

Step 3: Scoop out the wax.

Step 4: Placement of the mandibular lateral incisor.

The long axis of the mandibular lateral incisor (green line) is placed parallel to the vertical axis (red line) and the incisal edge is placed 0.5 –1 mm above the occlusal plane when viewed from the front (Fig 3.1.5.28).

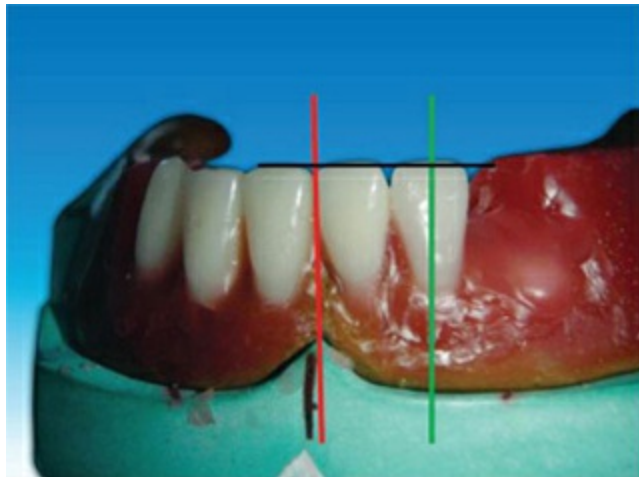


FIG 3.1.5.28 Placement of mandibular lateral incisor—front view

The incisal edge of the mandibular lateral incisor tooth is placed straight when viewed from the side (Fig 3.1.5.29).



FIG 3.1.5.29 Placement of mandibular lateral incisor—side view

The incisal edge of the mandibular lateral incisor should follow the outline of the occlusion rim and the incisal edge should not cross over the land area of the cast when viewed occlusally (Fig 3.1.5.30).

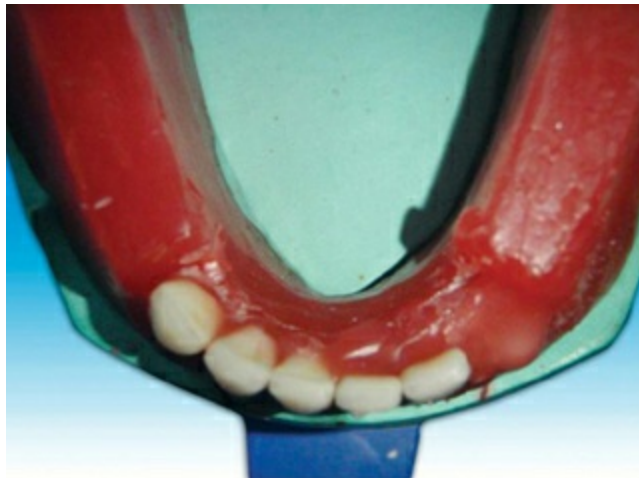

FIG 3.1.5.30 Placement of mandibular lateral incisor tooth—occlusal view

When viewed from:
Front: Long axis inclines towards the vertical axis.
Side: Slopes labially less than central incisor.
Occlusal plane: Incisal edge is 0.5–1 mm above the occlusal plane

(Fig 3.1.5.31).

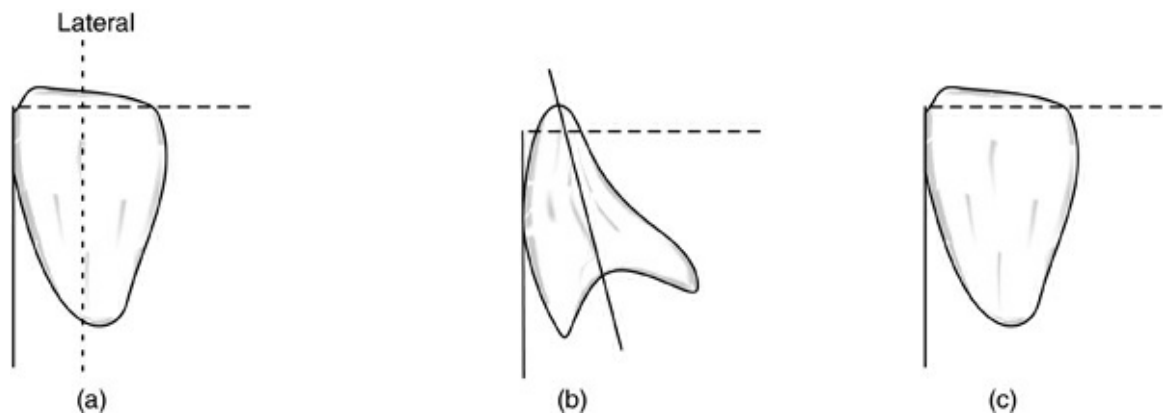


FIG 3.1.5.31 Illustration of mandibular lateral incisor in all three planes

Steps in placement of mandibular canine

Step 1: Measure the dimension of the tooth.

Step 2: Mark the desired outline of the tooth on the occlusal rim.

Step 3: Scoop out the wax.

Step 4: Placement of the mandibular canine.

The cuspid tip of the mandibular canine is placed 0.5–1 mm over the occlusal plane and long axis of the mandibular canine is inclined mesially when viewed from the front (Fig 3.1.5.32).

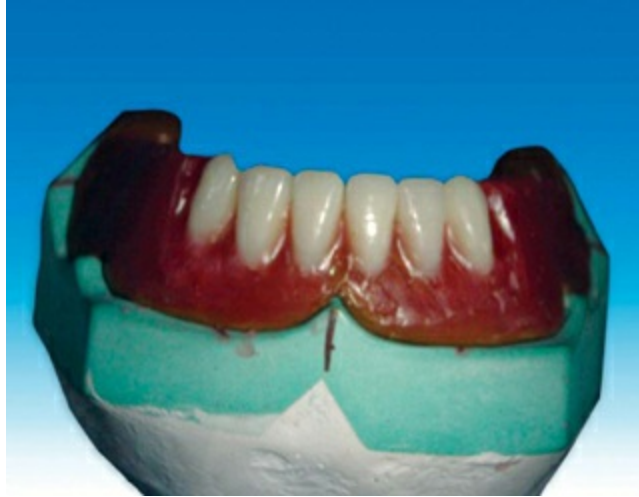

FIG 3.1.5.32 Placement of mandibular canine—front view

The cuspid tip of the mandibular canine slopes slightly lingually when viewed from the side ([Fig 3.1.5.33](#)).

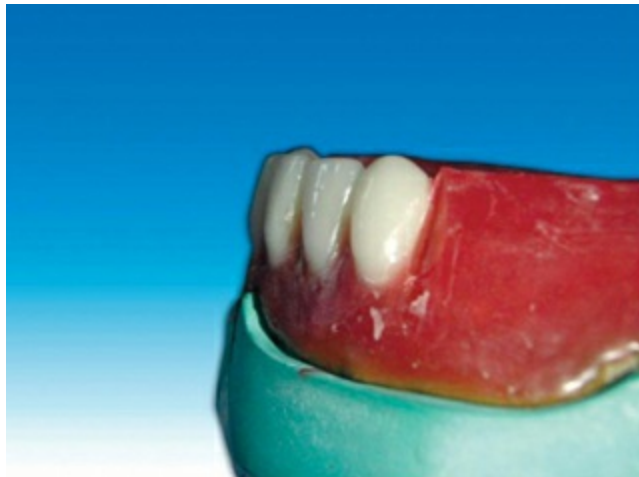

FIG 3.1.5.33 Placement of mandibular canine—side view

The cuspid tip of the mandibular canine should follow the outline of occlusal rim and the cuspid tip should not crossover the land area when viewed occlusally ([Fig 3.1.5.34](#)).

When viewed from:

Front: Long axis inclined towards midline.

Side: Slopes lingually.

Occlusal plane: Cuspid tip is 0.5–1 mm above the occlusal plane

(Fig 3.1.5.35).

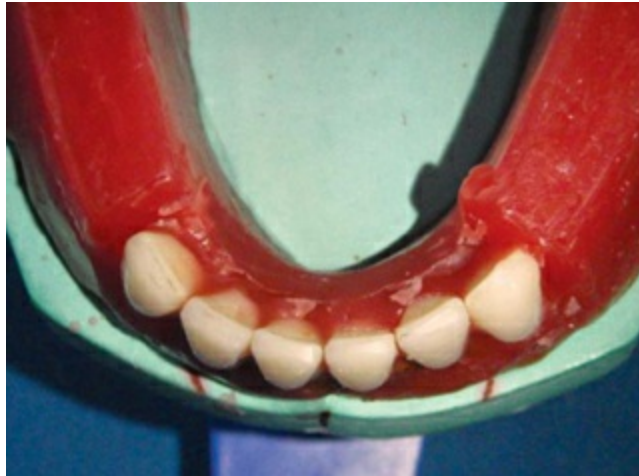

FIG 3.1.5.34 Placement of mandibular canine—occlusal view

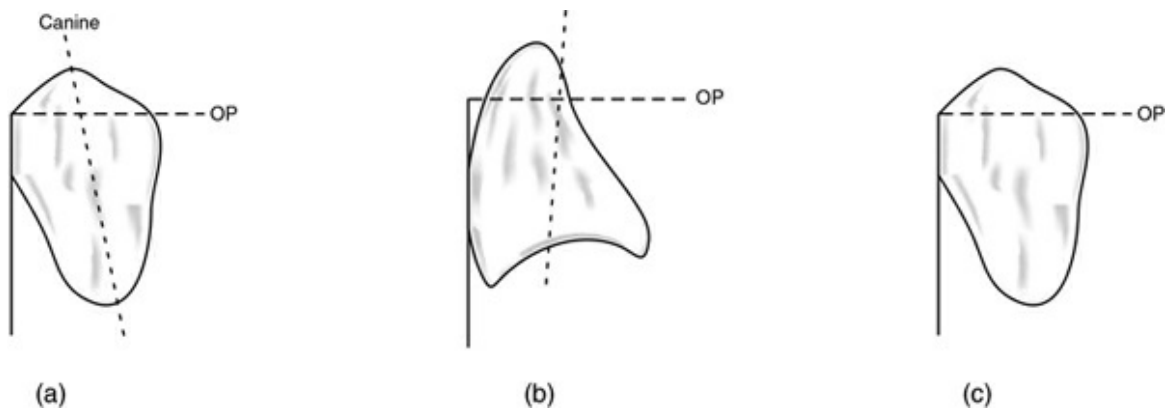


FIG 3.1.5.35 Illustration of mandibular canine in all three planes

Completed setting of maxillary and mandibular anterior teeth

Complete the other side by following the same principles of teeth setting.

The vertical overlap (over bite) between the maxillary and mandibular incisal edge should be 0.5–1 mm and the horizontal overlap (over jet) between the maxillary and mandibular incisal edges should be 1–2 mm. The horizontal overlap should be uniform from left maxillary to right maxillary canine (Fig 3.1.5.36).

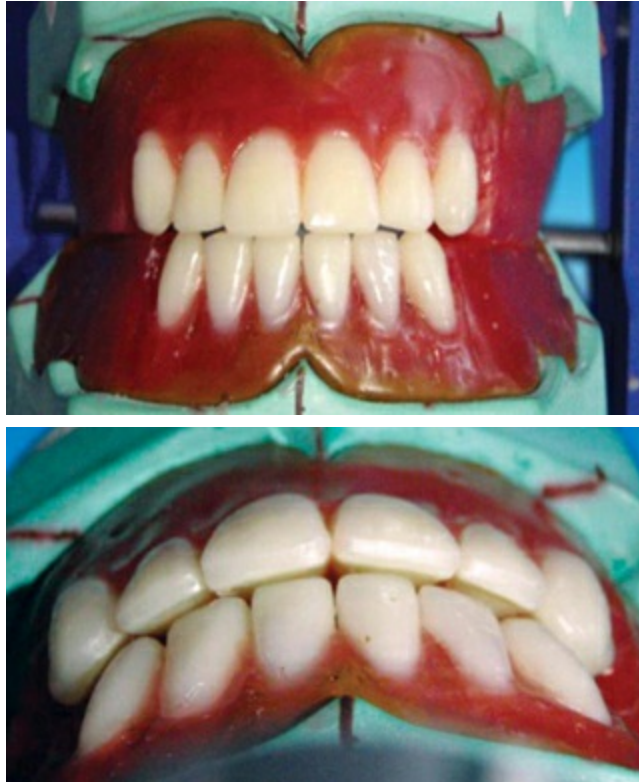

FIG 3.1.5.36A, B Anterior vertical overlap is 0.5–1 mm; and horizontal overlap is 1–2 mm

The mesial slope of the maxillary canine should overlap the distal slope of the mandibular canine as shown in Figure 3.1.5.37.

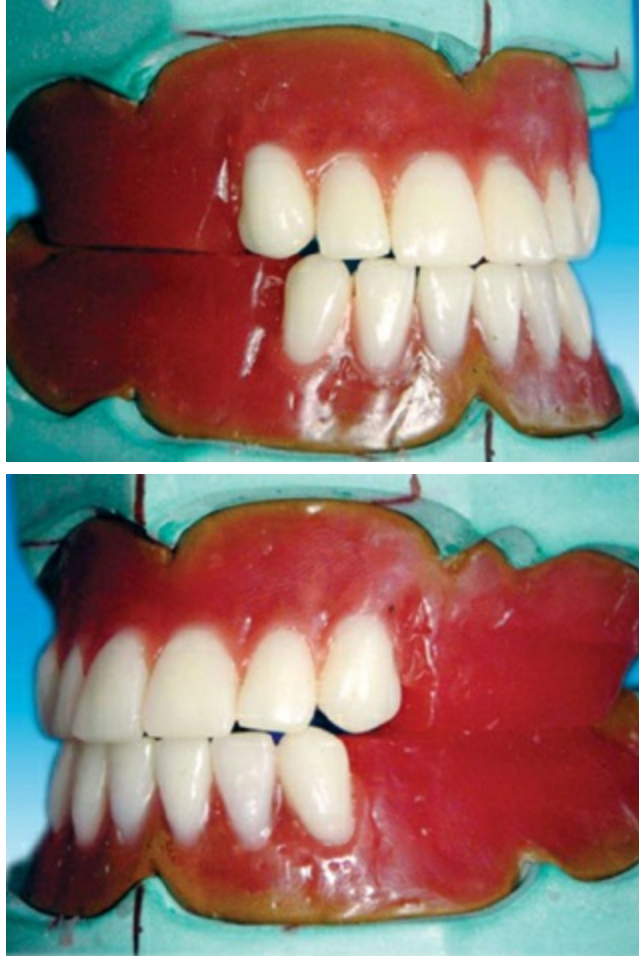


FIG 3.1.5.37 Maxillary and mandibular canine relationship (right and left)—side view

Posterior teeth setting

Guidelines for posterior teeth setting

Step 1: Mark a line on the occlusal surface of the lower occlusal rim, corresponding to the lower residual ridge and extend the line on the land area of the mandibular cast posterior to retromolar pad.

This line represents the central groove of the lower posterior teeth.

Step 2: Mark a line on the occlusal surface of the upper occlusal rim, line connecting the mid-point of lateral incisor and the line on the land area posterior to the tuberosity which is exactly opposite to the line on

the land area posterior to the retromolar pad (Figs 3.1.5.38—3.1.5.41).

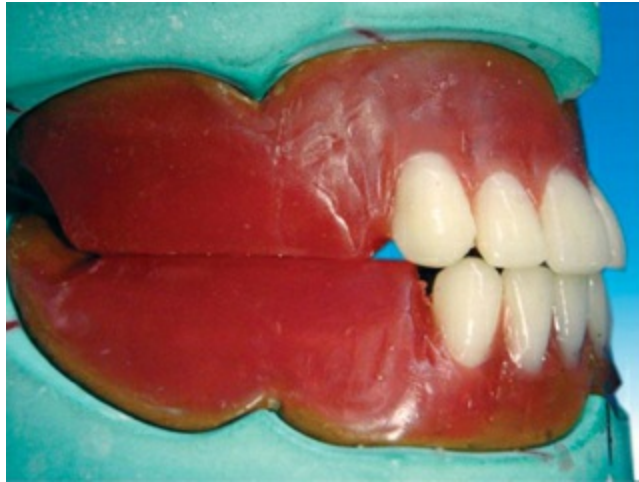


FIG 3.1.5.38 Maxillary and mandibular occlusal rims

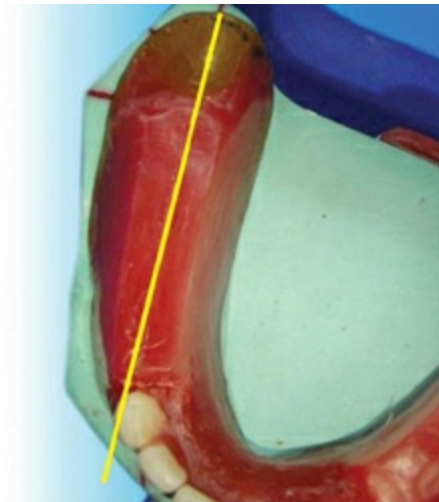


FIG 3.1.5.39 Line marked in the mandibular occlusion rim corresponding to the residual alveolar ridge




FIG 3.1.5.40 Lower line extended posteriorly and transferred to the upper cast

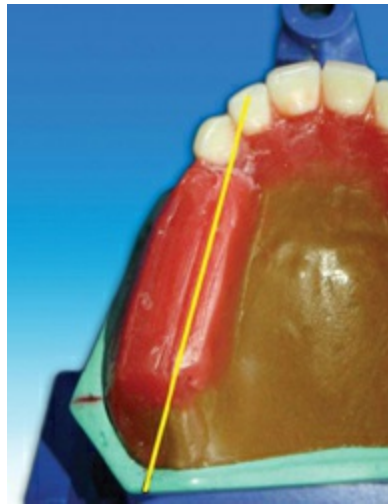


FIG 3.1.5.41 Line marked on the upper occlusal rim corresponding to the palatal cusps of upper posterior teeth

This line represents the palatal cusps of the upper posterior teeth.

Steps in placement of maxillary first premolar

Step 1: Scoop out the wax

Step 2: Placement of the maxillary first premolar in relation to all

three planes

The outline of the maxillary posteriors is marked on the maxillary occlusal rim with a heated wax carver and the required amount of wax is scooped out (Fig 3.1.5.42).

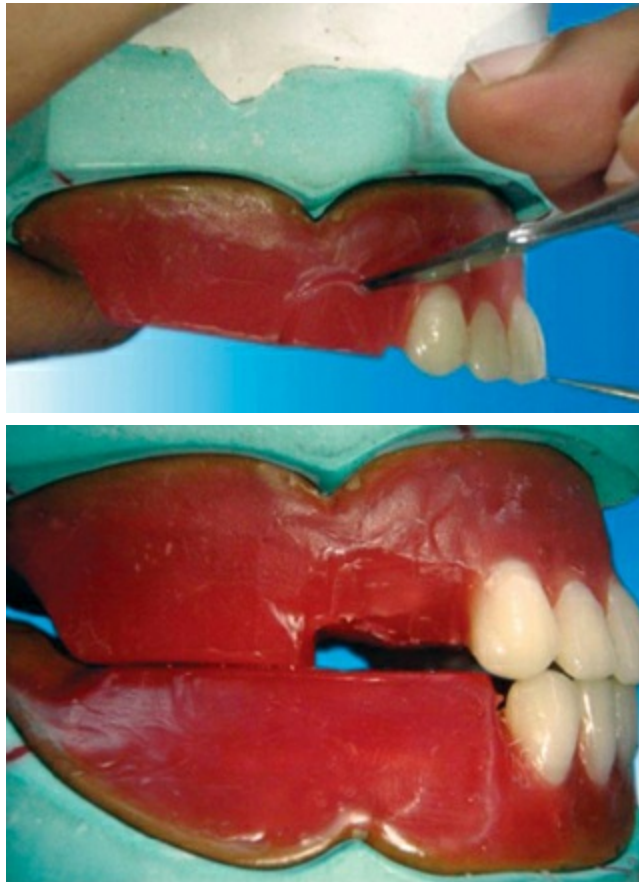


FIG 3.1.5.42 A. Mark the outline; **b.** Wax scooped out

The buccal cusp tip of the maxillary first premolar is in contact with occlusal plane (black line) and palatal cusp 1mm short of the occlusal plane (Fig 3.1.5.43).

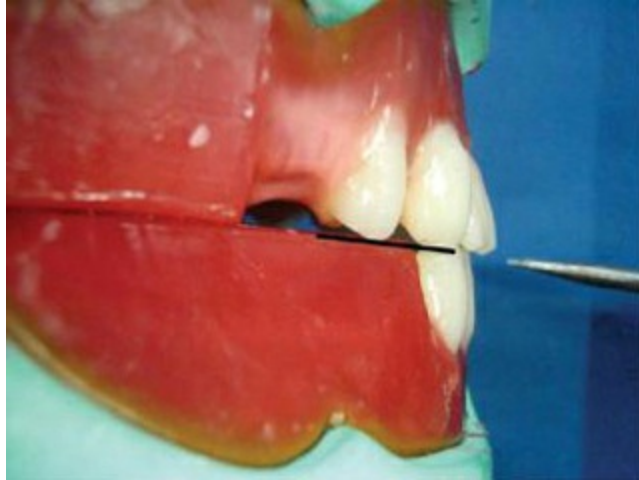

FIG 3.1.5.43 Maxillary premolar in relation to occlusal plane

The long axis of the maxillary first premolar (blue line) is parallel to the vertical axis (red line) (Fig 3.1.5.44).

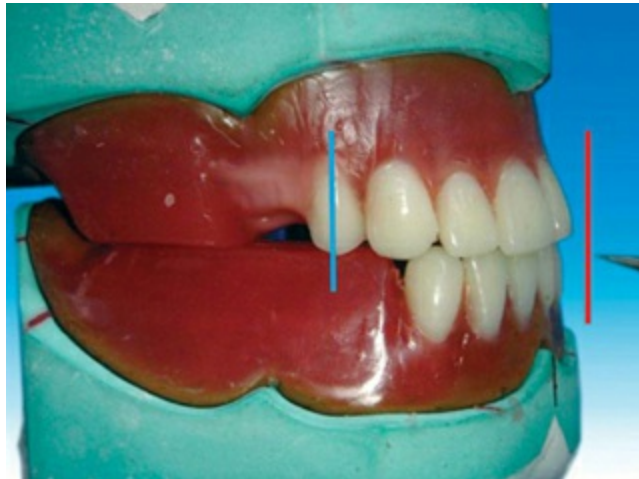


FIG 3.1.5.44 Maxillary first premolar in relation to vertical axis—side view.

The long axis of the maxillary first premolar (blue line) is placed parallel to the vertical axis (red line) when viewed from the front. When viewed from the front only small amount of the buccal surface should be visible when the patient smiles (Fig 3.1.5.45).

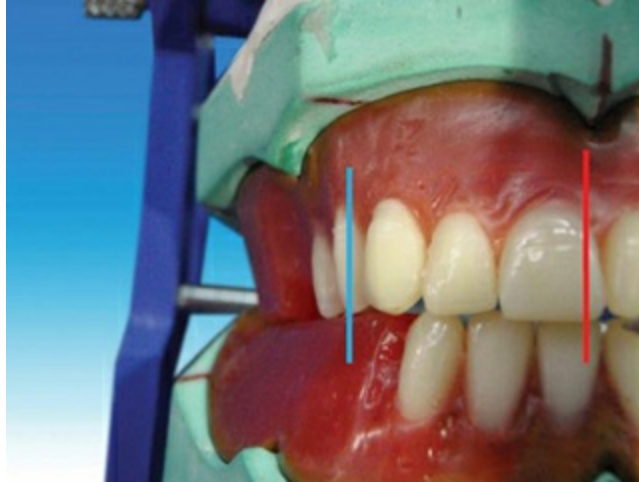

FIG 3.1.5.45 Maxillary first premolar in relation to vertical axis—front view

Figure 3.1.5.46 shows that buccal cusp corresponds with the canine tip and the palatal cusp corresponds to previous drawn reference line of the mandibular residual ridge line.

When viewed from:

Front: Long axis parallel towards the vertical axis.

Side: Long axis parallel towards the vertical axis .

Occlusal plane: Buccal cusp is in contact with occlusal plane and palatal cusp 1mm short of occlusal plane (Fig 3.1.5.47).

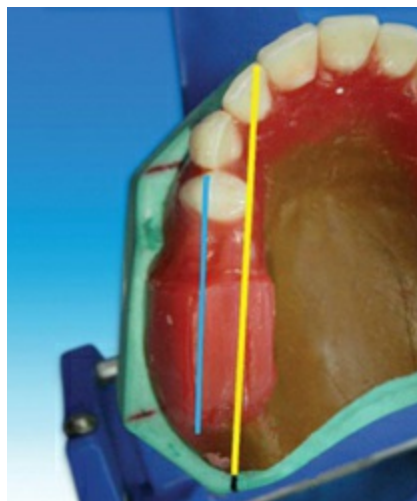


FIG 3.1.5.46 Placement of the maxillary first premolar—palatal cusp relation

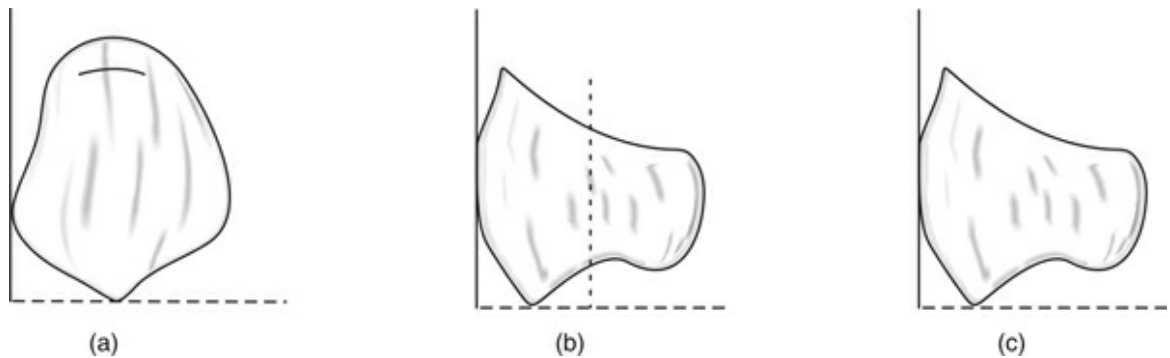


FIG 3.1.5.47 Illustration of maxillary first premolar in all three planes

Steps in placement of maxillary second premolar

Step 1:

Step 1: Scoop out the wax (Fig 3.1.5.48).

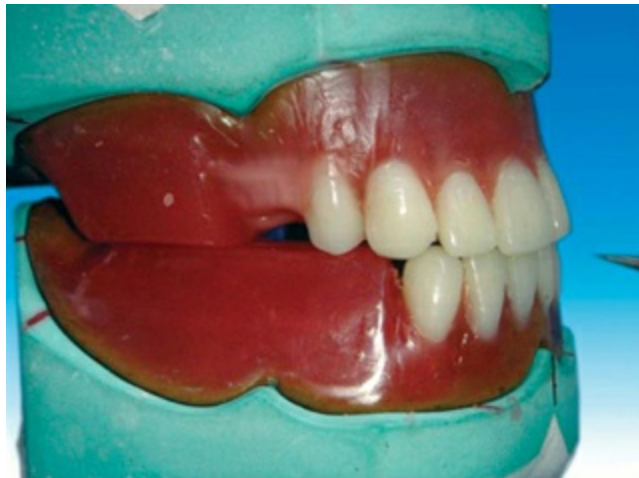

FIG 3.1.5.48 Scoop out the wax

Step 2: Placement of the maxillary second premolar in relation to all three planes.

The outline of the maxillary posteriors is marked on the maxillary occlusal rim with a heated wax carver and the required amount of wax is scooped out.

The buccal cusp tip and palatal cusp should be in contact with the occlusal plane—black line (Fig 3.1.5.49).

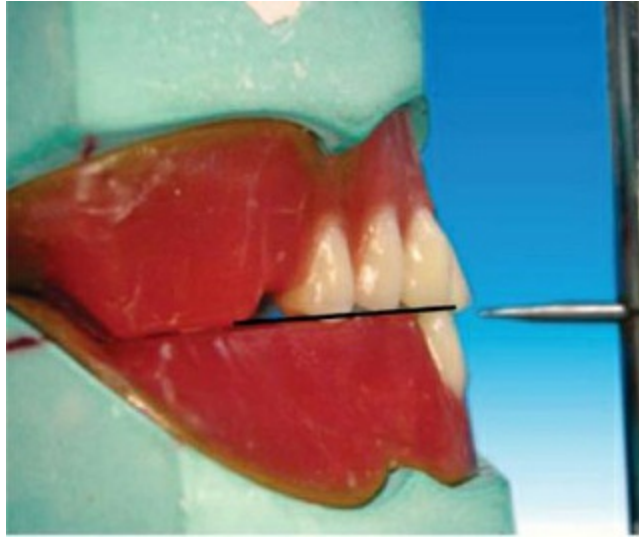


FIG 3.1.5.49 Maxillary second premolar in relation to occlusal plane

The long axis of the maxillary second premolar (green line) should be parallel to the vertical axis—red line (Fig 3.1.5.50).

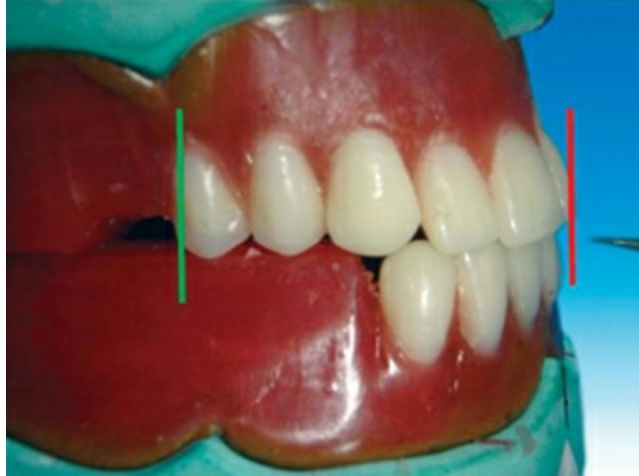


FIG 3.1.5.50 Maxillary second premolar in relation to vertical axis—side view

The buccal surface of the maxillary second premolar is barely visible when the patient smiles when viewed from the front ([Fig 3.1.5.51](#)).

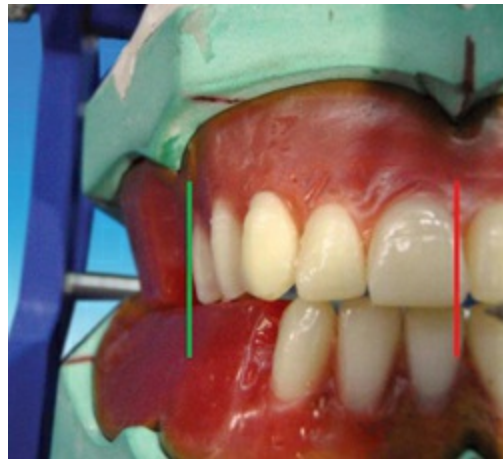


FIG 3.1.5.51 Maxillary second premolar in relation to vertical axis—front view

The buccal cusp of the maxillary second premolar corresponds with the buccal cusp of maxillary first premolar (blue line) and the palatal cusps of both the premolars correspond to the previous drawn line—yellow line ([Fig 3.1.5.52](#)).

When viewed from:

Front: Long axis parallel towards the vertical axis.
Side: Long axis parallel towards the vertical axis.
Occlusal plane: Both buccal cusp and palatal cusp is in contact with occlusal plane (Fig 3.1.5.53).

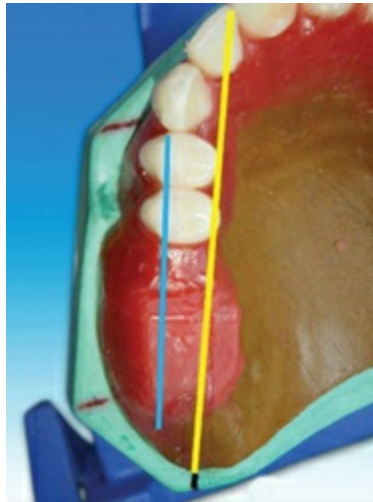

FIG 3.1.5.52 Placement of the maxillary second premolar

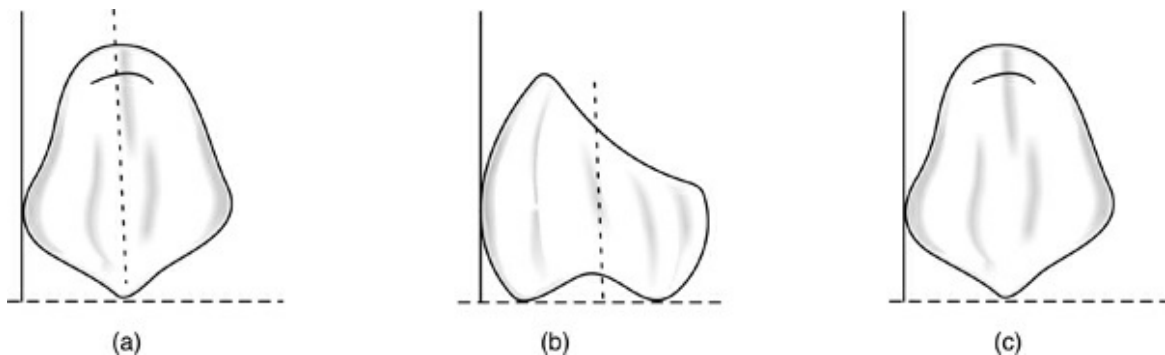


FIG 3.1.5.53 Illustration of maxillary second premolar in all three planes

Steps in placement of maxillary first molar

Step 1: Scoop out the wax.

Step 2: Placement of the maxillary first molar in relation to all three planes.

The outline of the maxillary posteriors is marked on the maxillary occlusal rim with a heated wax carver and the required amount of wax is scooped out. The long axis of the tooth (yellow line) is inclined distally in relation to vertical axis (red line). Only the mesiopalatal cusp is in contact with the occlusal plane—black line (Fig 3.1.5.54).

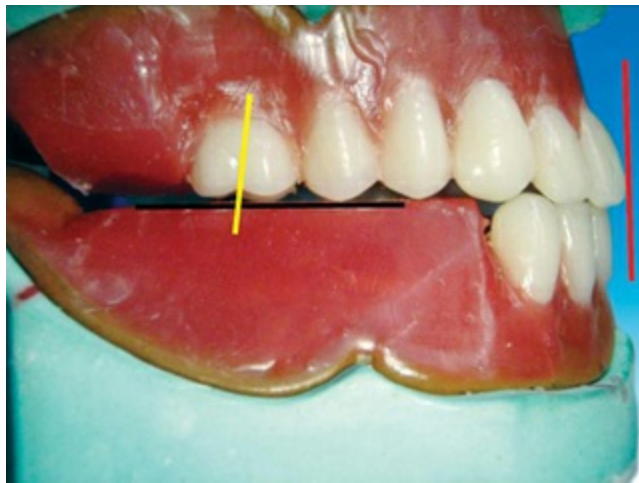


FIG 3.1.5.54 Placement of maxillary molar

The maxillary first molar is slightly inclined when viewed from the front. When the patient smiles, very minimal buccal surface should be visible when viewed from the front (Fig 3.1.5.55).

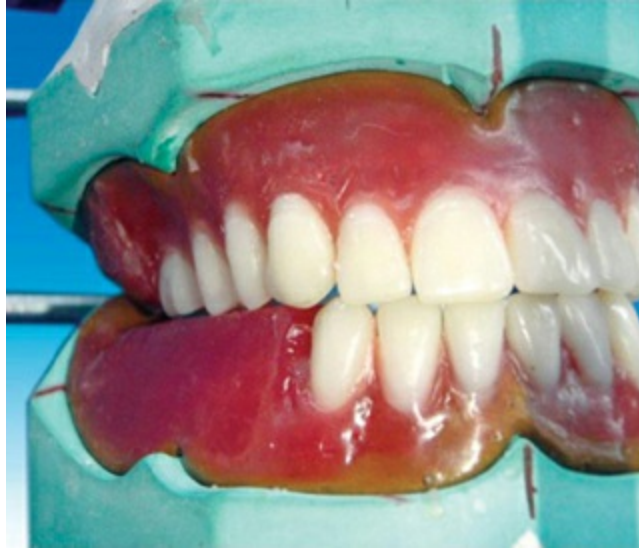

FIG 3.1.5.55 Maxillary first molar—front view

Figure 3.1.5.56 shows that the mesio- and distobuccal cusps correspond with the buccal cusp of second premolar (blue line) and the mesio- and distopalatal cusps correspond to the previous drawn line (yellow line).

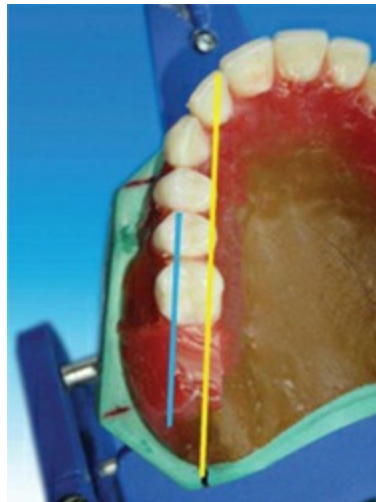

FIG 3.1.5.56 Placement of the maxillary first molar

When viewed from:
Front: Long axis slopes buccally.
Side: Long axis slopes distally.

Occlusal plane: Only mesiopalatal cusp is in contact with occlusal plane (Fig 3.1.5.57).

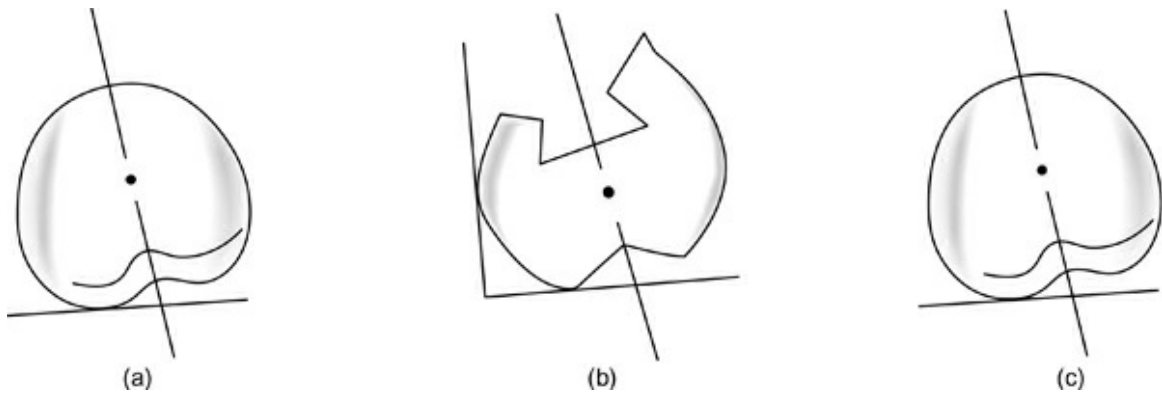


FIG 3.1.5.57 Illustration of maxillary first molar in all three planes

Steps in placement of maxillary second molar

Step 1: Scoop out the wax.

Step 2: Placement of the maxillary second molar.

The outline of the maxillary second molar is marked on the maxillary occlusal rim with a heated wax carver and the required amount of wax is scooped out. The long axis of the maxillary second molar (blue line) is distally inclined in relation to the vertical axis (red line) when viewed from the front (Fig 3.1.5.58). All the cusps are short of the occlusal plane (black line).

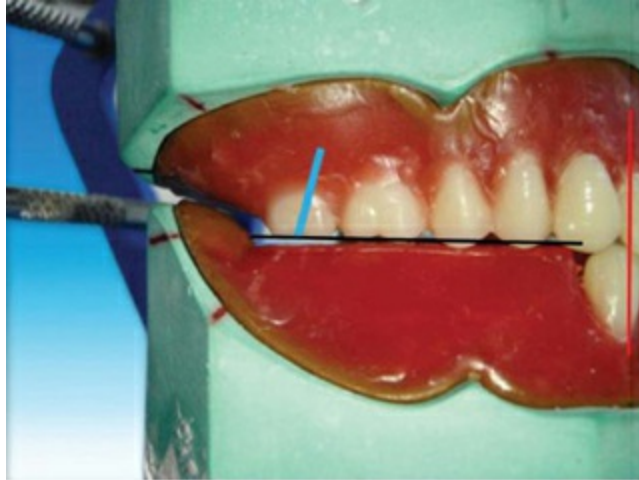


FIG 3.1.5.58 Maxillary second molar—side view

The maxillary second molar is slightly buccally inclined when viewed from the front. The buccal surface of the maxillary second molar is barely visible when viewed from the front ([Fig 3.1.5.59](#)).

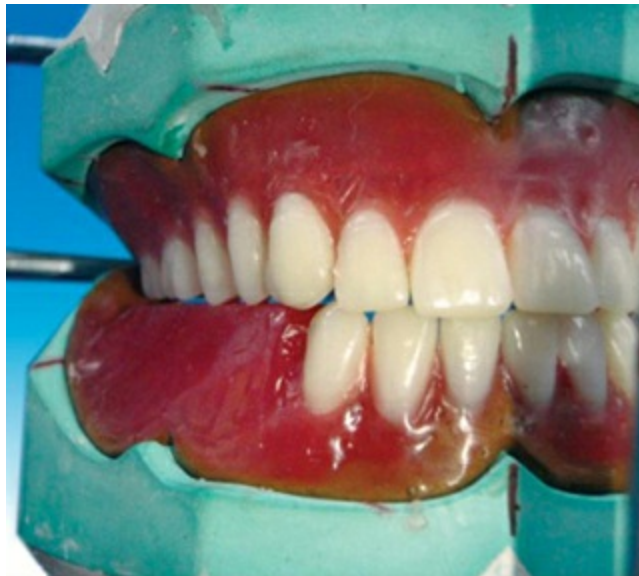

FIG 3.1.5.59 Maxillary second molar—front view

[Figure 3.1.5.60](#) shows that mesio- and distobuccal cusps correspond with the mesio- and distobuccal cusps of first molar (blue line) and the palatal cusp corresponds to the previous drawn line (yellow line).

When viewed from:

Front: Long axis slopes buccally more steeply than first molar.
Side: Long axis slopes distally more steeply than first molar.
Occlusal plane: Only mesiopalatal cusp is nearest to occlusal plane
(Fig 3.1.5.61).

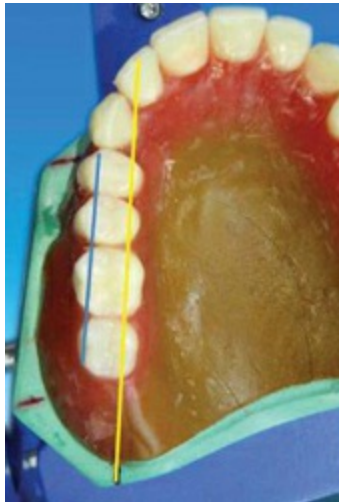

FIG 3.1.5.60 Placement of the maxillary second molar

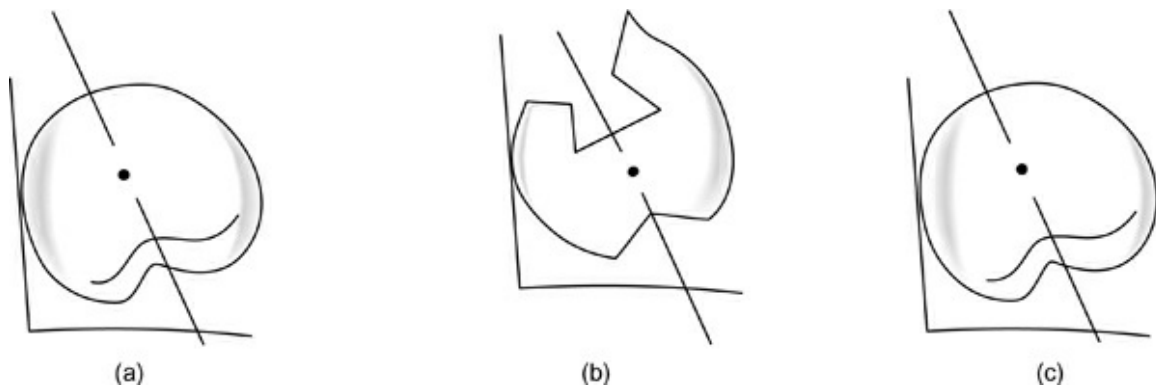


FIG 3.1.5.61 Illustration of maxillary second molar in all three planes

Steps in placement of mandibular first premolar

Step 1: Scoop out the wax.

Step 2: Placement of the mandibular first premolar in relation to all three planes.

The outline of the mandibular first premolar is marked on the mandibular occlusal rim with a heated wax carver (Fig 3.1.5.62).

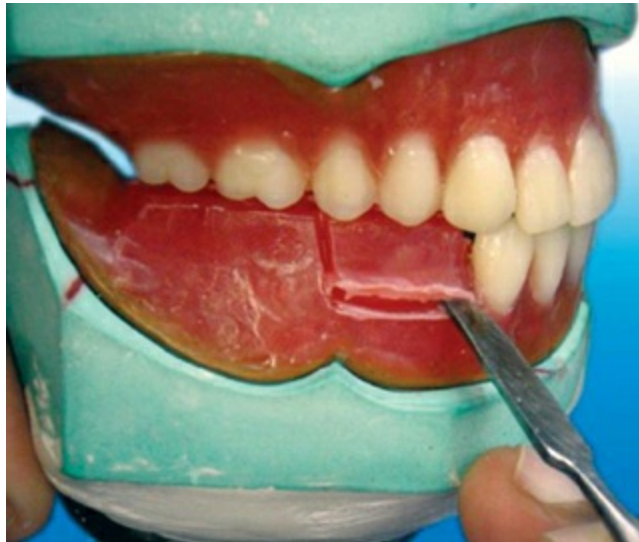

FIG 3.1.5.62 Mark the outline

The outlined area and required amount of wax is scooped out (Fig 3.1.5.63).

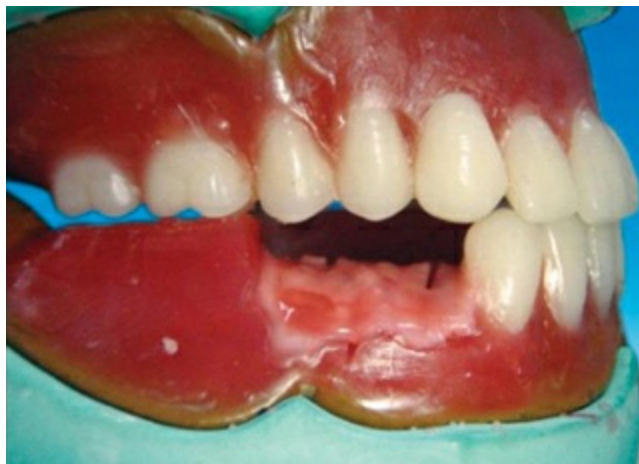

FIG 3.1.5.63 Wax scooped out

A reference guideline of the crest of the residual alveolar ridge is marked on the posterior occlusion rim (yellow line). The central fossa of the posterior teeth should be along the reference line ([Fig 3.1.5.64](#)).

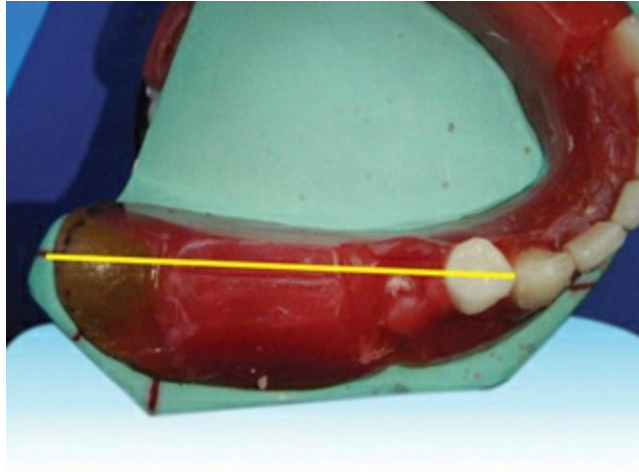


FIG 3.1.5.64 Placement of mandibular first premolar—occlusal view

The long axis of the tooth is placed parallel to the vertical axis when viewed from the front. The mandibular first premolar is placed maxillary canine and the maxillary first premolar as shown in [Figure 3.1.5.65](#).

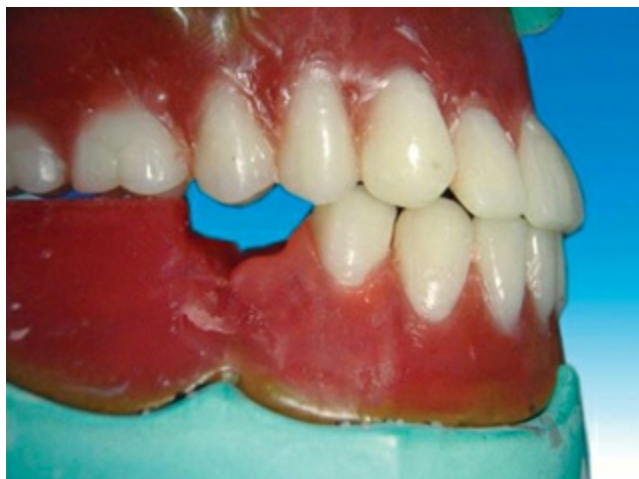

FIG 3.1.5.65 Mandibular first premolar—side view

The long axis of the mandibular first premolar should be inclined lingually when viewed from the front. The buccal surface of the tooth should be barely visible when viewed from the front ([Fig 3.1.5.66](#)).

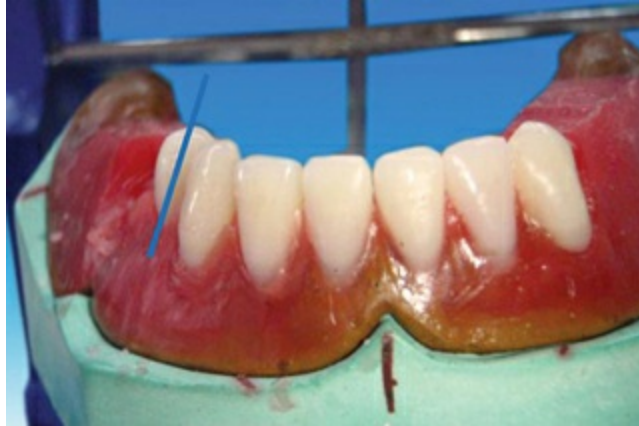

FIG 3.1.5.66 Mandibular first premolar—front view

There is no lingual intercuspation when viewed lingually ([Fig 3.1.5.67](#)).

When viewed from:

Front: Long axis parallel towards the vertical axis.

Side: Long axis parallel towards the vertical axis.

Occlusal plane: Lingual cusp below the horizontal plane, buccal cusp is 2 mm above the occlusal plane.

Occlusal contact: Buccal cusp contacts the mesial marginal ridge of upper first premolar ([Fig 3.1.5.68](#)).

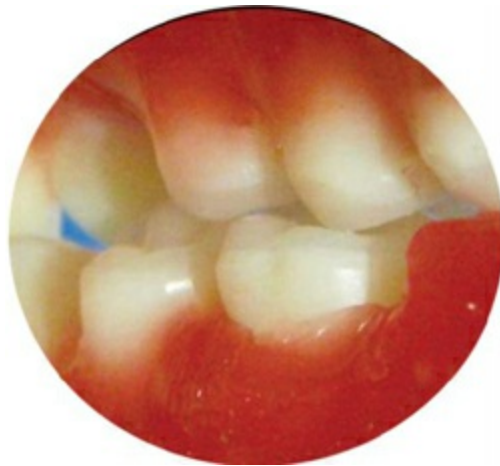
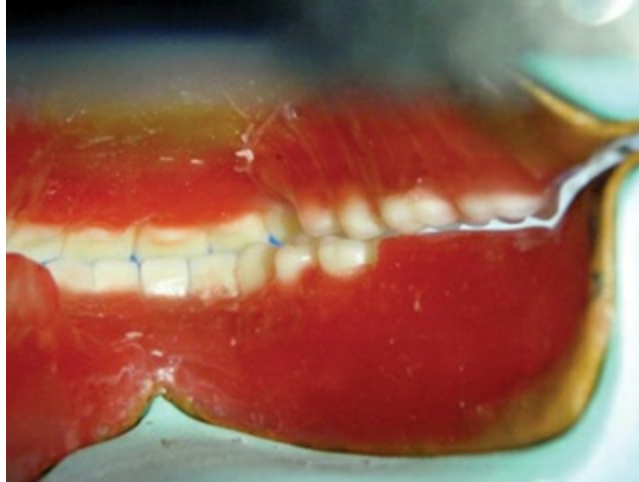
FIG 3.1.5.67 Mandibular first premolar—lingual view

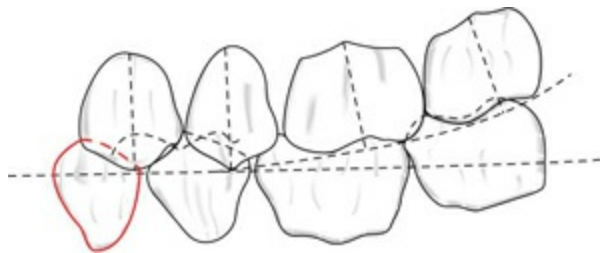


FIG 3.1.5.68 Illustration of mandibular first premolar in all three planes

Steps in placement of mandibular second

premolar

Step 1: Scoop out the wax.

Step 2: Placement of the mandibular second premolar in relation to all three planes.

The mandibular second premolar is placed on the occlusion rim. The central fossa of the posterior tooth should be placed along the reference line (yellow line) marked ([Fig 3.1.5.69](#)).

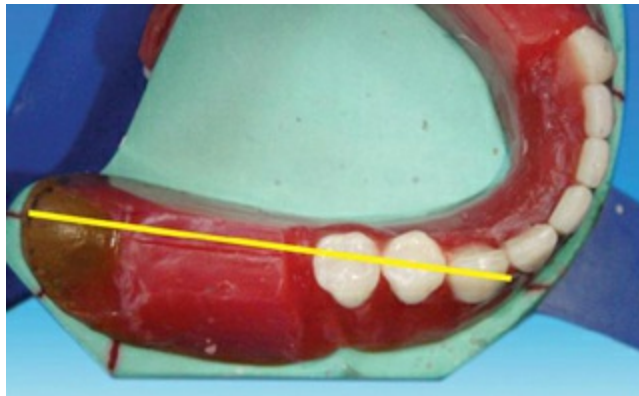


FIG 3.1.5.69 Mandibular second premolar—occlusal view

The mandibular second premolar is placed parallel to the vertical axis when viewed from the front. The mandibular second premolar is placed between the maxillary first and second premolars ([Fig 3.1.5.70](#)).

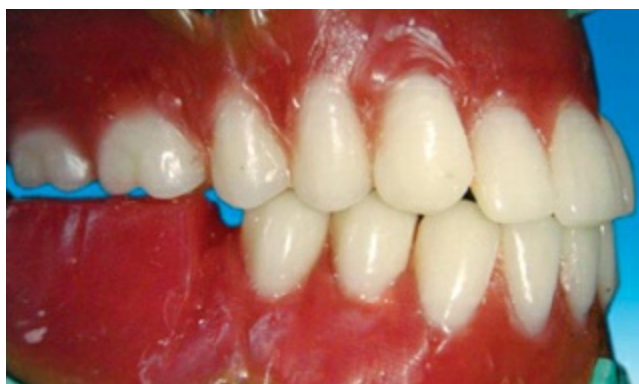

FIG 3.1.5.70 Mandibular second premolar—side view

The mandibular second premolar is placed slightly lingually inclined when viewed from the front (Fig 3.1.5.71).

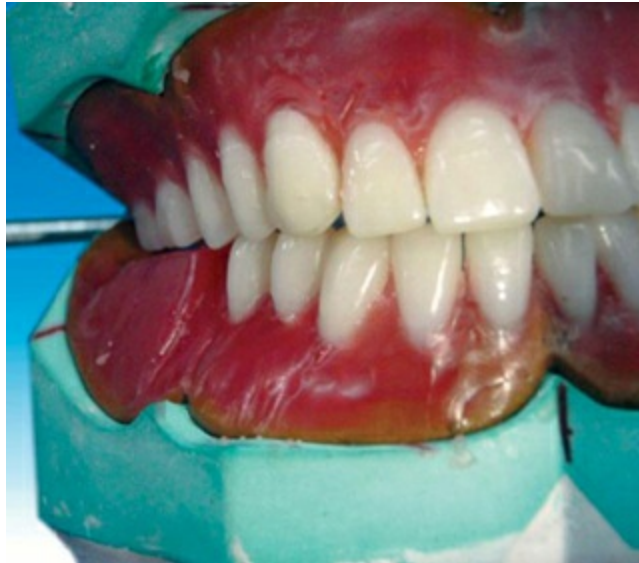

FIG 3.1.5.71 Mandibular second premolar—front view

The central groove of the lower mandibular second premolar is in contact with the palatal cusp of the maxillary second premolar when viewed lingually (Fig 3.1.5.72).

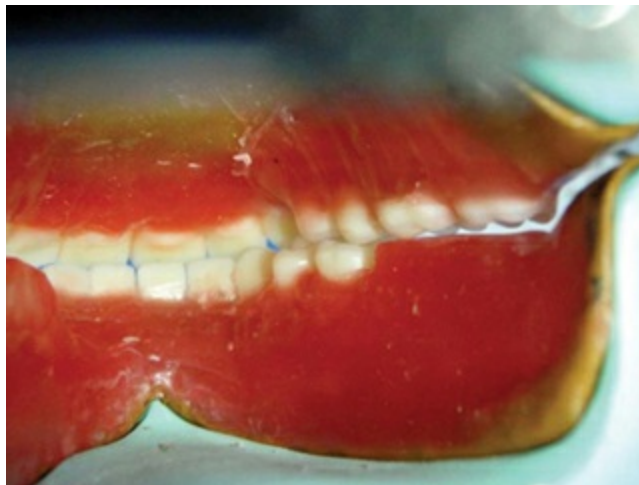

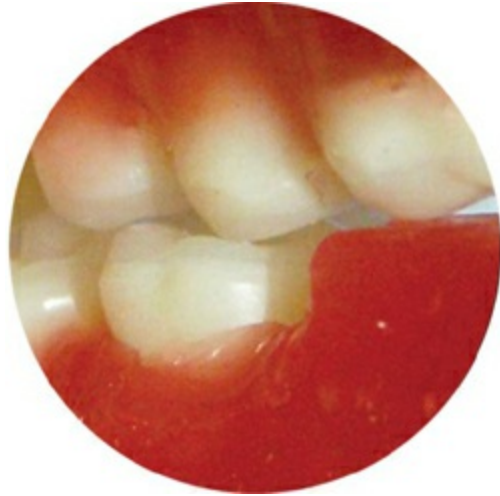


FIG 3.1.5.72 Mandibular second premolar—lingual view

When viewed from:

Front: Long axis parallel towards the vertical axis.

Side: Long axis parallel towards the vertical axis.

Occlusal plane: Both cusps are about 2mm above the occlusal plane.

Occlusal contact: The buccal cusp contacting the fossa between the two upper premolars ([Fig 3.1.5.73](#)).

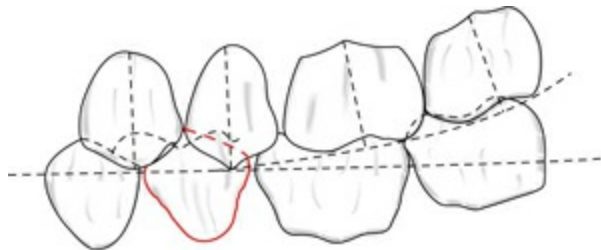


FIG 3.1.5.73 Illustration of mandibular second premolar in all three planes

Steps in placement of mandibular first molar

Step 1: Scoop out the wax.

Step 2: Placement of the mandibular first molar in relation to all three

planes.

The outline of the mandibular first molar is marked on the mandibular occlusal rim with a heated wax carver and the required amount of wax is scooped out (Fig 3.1.5.74).

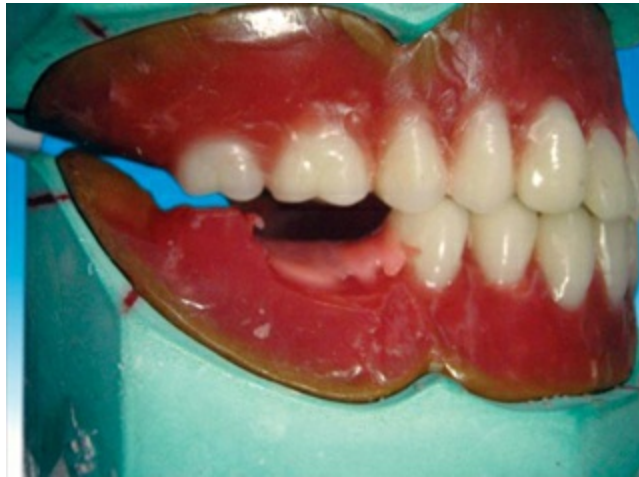

FIG 3.1.5.74 Scoop out the wax

The mandibular first molar is placed on the occlusion rim (Fig 3.1.5.75). The central fossa of the mandibular first molar is placed along the reference line (yellow line).

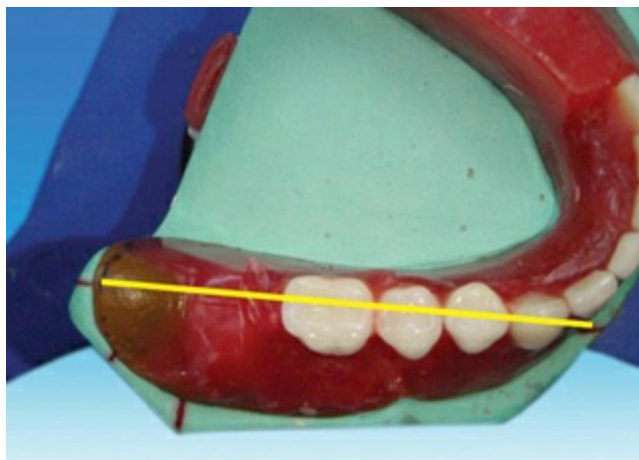


FIG 3.1.5.75 Mandibular first molar—occlusal view

The mandibular first molar is positioned in the occlusion rim below the maxillary first molar (Fig 3.1.5.76). The mesiobuccal cusp of the maxillary first molar (blue arrow) should rest on the mesiobuccal groove of the mandibular first molar (yellow arrow).

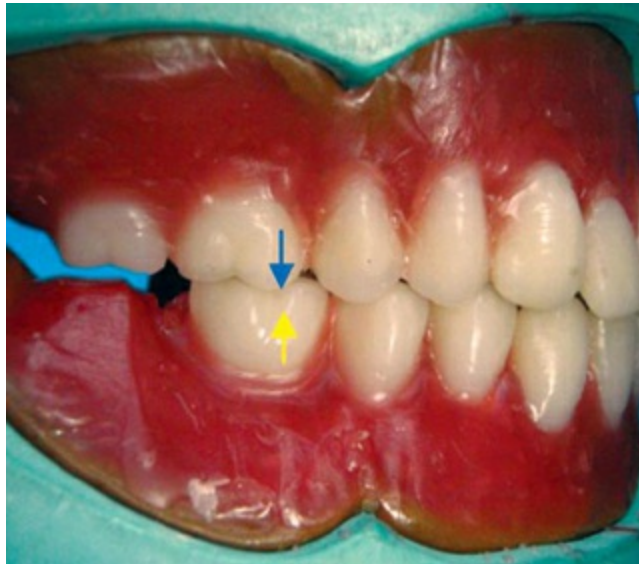

FIG 3.1.5.76 Mandibular first molar—side view

The mandibular first molar is slightly lingually inclined. The buccal surface of the tooth is barely visible when viewed from the front (Fig 3.1.5.77).

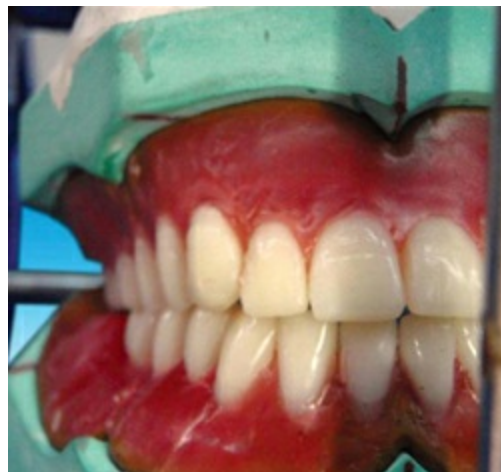

FIG 3.1.5.77 Mandibular first molar—front view

The mesiopalatal cusp of the maxillary first molar interdigitates with the central groove of the mandibular first molar (Fig 3.1.5.78).

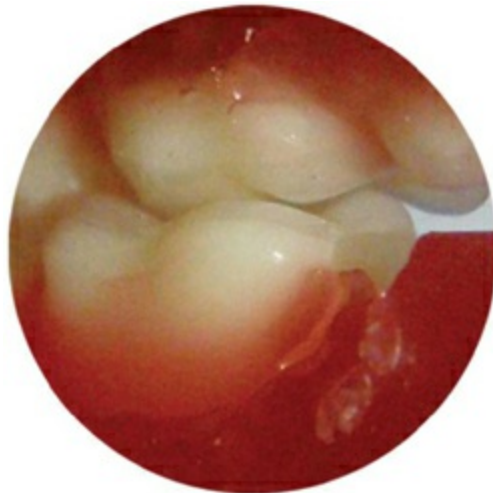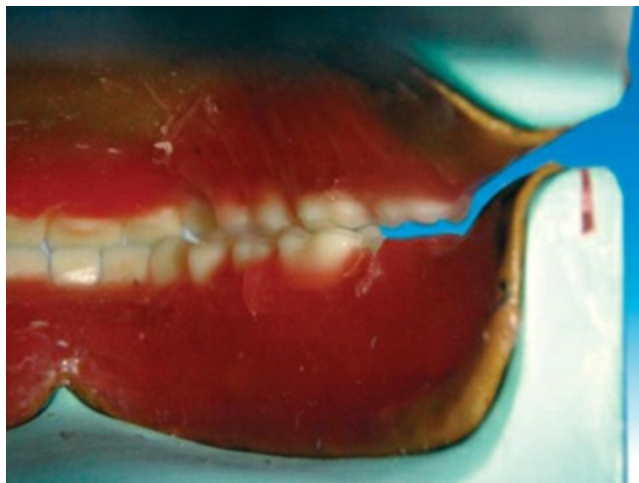


FIG 3.1.5.78 Maxillary and mandibular first molars—lingual view

When viewed from:

Front: Long axis lean lingually.

Side: Long axis lean mesially.

Occlusal plane: All cusps are at higher level than second premolar, buccal and distal cusps higher than the other two.

Occlusal contact: The mesiobuccal cusp occludes in the fossa

between upper second premolar and first molar ([Fig 3.1.5.79](#)).

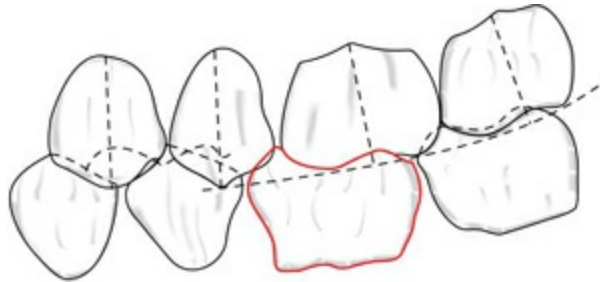


FIG 3.1.5.79 Illustration of mandibular first molar in all three planes

Steps in placement of mandibular second molar

Step 1: Scoop out the wax

Step 2: Placement of the mandibular second molar in relation to all three planes

The outline of the mandibular second molar is marked on the mandibular occlusal rim with a heated wax carver and the required amount of wax is scooped out. The mandibular second molar is positioned in the occlusion rim such that the central fossa or groove of the second molar is in line with the reference line (yellow line) ([Fig 3.1.5.80](#)).

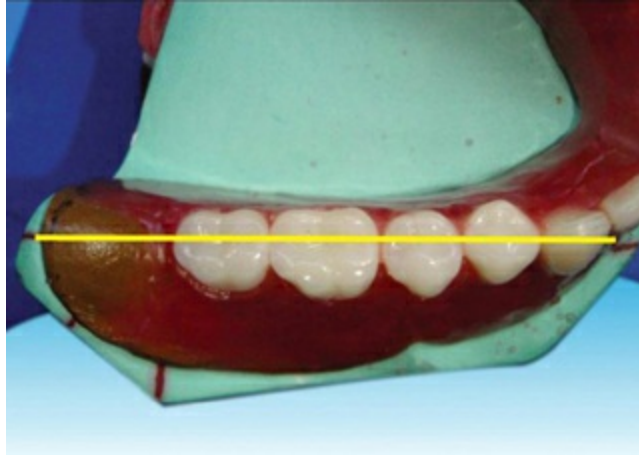


FIG 3.1.5.80 Mandibular second molar—occlusal view

The mandibular second molar is placed on the occlusion rim below the maxillary second molar. The mesiobuccal cusp of the maxillary molar should rest on the mesiobuccal groove of the mandibular second molar ([Fig 3.1.5.81](#)).

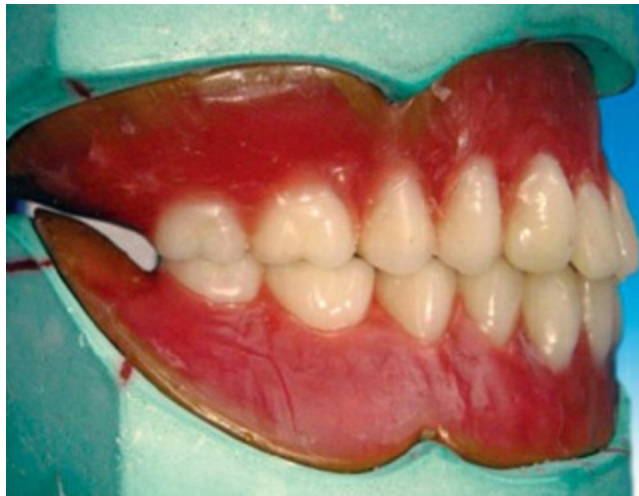

FIG 3.1.5.81 Mandibular second molar—side view.

The mandibular second molar is positioned slightly lingually inclined when viewed from the front. The buccal surface is barely visible when viewed from the front ([Fig 3.1.5.82](#)).

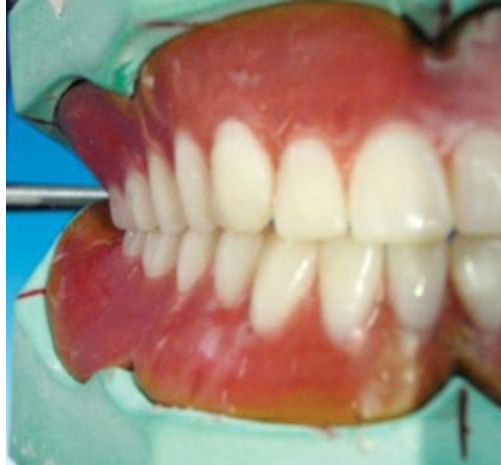

FIG 3.1.5.82 Mandibular second molar—front view

The lingual view shows that the central groove of the lower second molar is in contact with the palatal cusps of the maxillary first molar (Fig 3.1.5.83).

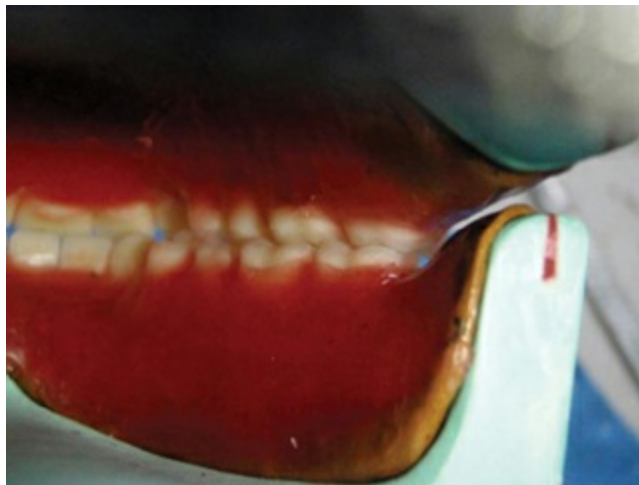

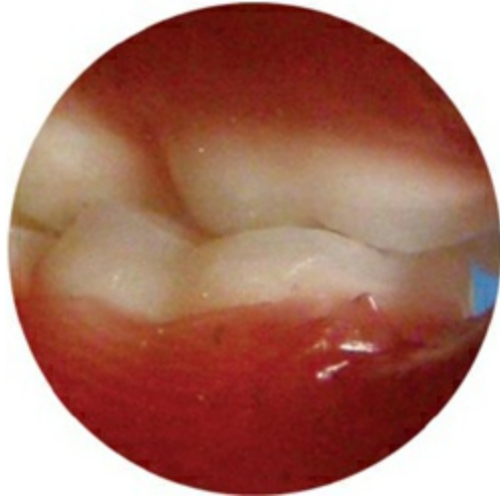


FIG 3.1.5.83 Maxillary and mandibular second molars—lingual view

When viewed from:

Front: Long axis lean more lingually.

Side: Long axis lean more mesially.

Occlusal plane: All cusps are at higher level than first molar, buccal and distal cusps higher than the other two.

Occlusal contact: The mesiobuccal cusp occludes in the fossa between the two upper molars ([Fig 3.1.5.84](#)).

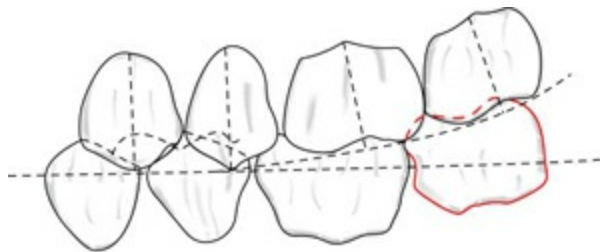


FIG 3.1.5.84 Illustration of mandibular second molar in all three planes

Same steps are followed to do the teeth setting on the other side ([Figs 3.1.5.85—](#))

[3.1.5.87](#)

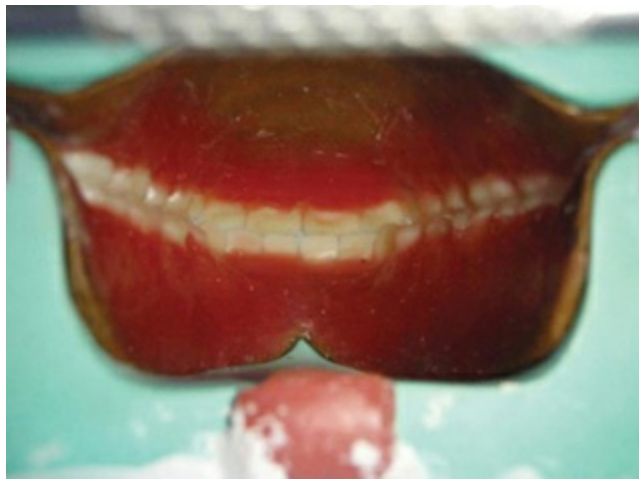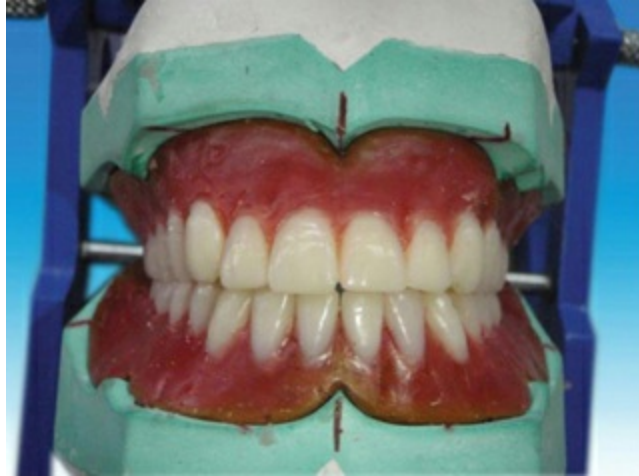

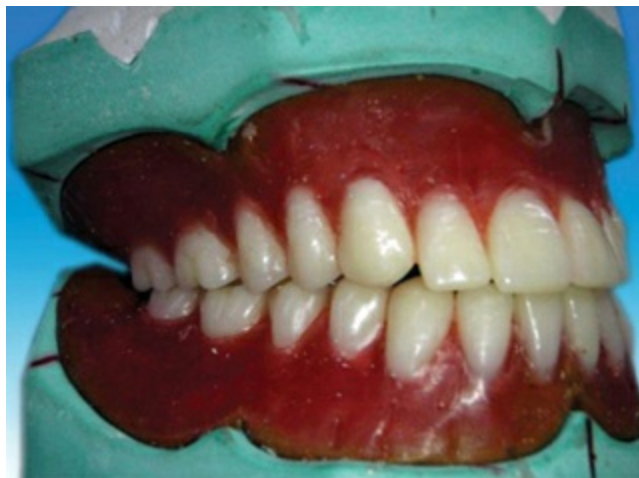
FIG 3.1.5.85 Completed teeth arrangement—right and left lingual views



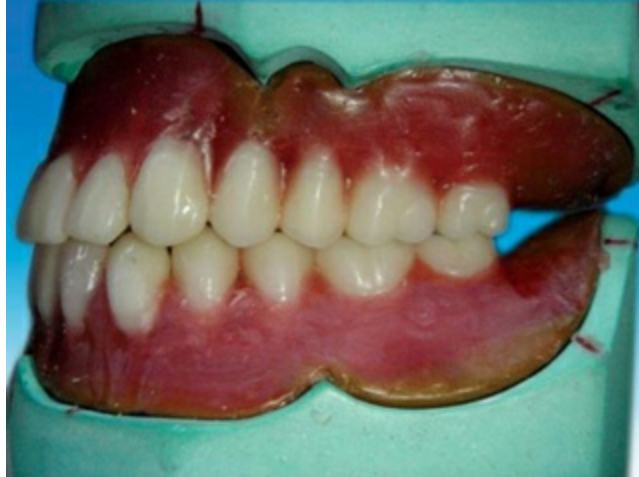

FIG 3.1.5.86 Completed teeth arrangement—right and left oblique views

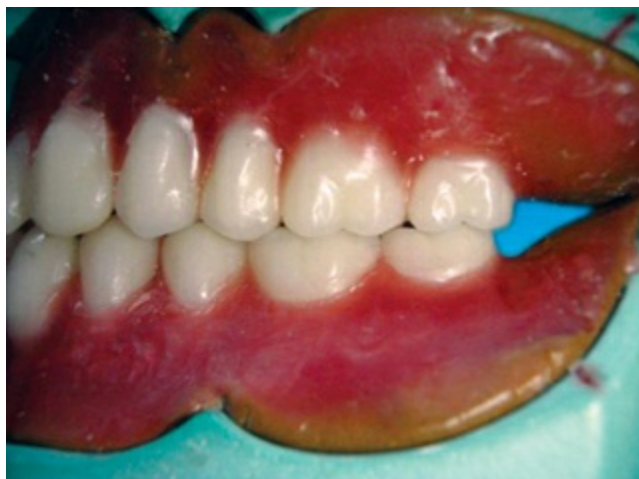
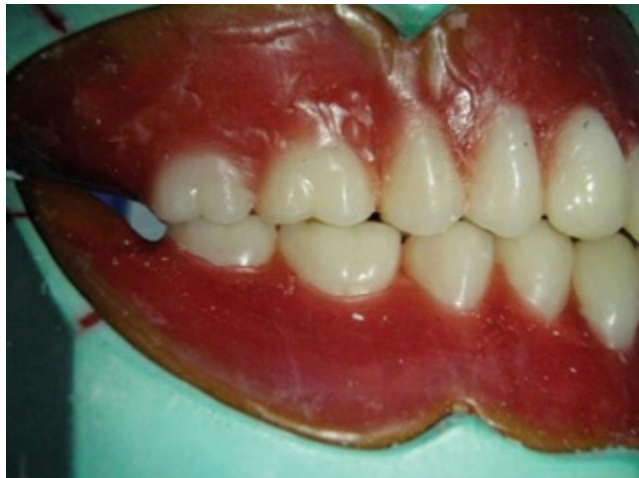
FIG 3.1.5.87 Completed teeth arrangement—right and left side views

3.1.6 Wax-up

Armamentarium (Fig 3.1.6.1)

- Maxillary trial denture with cast
- Mandibular trial denture with cast
- Mean value articulator
- Wax knife
- Roach carver
- Wax spatula
- Wax sheet
- Gas torch
- Modified bristle brush




FIG 3.1.6.1 Armamentarium

Addition of wax in maxillary trial denture

Soften a roll of baseplate wax over the Bunsen burner and add the molten wax on the palatal surface, buccal, labial surface of the waxed denture surface (Figs 3.1.6.2, 3.1.6.3).



FIG 3.1.6.2 Addition of softened wax

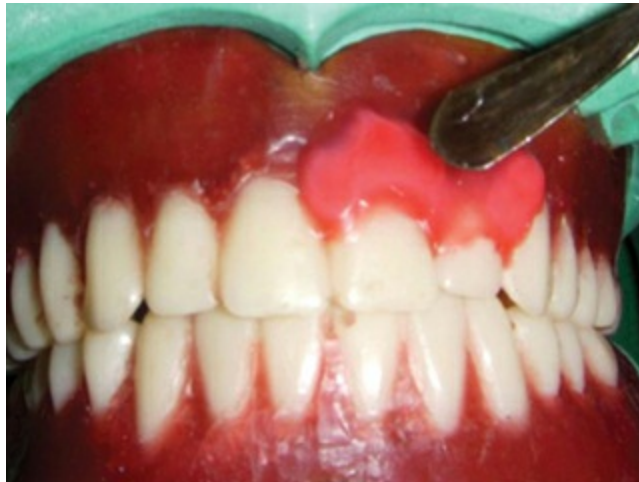

FIG 3.1.6.3 Addition of molten wax on the labial surface of the waxed denture

Adapt the softened roll of baseplate wax on the facial surface and extend it on the flange of the trial denture.

Adapt the softened roll of baseplate wax along the posterior borders of the trial denture distal to the second molar region ([Fig 3.1.6.4](#)).

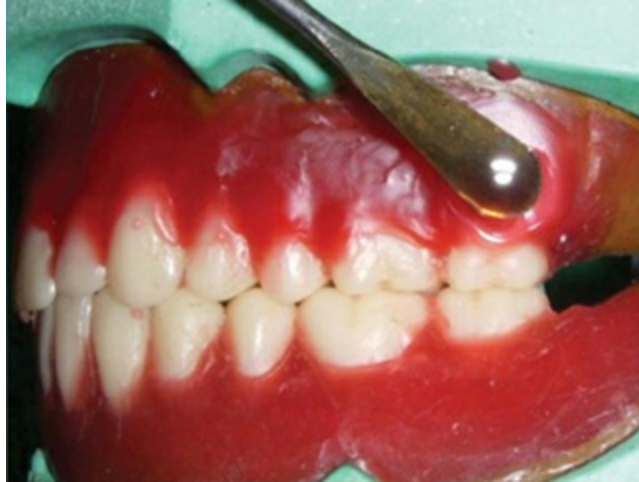

FIG 3.1.6.4 Addition of molten wax on the posterior aspect of the waxed denture

Adapt the softened roll of baseplate wax along the palatal surfaces of the denture teeth and extend it palatally so that palatal contour of the waxed denture is smooth and is of uniform thickness ([Fig 3.1.6.5](#)).

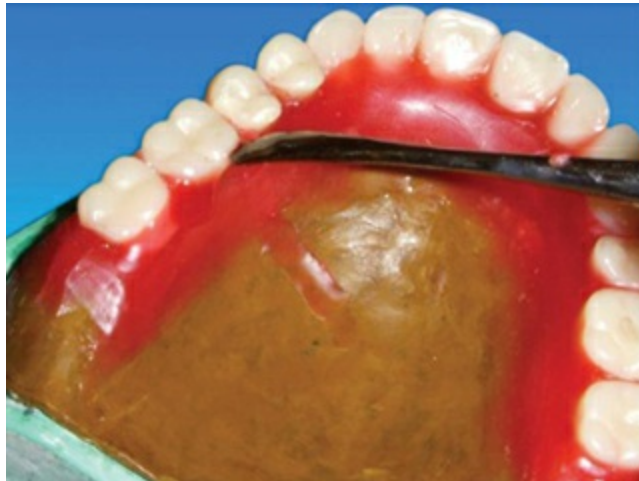

FIG 3.1.6.5 Addition of molten wax on the palatal surface of the waxed denture

Seal the baseplate wax around the necks of each tooth with a wax spatula ([Fig 3.1.6.6](#)).

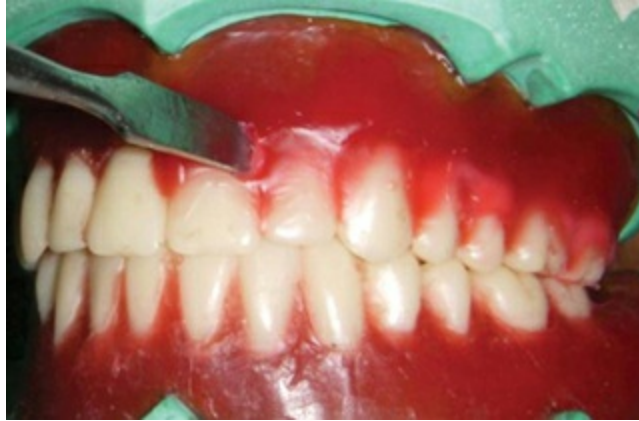

FIG 3.1.6.6 Addition of molten wax on the necks of the artificial teeth

Use a Roach carver held at approximately 60 degree angle to carve the gingival margins around the anterior teeth (Fig 3.1.6.7).

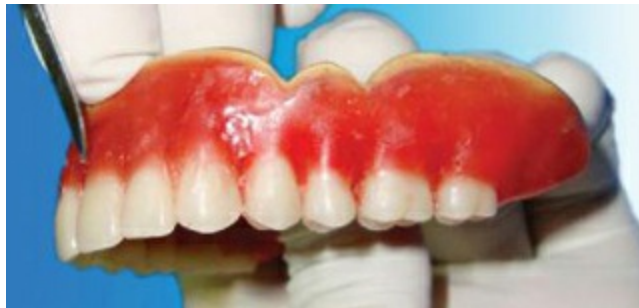

FIG 3.1.6.7 Carving the gingival margin of the anterior teeth

Use a Roach carver held at approximately 45 degree to carve the gingival margin around the posterior teeth (Fig 3.1.6.8).

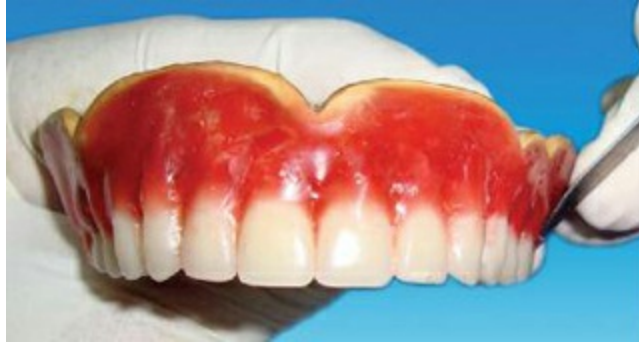

FIG 3.1.6.8 Carving the gingival margin of the posterior teeth

Use a Roach carver held at approximately 20 degree angle to carve the lingual surface of the denture teeth ([Fig 3.1.6.9](#)).

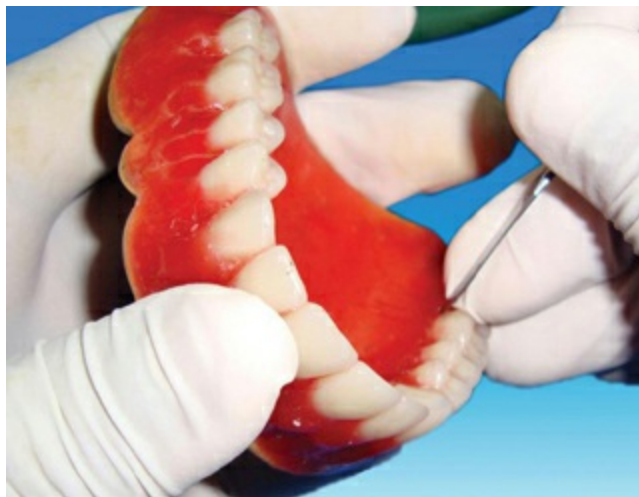

FIG 3.1.6.9 Carving gingival margin of the lingual surface

Follow the finish line around the necks of the teeth removing all wax remaining on the teeth above the finish line ([Fig 3.1.6.10](#)).

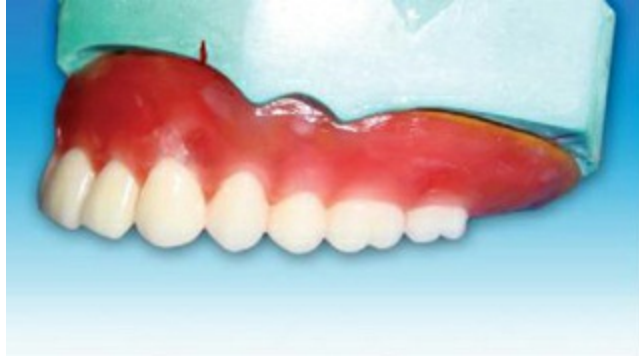

FIG 3.1.6.10 Side view of the gingival margins of the maxillary teeth

Carve the wax to produce gingival papilla. It should be convex, both occlusogingivally and mesiodistally (Fig 3.1.6.11).

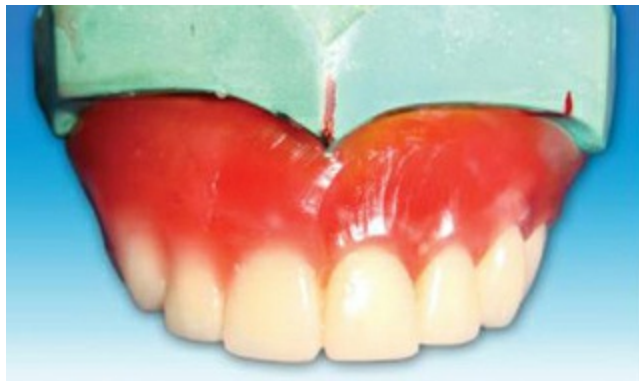

FIG 3.1.6.11 Carving gingival papilla

Contour the wax to form root prominences over maxillary central incisors and canine eminence over canine tooth (Fig 3.1.6.12).

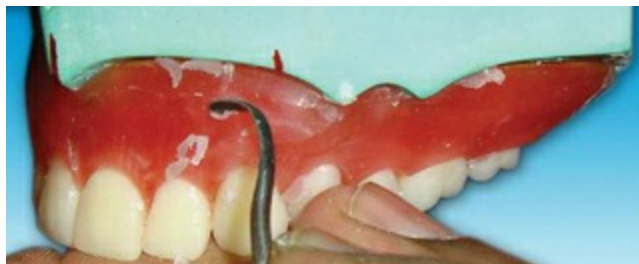

FIG 3.1.6.12 Carving the root eminence

Carve a slight depression between roots of central incisor and the canine eminence. Carve a slight depression above the premolar extending posteriorly to form the canine fossa (Fig 3.1.6.13).

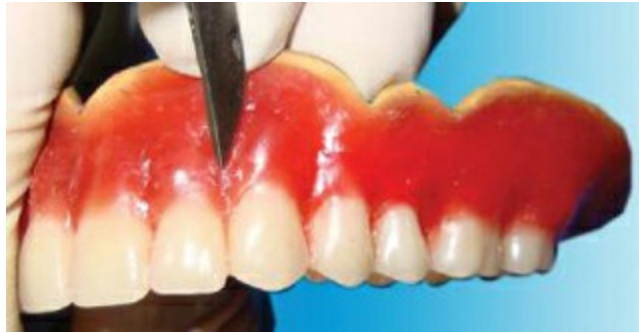

FIG 3.1.6.13 Carving the canine root form

Use a gas torch or a Bunsen burner to flame the wax surface taking care not to overheat the gingival contours (Fig 3.1.6.14). Stipple the region of attached gingiva with a modified bristle brush.

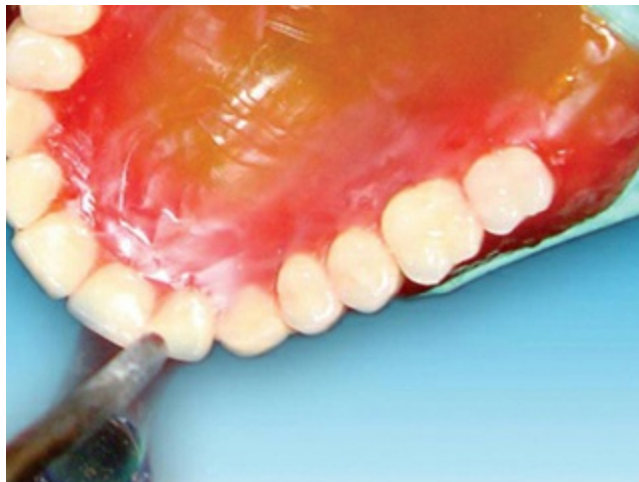

FIG 3.1.6.14 Smoothing the gingival contour

The maxillary waxed trial denture shows the gingival contour and the root forms (Fig 3.1.6.15).

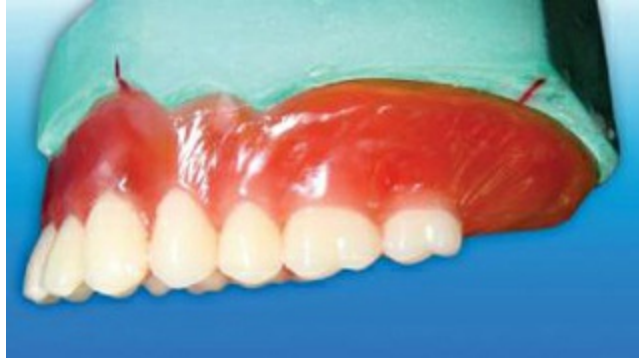

FIG 3.1.6.15 Completed wax up of upper trial denture

Addition of wax in mandibular trial denture

Adapt the softened roll of baseplate wax on the labial surface of the mandibular trial denture (Fig 3.1.6.16).

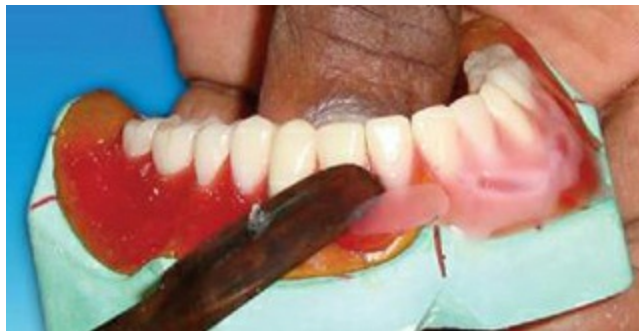

FIG 3.1.6.16 Addition of softened wax on the waxed mandibular trial denture

Adapt the softened roll of baseplate wax on the lingual surface of the mandibular trial denture (Fig 3.1.6.17).

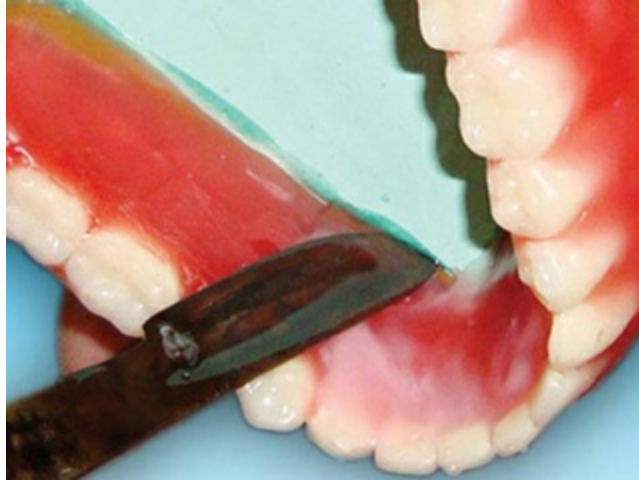

FIG 3.1.6.17 Addition of softened wax on the lingual aspect of the trial denture

Seal the baseplate wax around the necks of each tooth with a wax spatula (Fig 3.1.6.18).

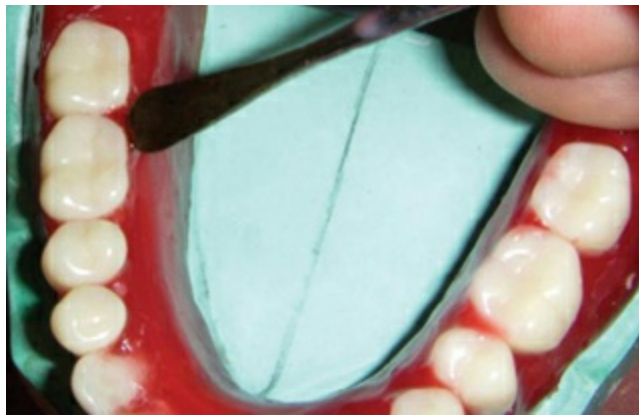

FIG 3.1.6.18 Sealing the necks of the teeth

Use a Roach carver held at approximately 20 degrees angle to carve the gingival margin around the teeth (Fig 3.1.6.19).

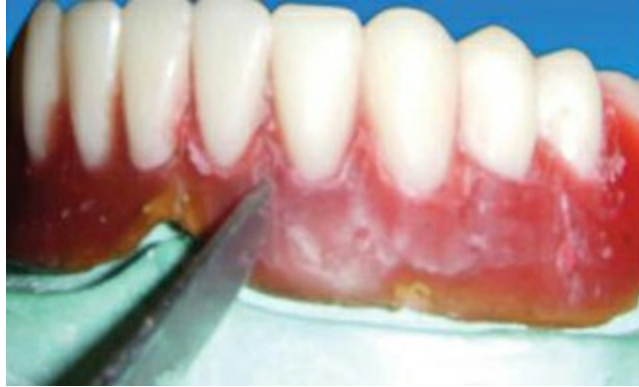

FIG 3.1.6.19 Carving the gingival margin

Follow the finish lines around the necks of the teeth removing all the wax remaining on the teeth above the finish line (Fig 3.1.6.20).

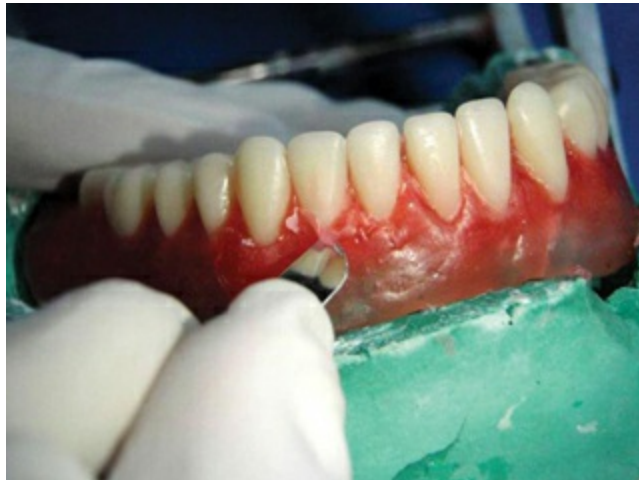

FIG 3.1.6.20 Removing wax on teeth above finish line

The free gingival margin, gingival bulge and interproximal papillae are contoured similar to the maxillary trial denture (Fig 3.1.6.21).

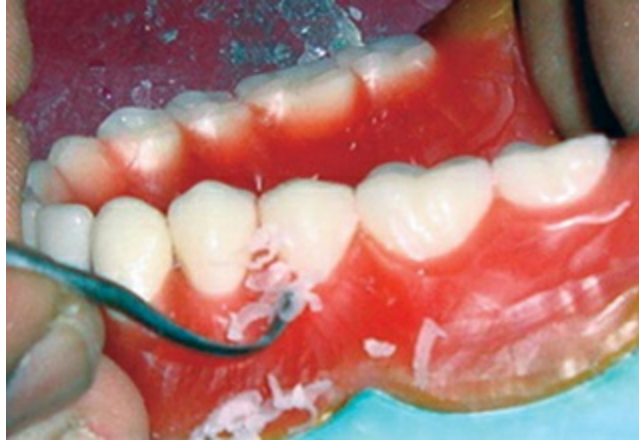

FIG 3.1.6.21 Carving the free gingival margin

Contour a small bulge below the incisors and develop a canine eminence below canine tooth (Fig 3.1.6.22).

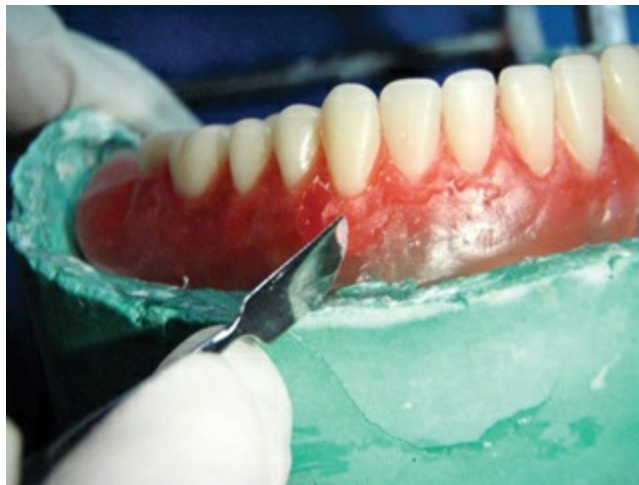

FIG 3.1.6.22 Carving the canine eminence

Wax the distolingual area of the lingual flange and blend it with the retromylohyoid space (Fig 3.1.6.23).

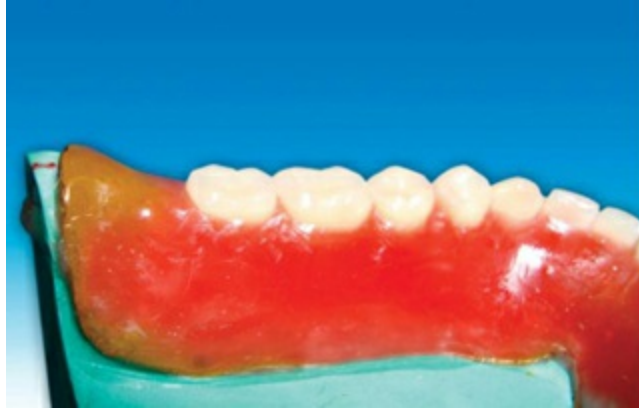

FIG 3.1.6.23 Wax up of the lingual flange region

The lingual flange has to have an inclined plane to accommodate the tongue (Fig 3.1.6.24).

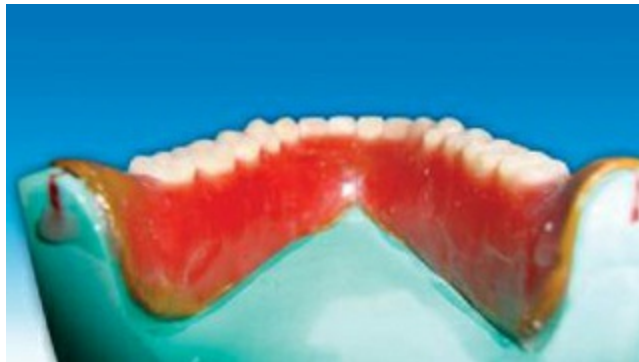

FIG 3.1.6.24 Lingual flange of the waxed trial denture

Use a gas torch or a Bunsen burner to flame the wax surface taking care not to overheat the wax contours (Fig 3.1.6.25). Stipple the region of attached gingiva with a modified bristle brush.

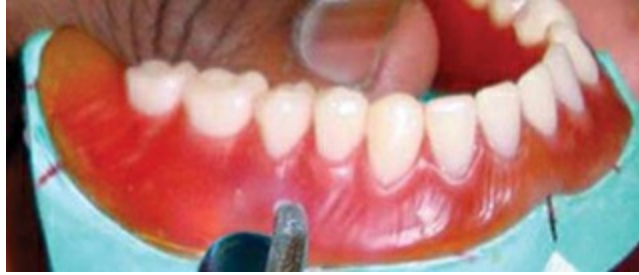

FIG 3.1.6.25 Softening the gingival margin

The completed wax up of the mandibular trial denture is depicted in [Figure 3.1.6.26](#).

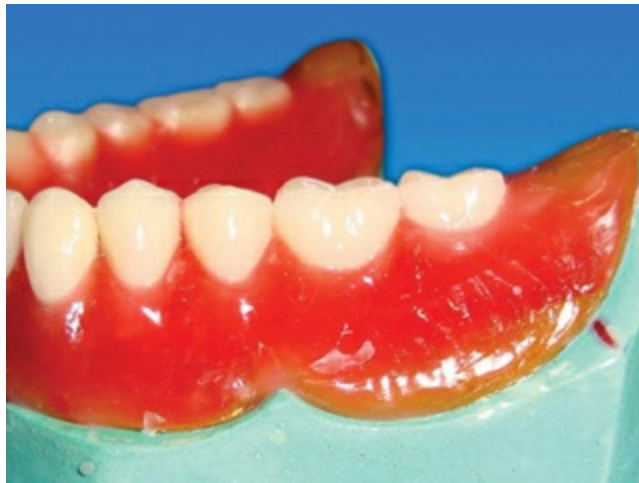

FIG 3.1.6.26 Completed wax up of the lower trial denture

Finally check the occlusion before proceeding to flasking ([Fig 3.1.6.27](#)).

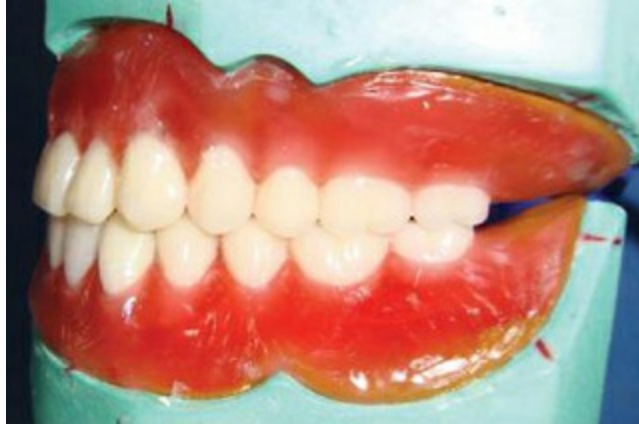

FIG 3.1.6.27 Completed wax up in the articulator

3.1.7. Processing of the waxed dentures

Armamentarium (Fig 3.1.7.1)

- Maxillary trial denture
- Mandibular trial denture
- Wax spatula
- Wax sheet
- Gas torch
- Plaster knife
- Hammer
- Flasks—upper
- Lower flask
- Vaseline
- Type II stone plaster
- Rubber bowl
- Spatula
- Sandpaper
- Cotton
- Wax carver
- Wax knife
- Separating medium
- Brush



FIG 3.1.7.1 Armamentarium

Check the occlusion and correct the occlusal errors before sealing the waxed denture to the master cast. Seal the upper trial denture to the upper cast by adding molten wax with the wax spatula ([Fig 3.1.7.2](#)).

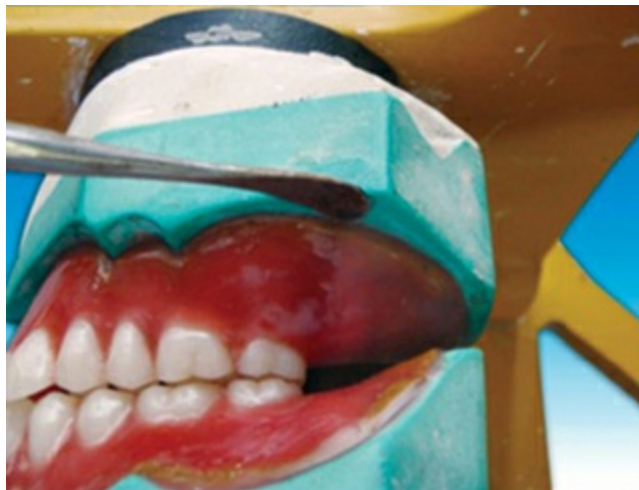

FIG 3.1.7.2 Sealing the waxed maxillary trial dentures

The waxed mandibular trial denture is sealed to the mandibular cast by adding molten wax with wax spatula ([Fig 3.1.7.3](#)).

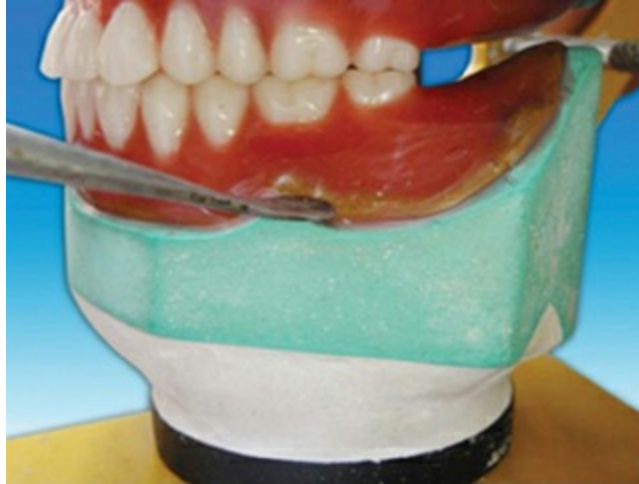

FIG 3.1.7.3 Seal the mandibular trial denture to the lower cast

Dearticulate the upper and lower trial dentures from the mounting plaster of the articulator. Lubricate the base of the cast with the Vaseline before flasking to facilitate easy deflasking after processing (Fig 3.1.7.4).

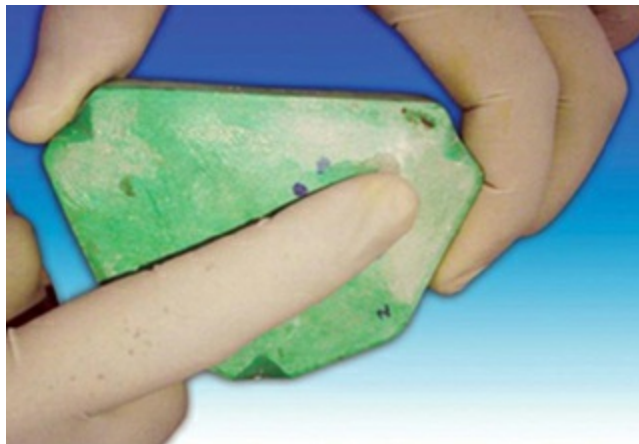


FIG 3.1.7.4 Application of separating medium

Select an appropriate dental flask by placing the trial denture into it. Check for the height of cast with artificial denture teeth in the flask (Fig 3.1.7.5). There should be sufficient clearance from the occlusal surface of the artificial teeth to the top rim of the body of the flask. There should be a minimum 628 mm of clearance from the land area

of the cast to inner aspect of the body of the flask when viewed from top.

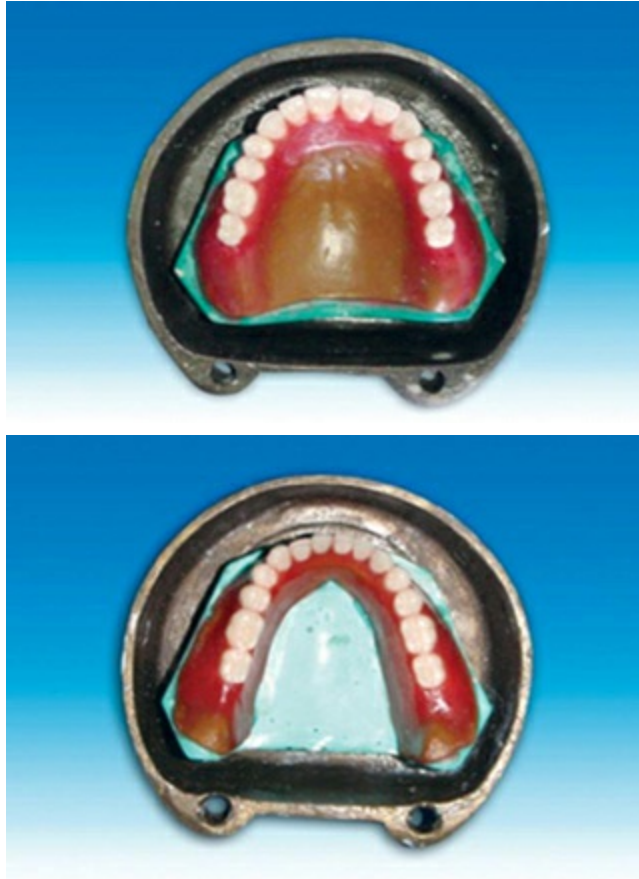

FIG 3.1.7.5 Checking the size of the flask

Type II dental plaster is mixed with right proportion [w:p 30cc 100 g, mixed for 30 seconds and vibrated for 15 seconds] and is poured in the base (lower half) of the flask (Fig 3.1.7.6).

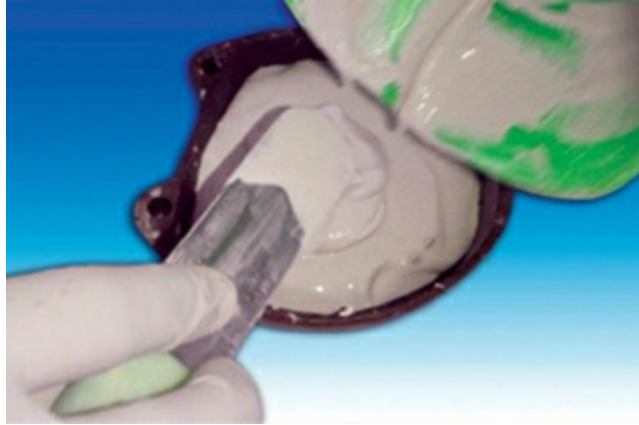

FIG 3.1.7.6 Dental plaster poured into the base of the flask

Place and press the trial denture with cast into the base of the flask and position it to the centre of base of the flask as shown in [Figure 3.1.7.7](#).

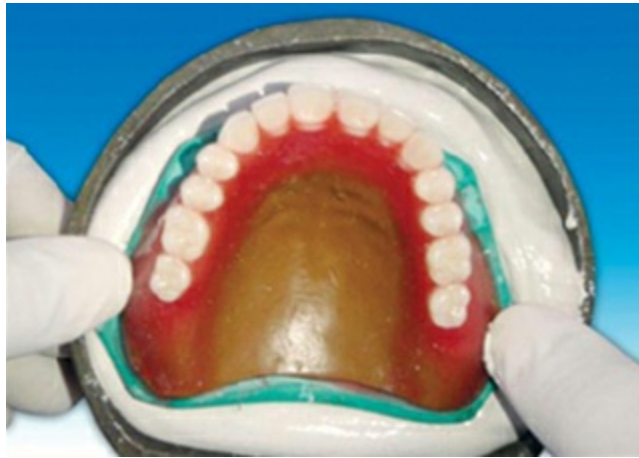

FIG 3.1.7.7 Position the maxillary waxed denture with the cast

Keep the occlusal plane approximately parallel to the base of the flask. Make sure the heel of lower cast should be at 45° angle in relation to the rim of the flask. Care should be taken not to create any undercuts ([Fig 3.1.7.8](#)).

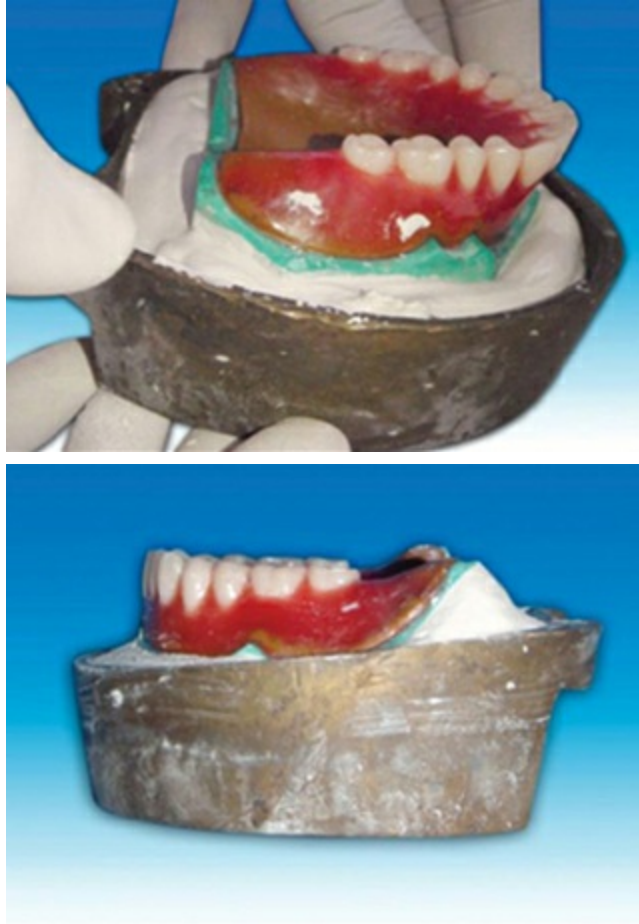

FIG 3.1.7.8 Maxillary and mandibular waxed dentures in the base of the flask

Remove the excess dental plaster as necessary and fill in any deficient areas as shown in [Figure 3.1.7.9](#) before the initial set of the dental plaster.

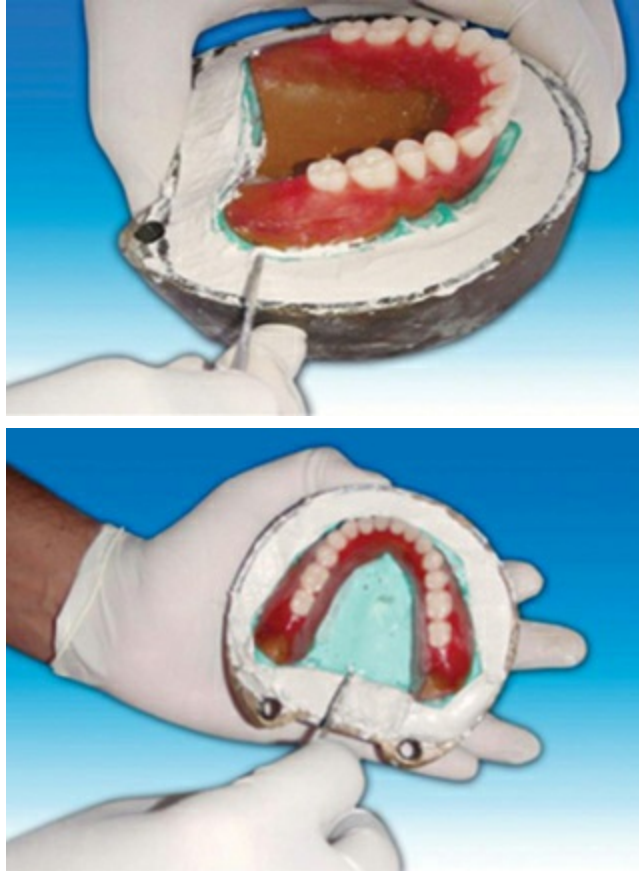

FIG 3.1.7.9 Removal of excess dental plaster

Smoothen the surface of the dental plaster with a cotton after its initial set ([Fig 3.1.7.10](#)).

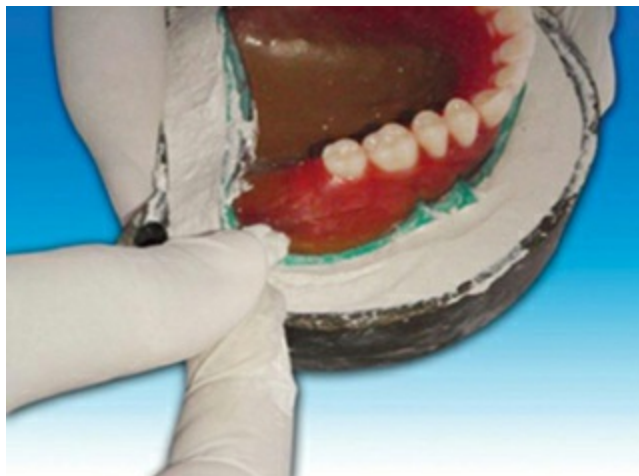

FIG 3.1.7.10 Smoothing the surface

Further smoothing is done by the emery paper (Fig 3.1.7.11). Make sure there are no remnants of dental plaster on the rim of the flask.

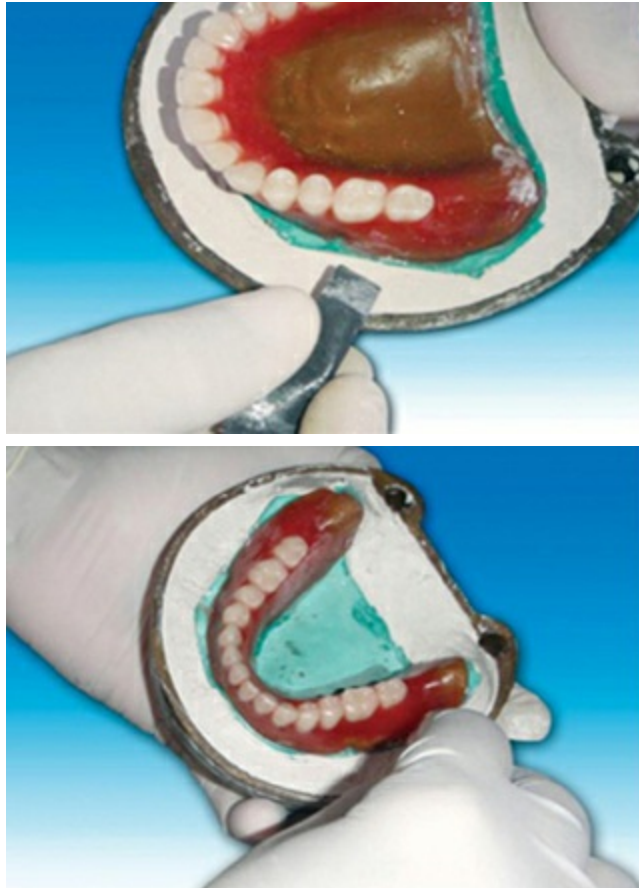

FIG 3.1.7.11 Smoothing the dental plaster with the emery paper

Figure 3.1.7.12 depicts completed lower half flasking of the maxillary and mandibular casts with waxed denture.

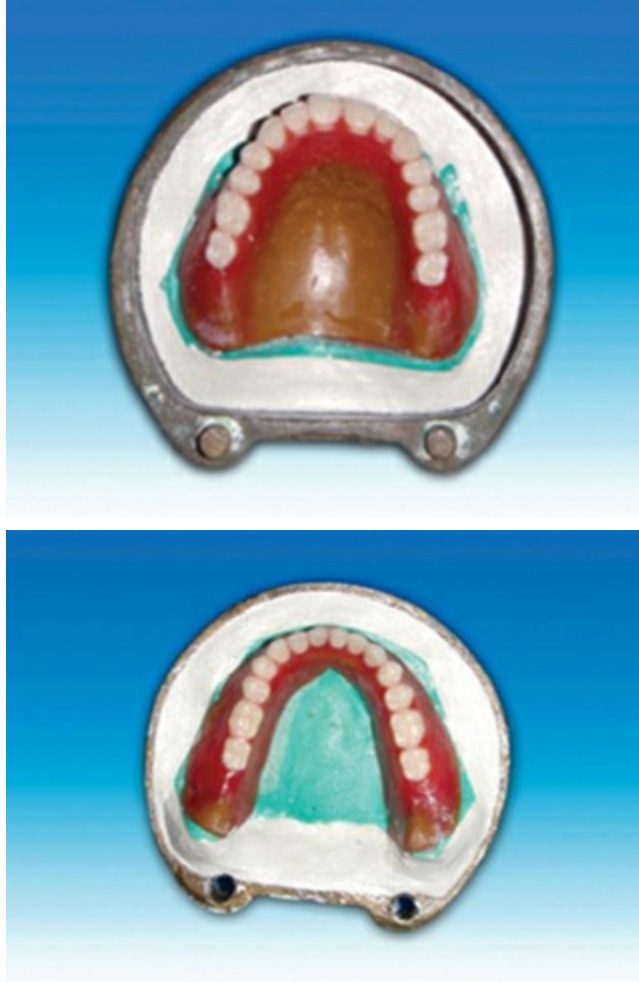

FIG 3.1.7.12 Upper and lower casts with the waxed denture in the base of the flask

Place the top half of the flask into position and check for its complete seating and verify the incisal edges and occlusal surfaces of denture teeth are within the top half of the flask ([Fig 3.1.7.13](#)).

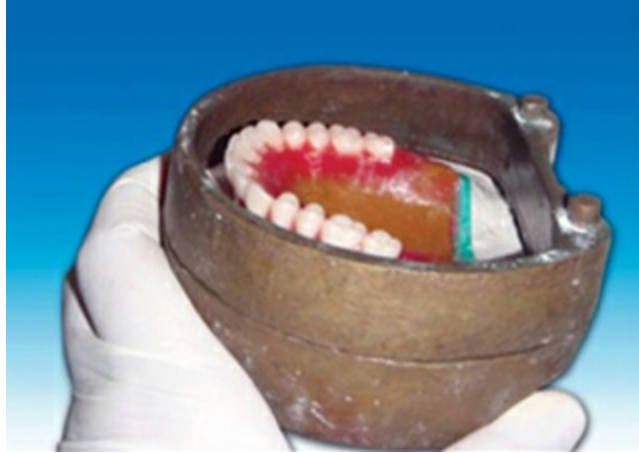

FIG 3.1.7.13 Check for clearance with top half of the flask

Apply the separating medium all over the plaster surface (Fig 3.1.7.14). Avoid applying it over the wax surface and denture teeth.

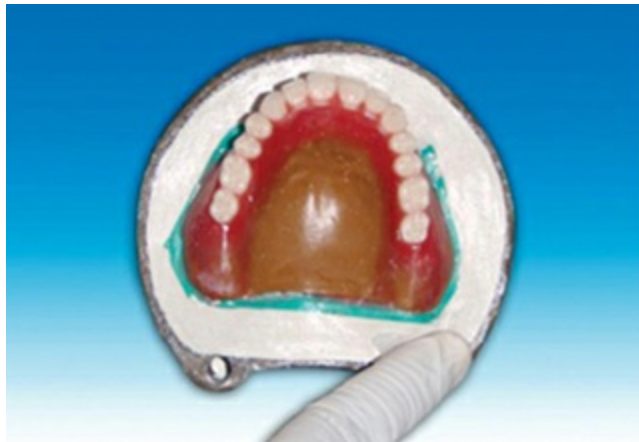

FIG 3.1.7.14 Application of separating medium

Place the upper half of the flask (Fig 3.1.7.15). Make a proper mix of Type II plaster and start pouring into the flask.

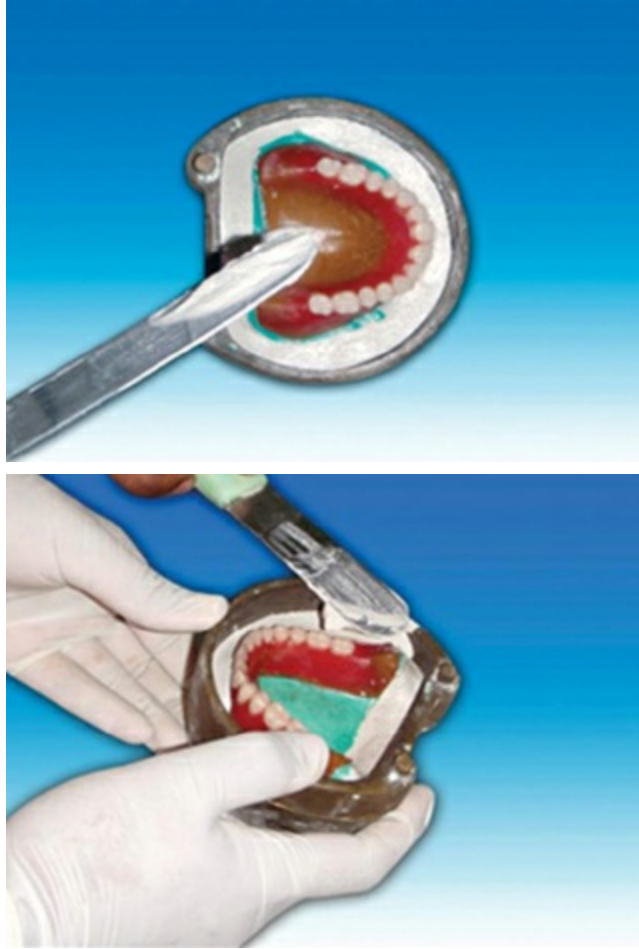
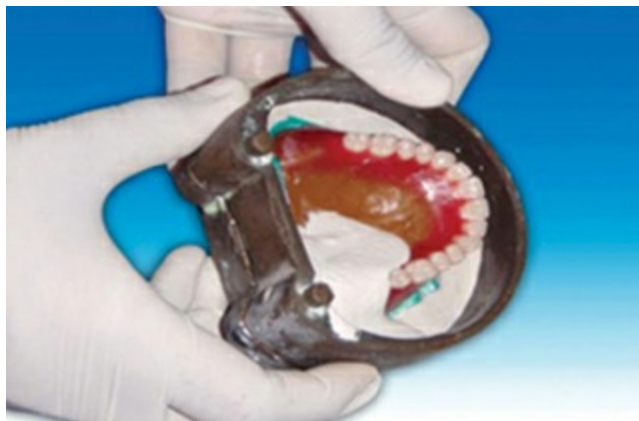

FIG 3.1.7.15 Flasking the top half of the flask

Fill the top half of the flask with the dental plaster and pour it from one side to avoid air entrapment (Fig 3.1.7.16).



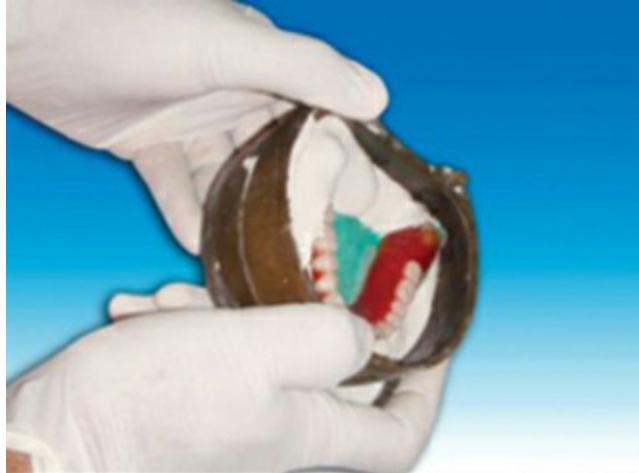


FIG 3.1.7.16 Mixed dental plaster is poured

Vibrate the flask and make sure the stone plaster flows and fills everywhere without air entrapment ([Fig 3.1.7.17](#)).

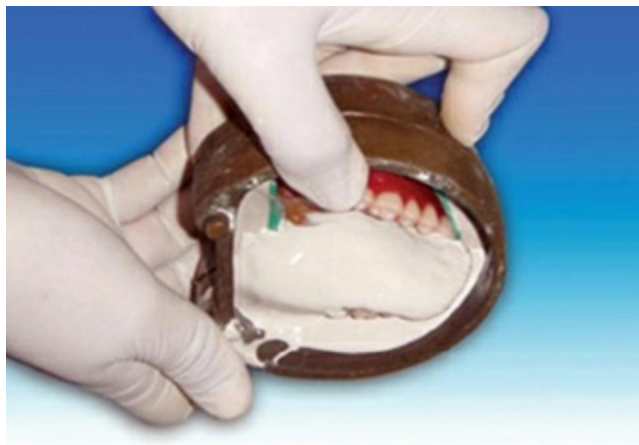

FIG 3.1.7.17 Spreading the mixed plaster uniformly

Fill the top half of the flask till the incisal and occlusal surfaces of the denture teeth ([Fig 3.1.7.18](#)).



FIG 3.1.7.18 Dental plaster is removed from the occlusal surface of the artificial teeth

Remove the dental plaster with a finger to expose the occlusal surfaces of the denture teeth ([Fig 3.1.7.19](#)).



FIG 3.1.7.19 Occlusal surface is exposed

Once the dental plaster sets initially, mix the Type III dental plaster and fill the top surface of the flask ([Fig 3.1.7.20](#)).

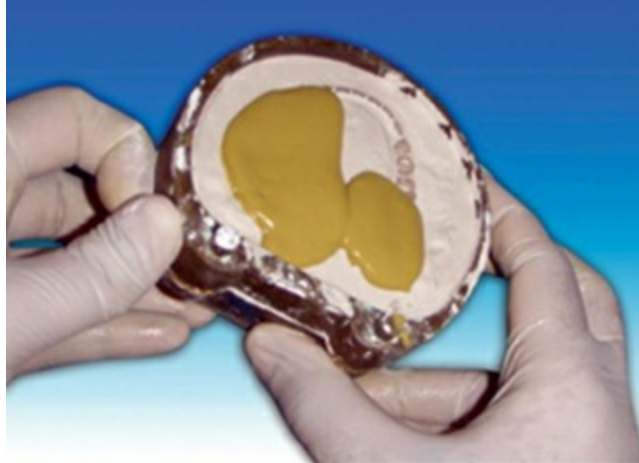

FIG 3.1.7.20 Pouring the dental stone

Fill it completely with Type III dental plaster ([Fig 3.1.7.21](#)).

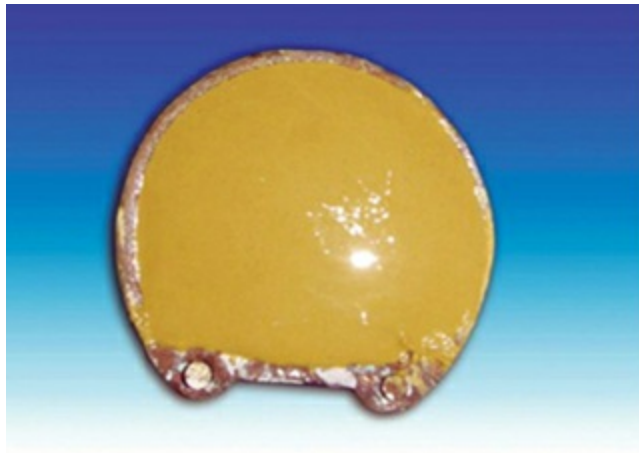


FIG 3.1.7.21 Type III plaster on the top surface

Place the lid on the filled flask and tap it gently. The excess material flows out through the vents in the lid. The excess of the dental plaster is removed ([Fig 3.1.7.22](#)).



FIG 3.1.7.22 Place the lid of the flask in the upper and lower flasks

Remove all the excess dental plaster material ([Fig 3.1.7.23](#)).

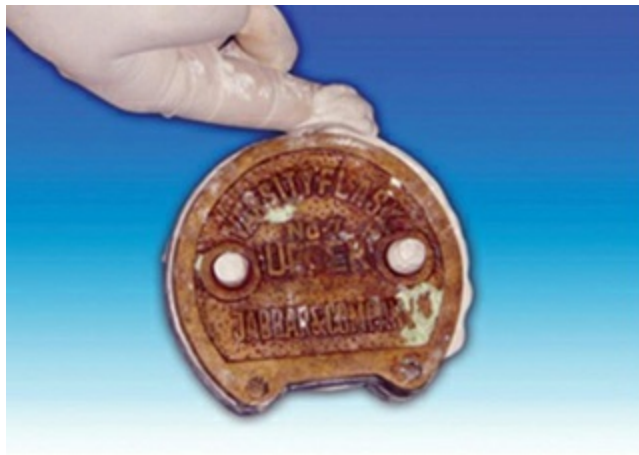

FIG 3.1.7.23 Removing the excess

Place the flask in the clamp assembly and tighten it ([Fig 3.1.7.24](#)).



FIG 3.1.7.24 Assemble the flask in the clamp

Clean the flask under the running tap water ([Fig 3.1.7.25](#)).



FIG 3.1.7.25 Clean the flask

Flasking is completed and allow for the material to set. The flask is ready for dewaxing after 30 min ([Fig 3.1.7.26](#)).



FIG 3.1.7.26A,B Upper and lower flasks with the clamp

Wax elimination

The flask with the clamp assembly is placed in the boiling water for 3–5 minutes ([Fig 3.1.7.27](#)).



FIG 3.1.7.27 Flasks with clamp in the dewaxing bath

After 3–5 min, flask is removed from the clamp assembly and placed in dewaxing tray (Fig 3.1.7.28).



FIG 3.1.7.28 Upper flask placed in the dewaxing tray

The plaster knife is positioned between the body and base of the flask (between the top half and bottom half of the flask). Pry it open with a plaster knife (Fig 3.1.7.29).



FIG 3.1.7.29A, B Opening the flask

Discard the softened wax and carefully remove the softened baseplate as shown in the [Figure 3.1.7.30](#).





FIG 3.1.7.30 Removal of the molten wax and softened baseplate

Clean boiling water is poured over the cast surface and on the denture teeth to eliminate all traces of wax on the cast surface and mould surface ([Fig 3.1.7.31](#)).





FIG 3.1.7.31 Pouring clean boiling water

A brush and a soap or detergent solution is used to clean the cast surface and the mould surface (Fig 3.1.7.32).



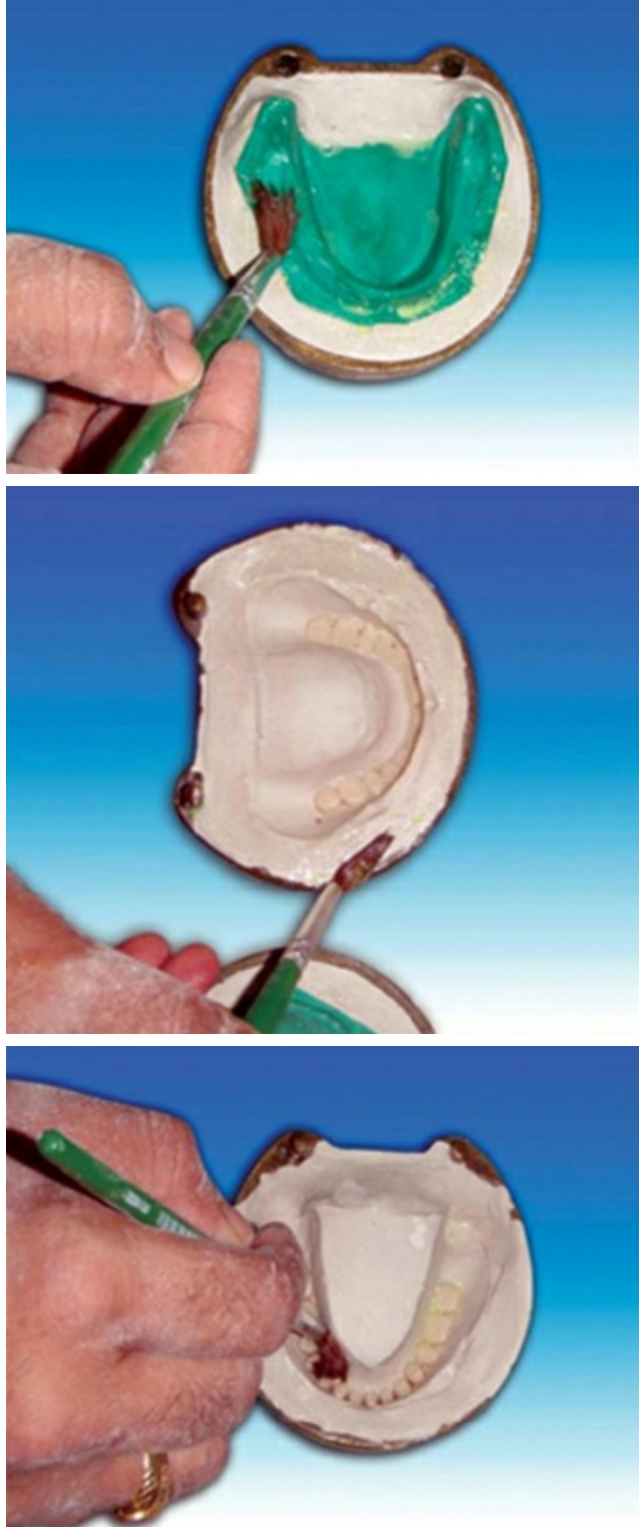

FIG 3.1.7.32 Application of soap solution

The soap solution is removed from the cast surface and the mould with clean water ([Fig 3.1.7.33](#)).

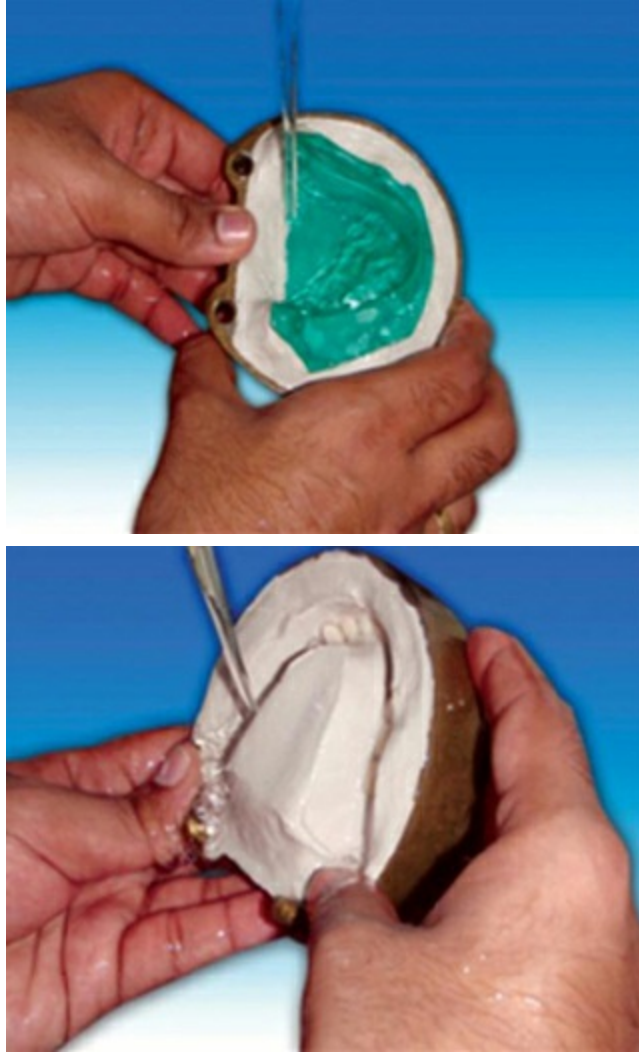

FIG 3.1.7.33 Removal of soap solution

Carefully paint the separating medium on the stone surface in the flask when it is warm and wet (Fig 3.1.7.34). Allow it to dry. Only one coat of separating medium should be applied on tissue surface of the cast and two coats on the opposite surface of the flask containing denture teeth. Application of separating medium should be done in one direction only. When the brush stroke is given to and fro, it removes the thin layer of calcium alginate which will act as the separating layer. Do not paint the separating medium on the tooth surface.

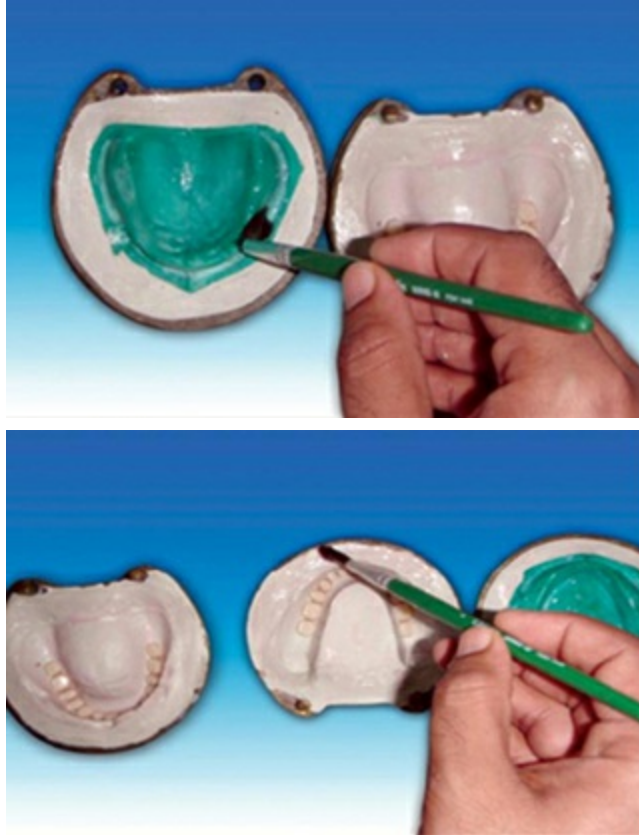
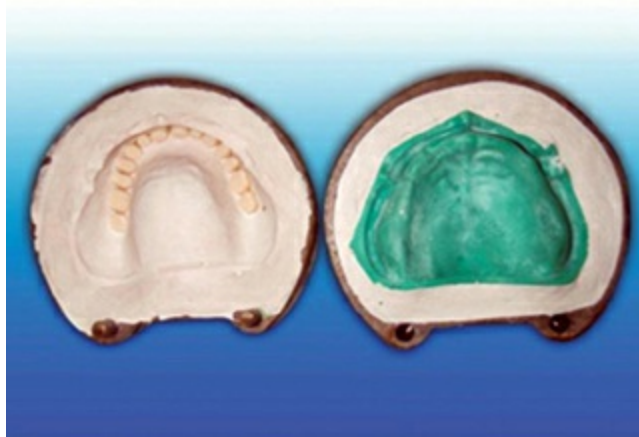

FIG 3.1.7.34 Application of separating medium

Allow the flask to cool and the separating medium should be completely dry ([Fig 3.1.7.35](#)).



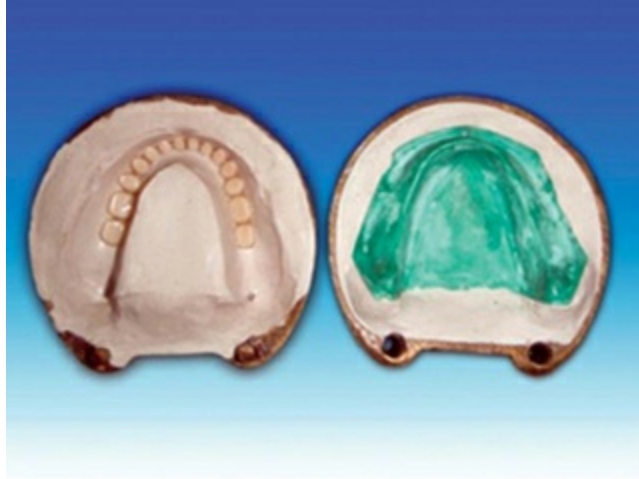

FIG 3.1.7.35 Upper and lower flasks ready to be packed

Packing the mould

Mix the resin in a clean mixing jar with a stainless steel spatula ([Fig 3.1.7.36](#)). The mixed resin has 5 physical stages, like sandy, stringy, dough-like, rubbery and stiff or plastic ([Figs 3.1.7.37–3.1.7.41](#)). The ideal stage to pack the mould is the dough stage. It is important to identify the third dough stage. The mixed resin in the jar when cut into two halves does not collapse together or when the material is removed from the jar it does not stick to the walls of the porcelain jar as shown in [Figure 3.1.7.39](#).

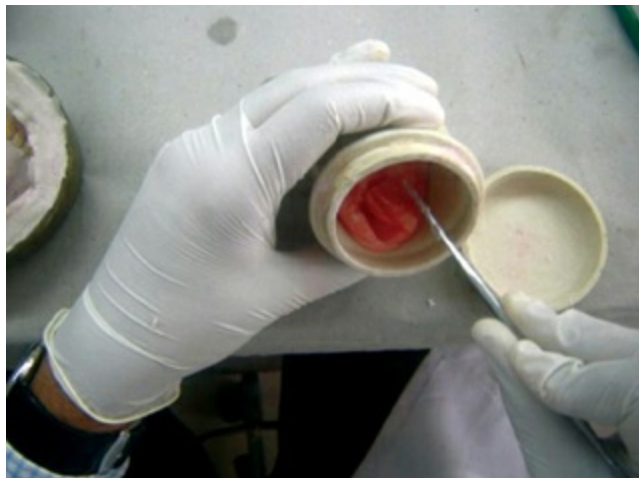

FIG 3.1.7.36 Select an appropriate denture base resin and mix it according to the manufacturer's instructions [powder to liquid ratio 3:1 by volume]



FIG 3.1.7.37 Sandy stage

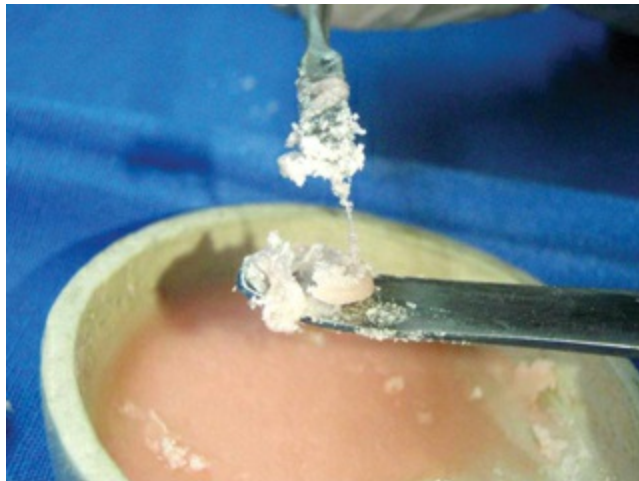

FIG 3.1.7.38 Stringy stage

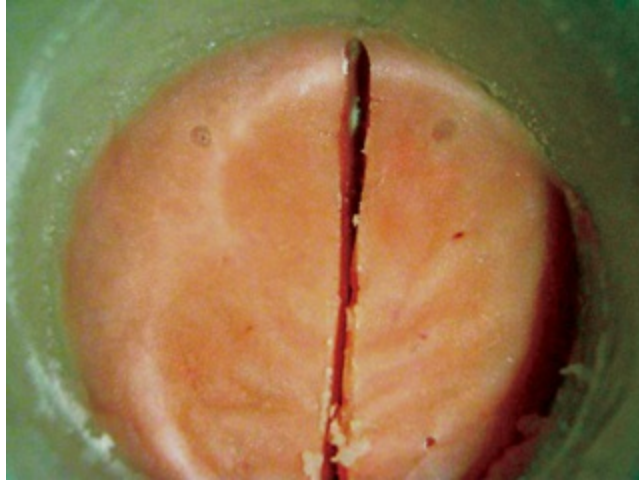

FIG 3.1.7.39 Dough stage

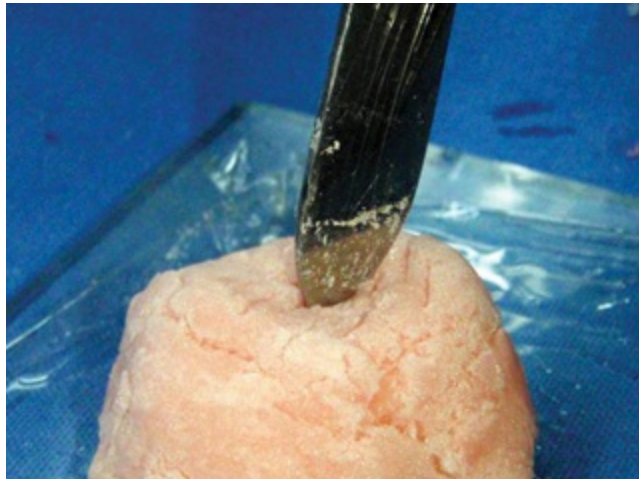


FIG 3.1.7.40 Rubbery stage

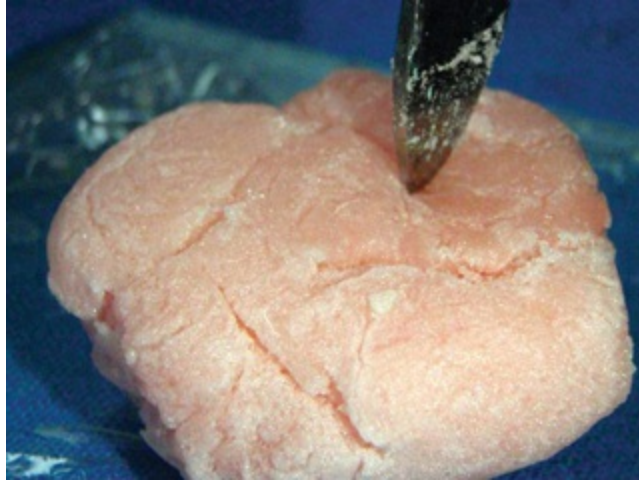

FIG 3.1.7.41 Plastic stage

Physical stages of polymerization

Close the jar with a lid to prevent evaporation of monomer and wait till it reaches the dough stage (Figs 3.1.7.37–3.1.7.39).

After the resin has reached the dough stage, remove it with gloved hands to prevent contamination (Figs 3.1.7.40–3.1.7.42).

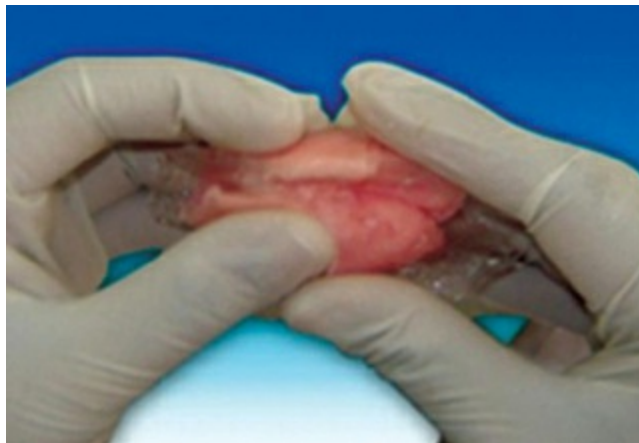


FIG 3.1.7.42 Manipulation of dough

The resin dough is adapted slowly into the mould of the flask (Fig 3.1.7.43).

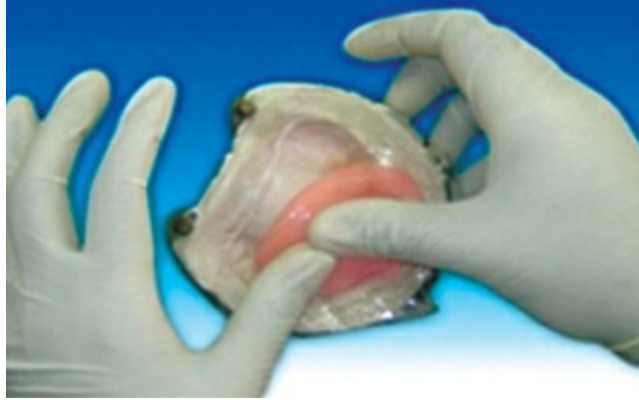

FIG 3.1.7.43 Resin dough placed in the mould

Place the wet cellophane sheets over the resin dough in the mould of the flask (Fig 3.1.7.44).

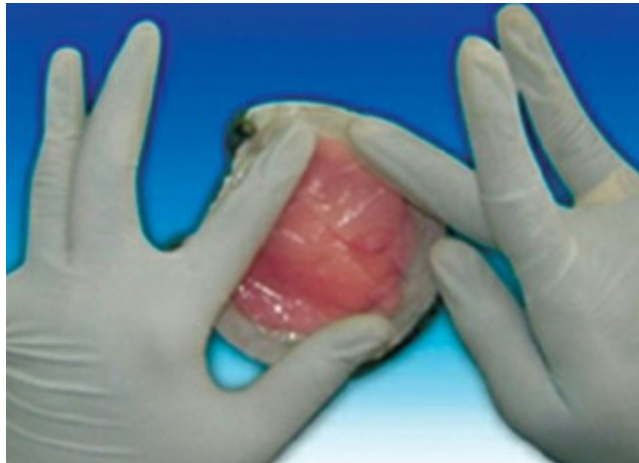


FIG 3.1.7.44 Placing wet cellophane sheet

Place the second half of the flask over the wet cellophane sheet in position as shown in Figure 3.1.7.45 and close the flask completely.

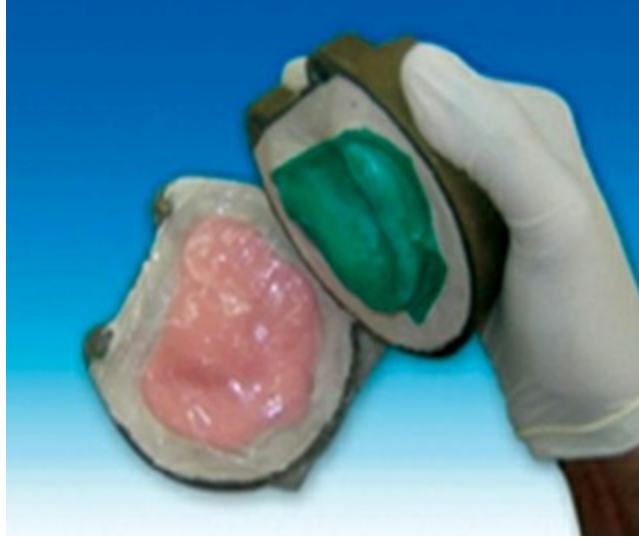

FIG 3.1.7.45 Positioning the cast on the mould

Compress the flask [1500 psi] slowly in a hydraulic bench press so that the excess resin material flows out. In the manual bench press, the bench press should be turned very slowly till the flash (the excess resin material) flows out between the upper and lower halves of the flask (Fig 3.1.7.46).



FIG 3.1.7.46 Initial trial closure

The flash material is removed and remove the flask from the clamp assembly and open the upper and lower half separately. Remove the

cellophane sheet (Fig 3.1.7.47).

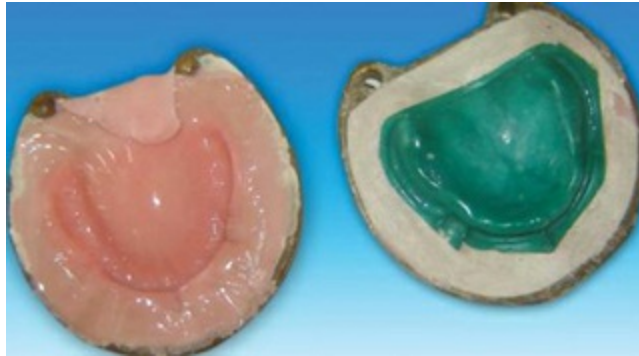

FIG 3.1.7.47 Removal of excess material

Remove the excess flash with a blunt knife without making a mark on the plaster surface (Fig 3.1.7.48).

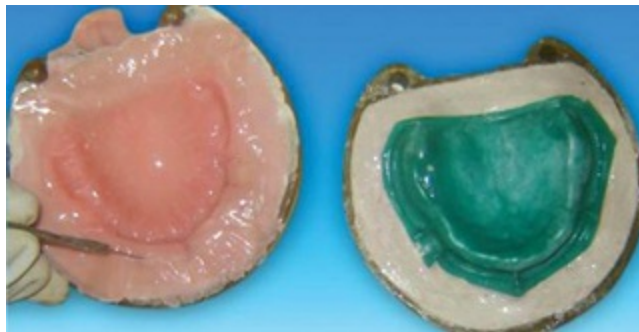

FIG 3.1.7.48 Flash is removed

The excess resin material is removed from all sides (Fig 3.1.7.49).

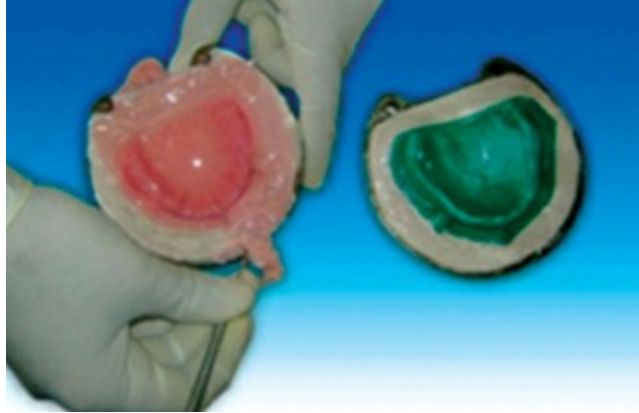

FIG 3.1.7.49 Excess resin material is removed

Continue trial packing till all the excess is removed. Apply another coat of separating medium on the stone surface before the final closure of the flask ([Fig 3.1.7.50](#)).

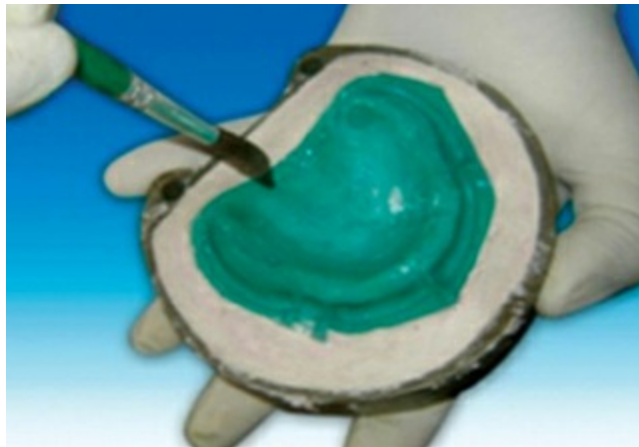

FIG 3.1.7.50 Application of separating medium

Do not place cellophane sheet when you close the upper and lower halves of the flask for the final closure ([Fig 3.1.7.51](#)).

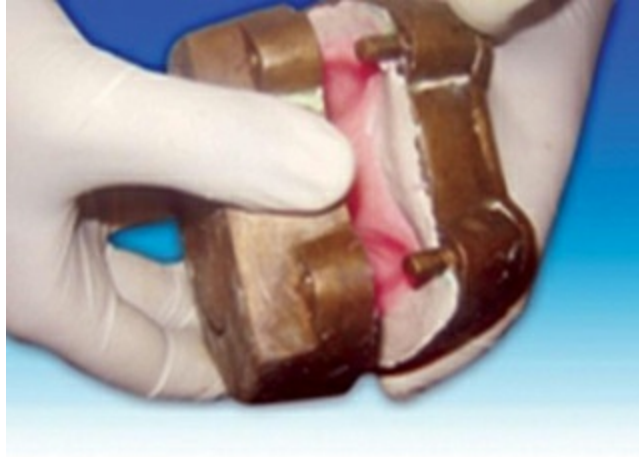

FIG 3.1.7.51 Final closure of the flask

Finally tighten the flask assembly under a pressure of [3500 psi] in a hydraulic bench press and in a manual bench press, the clamp is rotated slowly till the metallic rims of upper and lower rims of the flasks are in contact ([Fig 3.1.7.52](#)). The flask is kept in the bench press for 30 min before heat processing or polymerization. This is called bench set or bench cure.



FIG 3.1.7.52 Final closure of the flask

Heat processing cycle

After the bench set or bench cure, the flasks are removed and placed in the clamps. The flasks with the clamp are kept in the curing bath. The curing cycle can be short-term or long-term cycle. The short-term curing cycle is to maintain the temperature of the curing bath initially 1 and 1/2 hrs at 165°F followed by 30 minutes at a boil, followed by one hour of bench cooling before it is deflasked. The long-term curing cycle is to maintain the temperature of the water bath at 72–75 degrees F for 8 hours.

3.1.8. Finishing and polishing

Armamentarium (Fig 3.1.8.1)

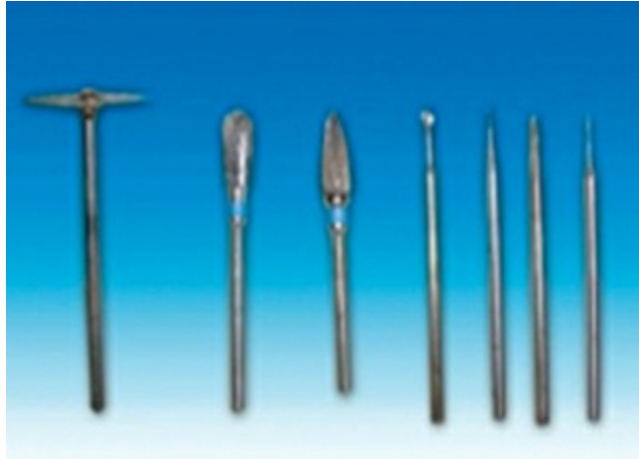

FIG 3.1.8.1 Armamentarium

- Maxillary denture with cast
- Mandibular denture with cast
- Plaster knife
- Hammer
- Saw blades with handle
- Shell blaster
- Arbor band
- Fissure bur
- Diamond disc
- Bard – Parker handle and no. 25 blade
- Sandpaper with mandrel
- Pumice
- Rag wheel
- Prophy cap
- No.200 finishing bur
- Brush and green soap

Deflasking

Remove the flask from the clamp and the lid from the flask (Fig 3.1.8.2).



FIG 3.1.8.2 Removal of flask from the clamp

A plaster knife is placed between the both halves of the flask and pry open the flask (Fig 3.1.8.3).



FIG 3.1.8.3 Separation of the upper and lower halves of the flask

Slowly tap the plaster surface to remove the stone enclosing the denture from the flask (Fig 3.1.8.4).

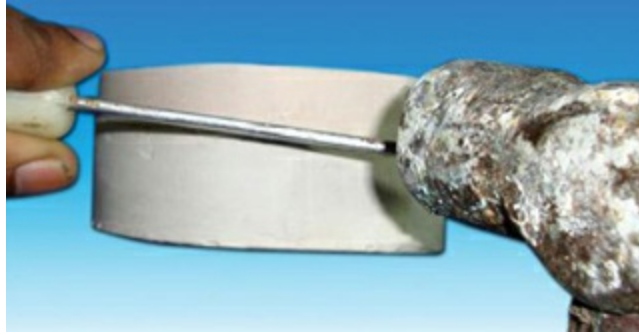

FIG 3.1.8.4 Removal of stone

Use saw blades and make several cuts at the stone surface. Gently remove the stone without damaging the dentures ([Fig 3.1.8.5](#)).



FIG 3.1.8.5 Removal of stone using saw blades

A shell blaster is used in removing stone from the interior of the denture. After removing the stone completely from denture surface, it is ready for polishing ([Fig 3.1.8.6](#)).

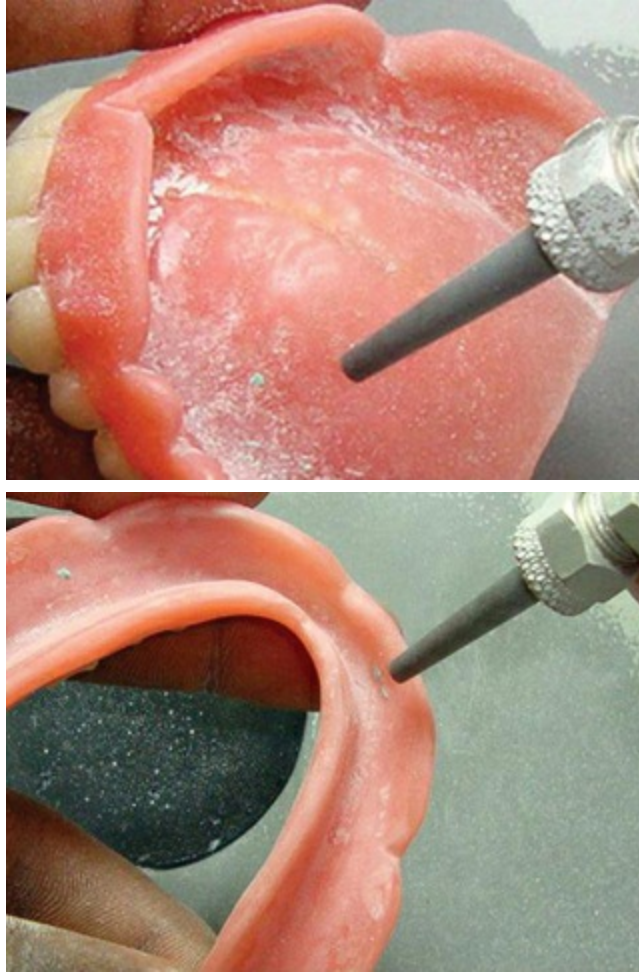

FIG 3.1.8.6 Removal of residual stone from the tissue surface of the denture

Polishing

Round end acrylic trimmer mounted on a micromotor straight handpiece is used to trim the excess borders of the maxillary and mandibular dentures ([Fig 3.1.8.7](#)).

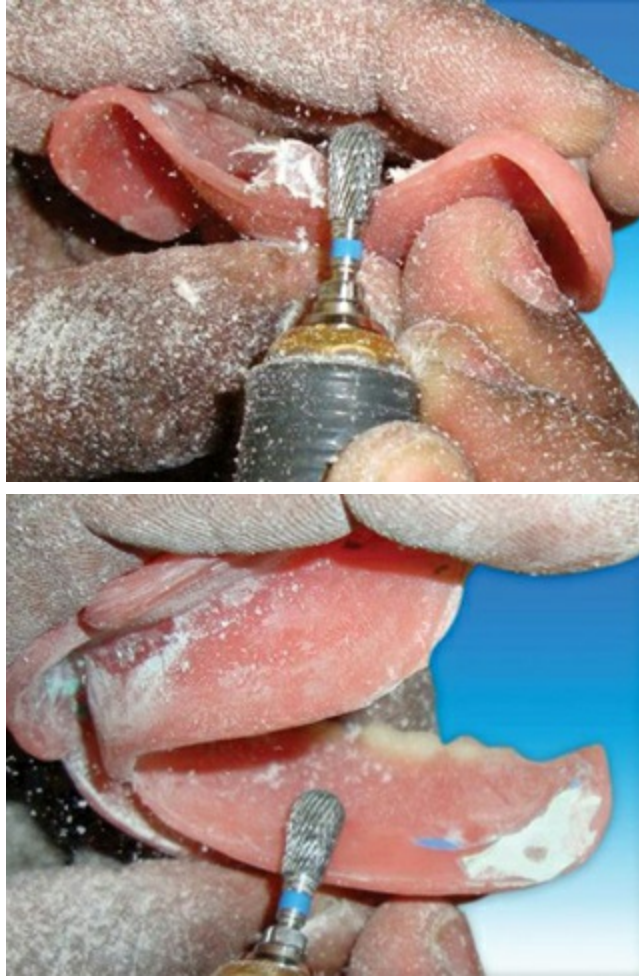

FIG 3.1.8.7 Trimming the dentures

The borders and the flanges of the denture are smoothed with aluminium oxide mounted acrylic trimmers ([Fig 3.1.8.8](#)).

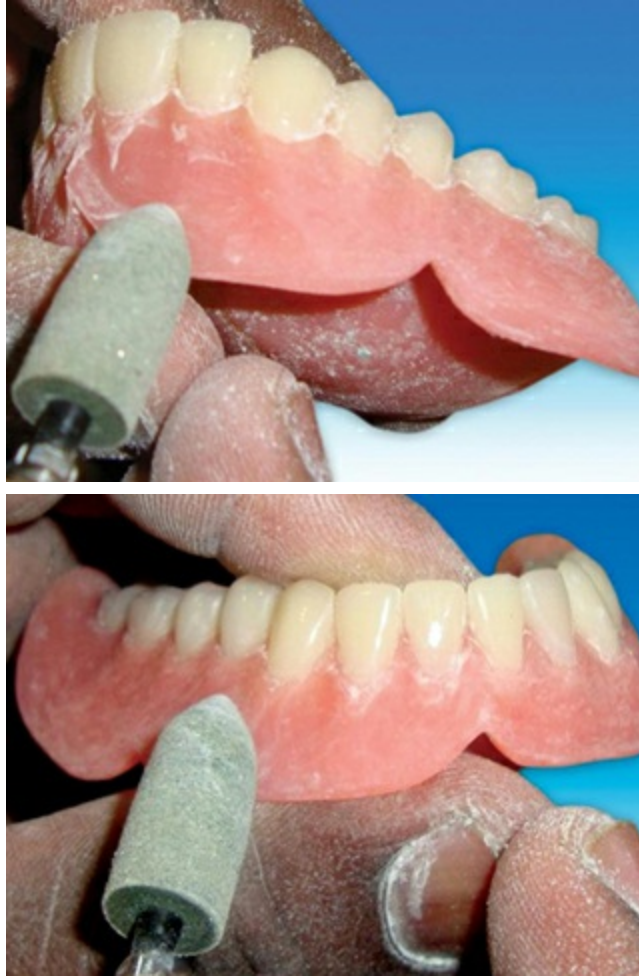

FIG 3.1.8.8 Smoothing the denture surface

Relief for the labial and buccal frenum is given with help of straight fissure bur and diamond disc mounted in straight micromotor handpiece (Fig 3.1.8.9).

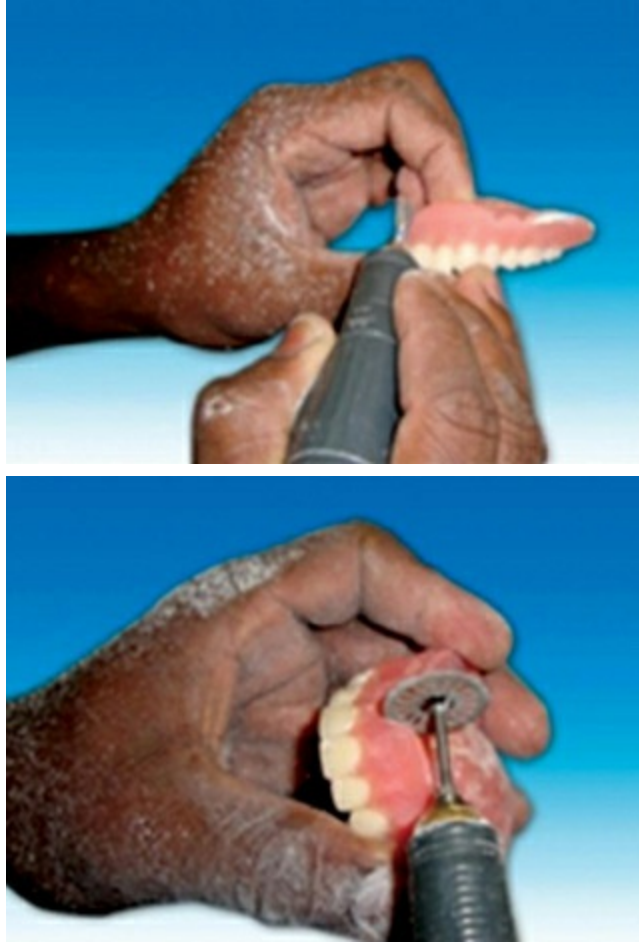

FIG 3.1.8.9 Relief for labial and buccal frenum

With the help of a small round bur in a straight micromotor driven handpiece, residual plaster or stone is removed from the gingival margins ([Fig 3.1.8.10](#)).

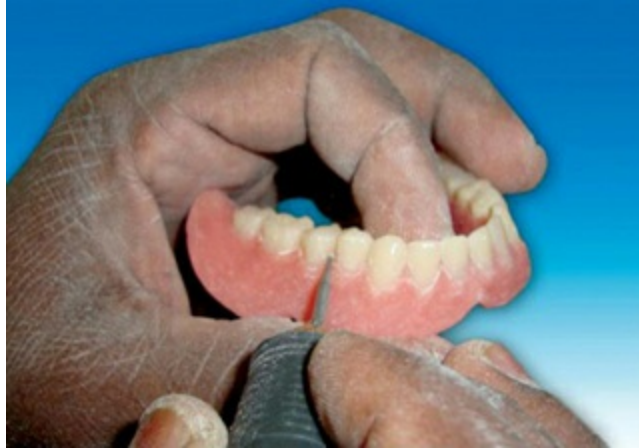
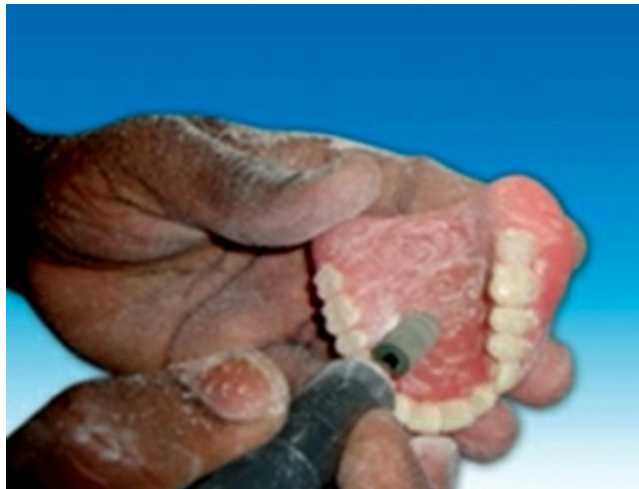
FIG 3.1.8.10 Removal of stone from gingival margins

Use a rubber point mounted on a mandrel on a micromotor to remove scratches from the denture base and use sandpaper mounted on a mandrel attached to a micromotor to remove finer scratches ([Fig 3.1.8.11](#)).



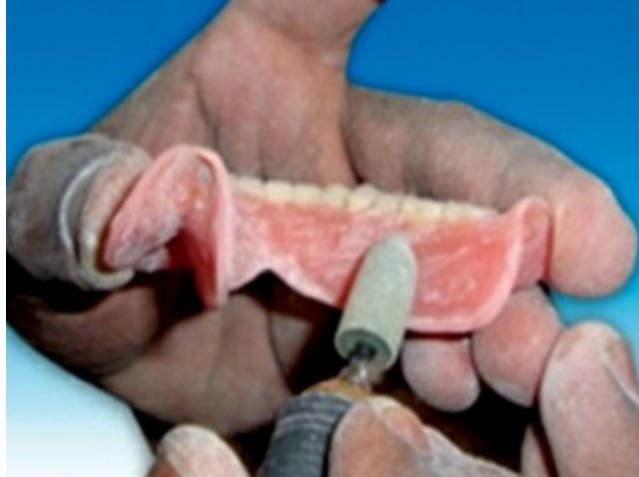
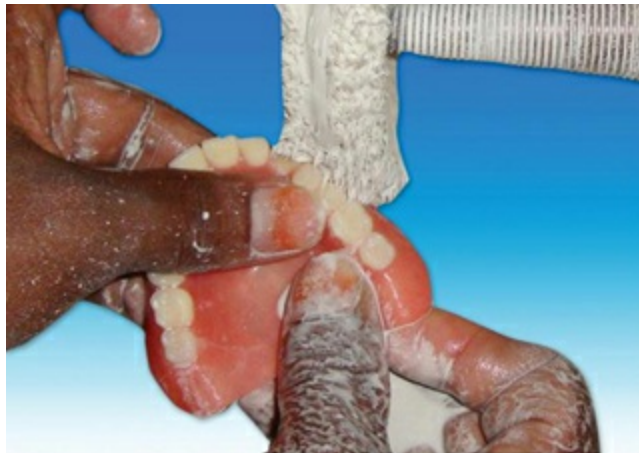
FIG 3.1.8.11 Removal of scratches from the denture base

Pumicing the denture

Make a slurry of fine flour of pumice with water using copious amounts of slurry with rag wheel polish of the denture at low speed (Fig 3.1.8.12).



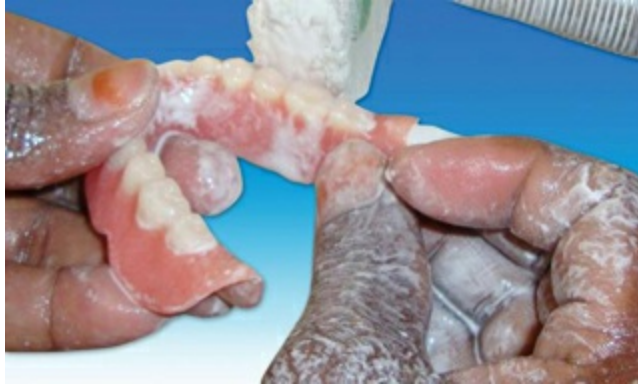

FIG 3.1.8.12 Slurry of pumice for polishing the dentures

Polish the palate and other areas of the denture which are not accessible to rag wheel with a prophy cap and slurry of pumice (Fig 3.1.8.13).

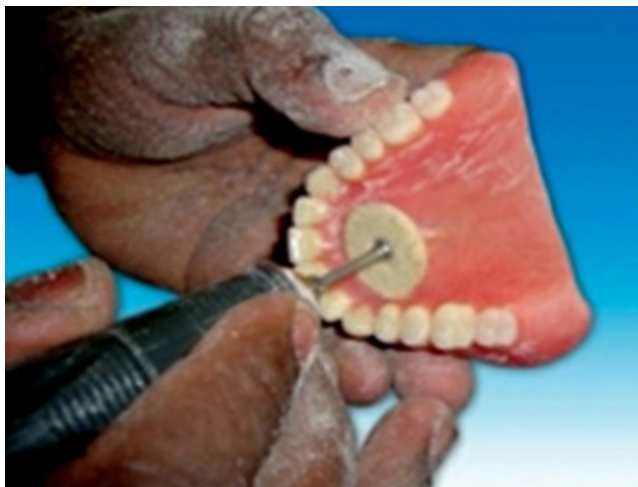

FIG 3.1.8.13 Polishing the palatal surface

Wash the denture thoroughly, dry it and examine it for any scratches. If scratches are found, repeat the pumicing (Fig 3.1.8.14).

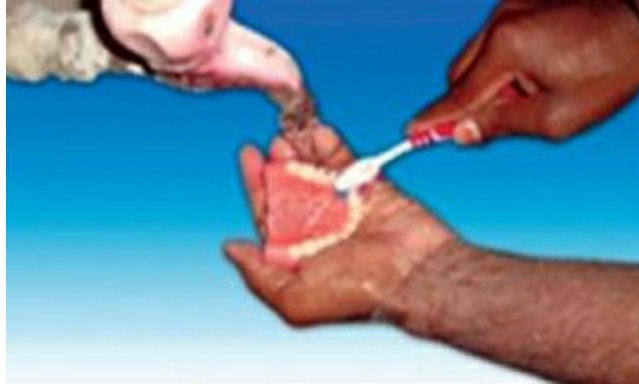

FIG 3.1.8.14 Washing the dentures

Using polishing cake and a modified rag wheel pumice the denture to set a high shine ([Fig 3.1.8.15](#)). Clean the denture surface with soap to remove all traces of polishing material. Examine the denture for any scratches. If found, repeat the pumicing procedures. Rinse the denture in water and store it in a plastic container of water till needed.



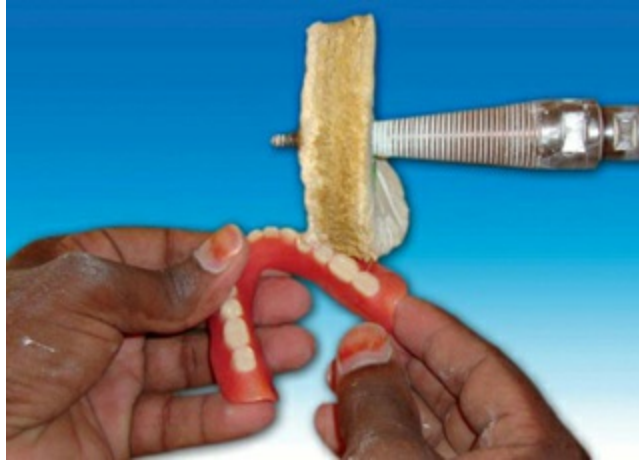

FIG 3.1.8.15 Polishing the denture surface with polishing cake

Figures 3.1.8.16 and 3.1.8.17 depict finished and polished surface of the denture.

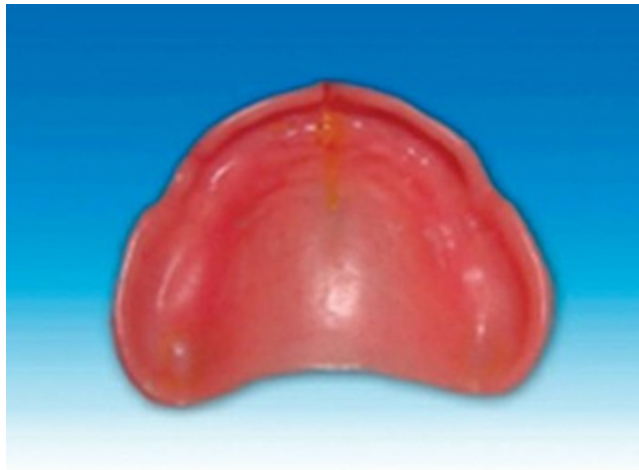



FIG 3.1.8.16 Tissue surface of the finished maxillary and mandibular dentures

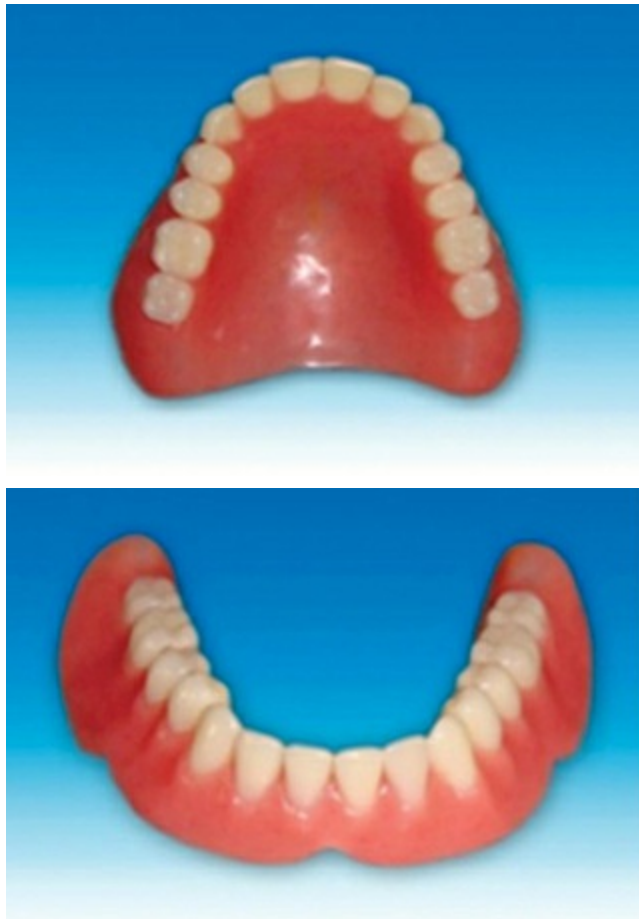

FIG 3.1.8.17 Polished surface of the maxillary and

mandibular dentures

3.2. Repair of fractured lower complete denture

Fracture of the complete dentures is a common problem. The fracture of the denture can occur during function or when accidentally dropped by the patient. Repair of fractured complete dentures can be done with the repair resins (auto-polymerizing acrylic resins). The procedure for repair of fractured dentures involves the following steps:

1. Preparation of a working cast

- Assemble the fractured parts of the denture.
- Stabilization of the fractured parts.
- Application of petrolatum jelly.
- Pouring the working cast in plaster.
- Making a base of the working cast.
- Removal of the working cast from the denture.

2. Repair work with repair resin

- Preparation of the denture.
- Beveling the fractured site.
- Application of separating medium on the working cast.
- Manipulation of repair resin.
- Pouring of the resin in the fractured site.
- Finishing of the denture.

Armamentarium (Fig 3.2.1)

1. Repair resin (pink)
2. Separating medium
3. Petrolatum jelly
4. Sticky wax
5. Cyanoacrylate
6. Sandpaper
7. Emery sheet
8. Matchsticks

9. Dental plaster
10. Rubber bowel spatula
11. Plaster knife
12. Glass plate
13. Dappen dish
14. Acrylic bur
15. Micromotor

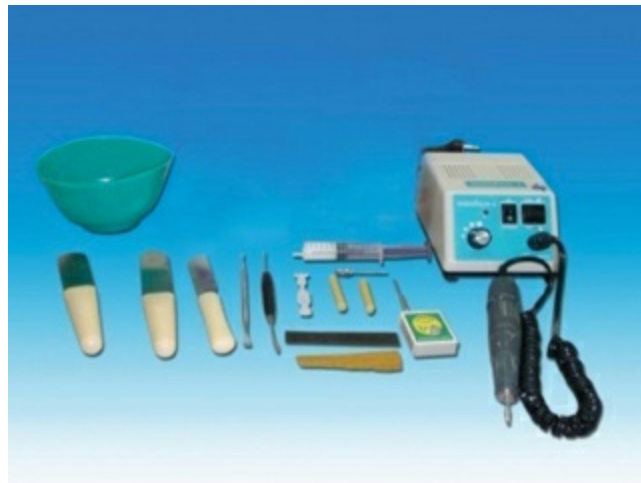

FIG 3.2.1 Armamentarium

Step: I preparation of a working cast

Lower complete denture is fractured at the midline of the denture ([Fig 3.2.2](#)).

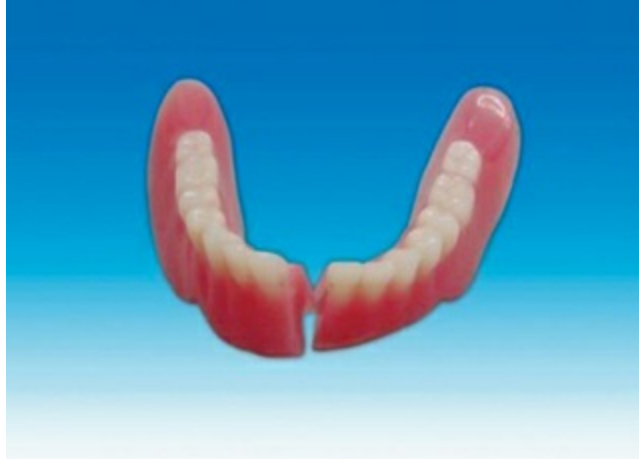

FIG 3.2.2 Fractured denture

The fractured pieces of the complete denture have to be assembled with the help of cyanoacrylate (Fig 3.2.3).

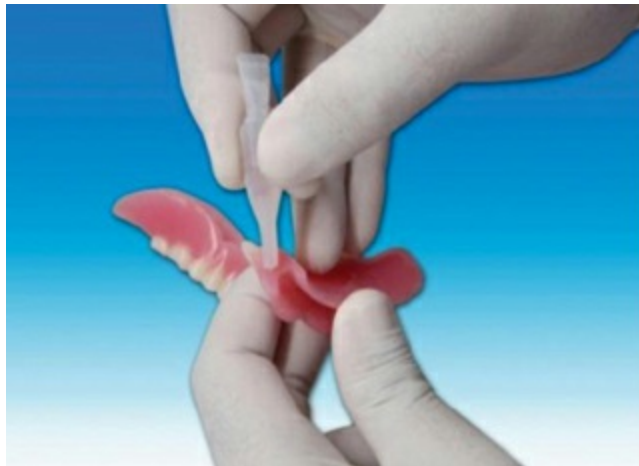

FIG 3.2.3 Assembling the fractured parts with cyanoacrylate

The assembled lower denture is further stabilized with the help of matchsticks and the sticky wax (Fig 3.2.4). The matchstick is placed on the occlusal surface of the denture teeth and is sealed with sticky wax so that the fractured denture pieces are further stabilized before making a working cast for doing the repair work.

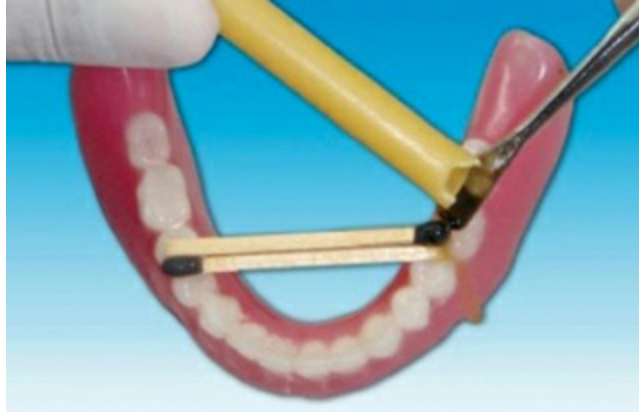

FIG 3.2.4 Stabilization of the fractured denture

After the stabilization of the denture, the tissue surface of the fractured lower denture is coated with petrolatum jelly with the help of a brush before making the working cast in model plaster (Fig 3.2.5).

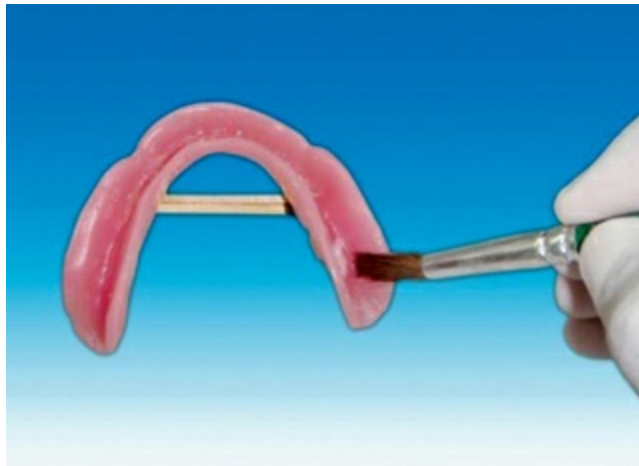

FIG 3.2.5 Application of petrolatum jelly

Model plaster is mixed with water in an appropriate proportion using a rubber bowl and spatula (Fig 3.2.6).



FIG 3.2.6 Mixing of dental plaster in a rubber bowl with spatula

The mixed plaster is poured with the wax knife onto the tissue surface of the stabilized fractured denture to make a working cast ([Fig 3.2.7](#)).

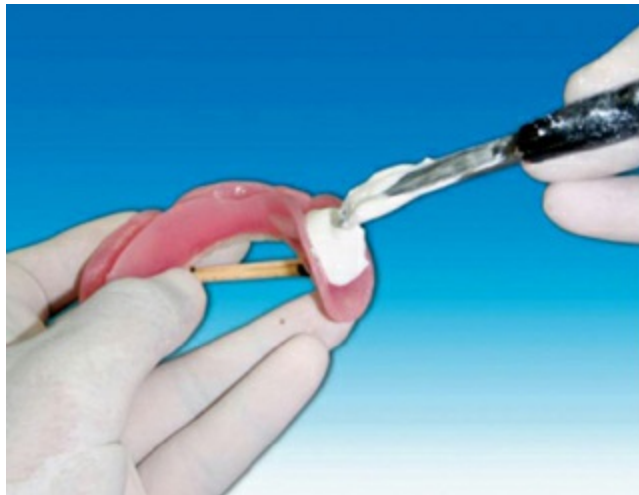

FIG 3.2.7 Pouring the dental plaster into tissue surface

The remaining mixed dental plaster is poured on the working slab. The stabilized denture is placed on the mixed plaster. A base for the working cast is made in model plaster ([Fig 3.2.8](#)). The material is allowed to set. A base of 10 mm height and a land area of 2 mm are made.

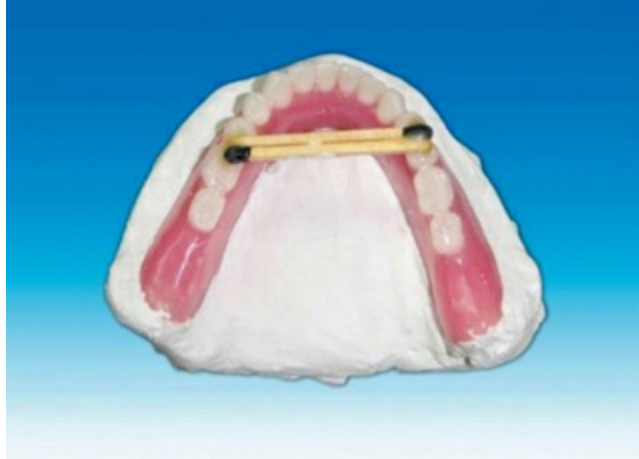

FIG 3.2.8 Making a base for working cast

Once the base and the working cast is set, the stabilized lower denture is removed from the working cast for repair work (Fig 3.2.9). If the repair work is done without the working cast, occlusion errors can occur in the repaired denture. Hence it is mandatory to make a working cast to avoid such errors.

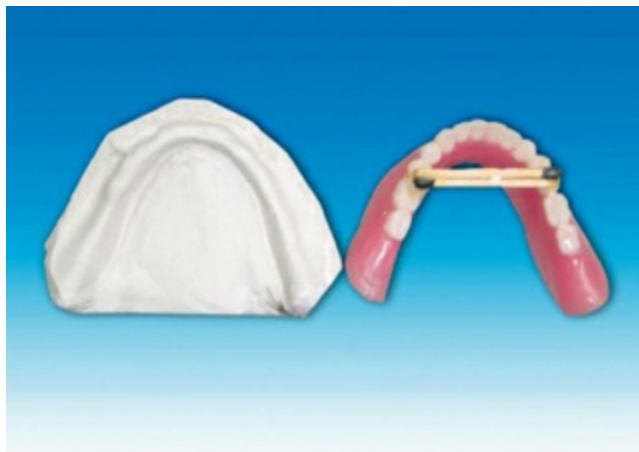

FIG 3.2.9 Stabilized fractured denture removed from the working cast

Step II: Repair work with repair resin

Once the lower denture is removed from the working cast, the

matchsticks and the sticky wax is removed. The fractured components are separated. The fractured edges are reduced by 2 mm to create space for repair resin using tungsten carbide bur (Fig 3.2.10).

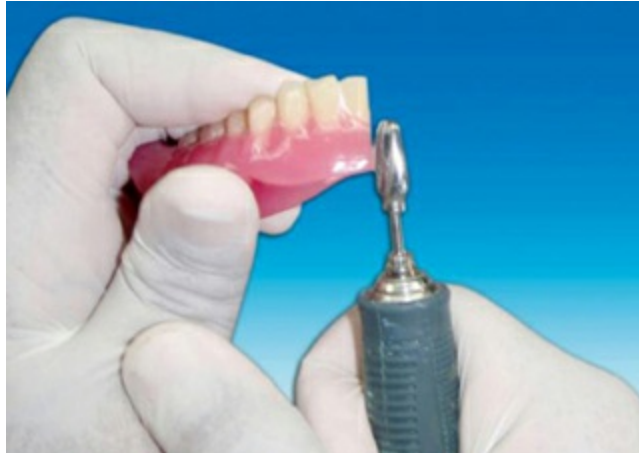

FIG 3.2.10 Creating space at the fracture site

The fractured site of the denture is beveled on the labial side and the lingual side with the tungsten carbide bur for better adaptation of the repair resin (Fig 3.2.11).

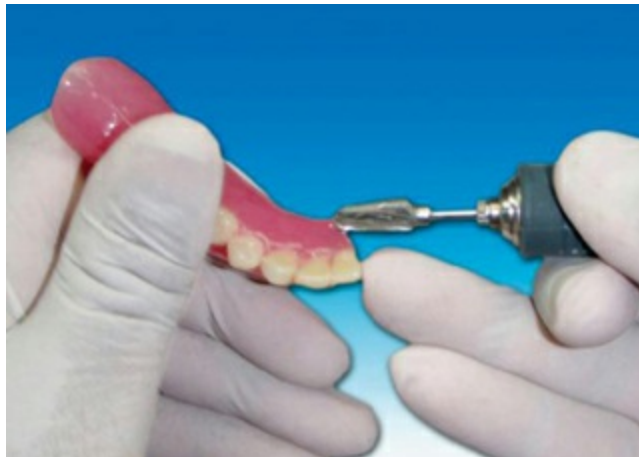

FIG 3.2.11 Beveling at the fracture site

Figure 3.2.12 shows the bevel that has been created at the fracture site.

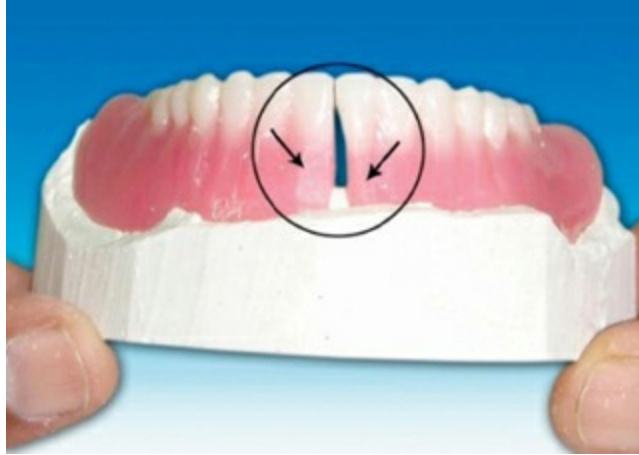

FIG 3.2.12 Bevel at fracture site

Figure 3.2.13 depicts the space created for the repair resin on the lingual side.

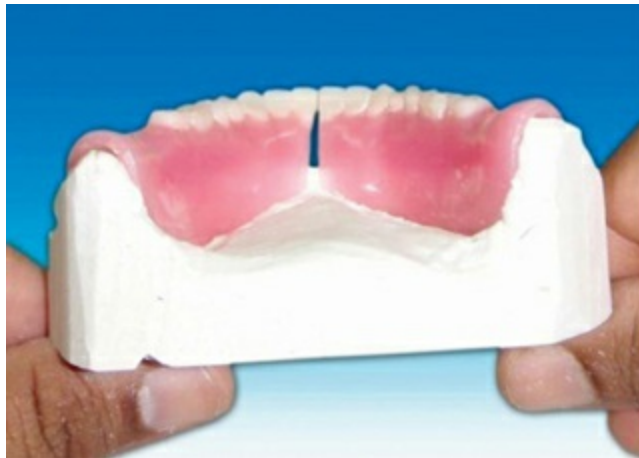

FIG 3.2.13 Prepared denture to receive repair resin

A separating medium like sodium alginate (cold mould seal) is applied on the working cast with a brush in a unidirectional stroke (Fig 3.2.14). Allow the separating medium to dry completely. The fractured denture is then placed on the working cast.

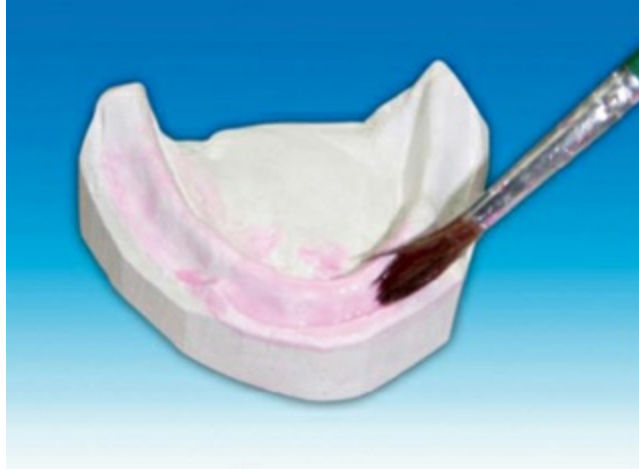

FIG 3.2.14 Application of separating medium on the working cast

The polymer and monomer of the repair resin are taken in an appropriate proportion of 3:1 by volume and are mixed in a Dappen dish (Fig 3.2.15).

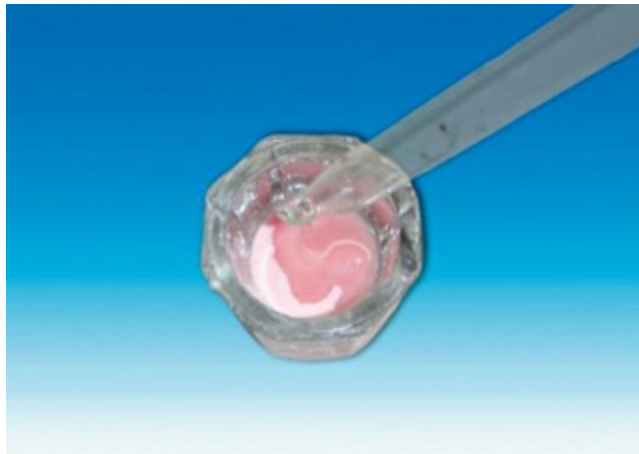

FIG 3.2.15 Manipulation of repair resin

The mixed resin is poured in the fluid state in the fractured site both on the buccal and the lingual aspect. It is allowed to polymerize completely (Fig 3.2.16).

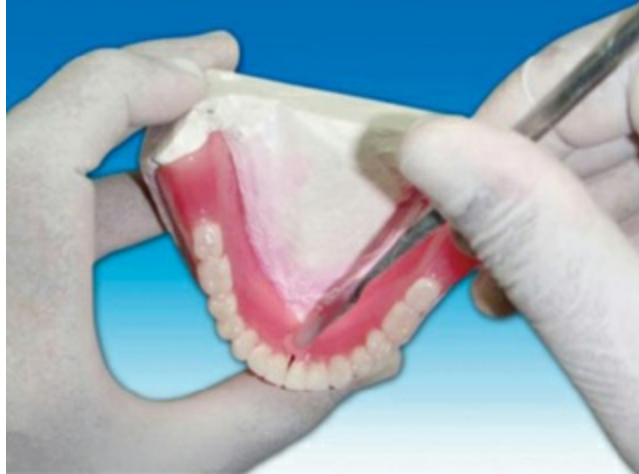

FIG 3.2.16 Pouring of the repair resin in the fractured site

Figure 3.2.17 depicts the repair resin in the fluid state on the labial side.

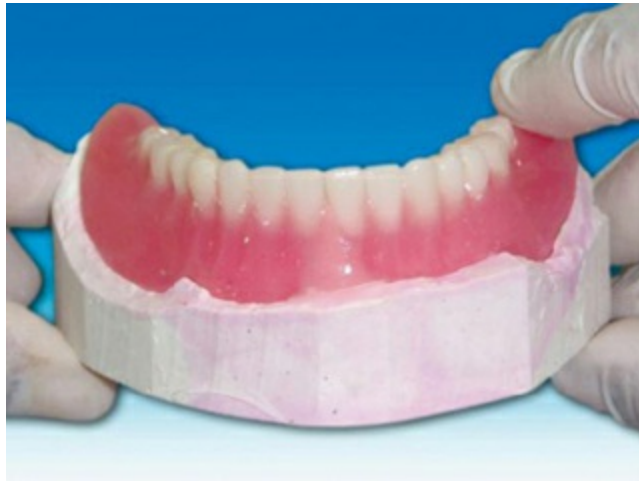

FIG 3.2.17 Repair resin on the labial side

Once the repair resin is polymerized, the excess is trimmed with the tungsten carbide bur on the labial and lingual surfaces (Fig 3.2.18).

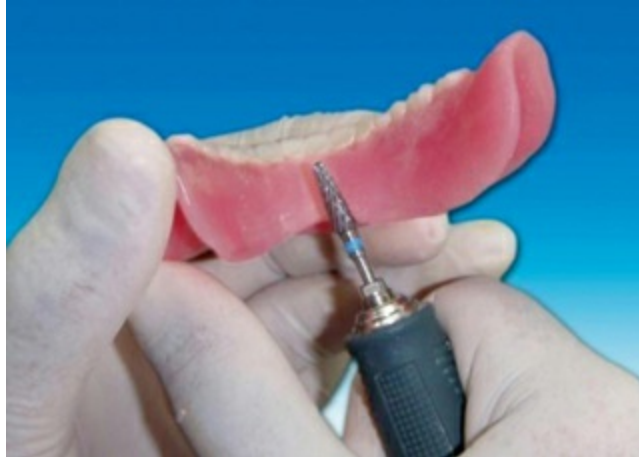

FIG 3.2.18 Trimming the excess resin

The surface is smoothed with no.100 sandpaper in a mandrel driven by micromotor ([Fig 3.2.19](#)).

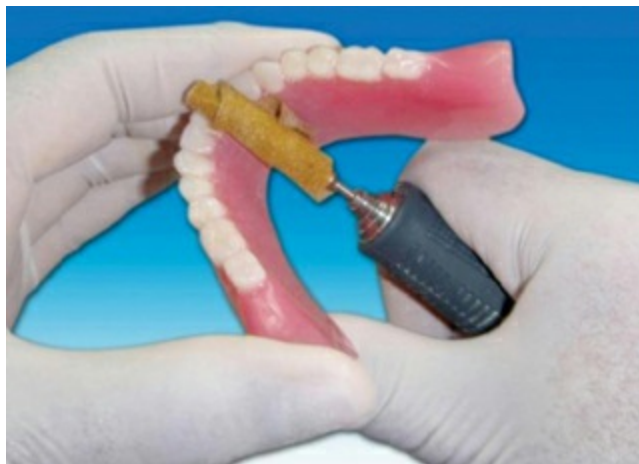

FIG 3.2.19 Smoothing the fractured site

The repaired surface is further smoothed with emery no. 400 ([Fig 3.2.20](#)).

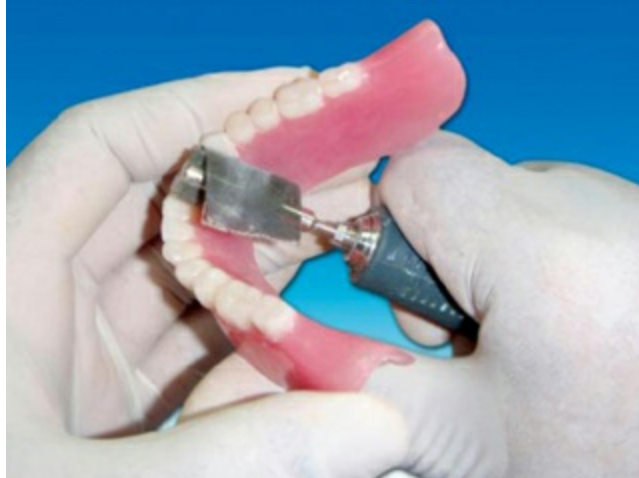

FIG 3.2.20 Surface is smoothed with emery

Polishing is done with pumice in a cloth wheel ([Fig 3.2.21](#)).

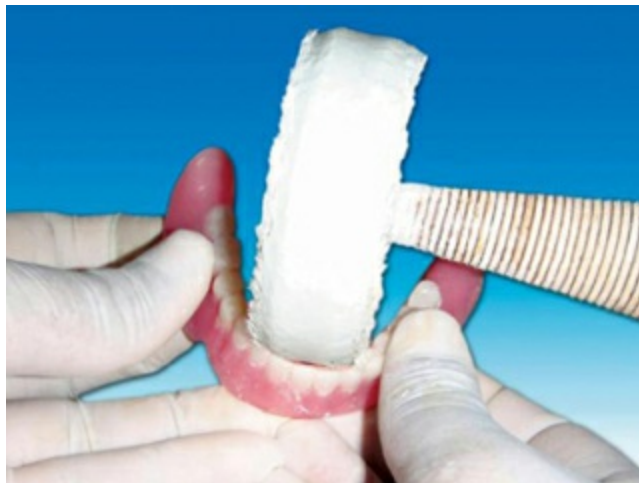

FIG 3.2.21 Polishing with pumice

The repaired denture should have a smooth surface both labially and lingually. The tissue surface should be adapted properly to the working cast ([Figs 3.2.22, 3.2.23](#)).

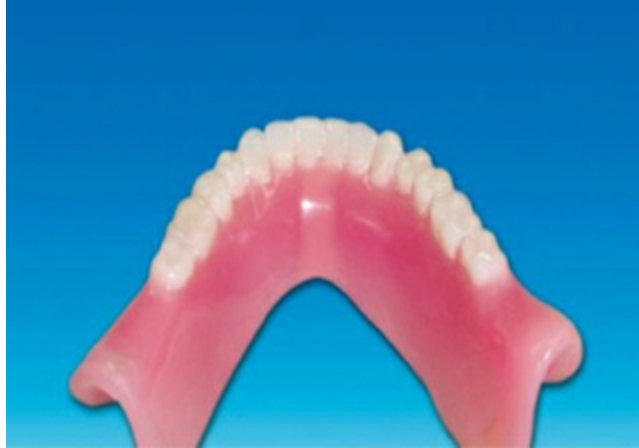

FIG 3.2.22 Lingual view of repaired denture

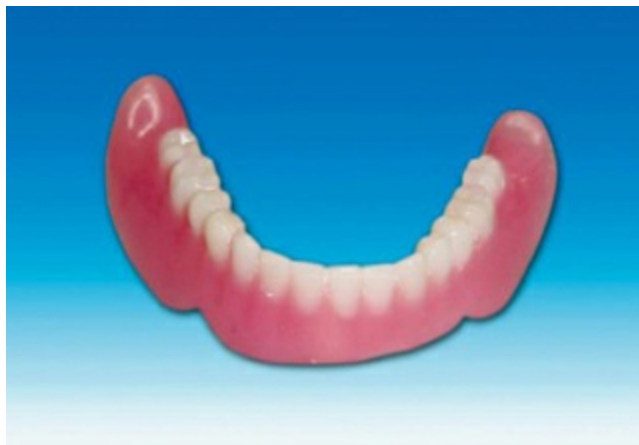

FIG 3.2.23 Labial view of the repaired denture

3.3. Custom impression tray fabrication for upper and lower edentulous arches

Step I: Outline of sulcus, custom tray border, wax spacer and tissue stops

Step II: Adaptation of wax spacer

Step III: Fabrication of resin custom tray

The technique of fabrication of resin custom tray can be done by two methods.

- i. Finger adapted method
- ii. Sprinkle on method.

Armamentarium (Fig 3.3.1)

1. Maxillary and mandibular preliminary edentulous cast
2. Three coloured pencils
3. Modelling wax sheet
4. Wax carver
5. Wax knife
6. BP handle and blade no. 15
7. Separating medium like sodium alginate solution
8. Brush
9. Dappen dish
10. Self-cure resin
11. Cellophane sheet
12. Template
13. Roller or a glass plate
14. Porcelain cup with lid
15. Micromotor
16. Tungsten carbide bur
17. Sandpaper and mandrels

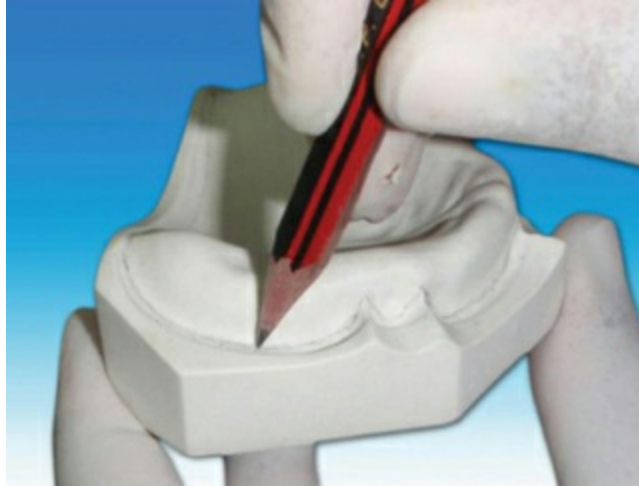

FIG 3.3.3 Outline of the sulcus

The periodontal probe is placed in the sulcus and the 2mm marking is done on the cast ([Fig 3.3.4](#)).

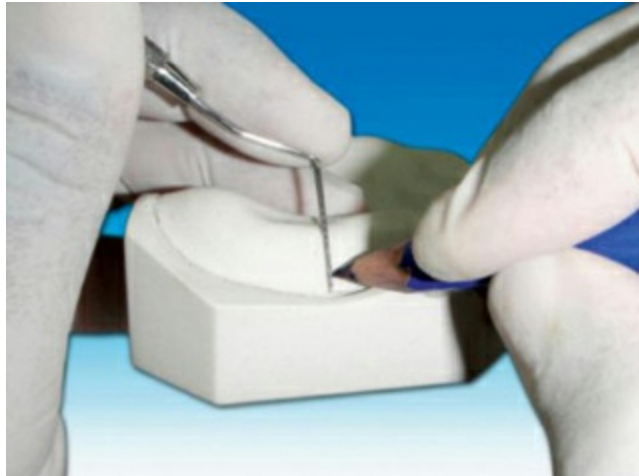

FIG 3.3.4 Tray outline done with the probe

The 2 mm markings are done on the cast with the probe along the labial and buccal sulcus ([Fig 3.3.5](#)).

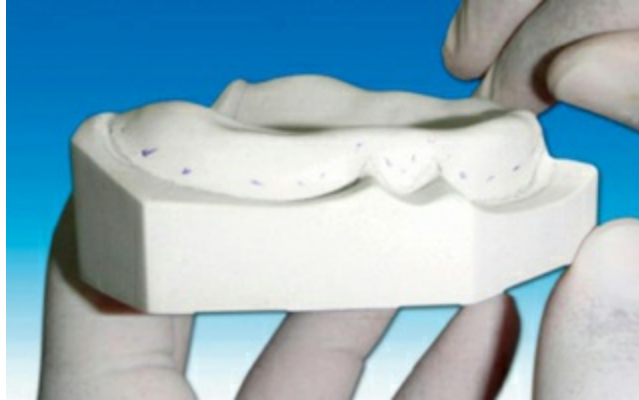

FIG 3.3.5 Points are marked 2mm short of sulcus

All the points are joined together to make a line. This line 2 mm short of the sulcus is the tray border which is marked in blue (Fig 3.3.6).

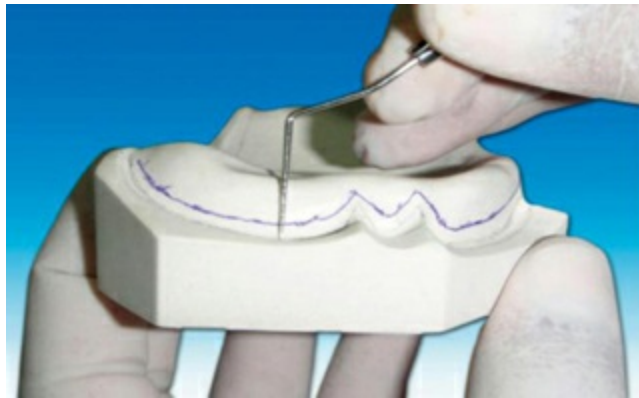


FIG 3.3.6 Outline of tray border

The posterior aspect of the maxillary cast is drawn at least 1mm beyond the posterior vibrating line of posterior palatal seal area (Fig 3.3.7).

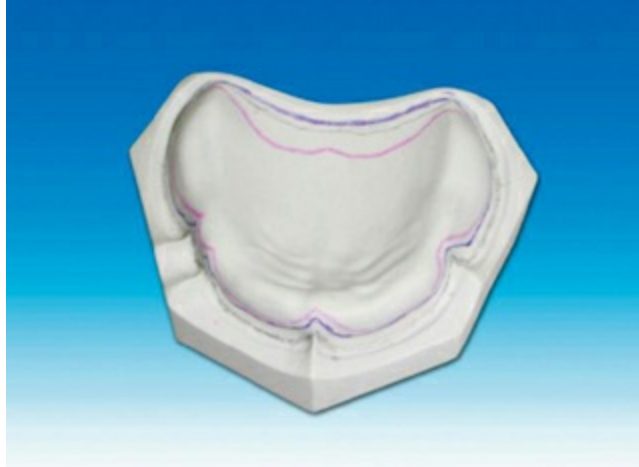

FIG 3.3.7 Outline of tray border in the posterior area

Outline of the wax spacer

The outline of the wax spacer is drawn with a red coloured pencil ([Fig 3.3.8](#)). The spacer outline is done at a level of 2mm short of the tray outline. The spacer outline in the posterior aspect of the maxillary cast is limited to the anterior vibrating line of the posterior palatal seal area. In the mandibular cast, the buccal shelf area is not included in the spacer design. The buccal shelf area is limited anteriorly by the buccal frenum, posteriorly the anterior aspect of the retromolar pad, medially by the crest of the alveolar ridge and laterally by the buccal sulcus.

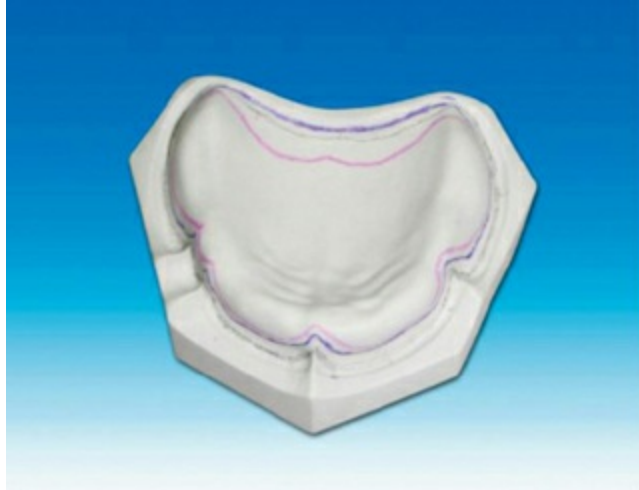
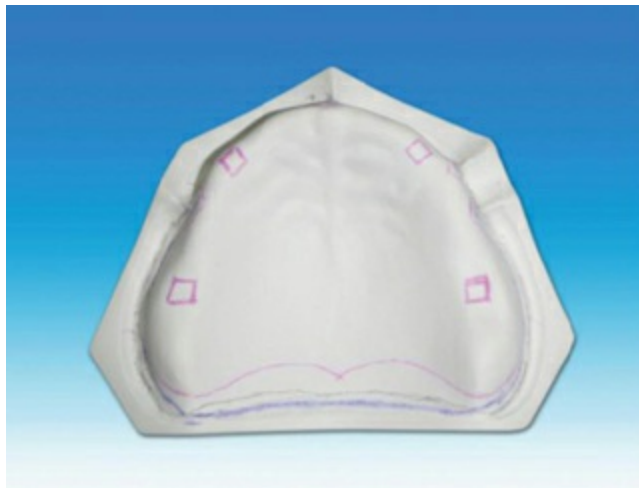
FIG 3.3.8 Outline of wax spacer in red

Outline of tissue stops

Four tissue stops are outlined in the maxillary cast, two in the anterior canine region and two in the posterior molar region (Fig 3.3.9a, b). A 4 × 4 mm square is outlined with a red coloured pencil in the above mentioned region. In the mandibular cast, two tissue stops are outlined in the anterior canine region only.



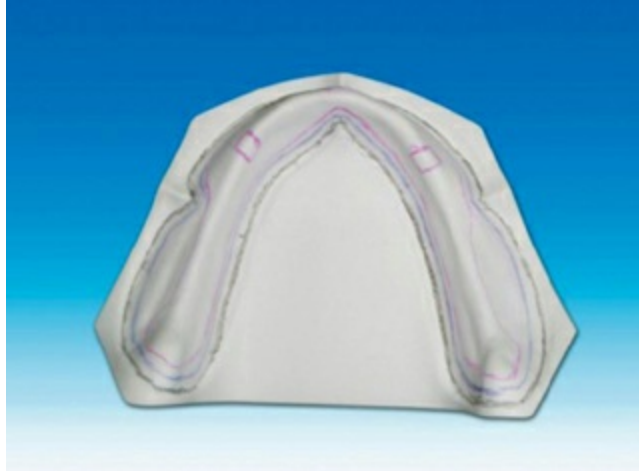


FIG 3.3.9A, B Outline of tissue stops

Step II:

Adaptation of wax spacer

A half sheet of modelling wax is softened over a Bunsen burner and is adapted on the cast without any wrinkles ([Fig 3.3.10](#)).

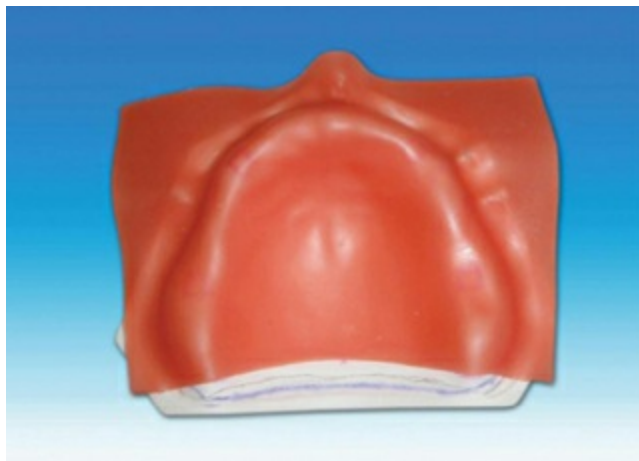

FIG 3.3.10 Adaptation of wax spacer

The wax spacer is trimmed on the cast to the derived outline with a no. 15 BP blade ([Fig 3.3.11](#)). The tissue stops area is also cut along the outline drawn of 4×4 square dimensions.

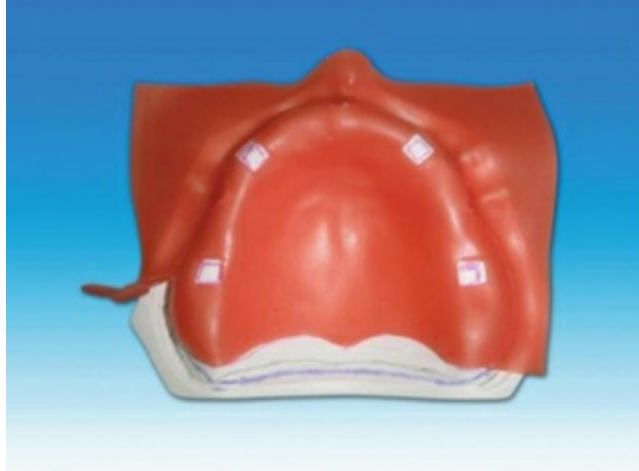

FIG 3.3.11 Excess wax and tissue stops are cut

The outline of wax spacer is done at a level of 4mm short of the sulcus and in the posterior aspect is limited to the anterior vibrating line (Fig 3.3.12).

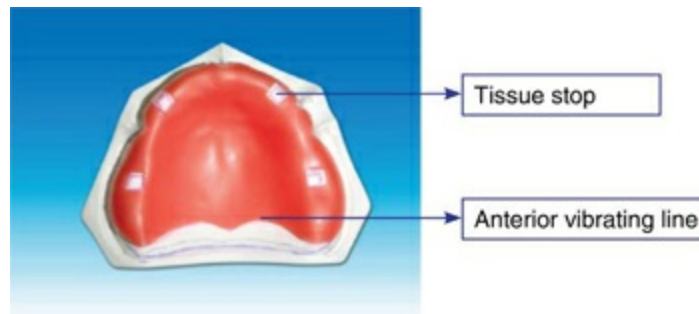


FIG 3.3.12 Outline of tissue stops and wax spacer

A half sheet of modelling wax is cut in the desired archform as shown in the Figure 3.3.13.



FIG 3.3.13 Wax spacer for mandibular arch

The wax sheet is softened and adapted on the mandibular cast without any wrinkles ([Fig 3.3.14](#)).

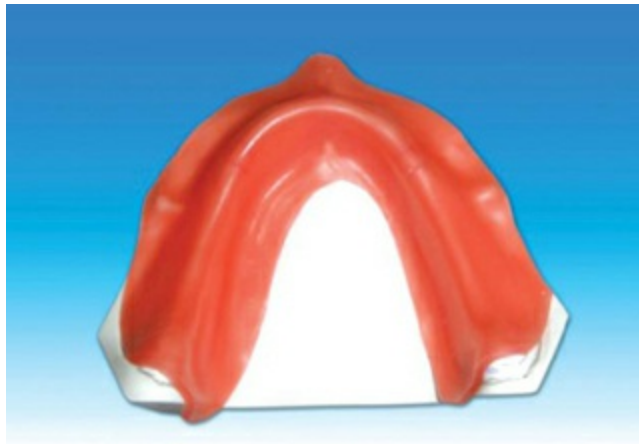

FIG 3.3.14 Adaptation of wax spacer in the mandibular cast

The wax spacer is trimmed on the cast to the desired outline with no. 15 BP blade ([Fig 3.3.15](#)). The tissue stop area is cut along the outline drawn of 4×4 square dimensions.

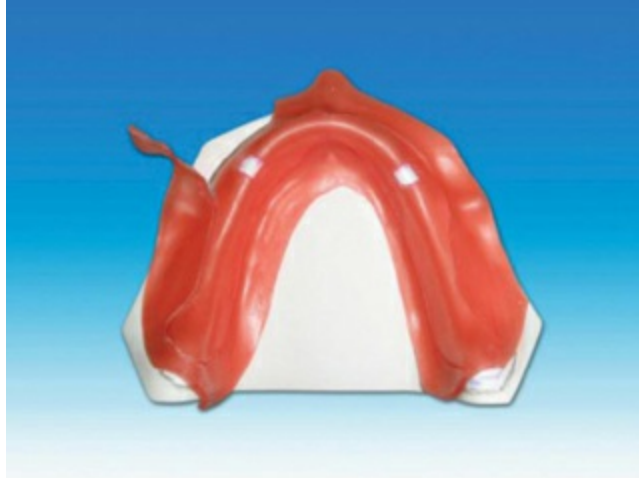

FIG 3.3.15 Excess wax and tissue stops are cut

The outline of wax spacer is done at a level of 4mm short of the sulcus and the wax spacer is not included in the buccal shelf area (Fig 3.3.16). Two tissue stops are cut at the anterior canine region.

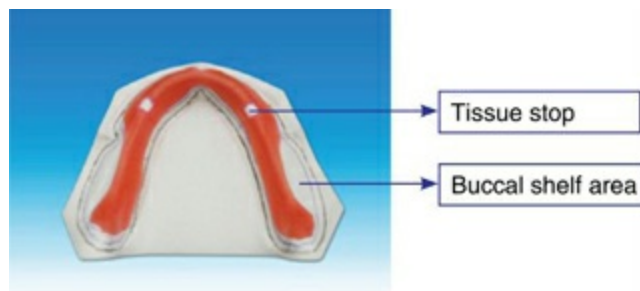


FIG 3.3.16 Outline of wax spacer and tissue stop in the mandibular cast

Step III:

Fabrication of custom tray

A separating medium of sodium alginate (cold mould seal) is applied on the cast with a brush in unidirectional stroke (Fig 3.3.17). The separating medium is applied to aid in easy removal of the tray from the cast.

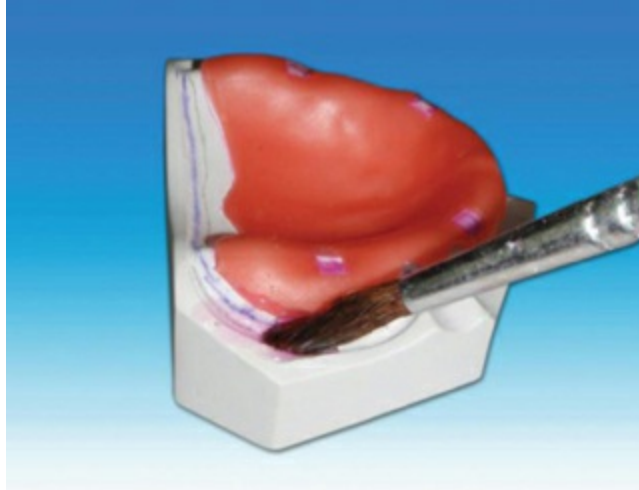


FIG 3.3.17 Separating medium applied

Finger adapted method

The finger adapted method is the most widely used technique of making impression trays. The resin is mixed in the form of dough and is rolled to the desired thickness with the help of a template and is adapted to the cast with finger pressure. In this technique, as we use the template there is a control over the uniform thickness of 2mm of resin impression tray.

Sprinkle on method

In this technique, the polymer powder and the liquid monomer are added in incremental layers. In this technique, there is no uniform control of thickness of resin impression tray. Hence, this technique is not widely used. In this chapter, finger adapted method is discussed.

The template is made of dental stone. [Figure 3.3.18](#) depicts the upper and lower templates.



FIG 3.3.18A, B Maxillary and mandibular tray templates

Separating medium, like cold mould seal is applied on the tray template and it is allowed to dry ([Fig 3.3.19](#)). A wet cellophane sheet is placed over the tray template. The polymer and monomer are mixed in a porcelain cup. When the dough stage is reached, the material is placed on the cellophane sheet placed over the tray template. A glass slab is placed over it to spread the material uniformly in the tray template. The resin dough is removed from the template along with the cellophane sheet.

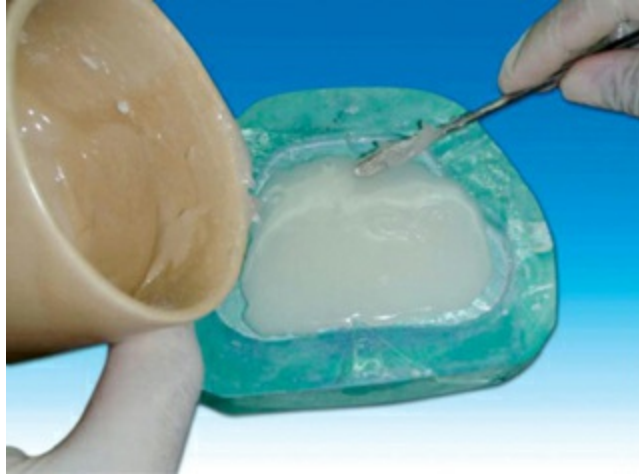

FIG 3.3.19 Resin dough in the template

The resin dough is adapted with light finger pressure starting from the mid-palatal area to the crest of the ridge and ending over the sulcus (Fig 3.3.20). The adaptation should be continuous. If not done continuously, there may be rebound of tray material resulting in poor adaptation of the tray material to the tissue surface of the cast especially in the posterior palatal seal area.

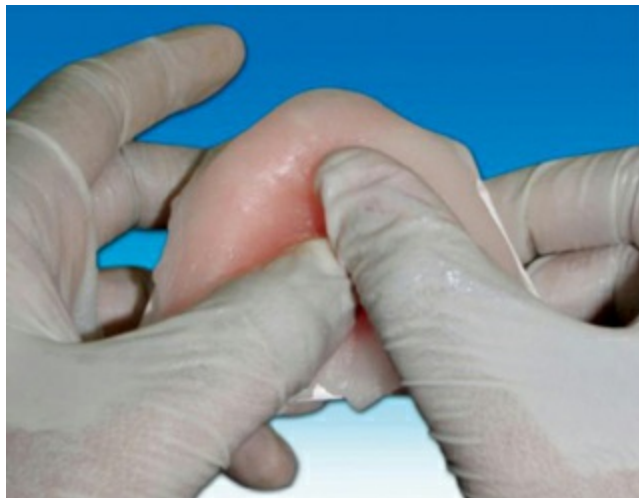

FIG 3.3.20 Adaptation of tray on the maxillary cast

The tray material is adapted on the lingual side, then over the crest of the ridge and along the buccal slope of the ridge (Fig 3.3.21).

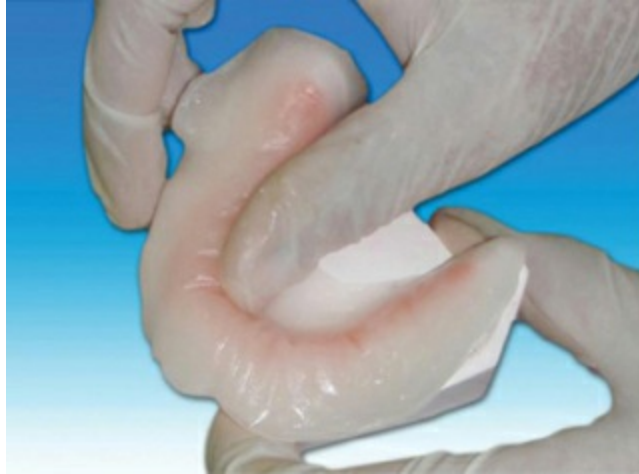

FIG 3.3.21 Adaptation of tray on the mandibular cast

The excess material is cut with a no. 15 BP blade along the anterior and posterior desired outline (Fig 3.3.22).

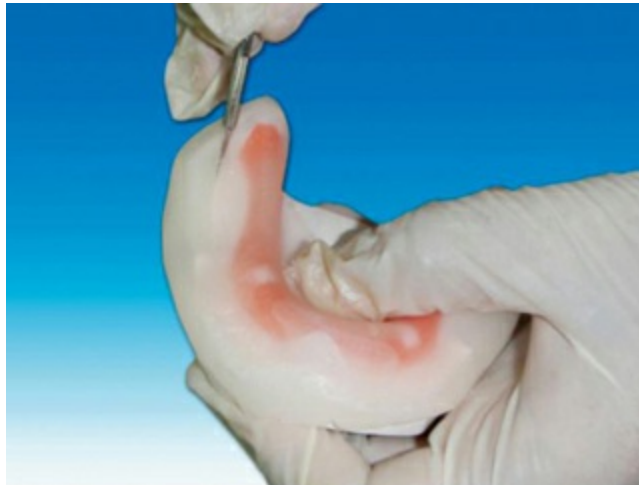

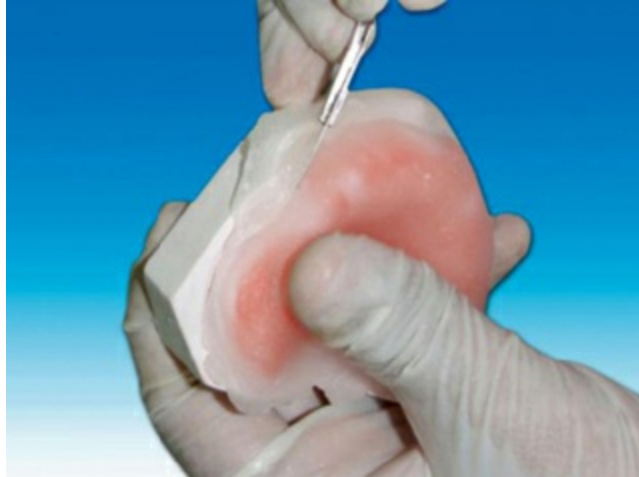


FIG 3.3.22A, B Excess material cut

The adaptation of the resin material should be continuous because there may be a rebound of the material causing a space to cover between the tissue surface of cast and the tray (Fig 3.3.23). There should be close adaptation of the tray especially in the posterior palatal seal area and in the lingual aspect of the mandibular tray.

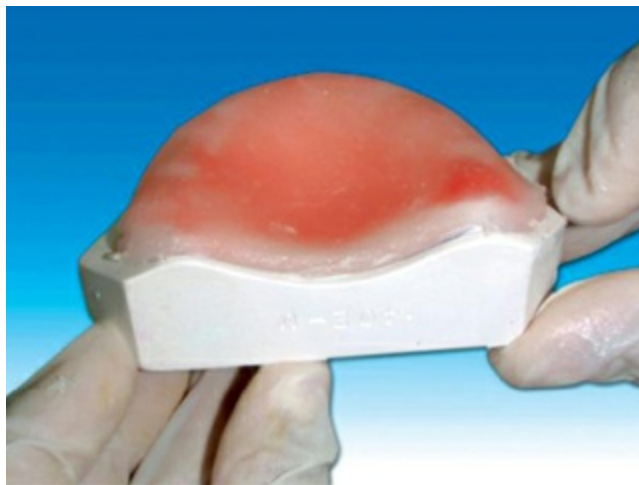

FIG 3.3.23 Adaptation of tray in posterior aspect

The polymer and monomer are mixed in a porcelain cup. When it reaches the dough stage, it is removed and adapted on the anterior portion of the upper tray to make a handle (Fig 3.3.24).

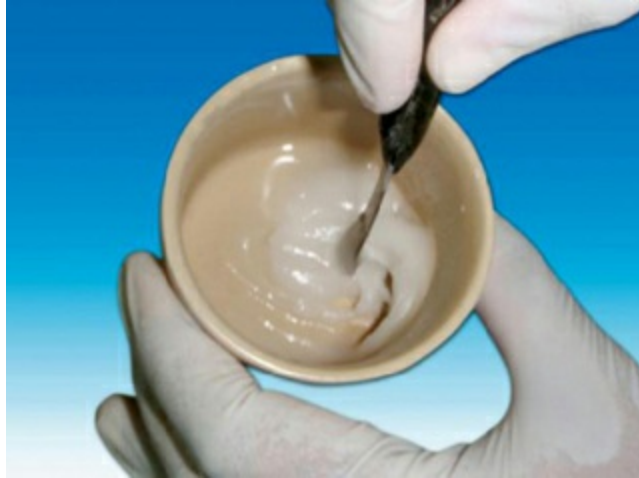
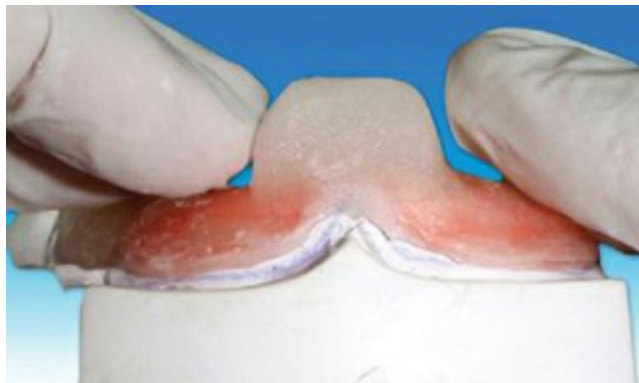
FIG 3.3.24 Resin mixed for tray handle

The handle should be approximately 3–4 mm thick, 8 mm in length, and 8 mm in height. The handle of the tray should be inclined at an angle of 45 degree (Fig 3.3.25). The handle should be positioned in such a way that it should not interfere with the lip movements of the patients during border moulding and impression making. The handle for the lower tray should be straight. Stabilizing handles one on either side are positioned posteriorly. The borders of the tray should be smoothed with tungsten carbide bur followed by using sandpaper.



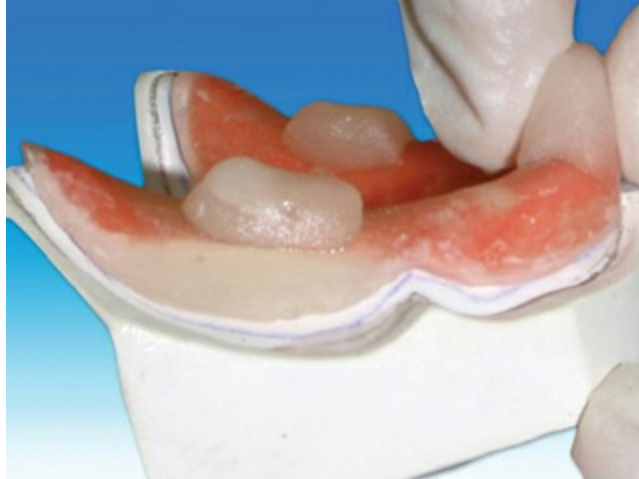
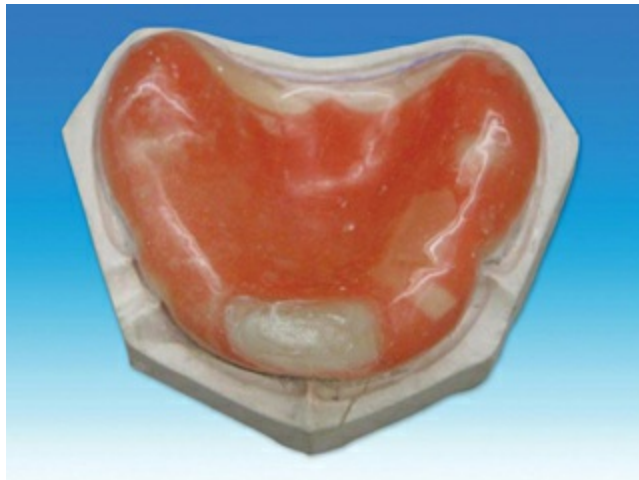
FIG 3.3.25A, B Maxillary and mandibular custom trays with handles

The borders of the tray should be smooth and uniform. The relief for the labial and buccal frenum is adequately given in the custom tray ([Fig 3.3.26](#)).



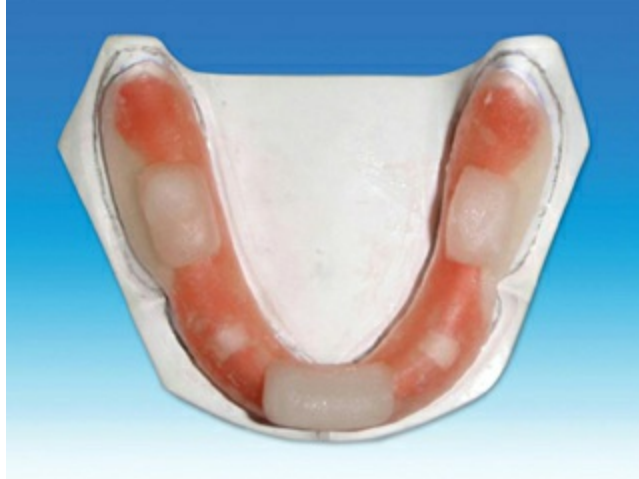

FIG 3.3.26A, B Maxillary and mandibular resin custom trays

3.4 Removable partial denture fabrication

Steps in making removable partial denture

3.4.1 Making of casts

Impressions from the dentulous models are made. Casts are poured and the required teeth are trimmed from the casts to make the corresponding Kennedy's classification of partially edentulous arches (Figs 3.4.1.1—3.4.1.4).



FIG 3.4.1.1 Class I: Posterior molars removed on both sides

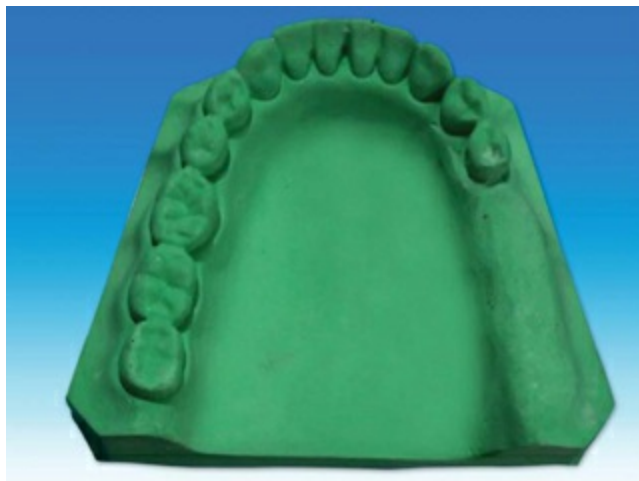

FIG 3.4.1.2 Class II: Posterior molars removed on one side

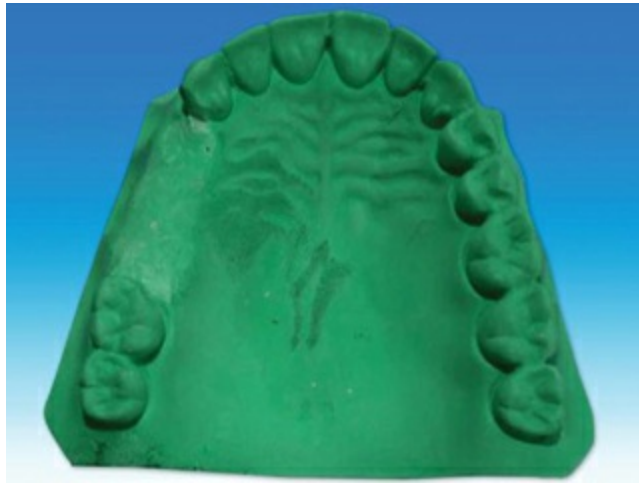

FIG 3.4.1.3 Class III: Premolars removed on one side




FIG 3.4.1.4 Class IV: Anteriors especially the incisors removed from both sides [crossing the midline]

3.4.2 Indexing of dental casts

Indexing of the casts is essential because the casts after processing of the waxed dentures can be remounted in the articulator in the same position. This helps us to do selective grinding procedures to reduce processing errors.

Indexing can be done by two methods: groove indexing and notch indexing (Fig 3.4.2.1).




FIG 3.4.2.1 Notch and groove indexing done on the base of the cast

Steps for making the index in a cast are explained in [Section 3.1.1](#).

Indexing of the dental casts.

3.4.3. Shellac baseplate adaptation for class IV

Armamentarium (Fig 3.4.3.1)

- Shellac baseplate
 - Maxillary
 - Mandibular
- Master cast
- Bunsen burner (or) gas torch
- Curved scissors
- Wax spatula
- Chip blower
- Sandpaper
- Marker pen



FIG 3.4.3.1 Armamentarium

The maxillary record base is placed over the maxillary partially edentulous cast in such a way that shellac record baseplate covers the entire surface of the cast (Fig 3.4.3.2). The baseplate should not be placed either too anteriorly or posteriorly.




FIG 3.4.3.2 Maxillary shellac baseplate on the maxillary cast

The flame from a Bunsen burner or a gas torch is moved slowly over the surface of the shellac baseplate wax till it appears shiny and slumps onto the cast ([Fig 3.4.3.3](#)).

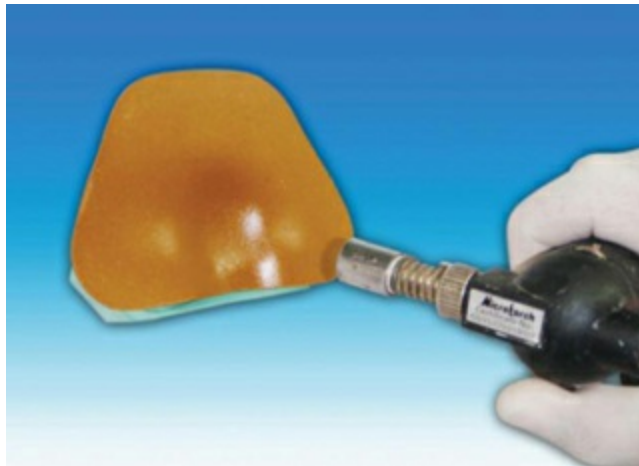


FIG 3.4.3.3 Shellac baseplate softened with torch flame

Pressure is applied with the fingers from the palatal portion of the maxillary cast to labial and buccal surfaces of the residual alveolar ridge ([Fig 3.4.3.4](#)). This is done to prevent air entrapment between the shellac baseplate wax and tissue surface of the cast.

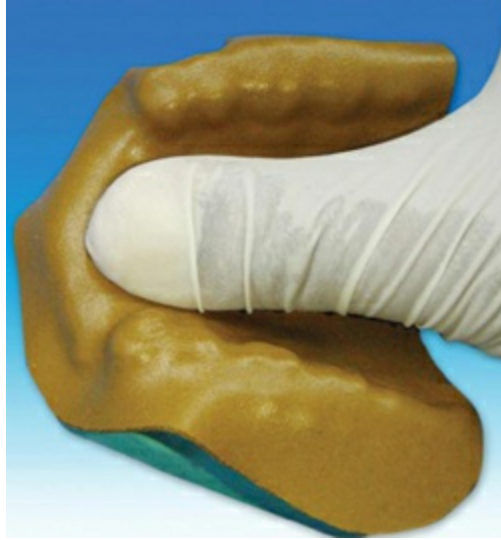

FIG 3.4.3.4 Adaptation of baseplate

An outline is drawn approximately at the height of contour of the remaining teeth with a pencil in the cast ([Fig 3.4.3.5](#)).

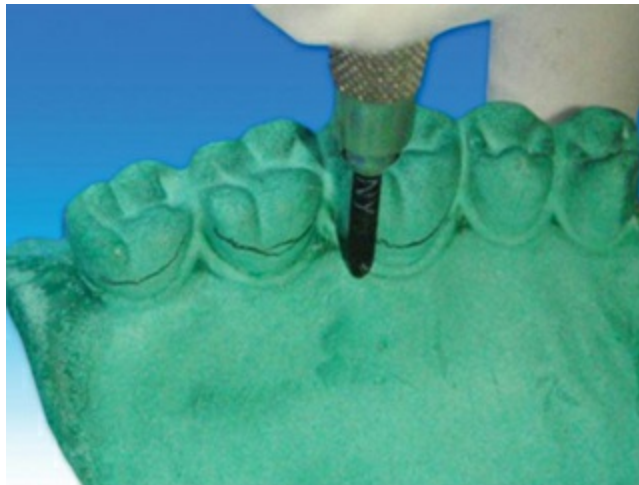

FIG 3.4.3.5 Outline of the record base at the height of contour of teeth

An outline is drawn at the shellac baseplate near the palatal cusps of the remaining natural teeth with a marker pen and in the edentulous area the outline is marked near the land area ([Fig 3.4.3.6](#)).

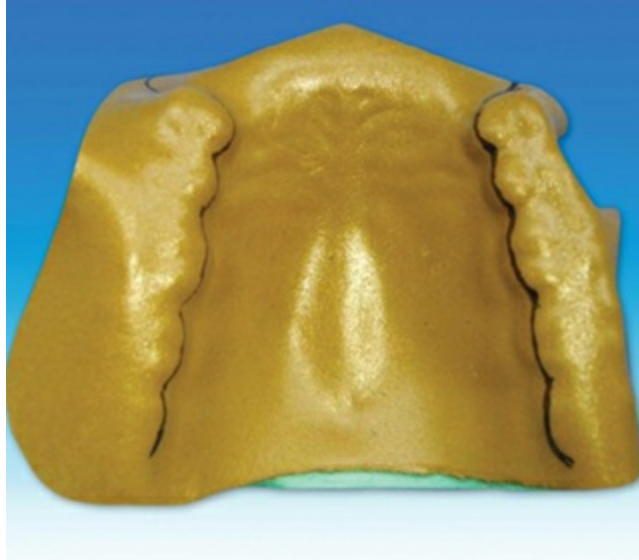


FIG 3.4.3.6 Outline of the record base

The shellac is softened again and the excess of the shellac baseplate wax is cut with a curved scissors along the marked outline ([Fig 3.4.3.7](#)).

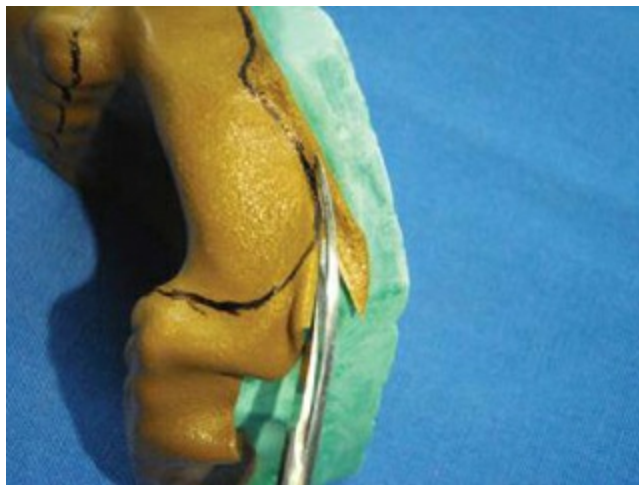


FIG 3.4.3.7 Excess is cut with the scissors

The trimmed edges are heated using the gas torch. The softened trimmed edges are adapted on the remaining natural teeth corresponding to the line marked at the height of contour ([Fig 3.4.3.8](#)). Near the edentulous area, the softened edges are elevated from the

cast and folded back on the shellac baseplate and are burnished with the wax spatula to form a smooth and rounded border. The borders must reproduce both the contours and dimensions of the reflections of the final cast.

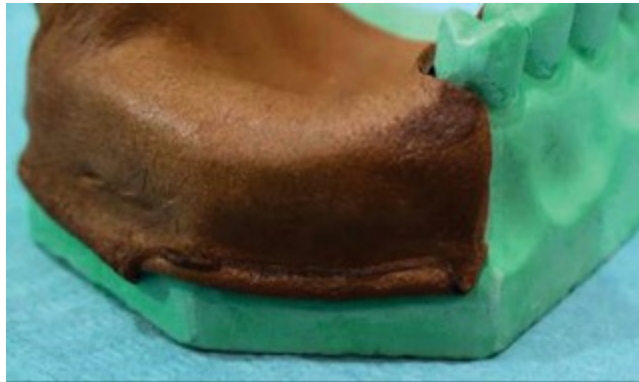


FIG 3.4.3.8 Borders are rolled

The adapted record base is removed from the cast and examined. The borders should be smooth and rounded (Fig 3.4.3.9). The relief given for the labial frenum should be adequate.



FIG 3.4.3.9 Tissue surface of the record base with smooth and rounded borders

Irregular and rough areas should be smoothed with a sandpaper (Fig 3.4.3.10).

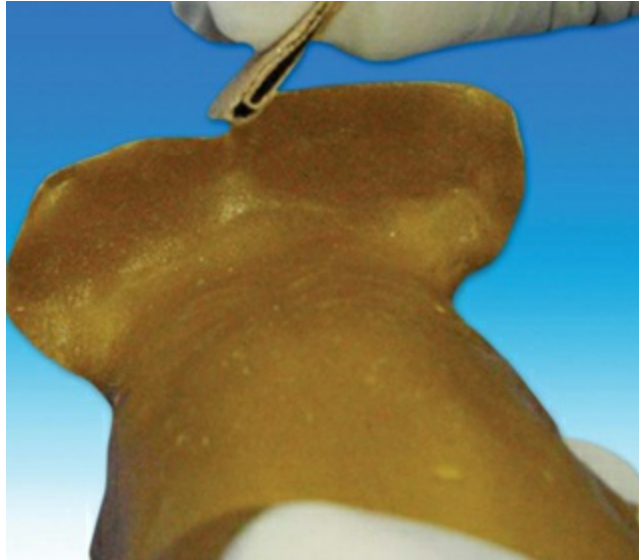



FIG 3.4.3.10 Rough areas smoothed

Figure 3.4.3.11 depicts the finished shellac record base with collars adapted in relation with the height of contour to the remaining natural teeth and in edentulous area it should have smooth and rounded borders.



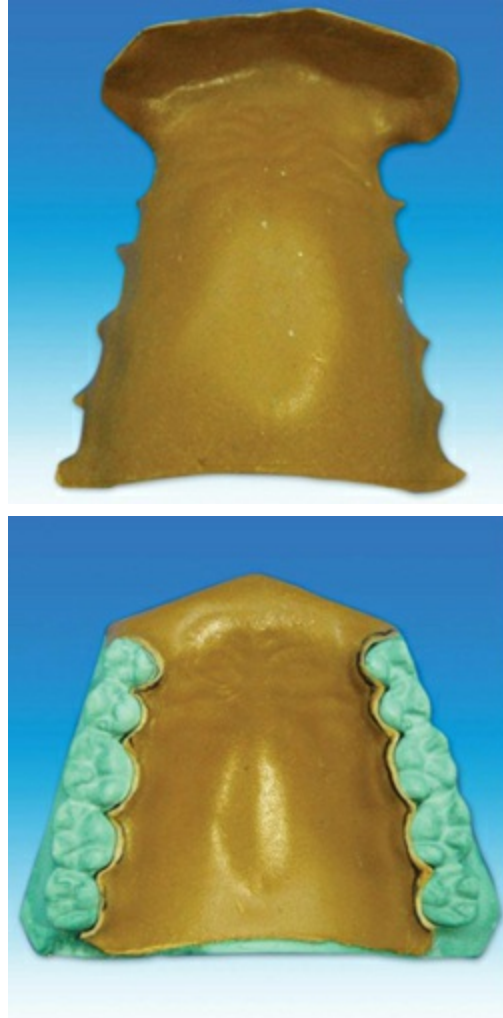


FIG 3.4.3.11 Finished maxillary record base

Adaptation of mandibular record base class I

The mandibular shellac record base is placed over the mandibular cast (Fig 3.4.3.12). Posteriorly, the record base should cover the retromolar pad area of the cast.



FIG 3.4.3.12 Mandibular shellac baseplate on the cast

The flame from a Bunsen burner or a gas torch is moved slowly over the surface of the shellac baseplate till it appears shiny and slumps onto the cast. Firm pressure is applied with wet fingers to the lingual surface of the mandibular cast ([Fig 3.4.3.13](#)). The record base is reheated and adaptation is done over the crest of the ridge near the edentulous area and then into the sulcular areas to prevent entrapment of air between the tissue surface of the cast and the shellac record base.

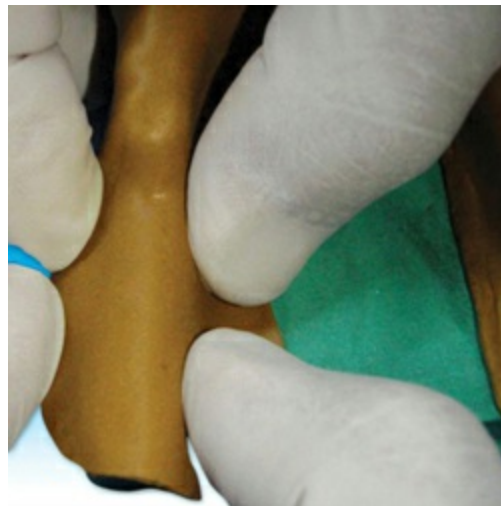


FIG 3.4.3.13 Adaptation of the record base from the lingual side

An outline is drawn approximately at the height of contour of the remaining teeth with a pencil in the cast (Fig 3.4.3.14).

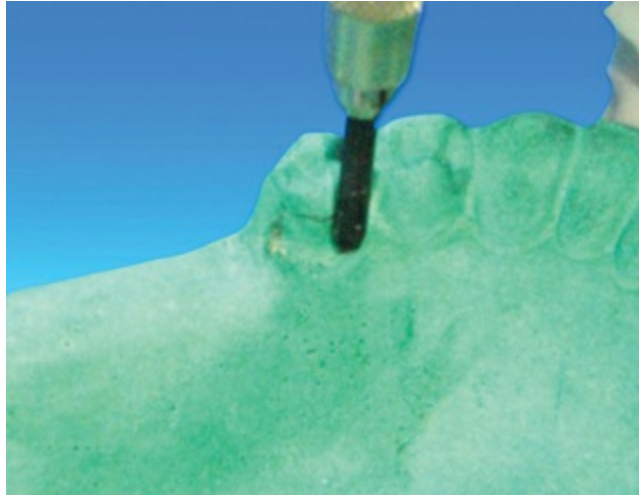

FIG 3.4.3.14 Outline of the record base on the height of contour of teeth

An outline is drawn at the shellac baseplate near the lingual cusps of the remaining natural teeth with a marker pen and in the edentulous area the outline is marked near the land area (Fig 3.4.3.15).

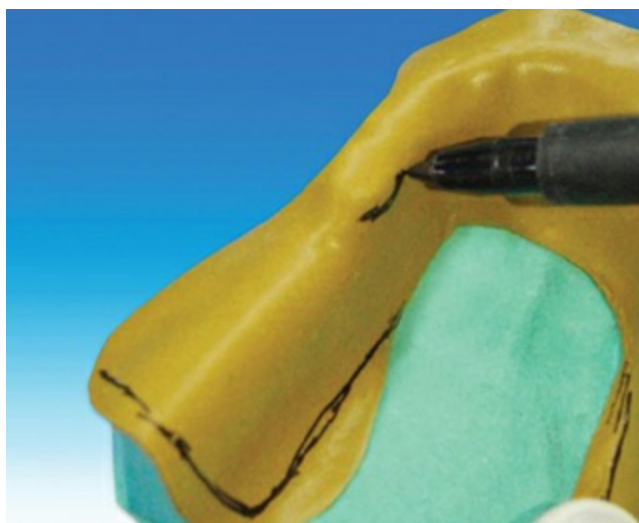

FIG 3.4.3.15 Excess is marked

The shellac is softened again and the excess of the shellac is cut along the marked outline with the help of a curved scissors (Fig 3.4.3.16).

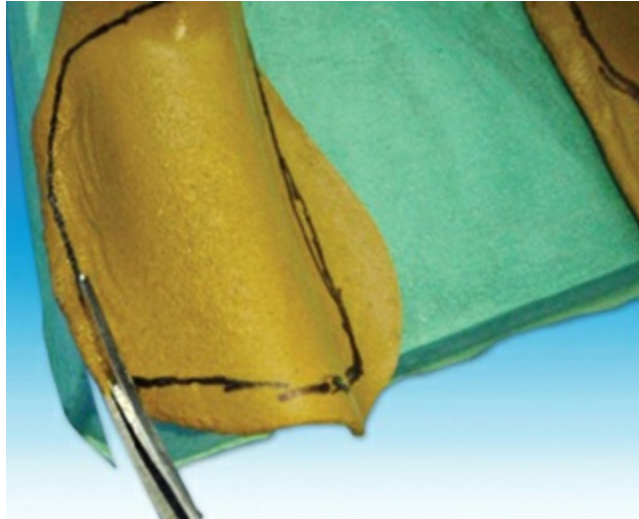


FIG 3.4.3.16 Excess is cut

The trimmed edges are heated using the gas torch (Fig 3.4.3.17). The softened trimmed edges are adapted on the remaining natural teeth corresponding to the line marked at the height of contour. Near the edentulous area, the softened edges are elevated from the cast and folded back on the shellac baseplate and are burnished with the wax spatula to form a smooth and rounded border. The borders must reproduce both the contours and dimensions of the reflections of the final cast.

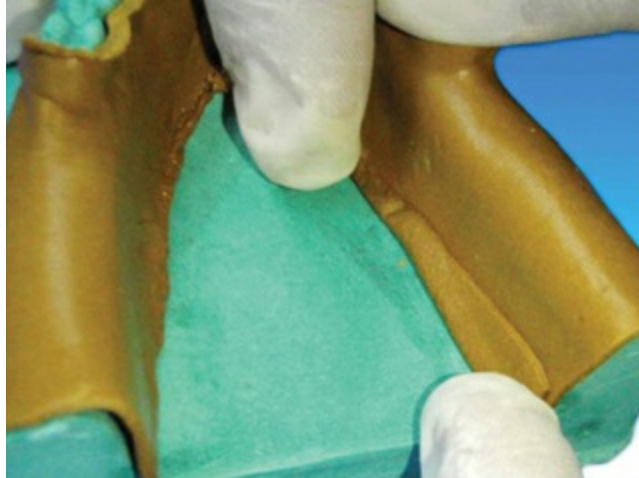


FIG 3.4.3.17 Borders are rolled

The adapted record base is removed from the cast and examined. The borders should be smooth and rounded (Fig 3.4.3.18). The relief given for the buccal frenum should be adequate.



FIG 3.4.3.18 Tissue surface of the record base with smooth and rounded borders

The rough surfaces are smoothed with a sandpaper (Fig 3.4.3.19).



FIG 3.4.3.19 Rough areas are smoothed

The finished shellac record base with collars adapted in relation with the height of contour to the remaining natural teeth and in edentulous area it should have smooth and rounded borders ([Fig 3.4.3.20](#)).



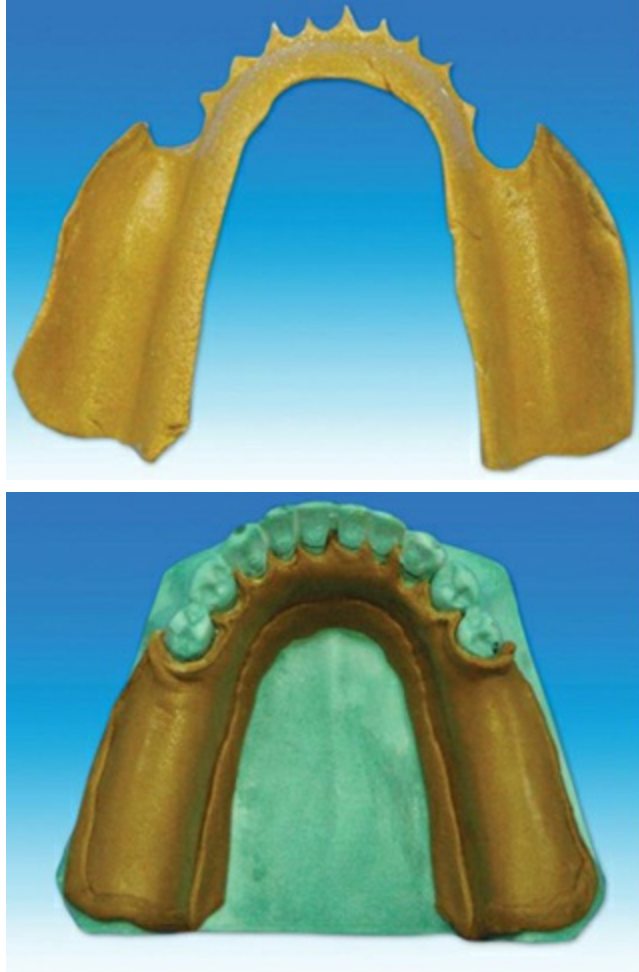

FIG 3.4.3.20 Finished mandibular record base

3.4.4. Fabrication of occlusion rims

Armamentarium (fig. 3.4.4.1)

- Maxillary and mandibular casts with the shellac record base
- Modelling wax sheet
- Wax knife
- Wax carver
- Hot plate
- Bunsen burner or gas torch
- Metallic scale
- Marker pen



FIG 3.4.4.1 Armamentarium

Fabrication of maxillary occlusal rims class IV

Required amount of modelling wax sheet is softened over the Bunsen burner and it is rolled uniformly without an air entrapment (Fig 3.4.4.2). The desired length of softened rolled wax rim is cut.

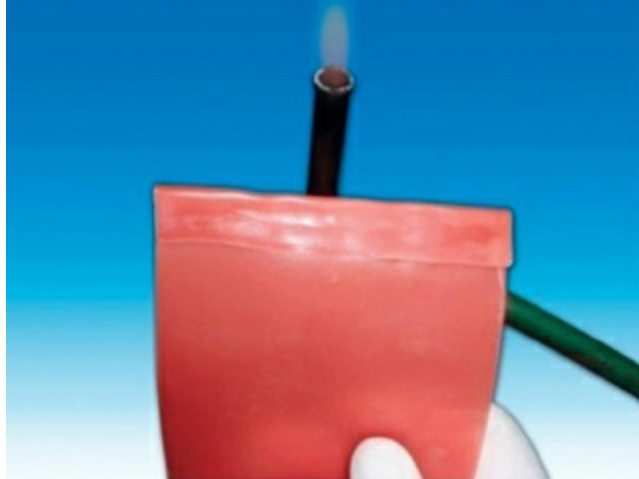

FIG 3.4.4.2 Softening of wax

The softened rolled modelling wax is positioned on the anterior aspect of the maxillary cast (Fig 3.4.4.3). The height—parallel to the remaining occlusal surface, extension—decided by the edentulous space, width —426 mm and the position of the rim with a slight labial inclination and the anterior edge is 2 mm away from the lower incisors.

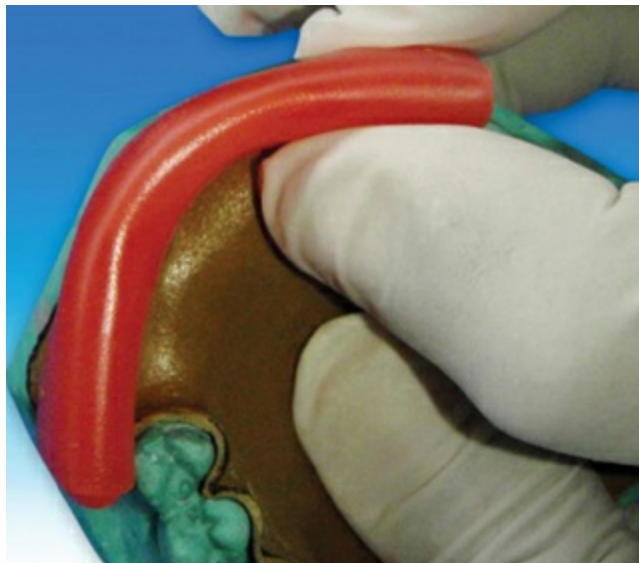

FIG 3.4.4.3 Positioning the wax rim

The wax knife is heated and the occlusion rim is sealed to the record

base on all sides (Fig 3.4.4.4). The wax rim is smoothed with a heated wax knife.

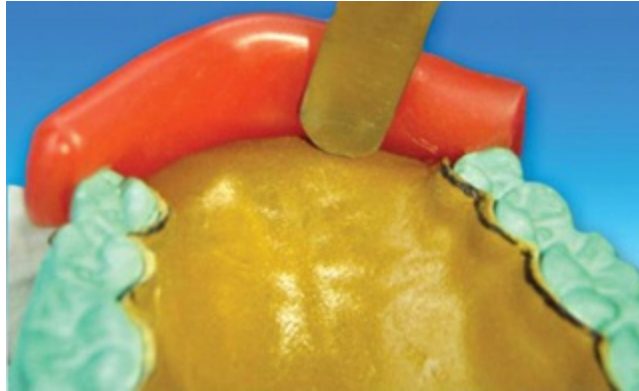


FIG 3.4.4.4 Sealing of wax rim

The finished maxillary occlusal rim is depicted in Figure 3.4.4.5.

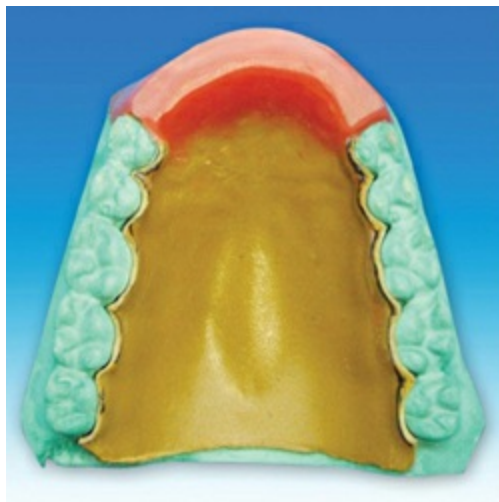


FIG 3.4.4.5 Finished maxillary occlusion rim

Fabrication of mandibular occlusion rim class I

Required amount of modelling wax sheet is softened over the Bunsen burner and it is rolled uniformly without any air entrapment (Fig

3.4.4.6). The desired length of rolled wax rim is cut.

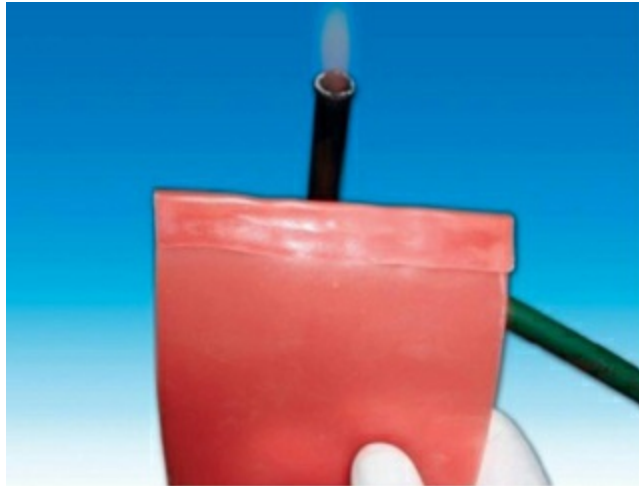

FIG 3.4.4.6 Softening of wax

The softened rolled modelling wax is positioned on the posterior aspect of the mandibular cast (Fig 3.4.4.7). The height of the occlusion rim should be parallel to the remaining occlusal surface, posterior extension upto the mesial end of retromolar pad, width—6 mm and the position of the rim decided by the opposing arch.

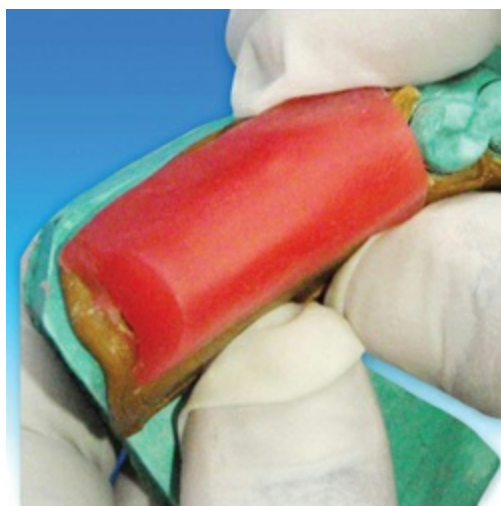

FIG 3.4.4.7 Positioning the wax rim

The wax knife is heated and the occlusion rim is sealed to the record base on all sides (Fig 3.4.4.8). The wax rim is smoothed with a heated wax knife.



FIG 3.4.4.8 Sealing of wax rim

The finished mandibular occlusal rim is depicted in Figure 3.4.4.9.

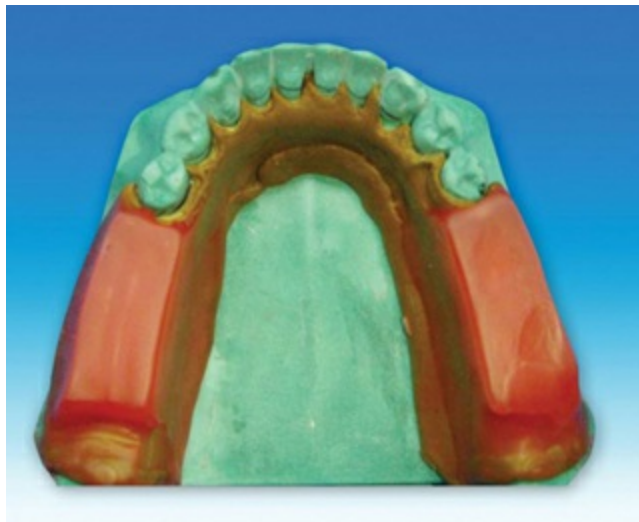

FIG 3.4.4.9 Finished mandibular occlusal rim

The finished maxillary and mandibular occlusion rims are depicted

in [Figure 3.4.4.10](#). When both are placed together the remaining maxillary teeth and the corresponding remaining mandibular teeth should occlude. The maxillary occlusal rim should overlap the mandibular anteriors labially. The mandibular occlusal rim should correspond to the maxillary posterior teeth.

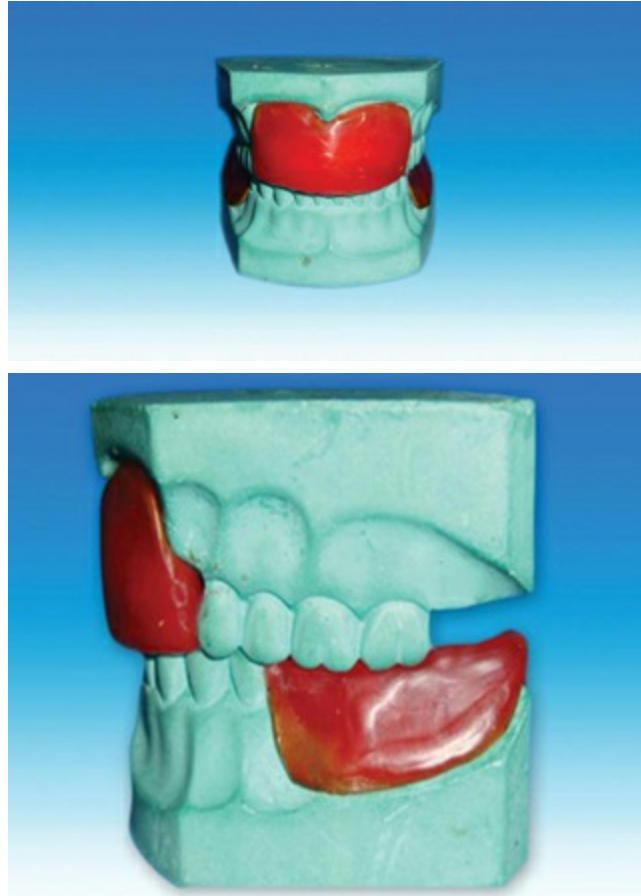

FIG 3.4.4.10 Finished maxillary and mandibular occlusion rims

3.4.5. Mounting of the casts in articulator

Armamentarium (Fig 3.4.5.1)

- Maxillary occlusion rim with the cast
- Mandibular occlusion rim with the cast
- Mean value articulator
- Dental plaster
- Rubber bowl
- Mixing spatula
- Wax knife
- Wax carver
- Modelling clay
- Long thread
- Vaseline
- Brush

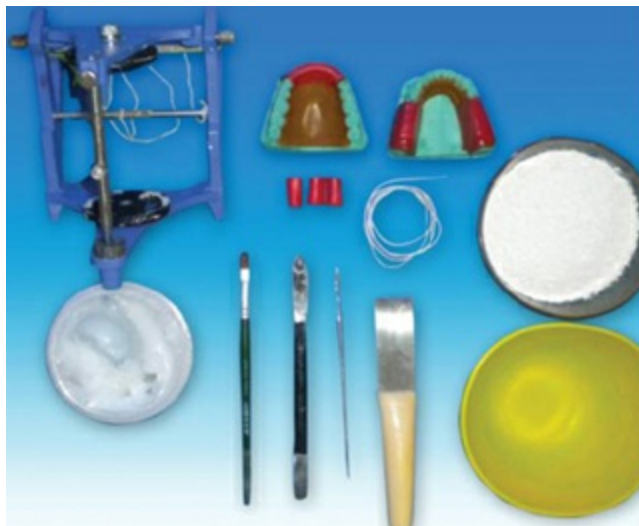

FIG 3.4.5.1 Armamentarium

The upper and the lower casts with the finished occlusal rims are

sealed together. Two small strips of wax are luted to the upper and lower bases of the casts as shown in [Figure 3.4.5.2](#). This is done for the easy removal of the casts from the articulator for processing the waxed denture.

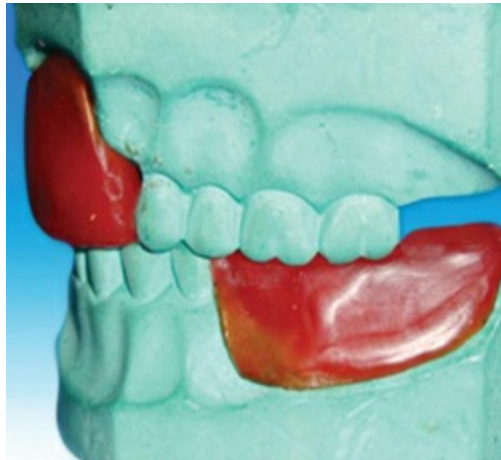

FIG 3.4.5.2 Upper and lower casts with occlusion rims on the base of the cast

Follow the steps of articulation as described in this chapter under [Section 3.1.4](#) Mounting of casts in the articulator.

The upper and lower casts are mounted in the articulator ([Fig 3.4.5.3](#)). The posterior occlusal plane is in line with the posterior reference rod. The central pin is pointing the midline of the casts and the anterior plane of occlusion.

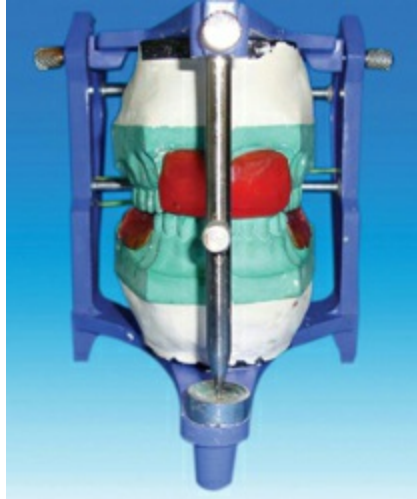

FIG 3.4.5.3 Upper and lower casts mounted in the articulator

3.4.6. Teeth setting

Armamentarium (Fig 3.4.6.1)

- Maxillary occlusal rim with cast
- Mandibular occlusal rim with cast
- Mean value articulator
- Teeth shade
- Measurement scale
- Wax knife
- Roach carver
- Wax spatula
- Wax sheet
- Gas torch
- Cotton
- Rubber bowl with cold water
- Marking pencil




FIG 3.4.6.1 Armamentarium

Follow the steps of teeth setting as described in this Chapter under

Section 3.1.5 to arrange the missing teeth in both the arches. At the end of teeth setting, all the natural teeth have to maintain their interdigitation and occlusion with the corresponding natural teeth. The vertical rod has to be in contact with the incisal table.

Completed teeth arrangement

Figures 3.4.6.2 to 3.4.6.3 depict completed teeth arrangement.




FIG 3.4.6.2 Completed teeth arrangement—front and back views

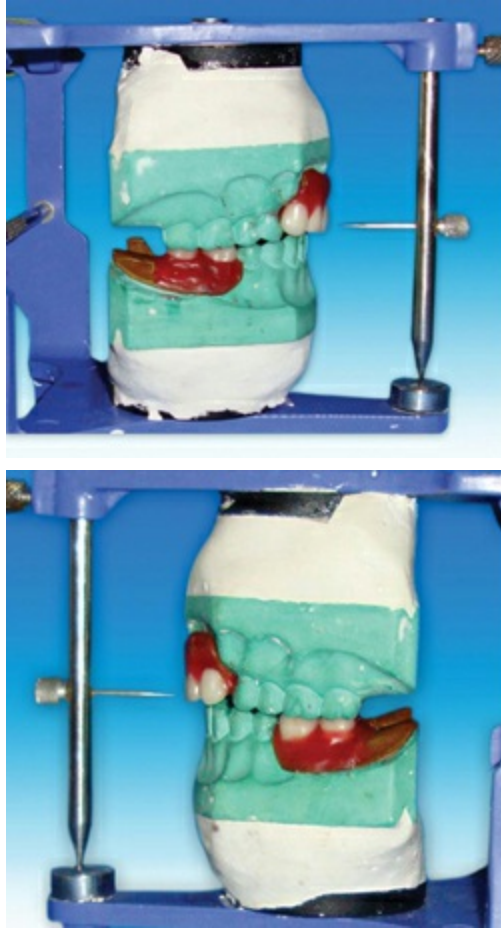


FIG 3.4.6.3 Completed teeth arrangement—right and left oblique views

3.4.7. Wax-up

Armamentarium (Fig 3.4.7.1)

- Maxillary trial denture with cast
- Mandibular trial denture with cast
- Mean value articulator
- Wax knife
- Roach carver
- Wax spatula
- Wax sheet
- Gas torch
- Modified bristle brush

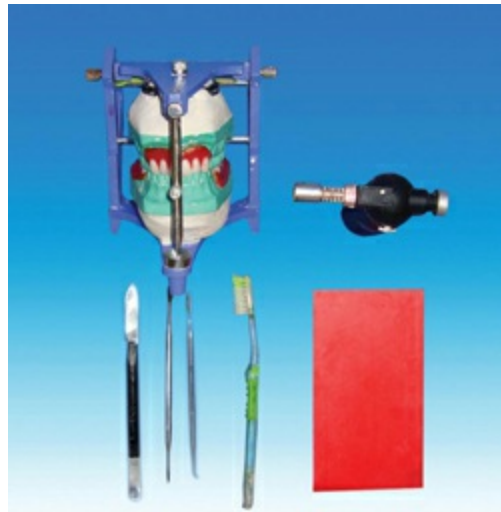

FIG 3.4.7.1 Armamentarium

Addition of wax in trial denture

Soften a roll of baseplate wax and adapt it on the shellac baseplate wherever it is necessary. Seal the baseplate wax around the necks of each artificial tooth with a wax spatula and along the collars in the

dentulous area (Fig 3.4.7.2).

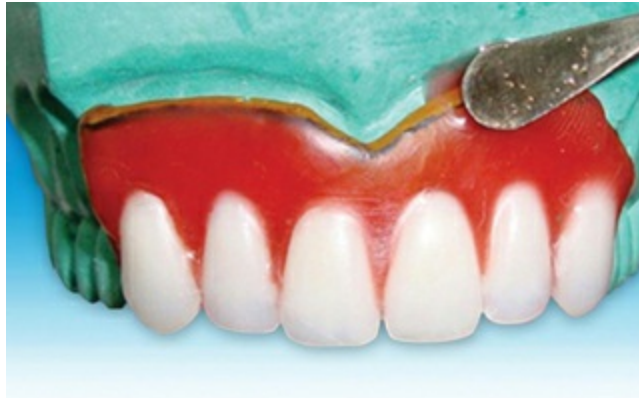

FIG 3.4.7.2 Sealing the maxillary trial base

Use a Roach carver to carve the gingival margins around the anterior teeth (Fig 3.4.7.3). Follow the finish line around the necks of the artificial teeth and remove all the wax remaining on the teeth above the finish line. Carve the wax to produce gingival papilla. It should be convex, both occlusogingivally and mesiodistally. Contour the wax to form root prominences and depressions.

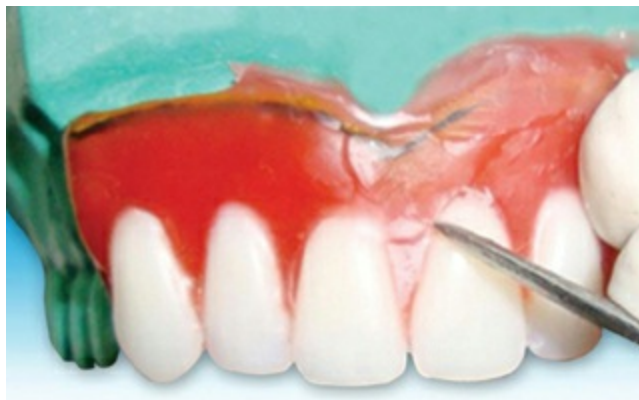

FIG 3.4.7.3 Carving the gingival margins

Use a gas torch to flame the wax surface taking care not to overheat the wax contours (Fig 3.4.7.4). Stipple the region of attached gingiva with a modified bristle brush (Fig 3.4.7.5).

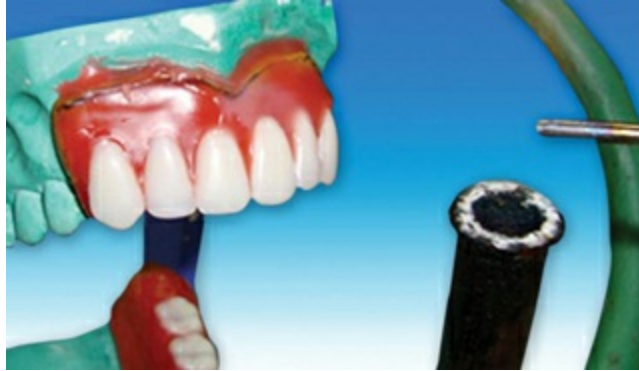
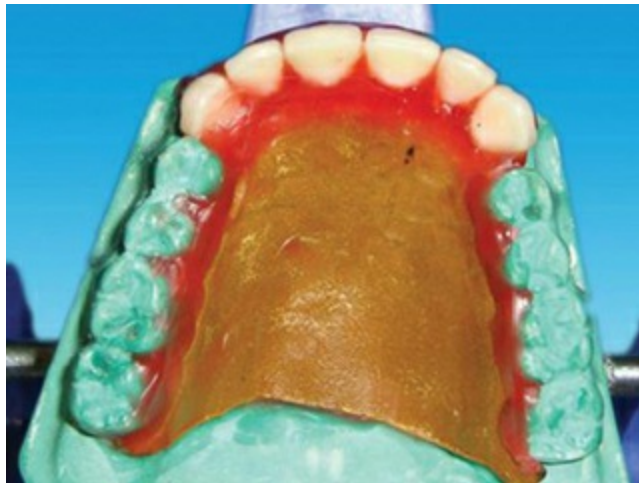
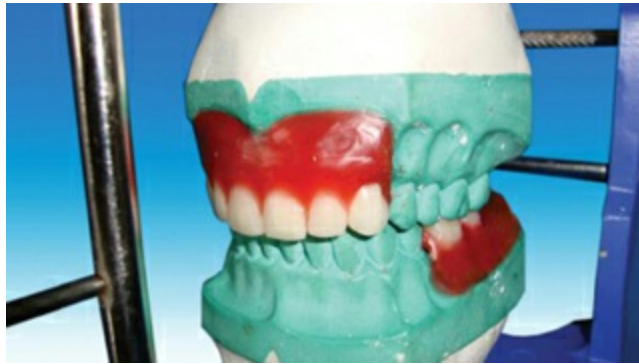FIG 3.4.7.4 Smoothing the gingival margins



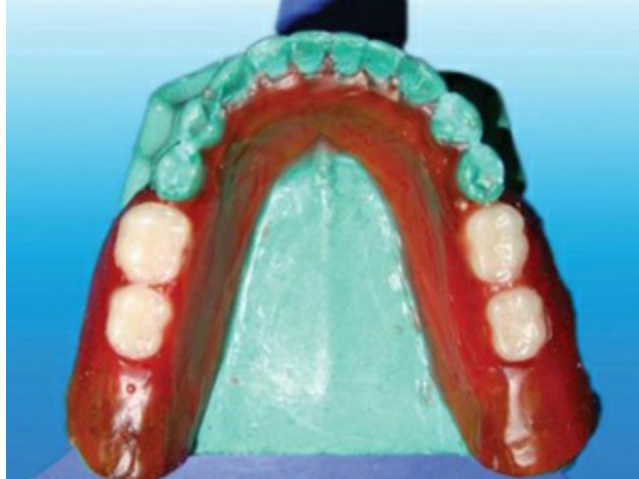

FIG 3.4.7.5 Completed waxed up partial dentures gingiva

The completed upper and lower trial dentures are depicted in [Figure 3.4.7.5](#).

At the end of wax-up check again for interdigitation and occlusion. Make sure the vertical rod is in contact with the incisal table.

3.4.8. Processing

Armamentarium (Fig 3.4.8.1)

- Maxillary trial denture
- Mandibular trial denture
- Wax spatula
- Wax sheet
- Gas torch
- Plaster knife
- Hammer
- Upper flasks
- Lower flask
- Vaseline
- Type II stone plaster
- Rubber bowl
- Spatula
- Sandpaper
- Cotton
- Wax carver
- Wax knife
- Separating medium
- Brush



FIG 3.4.8.1 Armamentarium

Seal the upper and lower partial trial dentures to the respective cast (Fig 3.4.8.2).

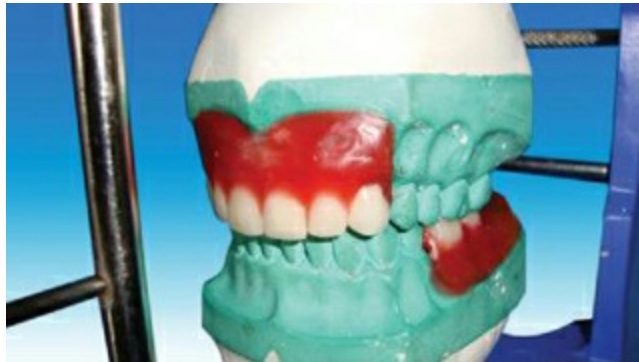

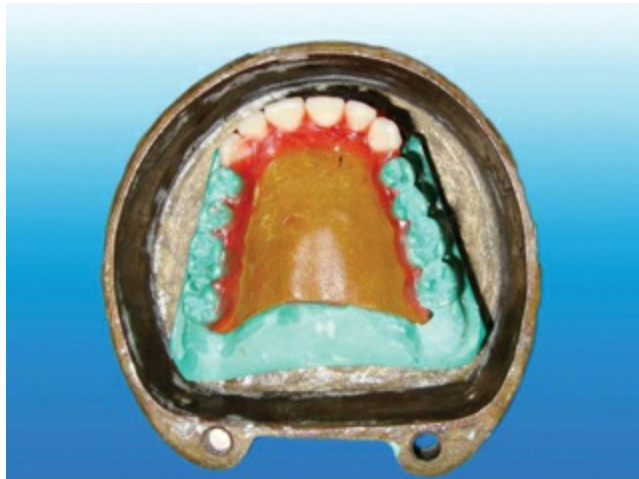FIG 3.4.8.2 Sealing upper and lower trial dentures

Dearticulate the upper and lower partial trial dentures. Lubricate the cast before flasking to facilitate easy deflasking (Fig 3.4.8.3).



FIG 3.4.8.3 Lubricating the base of the cast

Select an appropriate flask by placing the trial partial denture into it. Check for the height of denture teeth in the flask ([Fig 3.4.8.4](#)).



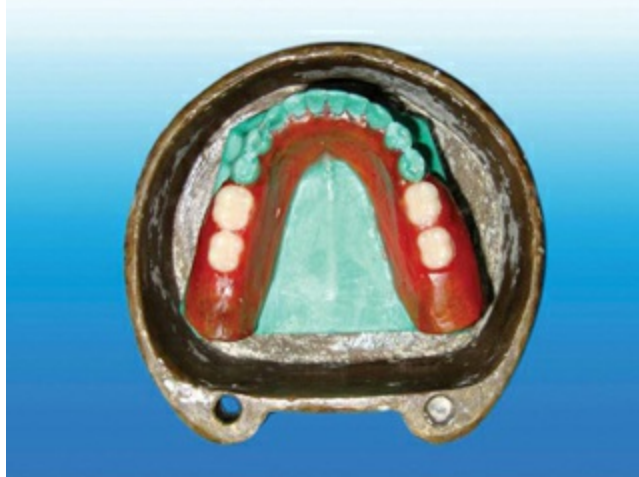

FIG 3.4.8.4 Placing trial partial denture in flask

Type II stone plaster is mixed with right proportion [w:p 30cc : 100 g, mixed for 30 seconds and vibrated for 15 seconds] and placed it in the flask (Fig 3.4.8.5).

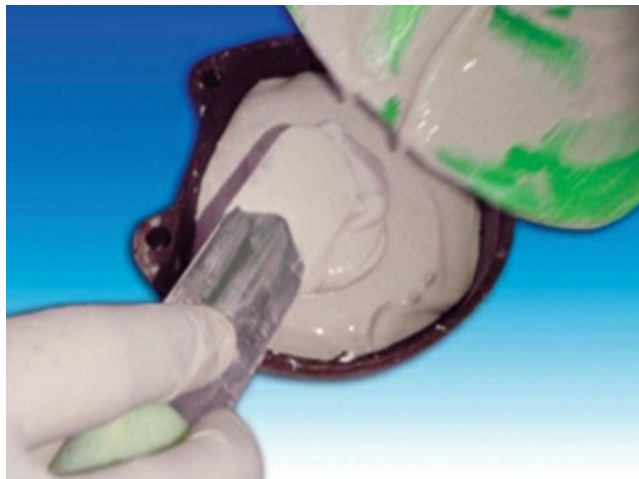

FIG 3.4.8.5 Mixing dental plaster

Press the partial trial denture into the flask and centre it to the flask (Fig 3.4.8.6).

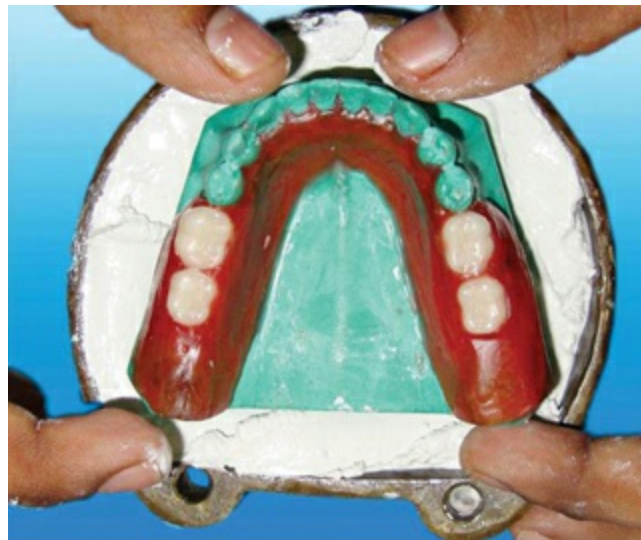
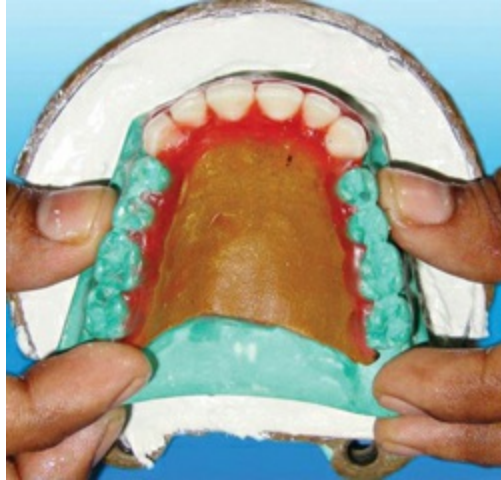
FIG 3.4.8.6 Pressing trial partial denture into the lower half of flask

Keep the occlusal plane approximately parallel to the base of the cast (Fig 3.4.8.7). Make sure the heel of lower cast should be at 45° angle and does not create any undercuts. Cover all the natural teeth with the plaster. Make sure to expose the wax surface and the artificial teeth.

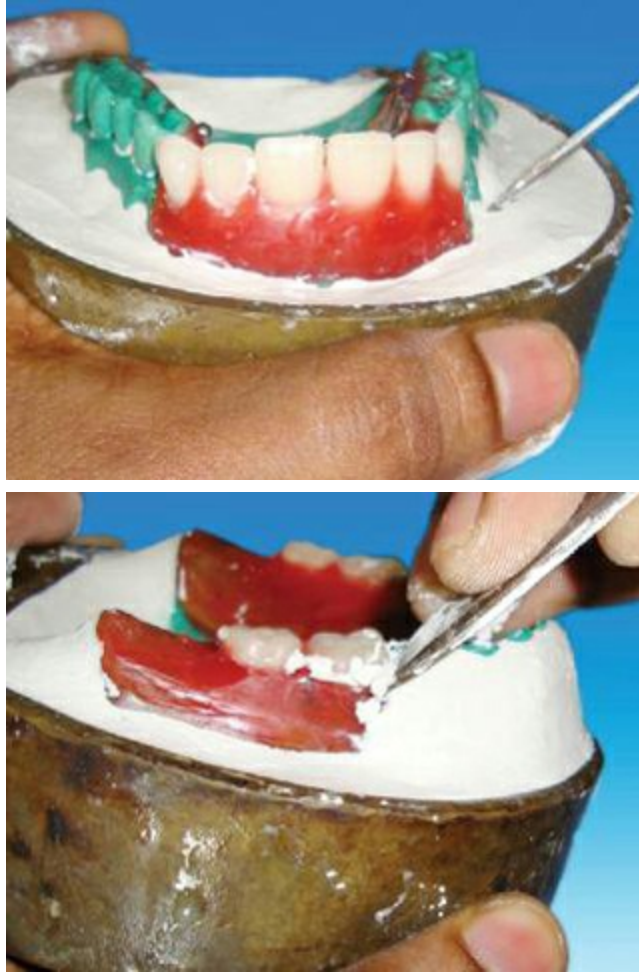

FIG 3.4.8.7 Maxillary and mandibular waxed partial dentures in the base of the flask

Remove stone as necessary and fill any deficient areas. Smoothen the stone plaster with cotton after its initial set. Further smoothing is done by the emery paper. Make sure there is no remnants of stone plaster on the rim of the flask ([Fig 3.4.8.8](#)).

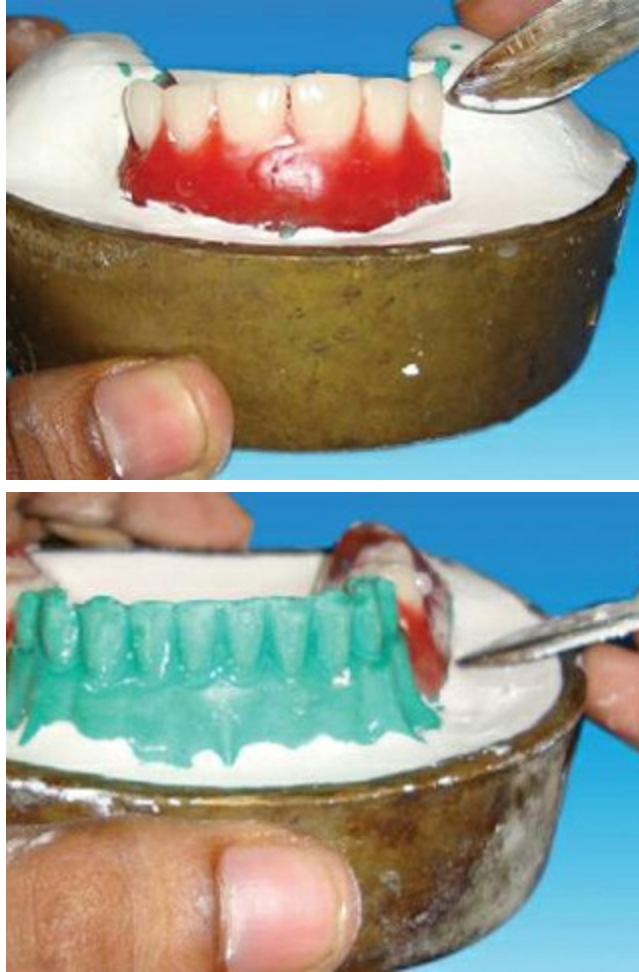


FIG 3.4.8.8 Removal of excess dental plaster

Place the top half of the flask into position and check for its complete seating and verify the incisal edges and occlusal surface of denture teeth are within it (Fig 3.4.8.9). Apply the separating medium all over the plaster surface. Avoid applying it over the wax surface and denture teeth.

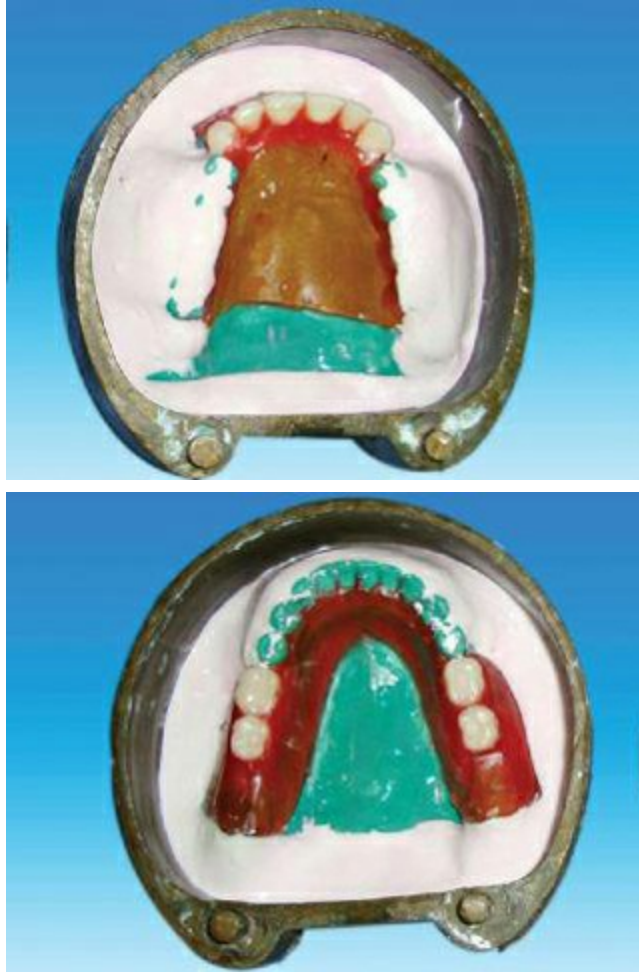

FIG 3.4.8.9 Check for clearance with top half of the flask

Place the upper half of the flask. Make a proper mix of Type II dental plaster. The mixed dental plaster is first applied on the artificial teeth with the help of the brush and the remaining dental plaster is filled from one side to avoid entrapment of air ([Fig 3.4.8.10](#)).

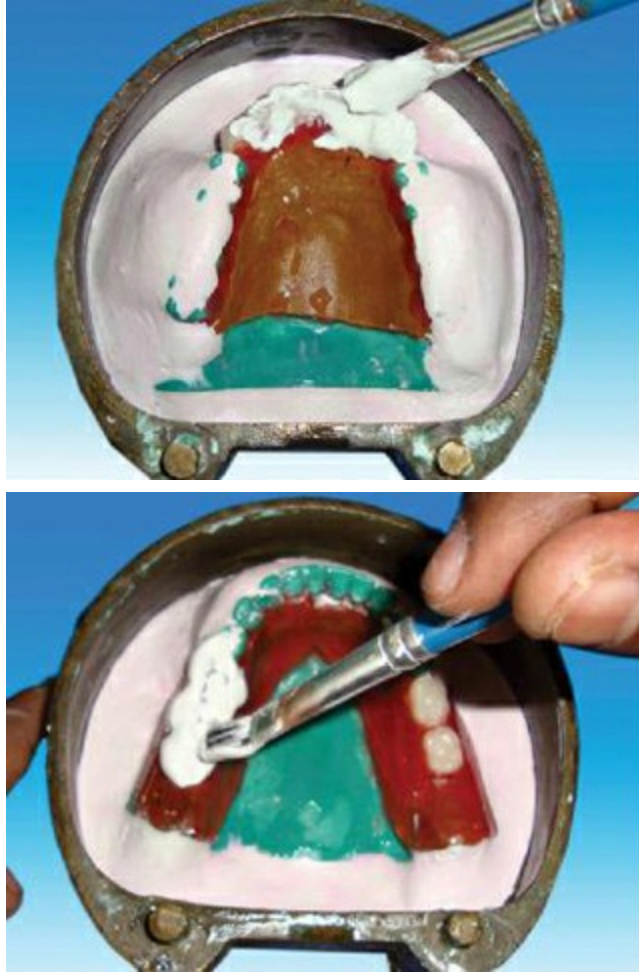


FIG 3.4.8.10 Flasking the top half of the flask

Fill the top half of the flask till the incisal and occlusal surfaces of the denture teeth ([Fig 3.4.8.11](#)). Remove the stone plaster with a finger to expose the occlusal surfaces of the denture teeth.




FIG 3.4.8.11 Dental plaster is removed from the occlusal surface of the artificial teeth

Once the dental plaster sets, mix the Type III stone plaster and fill the top surface of the flask ([Fig 3.4.8.12](#)).

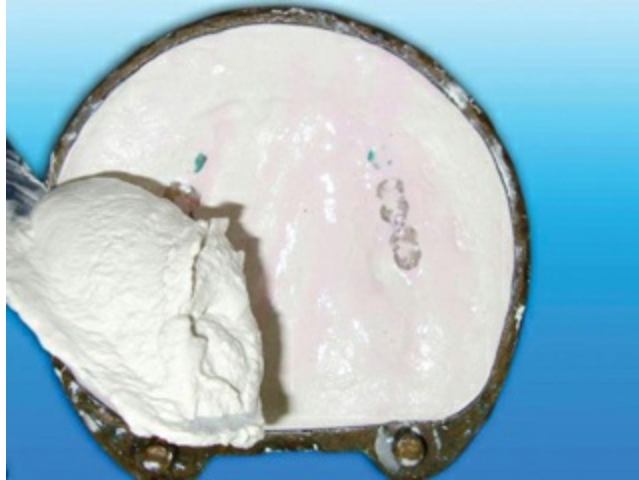

FIG 3.4.8.12 Pouring the dental stone

Fill it completely with Type III stone plaster ([Fig 3.4.8.13](#)).



FIG 3.4.8.13 Filling the flask with dental plaster

Place the lid on the filled flask and tap it gently ([Fig 3.4.8.14](#)).



FIG 3.4.8.14 Place the lid of the flask

Remove all the excess plaster material. Place the flask in the clamp assembly and tighten it completely (Fig 3.4.8.15).



FIG 3.4.8.15 Removing the excess and placing the flask in clamp

Flasking completed and the flask is ready for dewaxing ([Fig 3.4.8.16](#)).



FIG 3.4.8.16 Completed flask ready for dewaxing

Wax elimination, packing and processing

Wax elimination is done by following the steps given in this chapter under [Section 3.1.7](#) Processing ([Fig 3.4.8.17](#)).

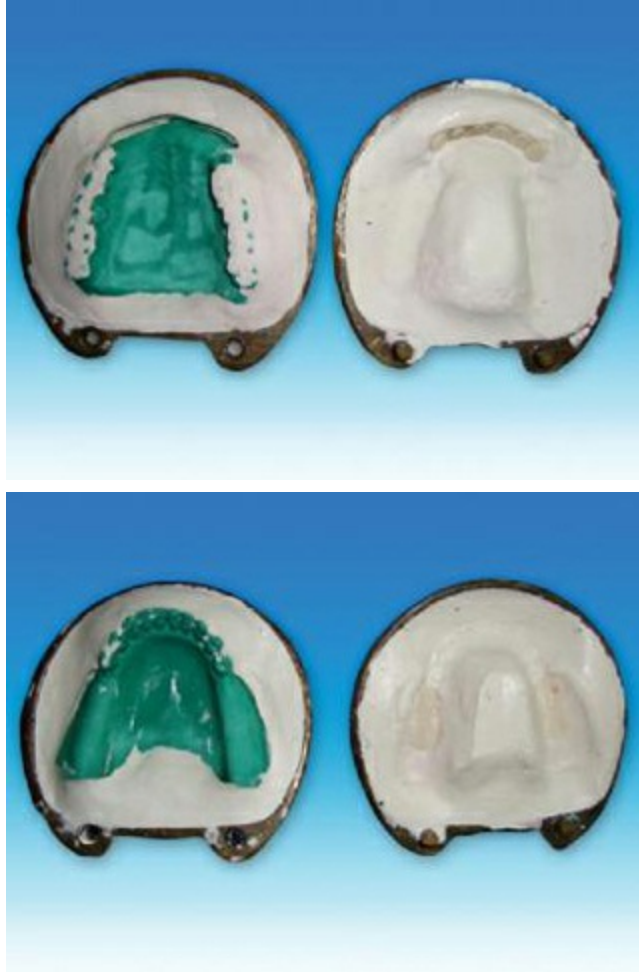

FIG 3.4.8.17 Completed wax elimination

Once the dewaxing is completed, allow the flasks to cool down. Packing is done by following the steps given under [Section 3.1.7](#) Processing of this chapter.

Packing is done and the flask is ready for curing. Allow it for bench set for 30 to 60 minutes ([Fig 3.4.8.18](#)).



FIG 3.4.8.18 Final closure of the flask after packing

Processing cycle

Processing cycle is of 1 and 1/2 hrs at 165°F followed by 30 minutes at a boil, followed by one hour of bench cooling before it is deflasked.

3.4.9. Finishing and polishing

Armamentarium (Fig 3.4.9.1)

- Maxillary denture with cast
- Mandibular denture with cast
- Plaster knife
- Hammer
- Saw blades with handle
- Shell blaster
- Arbour band
- Fissure bur
- Diamond disc
- Bard – Parker handle and no. 25 blade
- Sandpaper with mandrel
- Pumice
- Rag wheel
- Prophy cap
- No.200 finishing bur
- Brush and green soap



FIG 3.4.9.1 Armamentarium

Deflasking

Remove the flask from the clamp and lid from the flask and use a plaster knife between both halves of the flask and pry open the flask (Fig 3.4.9.2).



FIG 3.4.9.2 Removing flask from clamp

Slowly tap the plaster surface to remove the stone enclosing the denture from the flask. Place the plaster knife and tap slowly between the stone cap and rest of the stone surface (Fig 3.4.9.3).



FIG 3.4.9.3 Removing the stone enclosing the denture

Use saw blades and make several cuts at the stone surface. Gently remove the stone without damaging the partial dentures. Cuts are made along the labial or buccal surface of the stone teeth to eliminate undercuts and to remove the partial dentures without fractures (Fig 3.4.9.4).



FIG 3.4.9.4 Removal of stone using saw blades

Trim the flash from the partial denture with an arbor band or a large bur mounted on a micromotor (Fig 3.4.9.5).



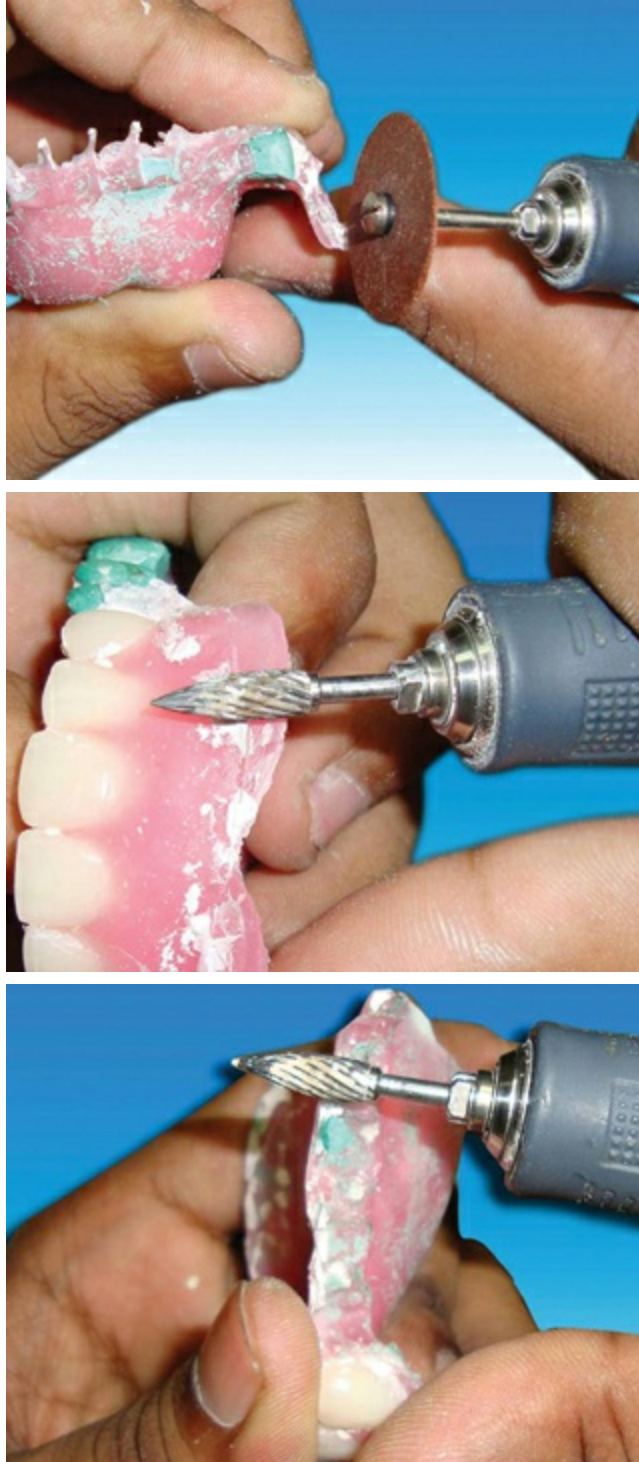


FIG 3.4.9.5 Trimming the partial denture

Trimming

A shell blaster is used in removing stone from the interior of the partial denture. After removing the stone completely from denture surface, it is ready for polishing (Fig 3.4.9.6).

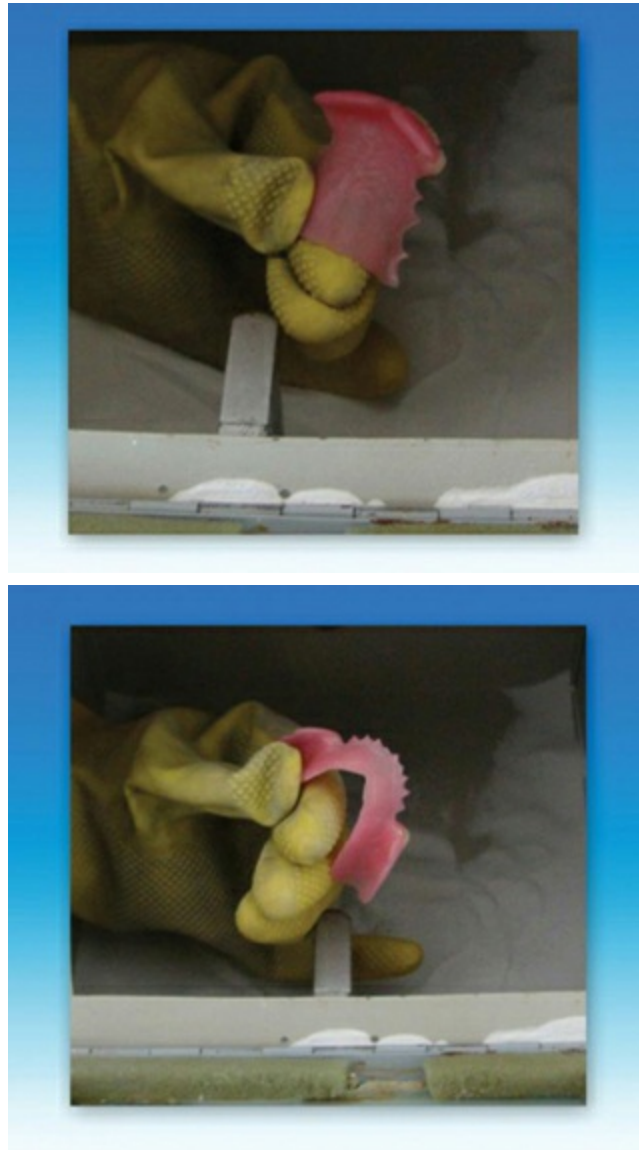


FIG 3.4.9.6 Removal of residual stone from the tissue surface of the partial denture

While trimming the collars, do not trim perpendicular to the collars. Collars are trimmed from the occlusal surface. Extension of acrylic into the cervical region below the collars has to be relieved as required

(Fig 3.4.9.7).

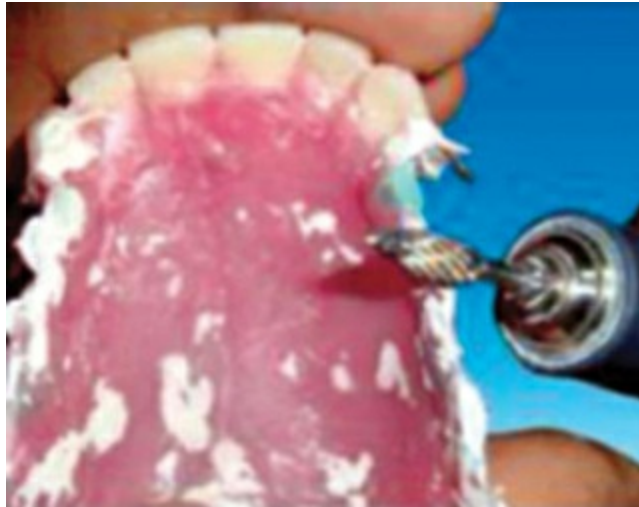
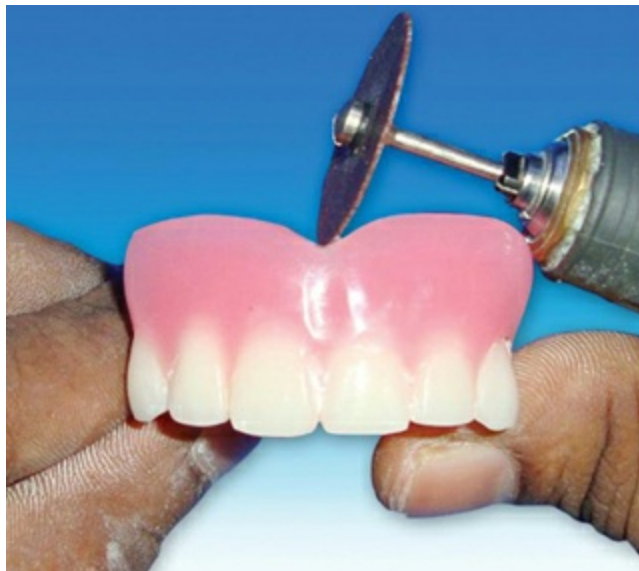
FIG 3.4.9.7 Trimming the collars

Complete the relief for the frenum attachment with a fissure bur/disc wherever necessary to create desired freedom (Fig 3.4.9.8).



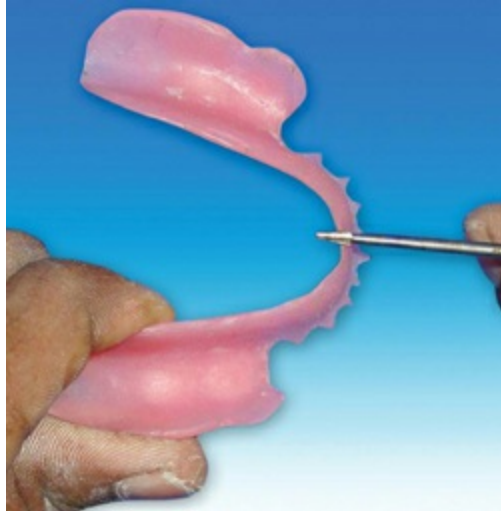
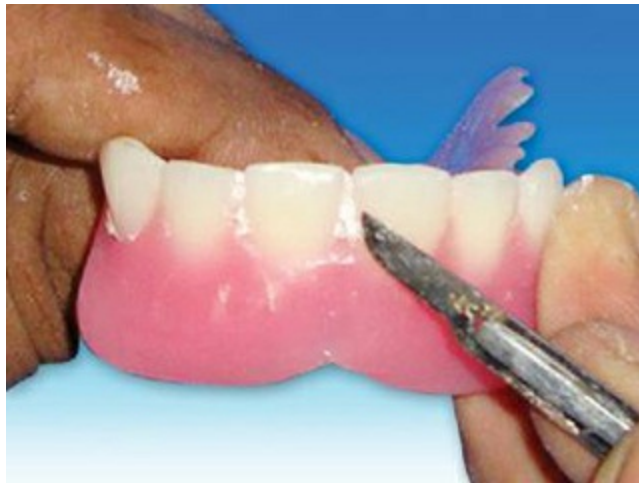

FIG 3.4.9.8 Relief from the labial and lingual frenum

Use a sharper instrument (Bard – Parker handle and a no. 25 blade) to remove the stone from the gingival margins ([Fig 3.4.9.9](#)).



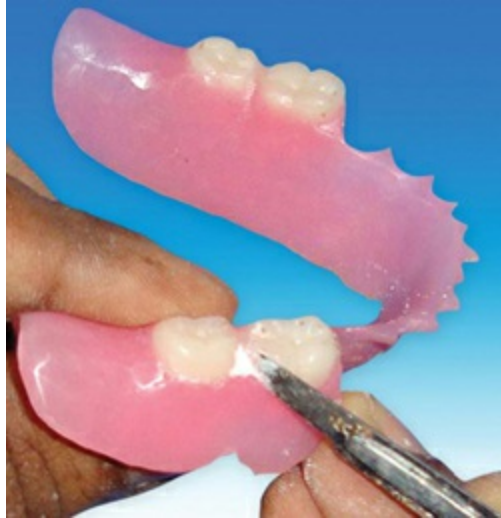
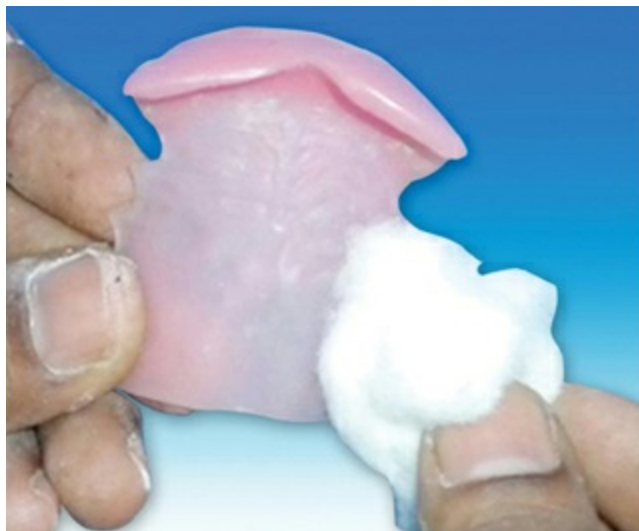
FIG 3.4.9.9 Removal of stone from gingival margins

Check the interior of the partial denture carefully with a finger to locate any modules of acrylic resin and remove them with a round bur. Use a rubber point mounted on a mandrel on a micromotor to remove scratches from the partial denture base ([Fig 3.4.9.10](#)).



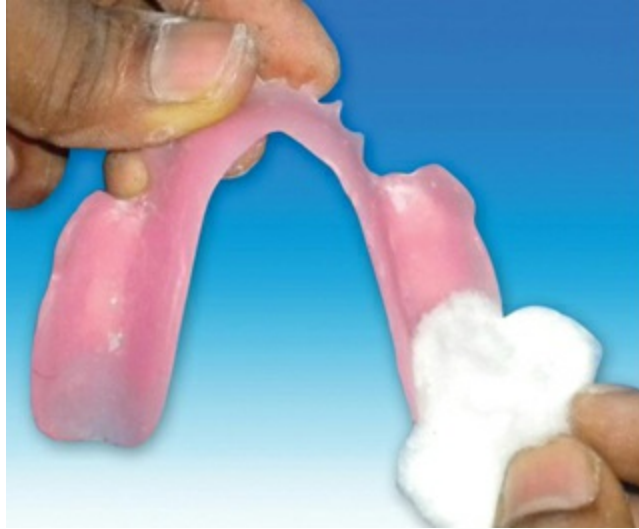

FIG 3.4.9.10 Checking the tissue surface

Use sandpaper mounted on a mandrel attached to a micromotor to remove finer scratches ([Fig 3.4.9.11](#)).

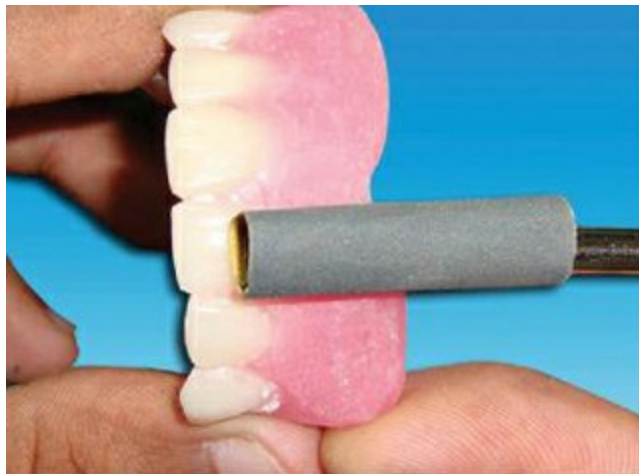
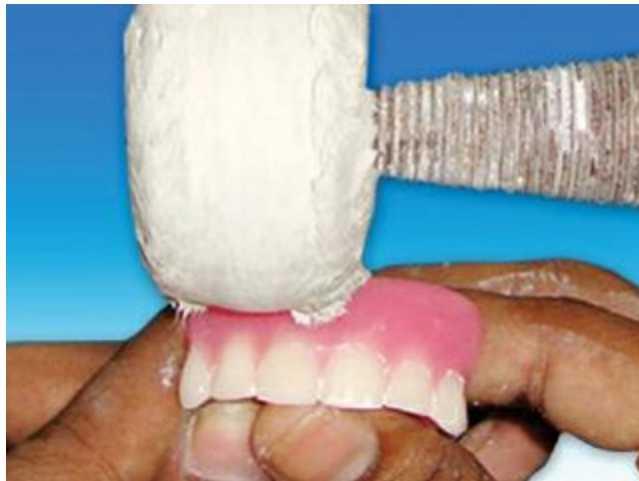


FIG 3.4.9.11 Removing finer scratches

Pumicing the denture

Make a slurry of fine flour of pumice with water using copier amounts of slurry with rag wheel polish the partial denture at low speed ([Fig 3.4.9.12](#)).



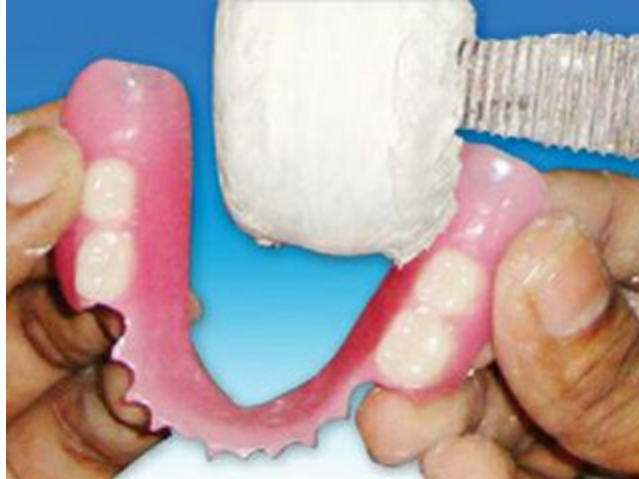

FIG 3.4.9.12 Slurry of pumice for polishing the partial dentures

Polish the palate and other areas of the partial denture which are not accessible to rag wheel with a prophy cap and slurry of pumice (Fig 3.4.9.13).

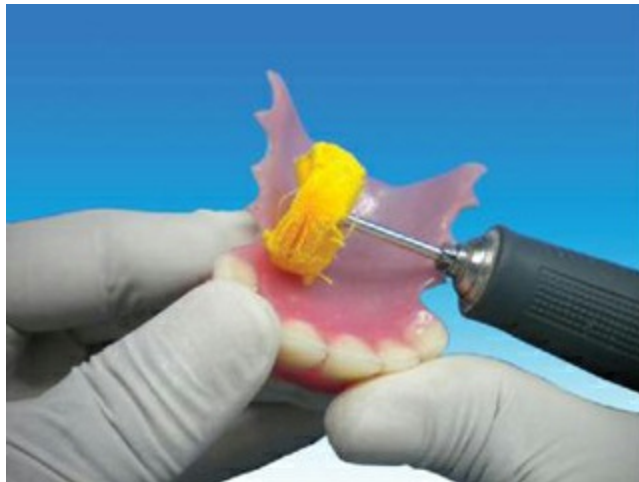

FIG 3.4.9.13 Polishing the palatal surface

Wash the partial denture thoroughly, dry it and examine it for any scratches. If scratches are found, repeat the pumicing (Fig 3.4.9.14).

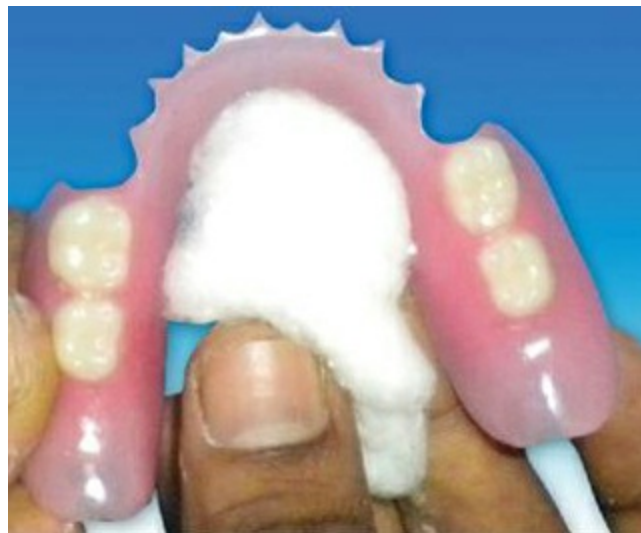
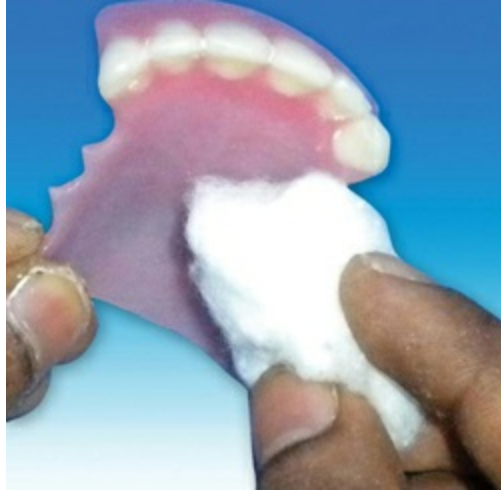
FIG 3.4.9.14 Examining for scratches on the polished surface

Brush the partial denture with green soap to remove all traces of polishing material ([Fig 3.4.9.15](#)).

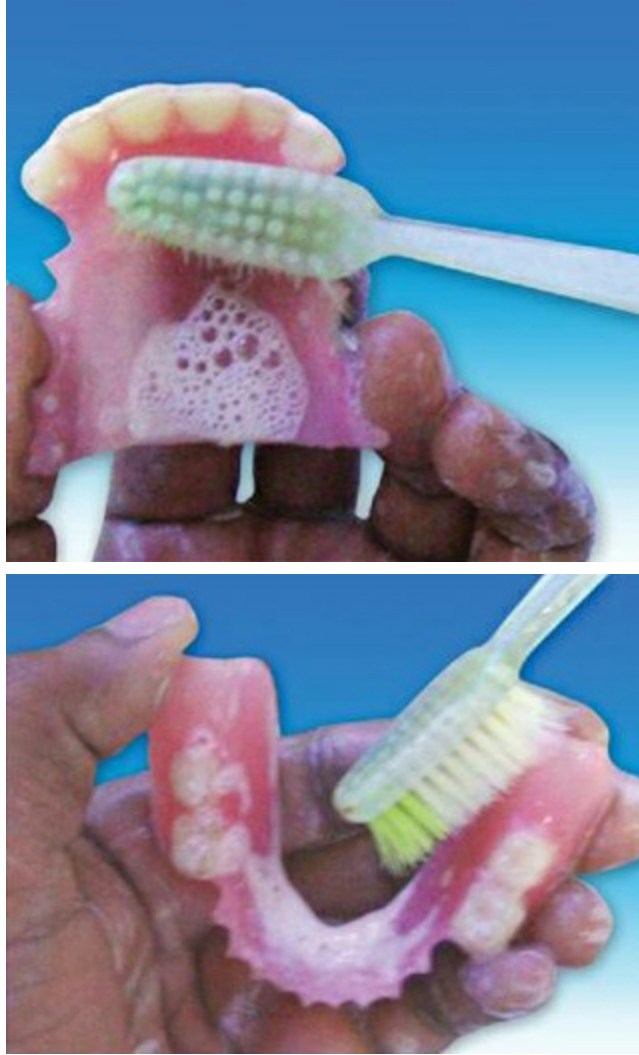
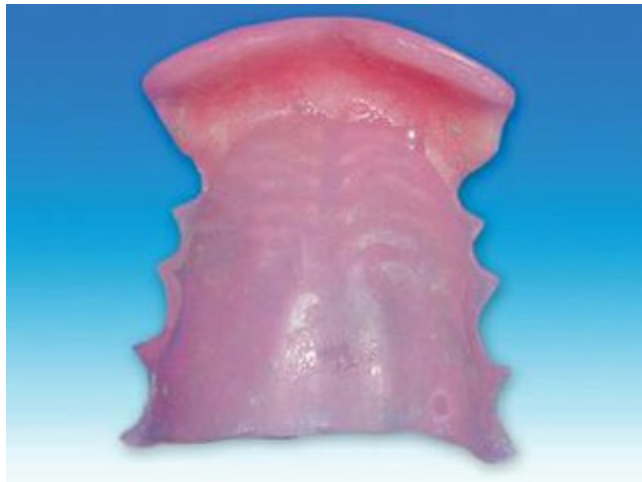
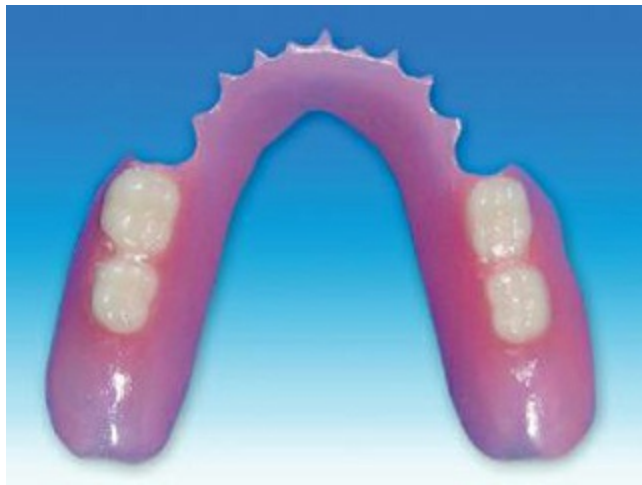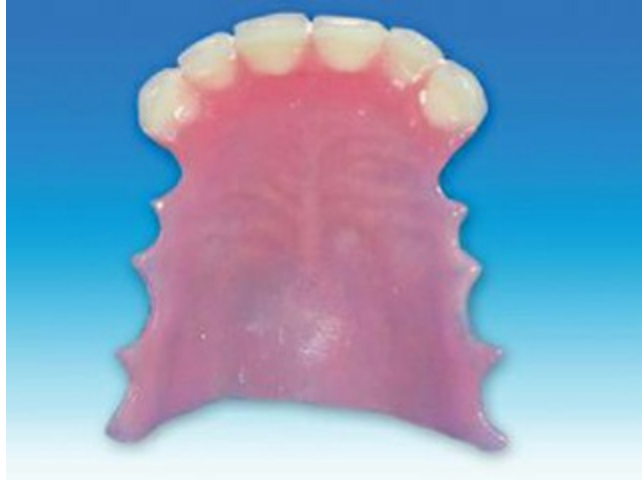FIG 3.4.9.15 Removing traces of polishing material

Examine the partial denture for any scratches. If found, repeat the pumicing procedures. Rinse the partial denture in water and store in a plastic container of water till needed ([Fig 3.4.9.16](#)).



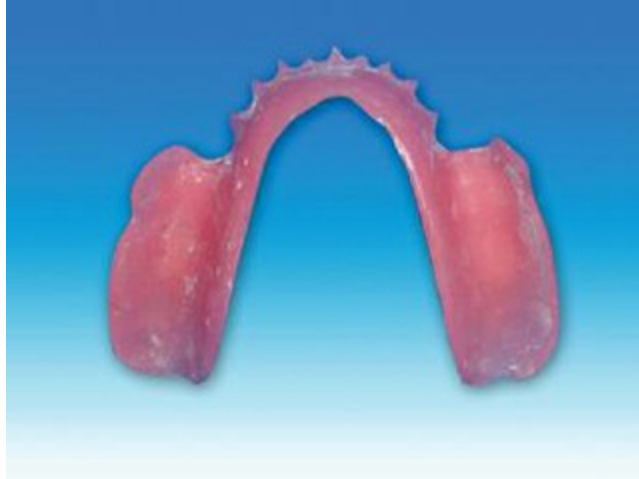

FIG 3.4.9.16 Completely polished upper and lower partial dentures

3.5 All ceramic crown preparation of central incisor tooth

Armamentarium (Fig 3.5.1)

"The armamentarium for the preparation of central incisor tooth to be restored with an all ceramic crown are:

1. Flat and tapered diamond
2. Wheel diamond
3. Finishing diamond



FIG 3.5.1 Armamentarium

The flat end tapered diamond is used to reduce all the axial surfaces and incisal surface. The flat end tapered diamond creates a shoulder finish line.

Steps in the preparation of central incisor tooth

1. Making of putty index

Before the beginning of preparation, it is important to make a putty index of the tooth to be prepared (Fig 3.5.2). Equal proportion of the base and the catalyst of addition silicone impression material of putty

consistency is mixed. The mix is adapted to the labial and palatal aspects of the tooth to be prepared.

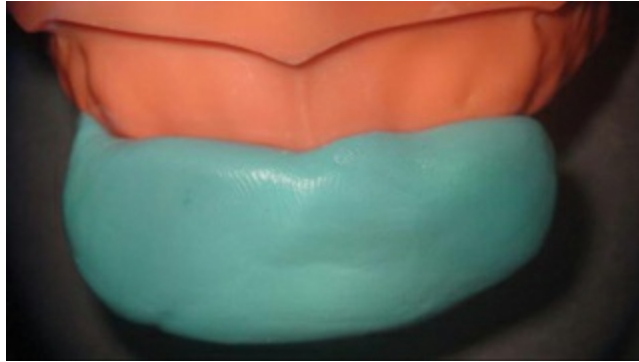

FIG 3.5.2 Putty index before tooth preparation

A labial index and a palatal index can be made splitting into labial and palatal halves (Fig 3.5.3). The index gives an indication of the amount of reduction on the labial and palatal aspects.

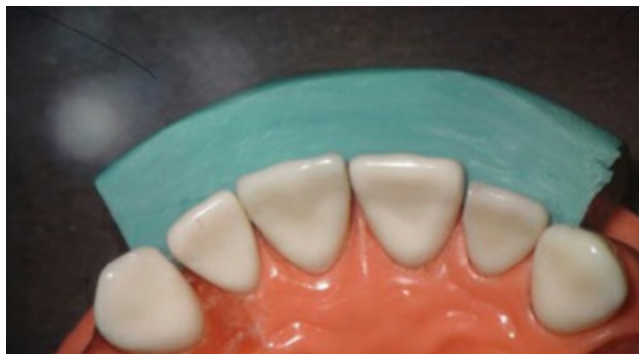

FIG 3.5.3 Labial index

A mid-sagittal index is prepared by sectioning the putty index along the midline of the tooth to be prepared (Fig 3.5.4).

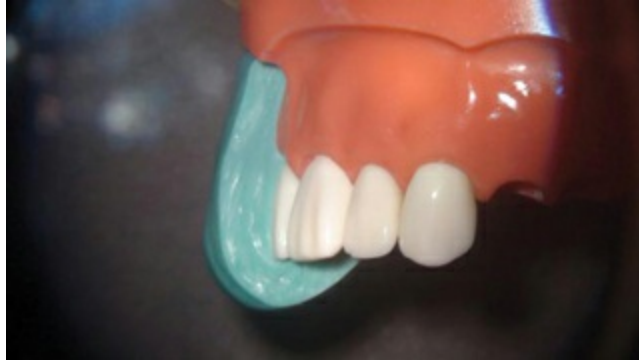

FIG 3.5.4 Mid-sagittal index

Flowchart of steps in preparation and the principles

Steps in Preparation	Principle
1. Incisal reduction	Structural durability
2. Labial reduction	Retention and resistance, structural durability, preservation of tooth structure
3. Lingual reduction	Retention and resistance, structural durability
4. Proximal reduction	Retention and resistance, structural durability
5. Finish margins	Marginal integrity, preservation of periodontium

2. Incisal reduction

Reduction of the incisal edge is done with a flat end tapered diamond (Fig 3.5.5a,b). A depth orientation groove is placed in the centre of the incisal edge to the level of 2 mm. The reduction is done from mesial incisal edge to distal incisal edge. The plane of the reduced surface should be parallel to the former incisal edge. An incisal bevel is placed on the incisal edge at an inclination of 45 degrees to the labial surface of the tooth (Figs 3.5.6 and 3.5.7a,b).

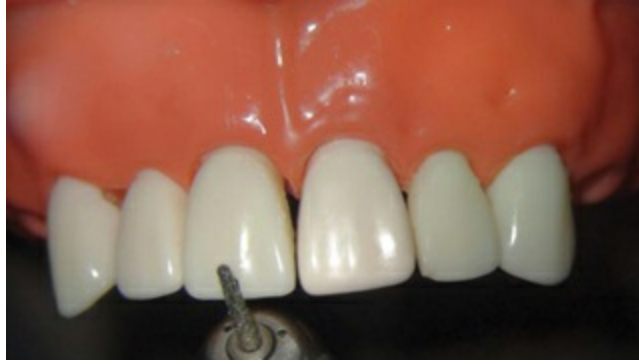

FIG 3.5.5A Depth orientation groove incisal reduction

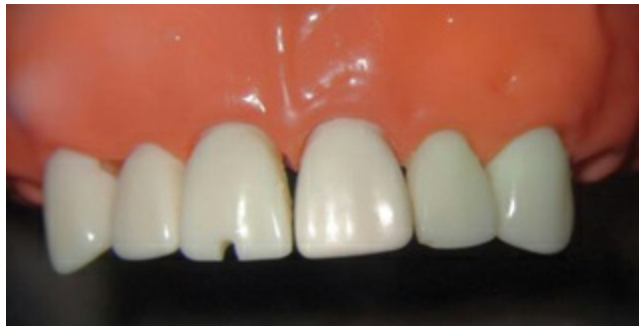

FIG 3.5.5B Depth orientation groove incisal bevel

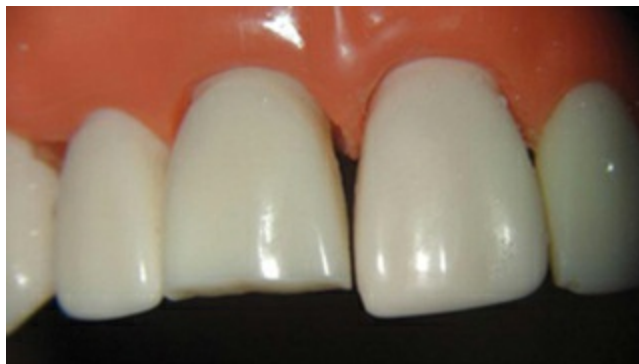

FIG 3.5.6 Incisal reduction—labial view

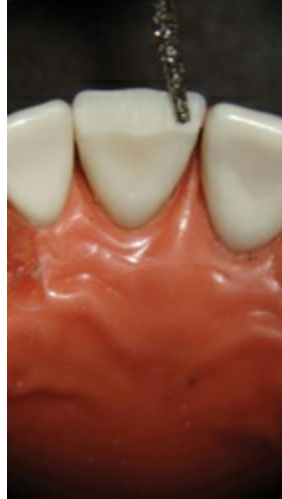

FIG 3.5.7A Incisal bevel

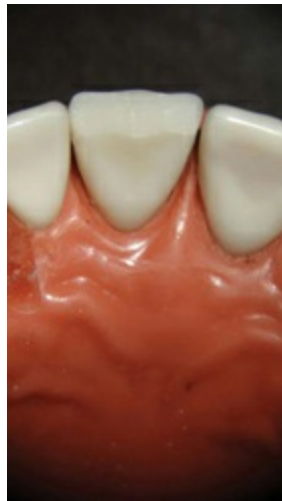

FIG 3.5.7B Incisal bevel—occlusal view

3. Labial reduction

The labial reduction is carried out with a flat end tapered diamond. The diamond is aligned parallel to the long axis of the tooth ([Fig 3.5.8](#)). A depth orientation groove is placed in the mesial or distal aspect on the labial surface ([Fig 3.5.9](#)). The diamond is inserted into the tooth to its full diameter. The tip of the diamond is placed slightly

supragingival. The labial reduction is done in two planes, the gingival half and the incisal half maintaining the natural contour of the labial surface. The labial reduction is carried from one proximal side to the other proximal side (Fig 3.5.10a, b). The orientation of the diamond should be parallel to the labial surface during the reduction and should be done in drawing or sweeping strokes of the diamond. The tip of the diamond creates the desired finish margin supragingivally. A reduction of about 1.2–1.4 mm is required for an optimum aesthetics of the final restoration. The reduction of the tooth structure in the interproximal region is wider than the diameter of the diamond. The lip or the undermined tooth structure in the interproximal surface is used as a protective barrier from nicking or damaging the adjacent tooth structure during preparation of proximal surface (Fig 3.5.11).

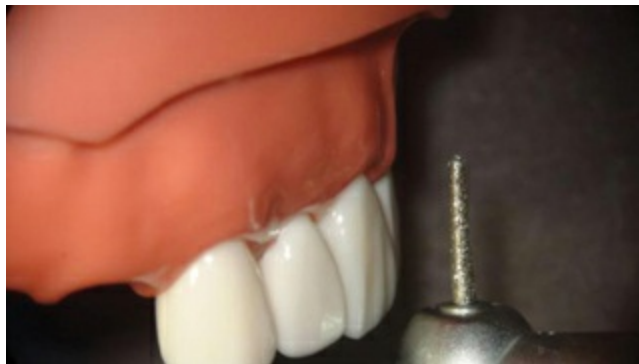


FIG 3.5.8 Positioning of the diamond point.

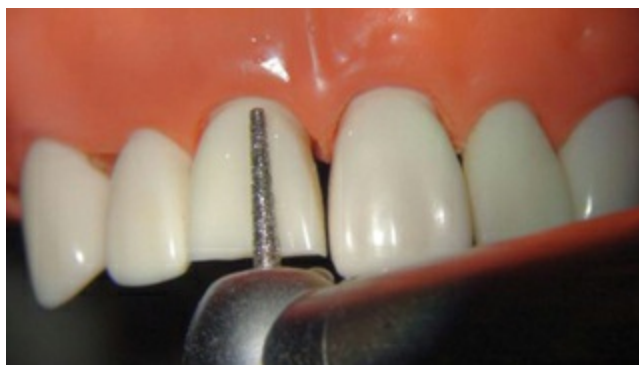


FIG 3.5.9 Depth orientation groove placement on the labial

surface

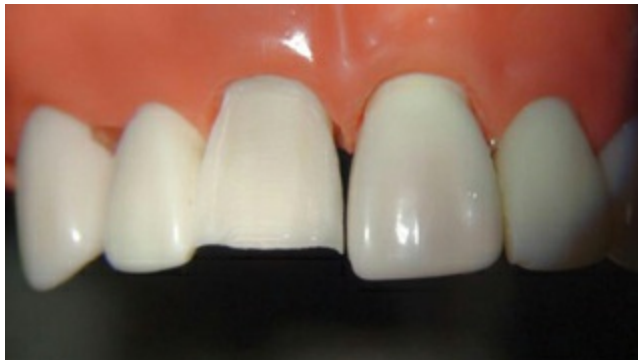

FIG 3.5.10A Labial reduction

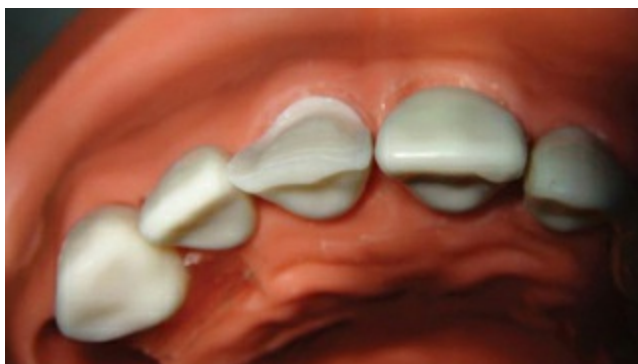

FIG 3.5.10B Labial reduction—occlusal view

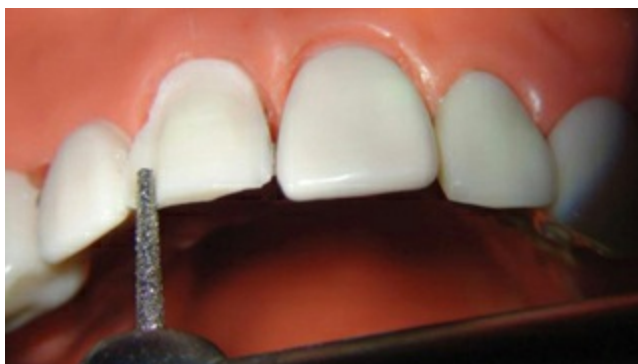

FIG 3.5.11 Labial reduction with proximal lip of enamel

4. Lingual reduction

The lingual reduction is carried out with a small wheel diamond (Fig 3.5.12a). The cingulum portion of the tooth is reduced. The amount of reduction on the lingual surface varies from 0.5 to 1 mm and depends on the clearance of space from the opposing teeth. The round edge wheel diamond is used to produce concave cingulum reduction. The wheel diamond is used in the direction of incisocervically and mesiodistally so that a distinct curve is produced in the cingulum. This curved surface will aid in the retention and resistance of the preparation.

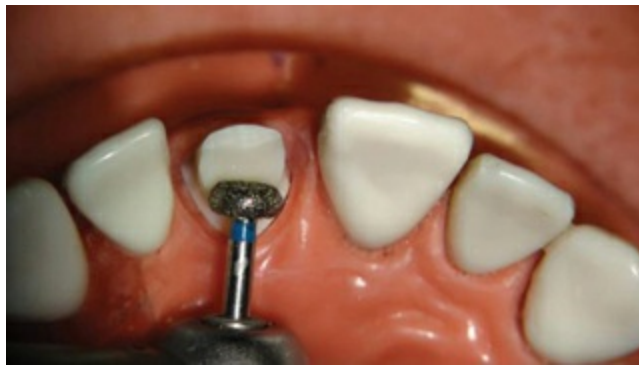

FIG 3.5.12A Lingual reduction using wheel diamond

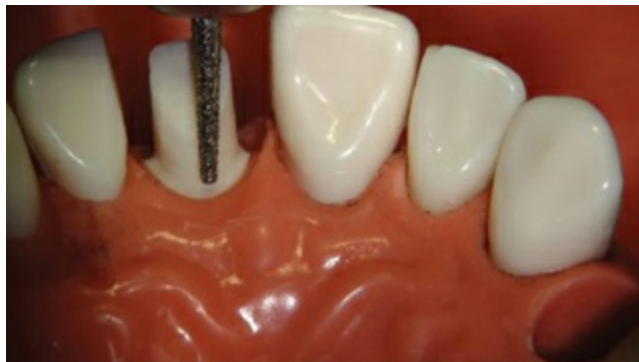

FIG 3.5.12B Lingual axial wall reduction

The lingual axial reduction is done with a flat end tapered diamond. The vertical lingual wall should be of 1mm into the tooth. The lingual axial wall should be parallel to the gingival portion of the labial surface. This aids in the resistance feature for the restoration (Fig 3.5.12b).

5. Proximal reduction

The labial and lingual reduction is extended through the proximal surface with a flat end tapered diamond producing a shoulder in the process (Fig 3.5.13). The lingual and the adjacent axial proximal reduction is carried out with same flat end tapered diamond. The axioproximal line angles are rounded off.

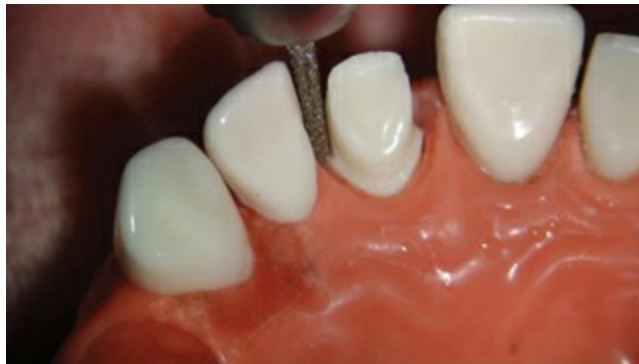

FIG 3.5.13 Proximal reduction using the flat end tapered diamond

6. Finishing

Finishing of all the axial walls is carried out with finishing diamond or tungsten carbide bur (Fig 3.5.14a,b). All the line angles and point angles are rounded off. Sharp line angles will cause stress concentration leading to fracture of the restoration (Fig 3.5.15).

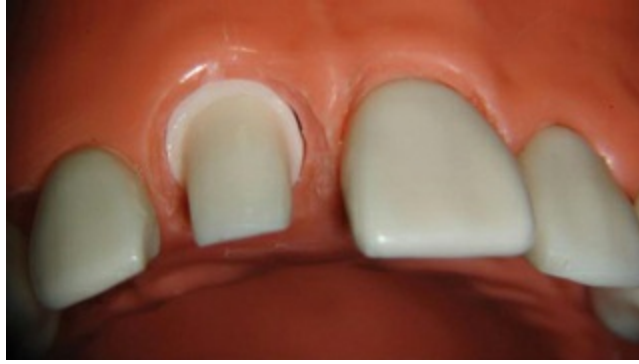

FIG 3.5.14A Finished preparation—labial view

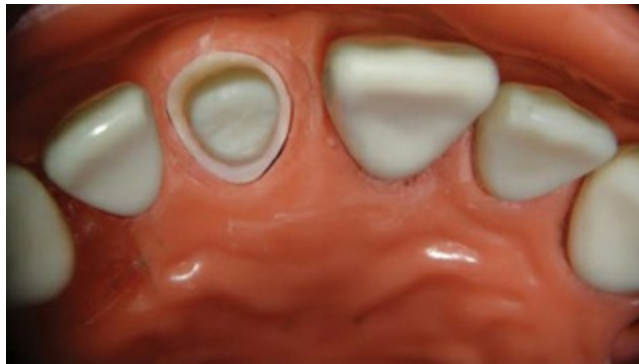

FIG 3.5.14B Finished preparation—lingual view

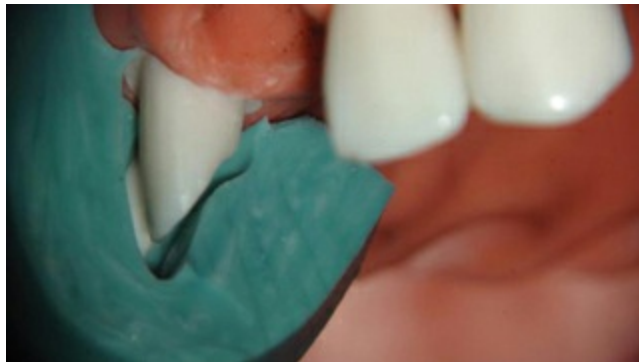

FIG 3.5.15 Finished preparation (assessment with the putty index)

CHAPTER 4

Common viva questions

CS Raj Mohan, S Lakshmi, D Sendhilnathan

What is prosthodontics?

Prosthodontics is a branch of dentistry pertaining to the diagnosis, treatment planning, rehabilitation and maintenance of the oral function, comfort, appearance and health of the patients with clinical conditions associated with missing or deficient teeth and or maxillofacial tissues using biocompatible substitutes.

What is complete denture prosthodontics?

A branch of prosthodontics pertaining to the restoration of the edentulous arch with a removable dental prosthesis.

What is a complete denture?

A removable dental prosthesis that replaces the entire dentition and associated structures of the maxillae or mandible; called a complete removable dental prosthesis.

What are the anatomical landmarks of the maxilla?

The anatomical landmarks are classified into:

1. Peripheral or limiting structures.
2. Supporting structures.

What are the supporting structures of maxilla?

The supporting structures of the maxilla are:

1. Hard palate
2. Residual ridge
3. Mucous membrane

What are the peripheral or limiting structures of maxilla?

1. Labial vestibule
2. Right and left buccal vestibule
3. The vibrating lines

What are the stress-bearing areas of maxilla?

The stress-bearing areas are primary and secondary.

- Primary: Hard palate and posterior lateral slopes of the residual alveolar ridge
- Secondary: Rugae area

What are the relief areas of maxilla?

The relief areas in the maxilla are:

1. Midpalatine raphe
2. Incisive papilla
3. Maxillary rugae
4. Anterolateral and posterolateral palatine glandular areas
5. Buccal surface of prominent tuberosities

Why is relief given over the midpalatine raphe?

The relief over the midpalatine region is given during the making of final impression because the median palatine suture area is covered with mucous membrane and little submucosal tissue. This area may require selective relief within the denture base. This relief compensates for movement of the maxillary denture that could result in a fulcrum response and causes pain and soreness.

Why is relief given over the incisive papilla?

Nasopalatine vessels and nerves exit through the incisive foramen. Incisive papilla is located above the incisive foramen. Compression of the papilla causes paraesthesia of soft tissues in the anterior region.

What is postpalatal seal?

The seal area at the posterior border of a maxillary removable complete dental prosthesis.

What is posterior palatal seal area?

The soft tissue area at or beyond the junction of the hard and soft palates on which pressure, within physiologic limits, can be applied by a complete removable denture prosthetics to aid in its retention.

What are the boundaries of posterior palatal seal?

The posterior palatal seal is bounded:

- Anteriorly by anterior vibrating line
- Posteriorly by posterior vibrating line
- Medially from one tuberosity to the other
- Laterally extends through the pterygomaxillary notch continuing for 3–4 mm anterolaterally approximating the mucogingival junction.

What are the functions of the posterior palatal seal?

The functions of posterior palatal seal are:

1. Primarily aids in retention.
2. Reduces the patient's awareness of this area hence reduces gag reflex.
3. Prevents food accumulation beneath the denture.
4. Reduces patient discomfort when contact occurs between dorsum of the tongue and the posterior extent of denture.
5. Compensates for volumetric shrinkage of the acrylic resin.

Define vibrating lines.

An imaginary line across the posterior part of the palate marking the division between the movable and immovable tissues of the soft palate. This can be identified when the movable tissues are in function.

What are the anatomical landmarks of the mandible?

The anatomical landmarks are classified into:

1. Peripheral or limiting structures.
2. Supporting structures.

What are the supporting structures of mandible?

The supporting structures of mandible are:

1. Crest of the residual alveolar ridge.
2. The buccal shelf.

What are the anatomical features influencing the supporting structures of mandible?

1. Mylohyoid ridge
2. Mental foramen
3. Genial tubercles
4. Torus mandibularis

What are the peripheral or limiting structures of mandible?

1. Labial border
 - a. Labial vestibule
 - b. Buccal vestibule
2. Lingual border
 - a. Mylohyoid muscle
 - b. Retromylohyoid fossa
 - c. Sublingual gland region
 - d. Alveololingual sulcus

Which is the primary stress bearing area of mandible and why?

Buccal shelf area is the primary stress bearing area of the mandible. The bone of buccal shelf is covered by a layer of cortical bone and the buccal shelf lies at right angles to the vertical occlusal forces, hence it is called as primary stress bearing area.

What are the boundaries of buccal shelf area?

The boundaries of buccal shelf area are:

- Anteriorly by the buccal frenum.
- Posteriorly by the anterior border of the retromolar pad.
- Medially by the crest of the residual alveolar ridge.
- Laterally by the external oblique ridge.

What are the relief areas of the mandibular arch?

1. Crest of lower anterior ridge
2. Prominent genial tubercles
3. Mental foramen
4. Torus mandibularis (if present)

Define an impression.

A negative likeness or copy in reverse of the surface of an object; an imprint of the teeth and adjacent structures for use in dentistry.

Define a dental impression.

A negative imprint of an oral structure used to produce a positive replica of the structure to be used as a permanent record or in the production of a dental restoration or prosthesis.

What are the basic objectives of impression making?

The objectives of impression making are:

1. Preservation of the alveolar ridges
2. Retention
3. Aesthetics
4. Stability
5. Support

What are the theories in impression making?

The theories in impression making are:

1. Pressure technique/functional pressure impressions
2. Nonpressure technique/minimal pressure impressions
3. Selective pressure technique

What are the techniques of impression making?

The techniques of impression making depends on:

- Amount of pressure used
- Open or closed mouth
- Hand manipulation/functional movements
- Type of tray – using custom tray and prefabricated tray

What is a preliminary impression?

A negative likeness made for the purpose of diagnosis, treatment planning or the fabrication of a custom impression tray.

Define an impression tray

A receptacle into which suitable impression material is placed to make a negative likeness. A device that is used to carry, confine, and control impression material while making an impression.

What is a stock tray?

A metallic or a nonmetallic prefabricated impression tray typically available in various sizes and used principally for preliminary impressions.

What is a custom tray?

An individualized impression tray made from a preliminary cast recovered from a preliminary impression. It is used for making a final impression.

What are the materials used to fabricate a custom tray?

The materials used to fabricate the custom tray are:

1. Acrylic resin
 - a. Self-cure
 - b. Heat-cure
 - c. Light-activated
2. Shellac base plates.

What should be the position, size and shape of the tray handle?

Anterior handle centred over the labial flange in the approximate position of the anterior teeth, height 20 mm, 3–4 mm thick. Posterior handles at first molar area, centre of the ridge, 20 mm in height.

What is the purpose of the tissue stops?

The tissue stops in the custom trays prevent the apical displacement of the tray while making the final impression and help to reseat the custom tray during the final impression.

Define a cast.

A life size likeness of some desired form. It is formed within or is a material poured into a matrix or impression of desired form.

What is a preliminary cast?

A cast formed from a preliminary impression for use in diagnosis or the fabrication of a custom impression tray.

What is a diagnostic cast?

A life size reproduction of a part or parts of the oral cavity and/or facial structures for the purpose of study and treatment planning.

What is a master cast?

A replica of the tooth surfaces, residual ridge areas and/or other parts of the dental arch and/or facial structures used to fabricate a dental restoration or prosthesis, which is also called final cast.

What are the requirements of a cast?

The requirements of the cast include:

1. All anatomic surfaces of the final impression.
2. A full peripheral border with a depth of 2—3 mm.
3. A 2—3 mm of land area around the entire periphery of the master cast.
4. The land area that should be slightly tapered outward.
5. The base of a cast that should not be less than 10—12 mm at the thinnest point.
6. No voids or flaws.

Define a die.

A positive reproduction of the form of a prepared tooth in any suitable substance.

What is border seal?

The contact of the denture border with the underlying or adjacent tissues to prevent the passage of air or other substances.

What is border movement?

Mandibular movement at the limits dictated by anatomic structures, as viewed in a given plane.

What is border tissue movements?

The action of the muscles and other tissues adjacent to the borders of a denture.

What is peripheral tracing/border moulding?

1. The shaping of the border areas of an impression material by functional or manual manipulation of the soft tissue adjacent to the borders to duplicate the contour and size of the vestibule.
2. Determining the extension of a prosthesis by using tissue function or manual manipulation of the tissues to shape the border areas of an impression material.

What are the materials used for border moulding?

The materials used for border moulding are:

- Greenstick compound
- Putty consistency of elastomeric impression material.

What is a wash impression?

The impression that represents the completion of the registration of the surface or object.

What are the materials used for making final impression?

The materials used for making final impression are:

- Impression plaster
- Zinc oxide–eugenol impression paste
- Light body consistency of addition silicone impression material
- Polyether impression material.

What is a record base?

An interim denture base used to support the record rim material for recording maxillomandibular records.

What are the requirements of a record base?

1. It should adapt to the basal seat area as the finished denture base.
2. It should have the same border form as the finished denture base.
3. It should be sufficiently rigid to resist biting forces.
4. It should be dimensionally stable.
5. It should permit its use as a base for setting up teeth.
6. It should be possible to construct record bases quickly, easily and inexpensively.
7. It should have no undesirable colour.
8. It should not abrade the cast during removal and replacement.

What are the requirements for record base material?

1. It should be readily adapted to the required shape and contours with a minimum of time, expense and technical skill.
2. It should be rigid and strong in relatively thin sections.
3. It should not exhibit flow at mouth temperature.
4. The record base should not warp or distort appreciably during the procedures required for denture fabrication.
5. Exhibit a colour that will not distract from viewing the arrangement of the teeth of the trial denture as they will appear in the complete denture.

What are the permanent record base fabricating materials?

The basic materials that are used for permanent record bases are:

1. Processed heat-cure acrylic resin
2. Gold alloys
3. Chromium-cobalt alloy.

What are the temporary record base materials?

The basic materials that are frequently used are:

1. Shellac base plate wax.
2. Cold-curing acrylic resin.
3. Light-curing acrylic resin.

What is an occlusal rim?

The occlusal surfaces fabricated on a record base for the purpose of making maxillomandibular relationship records and/or arranging teeth.

What is an articulator?

A mechanical instrument that represents the temporomandibular joints and jaws, to which maxillary and mandibular casts may be attached to simulate some or all mandibular movements.

What are the functions of an articulator?

The primary functions of an articulator are:

1. The articulator should be capable of producing some degree of movements.
2. Mounting of dental casts for diagnosis, treatment planning and patient presentation.
3. Fabrication of occlusal surfaces for dental restorations.
4. Arrangement of artificial teeth for complete and removable partial dentures.

What are the requirements of an articulator?

Minimal requirements

1. The articulator must accurately maintain the correct horizontal and vertical relationship of the patient's cast.
2. The patient's cast must be easily removable and attachable to the articulator without losing their correct horizontal and vertical relationship.
3. The articulator should have an incisal guide pin with a positive stop that is adjustable and calibrated.
4. The articulator should be able to open and close in a hinge-like fashion.
5. The articulator should accept a face-bow transfer utilizing an anterior reference point.
6. The articulator should be accurate, rigid, made of a noncorrosive material. The moving parts should resist wear.
7. There should be adequate distance between the upper and lower members. It should be stable and not bulky.

Additional requirements

1. The condylar guides should allow right lateral, left lateral and protrusive movements.
2. The condylar guides should be adjustable horizontally.
3. The articulator should have provisions for adjustment of Bennett movement.
4. The incisal guide table should be a mechanical table that can be adjusted in the sagittal and frontal planes.

What are the theories of articulation?

The three theories of articulation are:

1. Bonwill's theory
2. Monson's spherical theory
3. Conical theory

What is bonwill's theory?

Described by Bonwill in 1858, a 4-inch equilateral triangle bounded by lines connecting the contact points of the mandibular central incisor's incisal edge (or the midline of the mandibular residual ridge) to each condyle (usually its midpoint) and from one condyle to the other.

What is monson's spherical theory?

An arrangement of teeth that places their occlusal surfaces on the surface of an imaginary sphere (usually 8 inches in diameter) with its centre above the level of the teeth.

What is angle classification of malocclusion?

It is a classification system of occlusion based on the interdigitation of the first molar teeth originally described by Angle as four major groups depending on the anteroposterior jaw relationship.

1. Class I molar relation
2. Class II molar relation
3. Class III molar relation

What is horizontal overlap or overjet?

The horizontal relationship of the incisal edges of the maxillary incisors to the mandibular incisors when the teeth are in maximum intercuspation.

What is vertical overlap or overbite?

The vertical relationship of the incisal edges of the maxillary incisors to the mandibular incisors when the teeth are in maximum intercuspation.

What is compensating curve?

The anteroposterior curving (in the median plane) and the mediolateral curving (in the frontal plane) within the alignment of the occluding surfaces and incisal edges of artificial teeth that is used to develop balanced occlusion.

The arc introduced in the construction of complete removable dental prostheses to compensate for the opening influences produced by the condylar and incisal guidance's during lateral and protrusive mandibular excursive movements which is also called compensating curvature.

What is curve of occlusion?

The average curve established by the incisal edges and occlusal surfaces of the anterior and posterior teeth in either arch.

What is curve of monson?

It is a proposed ideal curve of occlusion in which each cusp and incisal edge touches or conforms to a segment of the surface of a sphere 8 inches in diameter with its centre in the region of the glabella.

What is curve of pleasure?

It is a helicoid curve of occlusion that, when viewed in the frontal plane, conforms to a curve that is convex from the superior view, except for the last molars which reverse that pattern.

What is anti-monson curve or reverse curve?

In excessive wear of the teeth, the obliteration of the cusps and formation of either flat or cupped-out occlusal surfaces, associated with reversal of the occlusal plane of the premolar, first and second molar teeth (the third molars being generally unaffected), whereby the occlusal surfaces of the mandibular teeth slope facially instead of lingually and those of the maxillary teeth incline lingually.

What is curve of spee?

Curve of Spee is an anteroposterior curve. The anatomic curve established by the occlusal alignment of the teeth, as projected onto the median plane, beginning with the cusp tip of the mandibular canine and following the buccal cusp tips of the premolar and molar teeth, continuing through the anterior border of the mandibular ramus, ending with the anterior most portion of the mandibular condyle. It was first described by Ferdinand Graf Spee, German anatomist, in 1890.

What is curve of wilson?

1. Eponym for the mediolateral curve.
2. In the theory that occlusion should be spherical, the curvature of the cusps as projected on the frontal plane expressed in both arches; the curve in the lower arch being concave and the one in the upper arch being convex. The curvature in the lower arch is affected by an equal lingual inclination of the right and left molars so that the tip points of the corresponding cross-aligned cusps can be placed into the circumferences of a circle. The transverse cuspal curvature of the upper teeth is affected by the equal buccal inclinations of their long axes.

What is christensen's phenomenon?

It is a space that occurs between the opposing occlusal surfaces of the upper and lower teeth during mandibular protrusion. This phenomenon occurs only in natural dentition.

Define centric relation.

The maxillomandibular relationship in which the condyles articulate with the thinnest avascular portion of their respective discs with the complex in the anterosuperior position against the shapes of the articular eminences. This position is independent of tooth contact. This position is clinically discernible when the mandible is directed superiorly and anteriorly. It is restricted to a purely rotary movement about the transverse horizontal axis.

Define centric occlusion.

The occlusion of opposing teeth when the mandible is in centric relation. This may or may not coincide with the maximal intercuspal position.

What is a transitional denture?

A removable dental prosthesis serving as an interim prosthesis to which artificial teeth will be added as natural teeth are lost and that will be replaced after postextraction tissue changes have occurred. A transitional denture may become an interim complete dental prosthesis when all of the natural teeth have been removed from the dental arch—called also complete denture.

What is an interim prosthesis?

A fixed or removable dental prosthesis, or maxillofacial prosthesis, designed to enhance aesthetics, stabilization and/or function for a limited period of time, after which it is to be replaced by a definitive dental or maxillofacial prosthesis. Often such prostheses are used to assist in determination of the therapeutic effectiveness of a specific treatment plan or the form and function of the planned for definitive prosthesis.

What is a treatment denture?

A dental prosthesis used for the purpose of treating or conditioning the tissues.

Define retention.

That quality inherent in the dental prosthesis acting to resist the forces of dislodgement along the path of placement.

Define stability.

Stability is the ability of the prosthesis to be firm, steady and constant and resists the forces of dislodgement along the horizontal direction.

What is a removable partial denture?

Any prosthesis that replaces some teeth in a partially dentate arch. It can be removed from the mouth and replaced at will—also called partial removable dental prosthesis.

What are the components of removable cast partial denture?

The components of the removable cast partial denture are:

1. Connectors—major, minor.
2. Retainers—direct, indirect.
3. Rests.
4. Denture base.
5. Artificial teeth.

What is a major connector?

The part of a partial removable dental prosthesis that joins the components on one side of the arch to those on the opposite side.

What are the functions of a major connector?

The functions of the major connector are:

1. It connects the components on one side of the arch to the other side of the arch.
2. It provides the cross-arch stabilization.

What are the types of maxillary major connector?

The types of maxillary major connector are:

1. Single palatal strap
2. Combination anterior and posterior palatal strap type connector
3. Complete palatal plate type connector
4. Horseshoe or U-shaped palatal connector
5. Single palatal bar
6. Closed horseshoe or anteroposterior palatal bars

What are the types of mandibular major connector?

The types of the mandibular major connector are:

1. Lingual bar
2. Linguoplate
3. Double lingual bar
4. Labial bar.

What is a minor connector?

The connecting link between the major connector or base of a partial removable dental prosthesis and the other components of the prosthesis, such as the clasp assembly, indirect retainers, occlusal rests, or cingulum rests.

What are the types of minor connector?

There are four types of minor connector. They are:

1. Connector that joins the clasp assembly to the major connector.
2. Connector that joins indirect retainers or auxiliary rests to the major connector.
3. Connector that joins the denture base to the major connector.
4. Connector that serves as an approach arm for a vertical projection or bar type clasp.

What are the types of minor connector that joins the denture base to the major connector?

There are three types of minor connector that joins the denture base to the major connector. They are:

1. Ladder or lattice work
2. Nail head or bead
3. Meshwork.

What is a direct retainer?

That component of a partial removable dental prosthesis that engages the abutment tooth and in doing so resists dislodging forces applied to the removable partial denture.

What are the types of direct retainer?

The direct retainers are of two types:

1. Extracoronary retainers or the clasp type:
 - a. Occlusally approaching, e.g. circumferential or Akers clasp
 - b. Gingivally approaching, e.g. bar or Roach clasp
2. Intracoronary retainers or the attachments.

What are the parts of the clasp?

The parts of the clasp are:

1. Rest
2. Body
3. Shoulder
4. Reciprocal clasp arm
5. Retentive clasp arm
6. Retentive terminal
7. Minor connector
8. Approach arm.

What are the requirements of a clasp design?

The basic requirements of clasp design are:

1. Retention
2. Support
3. Stability
4. Reciprocation
5. Encirclement
6. Passivity.

What is the other name for reciprocal arm?

Reciprocal arm is also called bracing arm or stabilizing arm.

Which is the only component of the clasp which is placed below the height of contour?

The retentive terminal tip is placed below the height of contour of the abutment tooth generated by the retentive terminal as it passes over the height of contour of the tooth when the partial denture is inserted or withdrawn from the mouth.

What are the factors which influence the flexibility of the clasp arm?

The factors which influence the flexibility of the clasp arm are:

- Length of the retentive arm
- Taper of the arm
- Cross-sectional form of the arm
- Type of alloy used.

What is a combination clasp?

The combination clasp consists of the cast reciprocal arm and wrought retentive arm. Combination clasp is usually indicated in greater or a deeper undercut area where more flexibility of the retentive clasp arm is required.

What are the types of circumferential clasp?

The types of circumferential clasp are:

- Simple circlet
- Multiple circlet
- Embrasure clasp
- Ring clasp
- Fish-hook clasp
- Onlay clasp.

What are the types of bar clasp?

The types of bar clasp are:

- T clasp
- Modified T clasp
- Y clasp
- I clasp.

What is an indirect retainer?

The component of a partial removable dental prosthesis that assists the direct retainer(s) in preventing displacement of the distal extension denture base by functioning through lever action on the opposite side of the fulcrum line when the denture base moves away from the tissues in pure rotation around the fulcrum line.

What are the functions of an indirect retainer?

The role of an indirect retainer is to effectively activate the direct retainer to prevent movement of a distal extension base away from the tissue surface.

In which classification of partially edentulous arch is mandatory to give an indirect retainer?

In Kennedy's class I and II, it is mandatory to design an indirect retainer.

What are the factors which influence the effectiveness of an indirect retainer?

The greater the distance between the fulcrum line and the indirect retainer, more effective will be the indirect retainer.

What are the forms of indirect retainer?

The forms of indirect retainer are:

- Auxiliary occlusal rest
- Lingual or cingulum rest
- Incisal rest

What is an occlusal rest?

A rigid component of the cast partial removable denture that serves primarily to transfer occlusal forces occurring against the prosthesis down the long axis of the abutment tooth.

What are the functions of occlusal rest?

- It transmits along the long axis so that the periodontal ligament absorbs the force without damaging the supporting bone.
- It acts as a vertical stop and prevents injury and over displacement of the soft tissues under the partial denture bases.
- It maintains the clasp in its position.
- It prevents food entrapment between the abutment tooth and the edentulous ridge.
- It reestablishes the continuity of arch and prevents further drifting or tipping of teeth.
- In combination with minor connector, it performs reciprocation action.

What is a dental cast surveyor?

A paralleling instrument used in construction of a dental prosthesis to locate and delineate the contours and relative positions of abutment teeth and associated structures.

What are the parts of a surveyor?

Ney dental surveyor:

1. Surveying platform
2. Surveying table or cast holder
3. Vertical arm
4. Horizontal arm
5. Surveying arm
6. Surveying tools:
 - a. Analyzing rod
 - b. Carbon markers
 - c. Undercut gauges
 - d. Wax knife.

What are the functions of a surveyor?

1. Surveying diagnostic cast
2. Tripoding the cast
3. Transferring tripod marks to another cast
4. Contouring wax pattern
5. Contouring crowns and cast restoration
6. Placing internal attachments and rests
7. Surveying the master cast

What is tripod marking?

Tripod marks or lines drawn on a cast in a single plane perpendicular to the survey rod to assist with repositioning the cast on a dental surveyor in a previously defined orientation.

What is an undercut?

1. The portion of the surface of an object that is below the height of contour in relationship to the path of placement.
2. The contour of a cross-sectional portion of a residual ridge or dental arch that prevents the insertion of a dental prosthesis.

What is a tooth supported removable partial denture?

A dental prosthesis or part of a prosthesis that depends entirely on the natural teeth for support. For example, Kennedy's class III partially edentulous situation.

What is a height of contour?

A line encircling a tooth and designating its greatest circumference at a selected axial position determined by a dental surveyor or a line encircling a body designating its greatest circumference in a specified plane.

What are guiding planes?

Vertically parallel surfaces on abutment teeth or/and dental implant abutments oriented so as to contribute to the direction of the path of placement and removal of a removable dental prosthesis.

What is a survey line?

A line produced on a cast by a surveyor marking the greatest prominence of contour in relation to the planned path of placement of a restoration.

What is a suprabulge?

That portion of a tooth or crown that converges toward the occlusal surface, i.e. above the height of contour.

What is an infrabulge?

That portion of the crown of a tooth apical to the survey line.

What are the alloys used for the fabrication of cast partial denture?

- Cobalt-chromium alloys
- Titanium alloys
- Type IV gold alloys

What is a fixed partial denture?

Any dental prosthesis that is cemented, screwed or mechanically attached or otherwise securely retained to natural teeth, tooth roots, and/or dental implant abutments that furnish the primary support for the dental prosthesis. This may include replacement of one to sixteen teeth in each dental arch.

What are the parts of a fixed partial denture?

The parts of a fixed partial denture are retainer, pontic and connector.

Define abutment.

A tooth, a portion of a tooth or that portion of a dental implant that serves to support and/or retain a prosthesis.

Define retainer.

Retainer is a component of fixed partial denture used for the stabilization or retention of a prosthesis.

Define connector.

In fixed dental prosthesis, the portion of a fixed dental prosthesis that joins the retainer and pontic.

Define pontic.

Pontic is the suspended member of the bridge or the artificial teeth of a fixed partial dental prosthesis that replaces missing natural teeth, restoring function and appearance.

CHAPTER 5

Glossary of terms

S Lakshmi

Abutment: A tooth, a portion of a tooth, or that portion of a dental implant that serves to support and/or retain a prosthesis.

Adjustable articulator: An articulator that allows some limited adjustment in the sagittal and horizontal planes to replicate recorded mandibular movements.

Anatomic occlusion: An occlusal arrangement for dental prostheses wherein the posterior artificial teeth have masticatory surfaces that closely resemble those of the natural healthy dentition and articulate with similar natural or artificial surfaces.

Anatomic teeth:

1. Artificial teeth that duplicate the anatomic forms of natural teeth.
2. Teeth that have prominent cusps on the masticating surfaces and that are designed to articulate with the teeth of the opposing natural or prosthetic dentition.
3. Anatomic teeth with cuspal inclinations greater than 0 degree that tend to replica natural tooth anatomy usage cusp teeth (30 to 45 degrees) are considered anatomic teeth. Modified occlusal forms are those with a 20-degree cusp incline or less called also anatomical teeth.

Anterior guide pin: That component of an articulator, generally a rigid rod attached to one member, contacting the anterior guide table on the opposing member. It is used for the purpose of maintaining the established vertical separation.

Anterior guide table: That component of an articulator on which the anterior guide pin rests to maintain the occlusal vertical dimension and influence articulator movements. The guide table influences the

degree of separation of the casts in all relationships.

Anteroposterior curve: The anatomic curve established by the occlusal alignment of the teeth, as projected onto the median plane, beginning with the cusp tip of the mandibular canine and following the buccal cusp tips of the premolar and molar teeth, continuing through the anterior border of the mandibular ramus, ending with the anterior most portion of the mandibular condyle. It was first described by Ferdinand Graf Spee, German anatomist, in 1890.

Arcon articulator: An articulator which has condylar analogues in the mandibular element and fossae assemblies within the maxillary element.

Articulator: A mechanical instrument that represents the temporomandibular joints and jaws, to which maxillary and mandibular casts may be attached to simulate some or all mandibular movements.

Artificial crown: A metal, plastic, or ceramic restoration that covers three or more axial surfaces and the occlusal surface or incisal edge of a tooth.

Balanced articulation: The bilateral, simultaneous, anterior and posterior occlusal contact of teeth in centric and eccentric positions.

Bar clasp: A clasp retainer whose body extends from a major connector or denture base, passing adjacent to the soft tissues and approaching the tooth from a gingivo-occlusal direction.

Basal: Pertaining to or situated near the base.

Basal bone: The osseous tissue of the mandible and maxillae exclusive of the alveolar process.

Base: The portion of a denture that supports the artificial dentition and replaces the alveolar structures and gingival tissues.

Base plate: A rigid, relatively thin layer of wax, shellac, or thermoplastic (heat, chemical, photo-activated) polymer adapted over edentulous surfaces of a definitive cast to form a base which, together with an attached occlusion rim made of wax or similar material, serves as the record base.

Bees' wax: A low-melting wax obtained from honeycomb and used as an ingredient of many dental impression waxes.

Bench set: A stage of resin processing that allows a chemical reaction to occur under the conditions present in the ambient environment; also used to describe the continuing polymerization of impression materials beyond the manufacture is stated set time.

Boxing an impression: The enclosure (box) of an impression to produce the desired size and form of the base of the cast and to preserve desired details.

Bracing: The resistance to horizontal components of masticatory force.

Buccal flange: The portion of the flange of a denture that occupies the buccal vestibule of the mouth.

Buccal vestibule: The portion of the oral cavity that is bounded on one side by the teeth, gingiva, and alveolar ridge (in the edentulous mouth, the residual ridge) and on the lateral side by the cheek posterior to the buccal frenula.

Bur: A steel or tungsten carbide rotary cutting instrument.

Bur head: The cutting portion of a dental bur.

Bur head length: The axial dimension of the bur head.

Bur head shape: The geometrical outline form of the cutting surface edges, usually described successively by proximity from the shank to the tip end.

Bur shank: That component of a dental bur which fits into the handpiece; the shaft section of the dental bur that may be friction gripping or latch-type in form.

Cameo surface: The viewable portion of a removable denture prosthesis; the portion of the surface of a denture that extends in an occlusal direction from the border of the denture and includes the facial, lingual and palatal surface. It is the part of the denture base that is usually polished, and includes the buccal and lingual surfaces of the teeth.

Cantilever fixed dental prosthesis: A fixed dental prosthesis in which the pontic is cantilevered, i.e. is retained and supported only on one end by one or more abutments.

Cast: A life-size likeness of some desired form. It is formed within or is a material poured into a matrix or impression of the desired form.

Centric relation: The maxillomandibular relationship in which the

condyles articulate with the thinnest avascular portion of their respective discs with the complex in the anterior-superior position against the shapes of the articular eminencies. This position is independent of tooth contact.

Ceramics: Compounds of one or more metals with a nonmetallic element, usually oxygen. They are formed of chemical and biochemical stable substances that are strong, hard, brittle, and inert nonconductors of thermal and electrical energy. It is the art of making porcelain dental restorations.

Christensen's phenomenon: Eponym for the space that occurs between opposing occlusal surfaces during mandibular protrusion.

Clasp: The component of the clasp assembly that engages a portion of the tooth surface and either enters an undercut for retention or remains entirely above the height of contour to act as a reciprocating element. Generally, it is used to stabilize and retain a removable dental prosthesis.

Combination clasp: A circumferential retainer for a removable dental prosthesis that has a cast reciprocal arm and a wrought wire retentive clasp.

Compensating curve:

1. The anteroposterior curving (in the median plane) and the mediolateral curving (in the frontal plane) within the alignment of the occluding surfaces and incisal edges of artificial teeth that is used to develop balanced occlusion.
2. The arc introduced in the construction of complete removable dental prostheses to compensate for the opening influences produced by the condylar and incisal guidance is during lateral and protrusive mandibular excursive movements.

Complete denture: A removable dental prosthesis that replaces the entire dentition and associated structures of the maxillae or mandible; called a complete removable dental prosthesis.

Complete denture prosthetics:

1. The replacement of the natural teeth in the arch and their associated parts by artificial substitutes.
2. The art and science of the restoration of an edentulous

mouth.

Condylar guidance: The mechanical form located in the upper posterior region of an articulator that controls movement of its mobile member.

Convergence angle: The angle, measured in degrees, formed between opposing axial walls when a tooth or teeth are prepared for crowns or fixed dental prostheses.

Crest of the ridge: The highest continuous surface of the residual ridge not necessarily coincident with the centre of the ridge.

Cross-arch stabilization: Resistance against dislodging or rotational forces obtained by using a partial removable dental prosthesis design that uses natural teeth on the opposite side of the dental arch from the edentulous space to assist in stabilization.

Crown:

1. That portion of a tooth occlusal to the dentinoenamel junction or an artificial substitute.
2. An artificial replacement that restores missing tooth structure by surrounding part or all of the remaining structure with a material, such as cast metal, porcelain, or a combination of materials, such as metal and porcelain.

Curve of Monson: Eponym for a proposed ideal curve of occlusion in which each cusp and incisal edge touches or conforms to a segment of the surface of a sphere 8 inches in diameter with its centre in the region of the glabella.

Curve of Pleasure:

1. Eponym for a helicoid curve of occlusion that, when viewed in the frontal plane, conforms to a curve that is convex from the superior view, except for the last molars which reverse that pattern.
2. In excessive wear of the teeth, the obliteration of the cusps and formation of either flat or cupped-out occlusal surfaces, associated with reversal of the occlusal plane of the premolar, first and second molar teeth (the third molars being generally unaffected), whereby the occlusal surfaces of the mandibular teeth slope facially instead of lingually and

those of the maxillary teeth incline lingually.

Curve of Wilson:

1. Eponym for the mediolateral curve.
2. In the theory that occlusion should be spherical, the curvature of the cusps as projected on the frontal plane expressed in both arches; the curve in the lower arch being concave and the one in the upper arch being convex. The curvature in the lower arch is affected by an equal lingual inclination of the right and left molars so that the tip points of the corresponding cross-aligned cusps can be placed into the circumferences of a circle. The transverse cuspal curvature of the upper teeth is affected by the equal buccal inclinations of their long axes.

Cusp: Cone-shaped protuberance on the crown of a tooth that forms the occlusal surface.

Cusp angle: The angle made by the average slope of a cusp with the cusp plane measured mesiodistal or buccolingually.

Cusp height: The perpendicular distance between the tip of a cusp and its base plane.

Cuspless teeth: Teeth designed without cuspal prominence on the occlusal surface.

Custom tray: An individualized impression tray made from a cast recovered from a preliminary impression. It is used in making a final impression.

Cyanoacrylate: A single component, moisture activated, thermoplastic group of adhesives characterized by rapid polymerization and excellent bond strength.

Definitive cast: A replica of the tooth surfaces, residual ridge areas, and/or other parts of the dental arch and/or facial structures used to fabricate a dental restoration or prosthesis; called also final cast.

Dental cast: A positive life-size reproduction of a part or parts of the oral cavity.

Dental implant: A prosthetic device made of all plastic material(s) implanted into the oral tissues beneath the mucosal or/and periosteal layer, and on/or within the bone to provide retention and support for

a fixed or removable dental prosthesis; a substance that is placed into or/and upon the jaw bone to support a fixed or removable dental prosthesis.

Dental impression: A negative imprint of an oral structure used to produce a positive replica of the structure to be used as a permanent record or in the production of a dental restoration or prosthesis.

Dental prosthesis: An artificial replacement (prosthesis) of one or more teeth (up to the entire dentition in either arch) and associated dental/alveolar structures. Dental prostheses usually are subcategorized as either fixed dental prostheses or removable dental prostheses.

Denture base: The part of a denture that rests on the foundation tissues and to which teeth are attached.

Denture border:

1. The margin of the denture base at the junction of the polished surface and the impression surface.
2. The peripheral border of a denture base at the facial, lingual and posterior limits.

Denture foundation area: The surfaces of the oral structures available to support a denture.

Denture occlusal surface: The portion of the surface of a denture that makes contact with its antagonist.

Denture polished surface: The portion of the surface of a denture that extends in an occlusal direction from the border of the denture and includes the palatal surface. It is the part of the denture base that is usually polished, and it includes the buccal and lingual surfaces of the teeth.

Denture retention:

1. The resistance in the movement of a denture away from its tissue foundation especially in a vertical direction.
2. A quality of a denture that holds it to the tissue foundation and/or abutment teeth.

Denture stability

1. The resistance of a denture to movement on its tissue foundation, especially to lateral (horizontal) forces as

- opposed to vertical displacement (termed denture retention).
2. A quality of a denture that permits it to maintain a state of equilibrium in relation to its tissue foundation and/or abutment teeth.

Diagnostic cast: A life-size reproduction of a part or parts of the oral cavity and/or facial structures for the purpose of study and treatment planning.

Die: The positive reproduction of the form of a prepared tooth in any suitable substance.

Edentulism: The state of being edentulous; without natural teeth.

Extracoronary retainer: That part of a fixed dental prosthesis uniting the abutment to the other elements of a prosthesis that surrounds all or part of the prepared crown.

Facial prosthesis: A maxillofacial prosthesis that artificially replaces a portion of the face lost due to surgery, trauma or congenital absence called also extraoral prosthesis.

Final impression: The impression that represents the completion of the registration of the surface or object.

Fixed dental prosthesis: Any dental prosthesis that is luted, screwed or mechanically attached or otherwise securely retained to natural teeth, tooth roots and/or dental implant abutments that furnish the primary support for the dental prosthesis.

Fixed prosthodontics: The branch of prosthodontics concerned with the replacement and/or restoration of teeth by artificial substitutes that not readily removed from the mouth.

Flask: A metal case used in investing procedures.

Fulcrum line:

1. A theoretical line passing through the point around which a lever functions and at right angles to its path of movement.
2. An imaginary line, connecting occlusal rests, around which a partial removable dental prosthesis tends to rotate under masticatory forces. The determinants for the fulcrum line are usually the cross-arch occlusal rests located adjacent to the tissue borne components.

Group function: Multiple contact relations between the maxillary and

mandibular teeth in lateral movements on the working side whereby simultaneous contact of several teeth acts as a group to distribute occlusal forces.

Height of contour: A line encircling a tooth and designating its greatest circumference at a selected axial position determined by a dental surveyor; a line encircling a body designating its greatest circumference in a specified plane.

Horizontal plane of reference: A horizontal plane established on the face of the patient by one anterior reference point and two posterior reference points from which measurements of the posterior anatomic determinants of occlusion and mandibular motion are made.

Horizontal overlap: The projection of teeth beyond their antagonists in the horizontal plane.

Immediate denture: Any removable dental prosthesis fabricated for placement immediately following the removal of a natural tooth/teeth.

Impression material: Any substance or combination of substances used for making an impression or negative reproduction.

Impression tray:

1. A receptacle into which suitable impression material is placed to make a negative likeness.
2. A device that is used to carry, confine and control impression material while making an impression.

Incisal rest: A rigid extension of a removable partial denture that contacts a tooth at the incisal edge.

Index: A core or mould used to record or maintain the relative position of a tooth or teeth to one another, to a cast or to some other structure.

Indirect retainer: The component of a partial removable dental prosthesis that assists the direct retainer(s) in preventing displacement of the distal extension denture base by functioning through lever action on the opposite side of the fulcrum line when the denture base moves away from the tissues in pure rotation around the fulcrum line.

Infrabulge: That portion of the crown of a tooth apical to the survey line.

Intaglio surface: The portion of the denture or other restoration

surface that has its contour determined by the impression; the interior or reversal surface of an object.

Interim prosthesis: A fixed or removable dental prosthesis, or maxillofacial prosthesis, designed to enhance aesthetics, stabilization and/or function for a limited period of time, after which it is to be replaced by a definitive dental or maxillofacial prosthesis.

Investing: The process of covering or enveloping, wholly or in part, an object, such as a denture, tooth, wax form, crown, etc. with a suitable investment material before processing, soldering or casting.

Investment cast: A cast made of a material that will withstand high temperature without disintegration.

Labial flange: The portion of the flange of a denture that occupies the labial vestibule of the mouth.

Labial vestibule: The portion of the oral cavity that is bounded on one side by the teeth, gingiva, and alveolar ridge in the edentulous mouth, the residual ridge and on the other by the lips anterior to the buccal frenula.

Land area: The portion of a dental cast that extends beyond the impression is replica surface laterally that defines the area between the end of the replica is surface and the cast.

Lingual flange: The portion of the flange of a mandibular denture that occupies the alveololingual sulcus.

Major connector: The part of a partial removable dental prosthesis that joins the components on one side of the arch to those on the opposite side.

Mandrel:

1. Usually a tapered or cylindrical axle, spindle or arbor placed in a hole to support it during machining bent or shaped.
2. The shaft and bearings on which a tool is mounted.

Minor connector: The connecting link between the major connector or base of a partial removable dental prosthesis and the other units of the prosthesis, such as the clasp assembly, indirect retainers, occlusal rests or bar retainers.

Mucobuccal fold: The line of flexure of the mucous membrane as it passes to the cheek.

Mucostatic: The state of the oral mucosa when external forces are not displacing it.

Neutral zone: The potential space between the lips and cheeks on one side and the tongue on the other; that area or position where the forces between the tongue and cheeks or lips are equal.

Nonadjustable articulator: An articulator that does not allow adjustment to replicate mandibular movements.

Nonarcon articulator: Any articulator design in which the condylar element is not part of the lower member of the articulator and may be used to simulate the three-dimensional motions of the left and right condylar compartments.

Nonanatomic teeth: Artificial teeth with occlusal surfaces that are not anatomically formed teeth with flat occlusal surfaces set to a flat occlusal plane.

Occlusal rest: A rigid extension of a partial removable dental prosthesis that contacts the occlusal surface of a tooth or restoration, the occlusal surface of which may have been prepared to receive it.

Occlusal table: The portion of the occlusal surfaces of posterior teeth that lies within the perimeter of the cusp tips and marginal ridges; the functional portion(s) of the occlusal surface(s) of a posterior tooth (teeth).

Occlusion: The static relationship between the incising or masticating surfaces of the maxillary or mandibular teeth or tooth analogues.

Occlusion rim: Occluding surfaces fabricated on interim or final denture bases for the purpose of making maxillomandibular relation records and arranging teeth called also record rim.

Orbital prosthesis: A maxillofacial prosthesis that artificially restores the eye, eyelids, and adjacent hard and soft tissues.

Overdenture: Any removable dental prosthesis that covers and rests on one or more remaining natural teeth, the roots of natural teeth and/or dental implants; a dental prosthesis that covers and is partially supported by natural teeth, natural tooth roots and/or dental implants —called also overlay denture, overlay prosthesis, superimposed prosthesis.

Passivity: The quality or condition of in activity or rest assumed by

the teeth, tissues, and denture when a removable dental prosthesis is in place but not under masticatory pressure.

Polished denture surface: That portion of the surface of a denture that extends in an occlusal direction from the border of the denture and includes the palatal surfaces. It is that part of the denture base that is usually polished, and it includes the buccal and lingual surfaces of the teeth.

Pontic: An artificial tooth on a fixed dental prosthesis that replaces a missing natural tooth, restores its function and usually fills the space previously occupied by the clinical crown.

Postpalatal seal: The seal area at the posterior border of a maxillary removable dental prosthesis.

Posterior palatal seal area: The soft tissue area at or beyond the junction of the hard and soft palates on which pressure, within physiologic limits, can be applied by a complete RDP to aid in its retention.

Preliminary cast: A cast formed from a preliminary impression for use in diagnosis or the fabrication of an impression tray.

Preliminary impression: A negative likeness made for the purpose of diagnosis, treatment planning or the fabrication of a tray.

Prosthodontics: Prosthodontics is the dental specialty pertaining to the diagnosis, treatment planning, rehabilitation and maintenance of the oral function, comfort, appearance and health of patients with clinical conditions associated with missing or deficient teeth and/or maxillofacial tissues using biocompatible substitutes.

Rebase: The laboratory process of replacing the entire denture base material on an existing prosthesis.

Reciprocal clasp: A component of the clasp assembly specifically designed to provide reciprocation by engaging a reciprocal guiding plane; it contacts the action of the clasp during removal and insertion of a partial removable dental prosthesis.

Reciprocation: The mechanism by which lateral forces generated by a retentive clasp passing over a height of contour are counterbalanced by a reciprocal clasp passing along a reciprocal guiding plane.

Relief: The reduction or elimination of undesirable pressure or force

from a specific region under a denture base. The creation of space in an impression tray for impression material.

Relief area: That portion of the dental prosthesis that is reduced to eliminate excessive pressure.

Remount cast: A cast formed of a prosthesis for the purpose of mounting the prosthesis on an articulator.

Remount procedure: Any method used to relate restorations to an articulator for analysis and/or to assist in development of a plan for occlusal equilibration or reshaping.

Removable partial denture prosthesis: Any prosthesis that replaces some teeth in a partially dentate arch. It can be removed from the mouth and replaced at will also called partial removable dental prosthesis.

Sectional impression: A negative likeness that is made in sections.

Shellac base: A record base constructed using a shellac-based wafer that has been adapted to the cast with heat (GPT-4).

Stability: The quality of a removable dental prosthesis to be firm, steady, or constant, to resist displacement by functional horizontal or rotational stresses resistance to horizontal displacement of a prosthesis.

Stock tray: A metal prefabricated impression tray typically available in various sizes and used principally for preliminary impressions.

Stress-bearing region:

1. The surfaces of oral structures that resist forces, strains, or pressures brought on them during functional support.
2. The foundation area on which a dental prosthesis rests.

Suprabulge: That portion of a tooth or crown that converges toward the occlusal surface, i.e. above the height of contour.

Survey: The procedure of locating and delineating the contour and position of the abutment teeth and associated structures before designing a removable partial denture.

Survey line: A line produced on a cast by a surveyor marking the greatest prominence of contour in relation to the planned path of placement of a restoration.

Surveyor: A paralleling instrument used in construction of a dental

prosthesis to locate and delineate the contours and relative positions of abutment teeth and associated structures.

Treatment denture:

1. A dental prosthesis used for the purpose of treating or conditioning the tissues that is called on to support and retain it.
2. A dental prosthesis that is placed in preparation for future therapy.

Trial denture: A preliminary arrangement of denture teeth that has been prepared for placement into the patient's mouth to evaluate aesthetics and maxillomandibular relationships.

Undercut:

1. The portion of the surface of an object that is below the height of contour in relationship to the path of placement.
2. The contour of a cross-sectional portion of a residual ridge or dental arch that prevents the insertion of a dental prosthesis.
3. Any irregularity in the wall of a prepared tooth that prevents the withdrawal or seating of a wax pattern or casting.

Vertical dimension: The distance between two selected anatomic or marked points (usually one on the tip of the nose and the other upon the chin), one on a fixed and one on a movable member.

Vertical overlap:

1. The distance teeth lap over their antagonists as measured vertically; especially the distance the maxillary incisal edges extend below those of the mandibular teeth. It may also be used to describe the vertical relations of opposing cusps.
2. The vertical relationship of the incisal edges of the maxillary incisors to the mandibular incisors when the teeth are in maximum intercuspation.

Vestibule: The portion of the oral cavity that is bounded on the medial side by the teeth, gingiva, and alveolar ridge or the residual ridge, and on the lateral side by the lips and cheeks.

Vibrating line: An imaginary line across the posterior part of the palate marking the division between the movable and immovable tissues of the soft palate. This can be identified when the movable

tissues are functioning.

Wax elimination: The removal of wax from a mould, usually by heat.

Waxing: The contouring of a wax pattern or the wax base of a trial denture into the desired form.

Zero-degree teeth: Posterior denture teeth having zero degree cuspal angles in relation to the plane established by the horizontal occlusal surface of the tooth called also zero degree nonanatomic teeth.