Radiological differential diagnosis — describing a lesion

Many different conditions that can affect the jaws, they can present radio graphically only as areas of relative ***radiolucency*** *or* ***radiopacity***compared to the surrounding bone.

Many of these pathological conditions resemble one another closely. This often creates considerable confusion. Fortunately, the sites where the lesions develop, how they grow and the effects they have on adjacent structures tend to follow recognizable patterns

A detailed description helps to identify these patterns and determine the lesion's basic characteristics. For example, it may reveal whether the lesion is a cyst or a tumor, whether it is composed of hard or soft tissue and whether, in the case of a tumor, it is benign or malignant. The resultant list of possible diagnoses in turn often determines the patient management and mode of treatment. The final definitive diagnosis is almost always based on histological examination

Detailed description of a lesion

- Site or anatomical position
- Size
- Shape
- Outline/edge or periphery
- Relative radio density and internal structure
- Effect on adjacent surrounding structures
- Time present, if known.

Site or anatomical position

The site or anatomical position of a lesion may therefore provide the initial clue as to its identity.

- Localized to the mandible, affecting:
  - — the anterior region
  - — the body — above or below the inferior dental canal, or related to the teeth
  - — the angle
  - — the ramus
  - — the condylar process
  - — the coronoid process
  - — both sides (bilateral)
  - — several sites
- Localized to the maxilla, affecting:
  - — the anterior region
  - — the posterior region
  - — both sides (bilateral)
  - — several sites
- Generalized, affecting:
  - — both jaws
    - * cranial vault
    - * long bones
    - * cervical spine
  - — and/or other bones — multiple lesions may also affect the:
- Originating from a point or epicentre relative to surrounding structures, e.g.:
  - — in bone or soft tissue
  - — above or below the inferior dental canal
  - — in or outside the inferior dental canal
  - — in or outside the maxillary antrum
  - — inside or outside a tooth follicle
  - — at a tooth root apex.

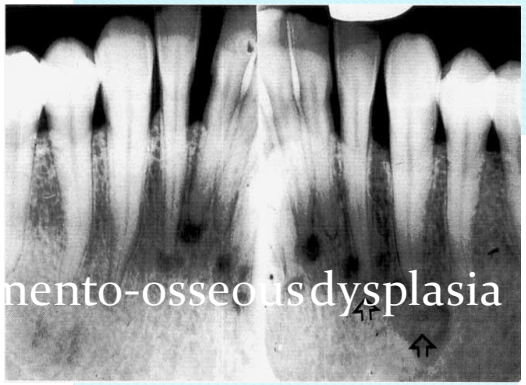

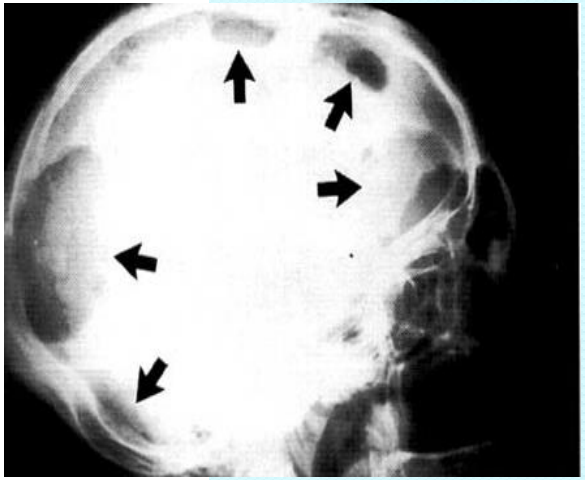

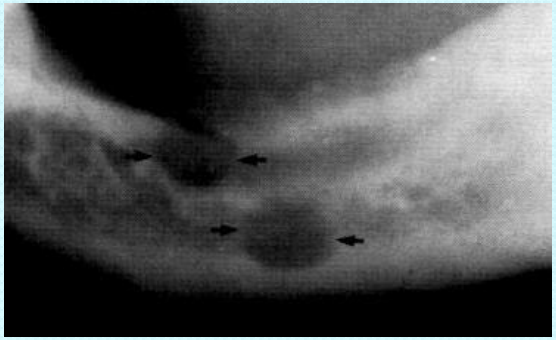

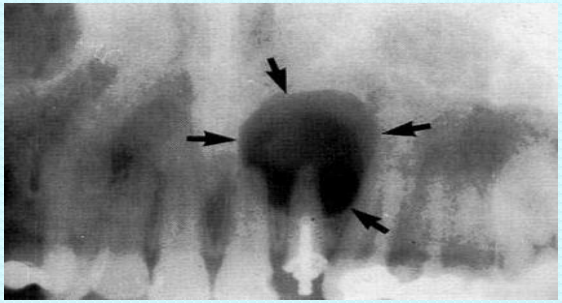

The point of origin may indicate the tissue types that compose the abnormality

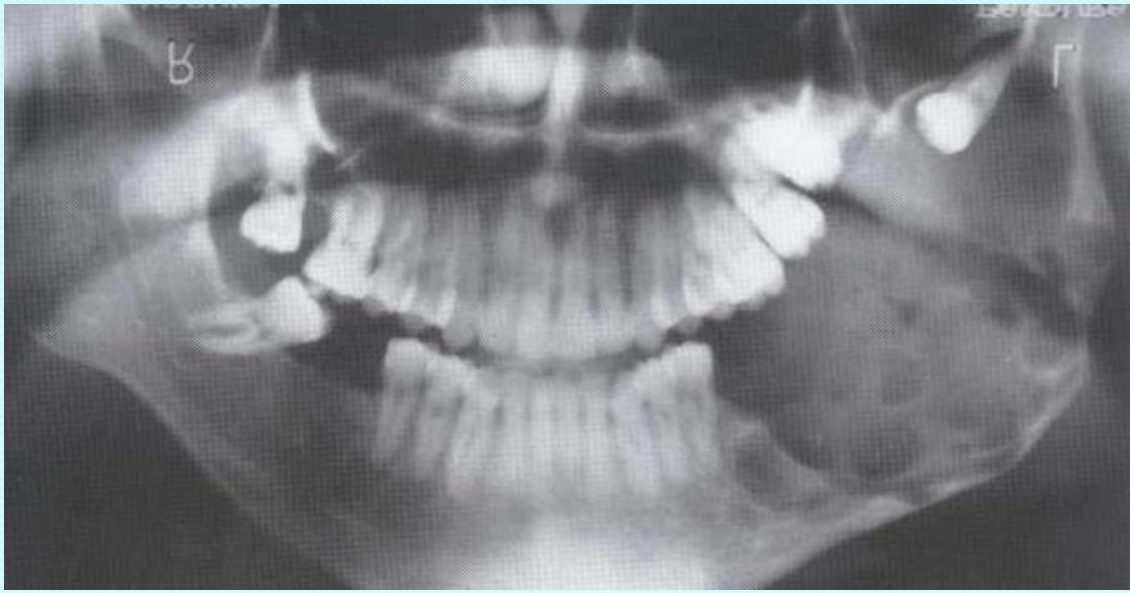

Size

Thus the size of a lesion, while not being specific, may still give some idea of the type of underlying condition.

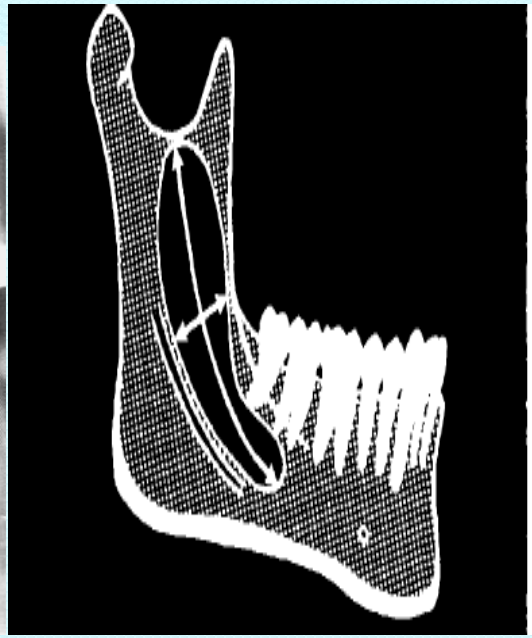

Describing the boundaries, i.e. the lesion extends from ... to ... in one dimension and extends from ... to ... in the other dimension. Measuring the dimensions in centimeters .ameloblastoma can grow, if untreated, to an enormous size (10 cm or more). Stafne's bone cavity 1-2 cm in diameter

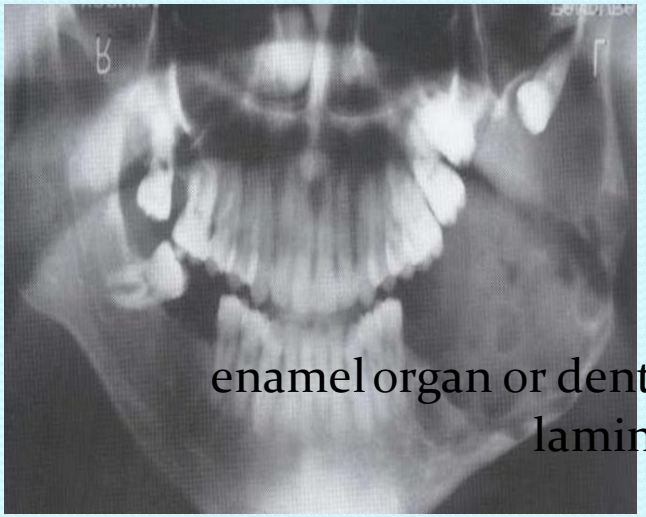

enamel organ or dental lamina.

Shape

useful and specific characteristics that contribute to the radiological diagnosis

- Monolocular or unilocular
- Multilocular
- Pseudoloculated
- Round
- Oval
- Scalloped or undulating
- Irregular.

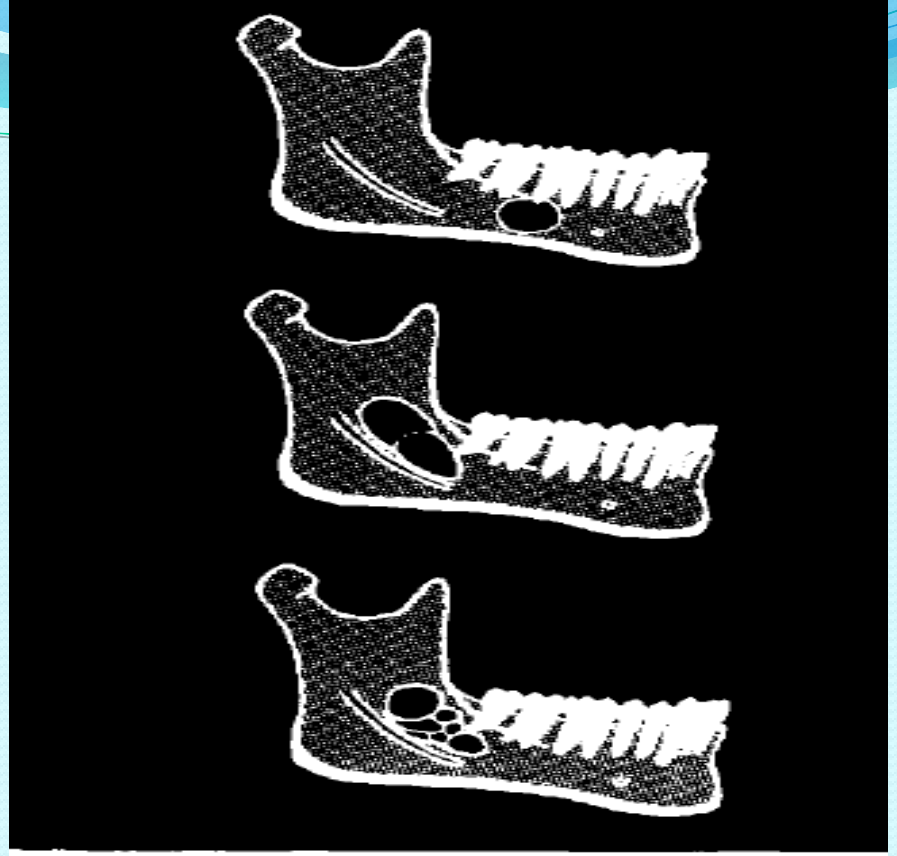

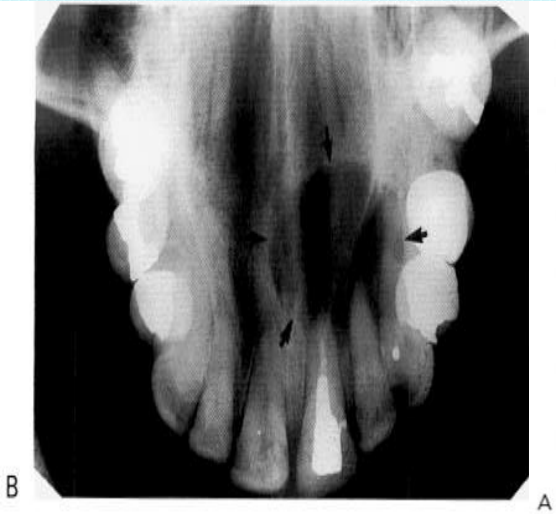

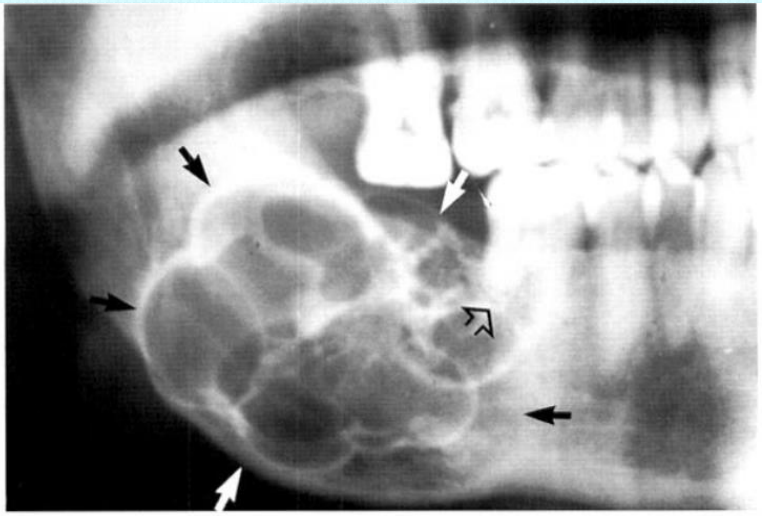

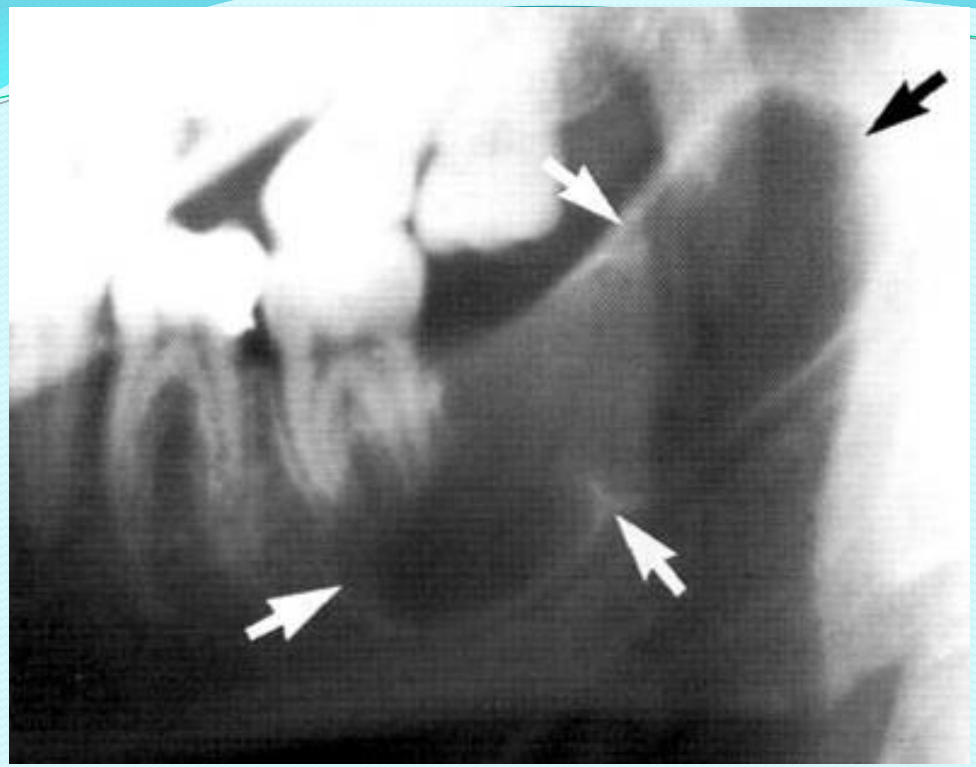

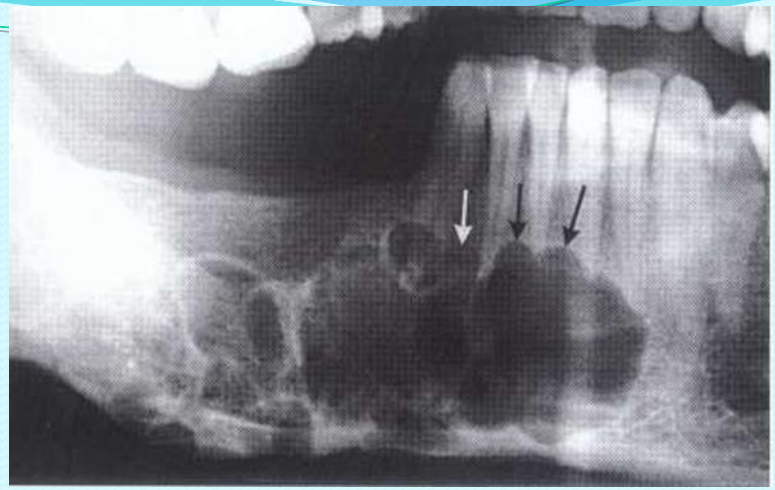

periphery

well-defined outlines

- Smooth
- Punched-out, i.e. showing no peripheral bone reaction
- Corticated, i.e. having a thick or thin surrounding radiopaque (white) cortex
- Sclerotic, i.e. having a non-uniform radiopaque boundary
- Encapsulated, i.e. surrounded by a radiolucent (black) line which may be complete or partial

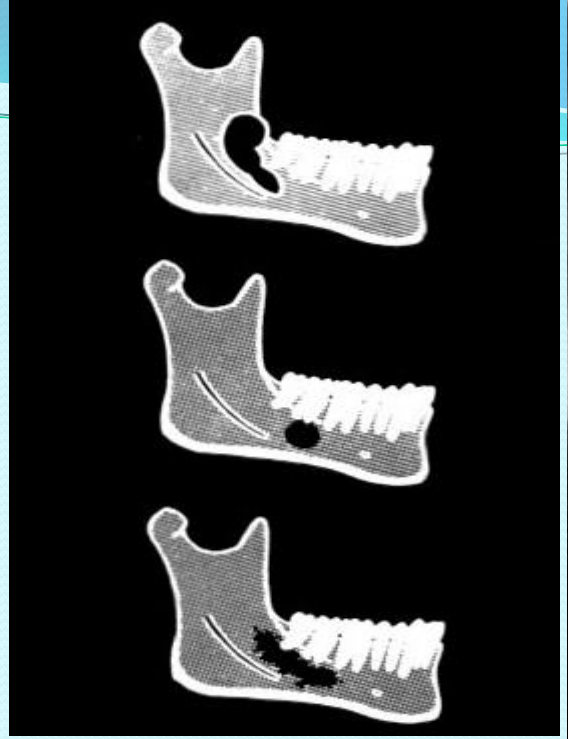

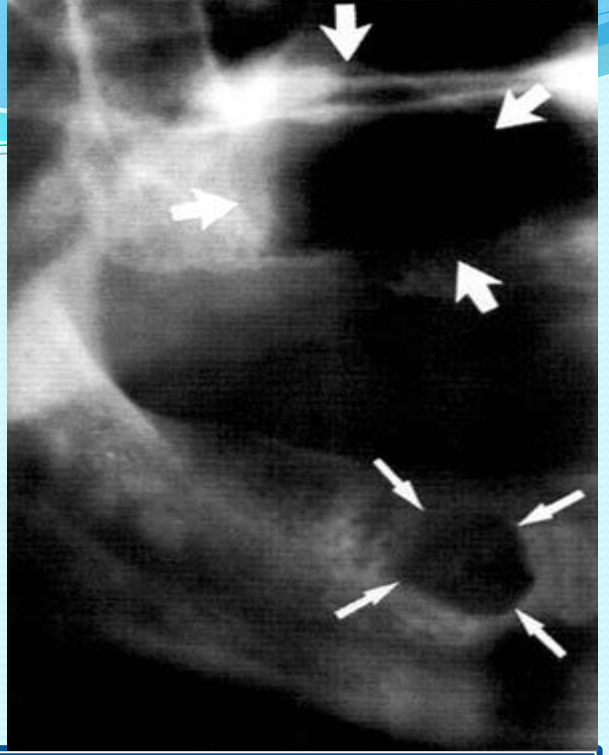

The outline or periphery provides information about the nature of the lesion, for example, whether it is benign or malignant and what the speed of growth or development appears to be. The more benign and slow growing the lesion is, the more likely it is to have a well-defined corticated outline. The malignant, more rapidly growing lesions tend to have poorly defined margins because the speed of bone destruction outstrips any bony repair.

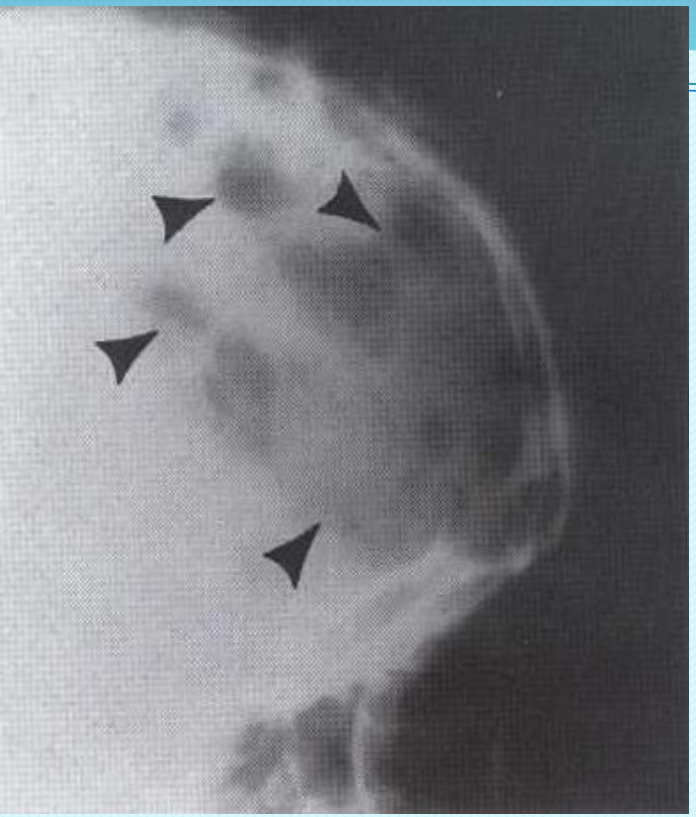

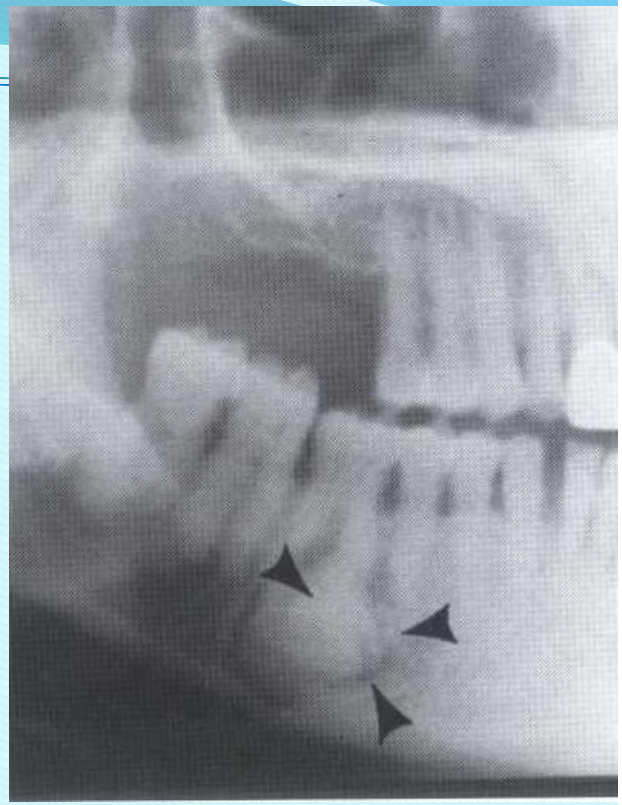

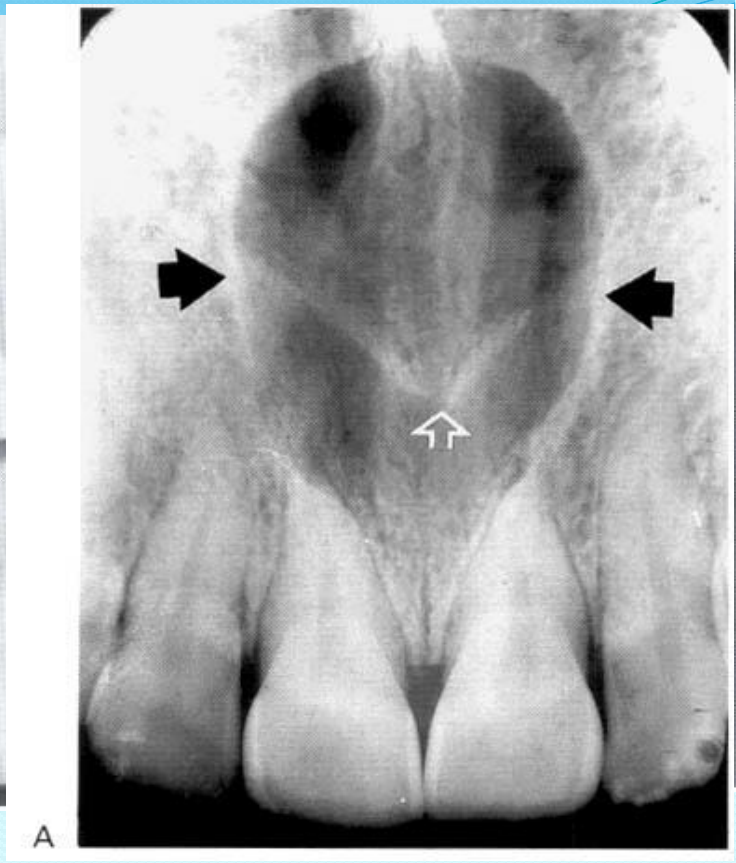
A

poorly defined outlines

- Blend in with normal anatomy and show a gradual change between trabecular patterns
- Show signs of invasion and appear ragged or *moth-eaten*.

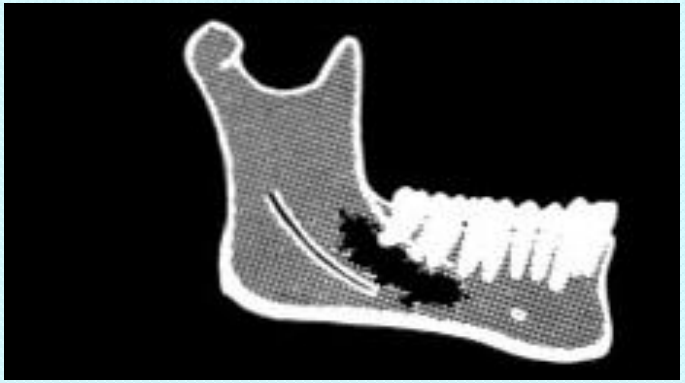

Relative radio density and internal structure

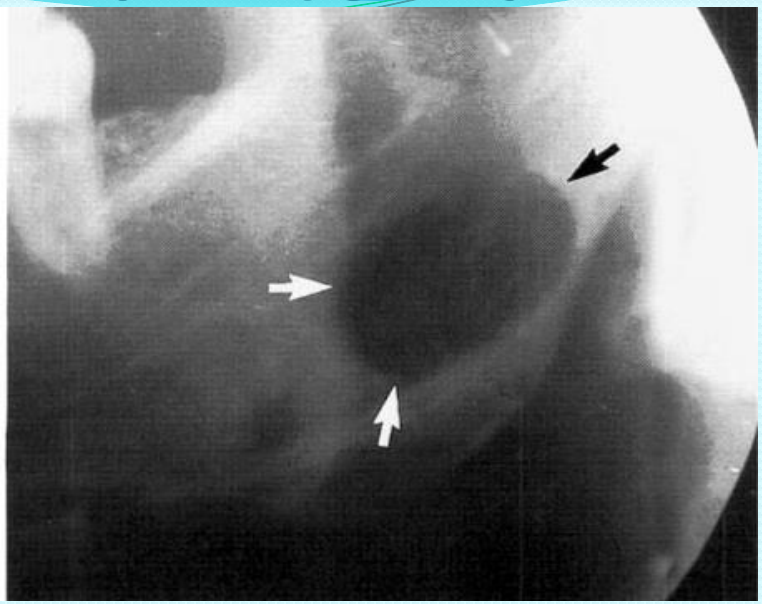

Thus, relative to the surrounding tissues, the radio density of the lesion could be

- Uniformly radiolucent
- Radiolucent with patchy opacities within (mixed)
- Radiopaque.

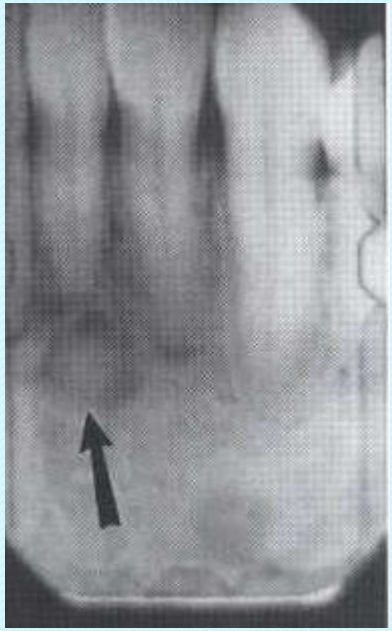

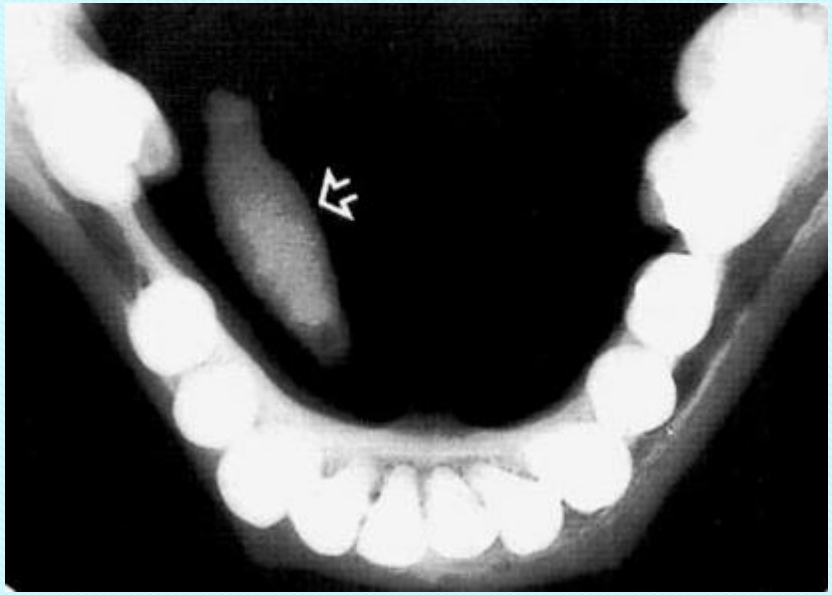

Fine bone trabeculae, e.g. ground glass appearance

• Thick, coarse trabeculae with trabecular spaces, e.g. honeycomb appearance

• Haphazard sclerotic bone, e.g. cottonwoolpatches

• Homogeneous dense cortical bone

• Discrete bony septa, which could be:

— thin or coarse

— straight or curved

— prominent or faint

• Cementum — oval or round amorphous

calcification

• Identifiable dental tissue — enamel and/or

dentine

• No specific pattern.

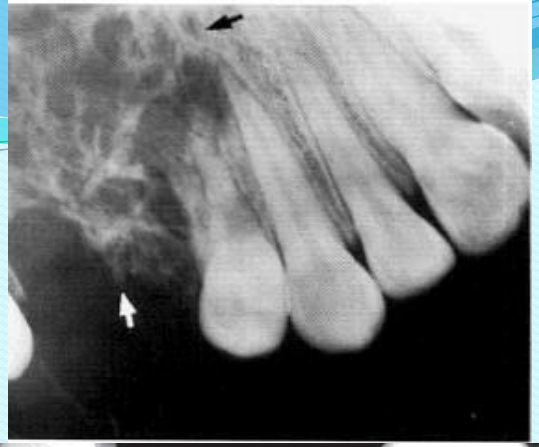

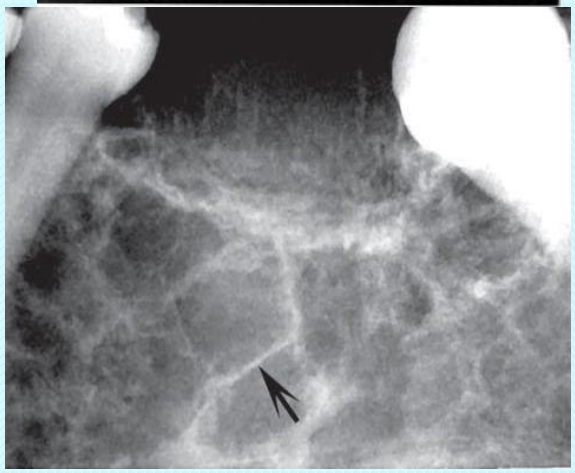

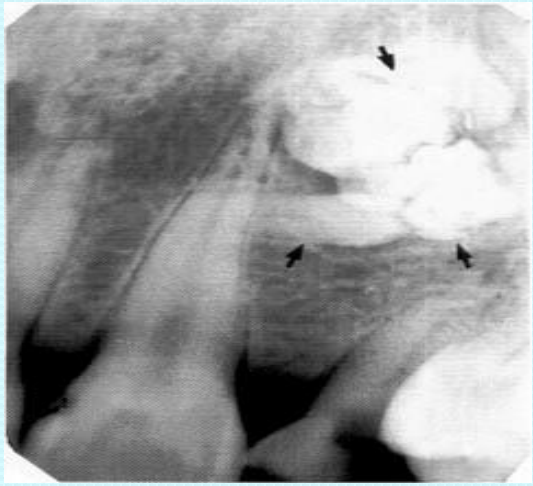

THE EFFECTS OF THE LESION ON SURROUNDING STRUCTURES

provides information
about the nature of the lesion and its mode of growth. For example, the more dangerous the lesion, the more damaging and destructive its effects, and the faster its growth. Some lesions grow and expand in particular ways, such as the odontogenic keratocyst (primordial) which tends to infiltrate the cancellous bone and grow along the body of the mandible and produces little buccal or lingual expansion, whilst an amelo
blastema in the same site tends to expand and infiltrate in all directions.

ANALYZE THE EFFECTS OF THE LESION ON SURROUNDING STRUCTURES

The teeth

- Resorption, which is a feature of longstanding,
benign but locally aggressive lesions,
chronic inflammatory lesions, and malignancy
- Displacement
- Delayed eruption
- Disrupted development, resulting in abnormal
shape and/or density
- Loss of associated lamina dura
- Increase in the width of the periodontal
ligament space
- Alteration in the size of the pulp chamber
- Hypercementosis.

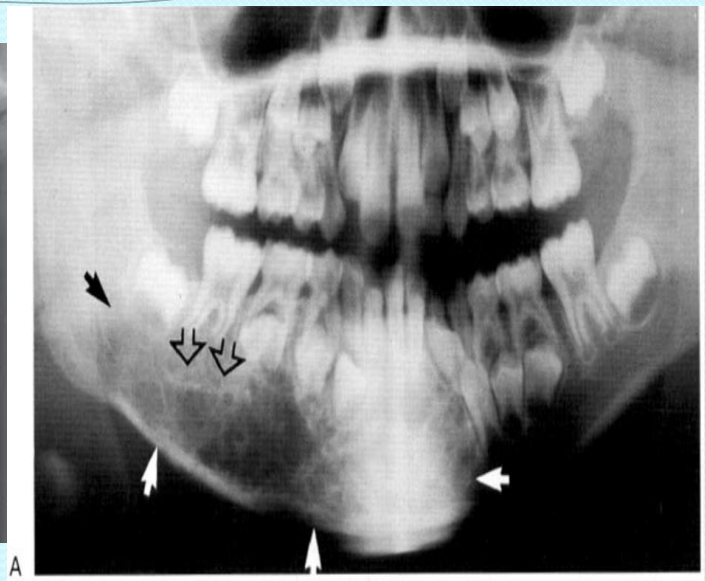

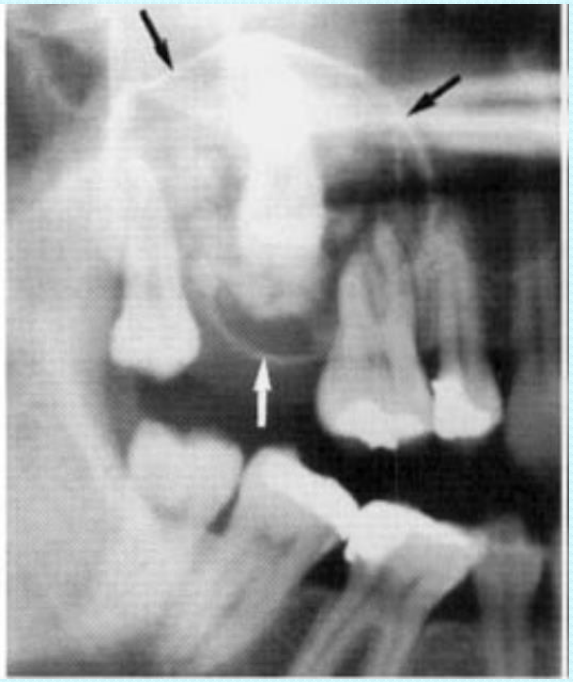

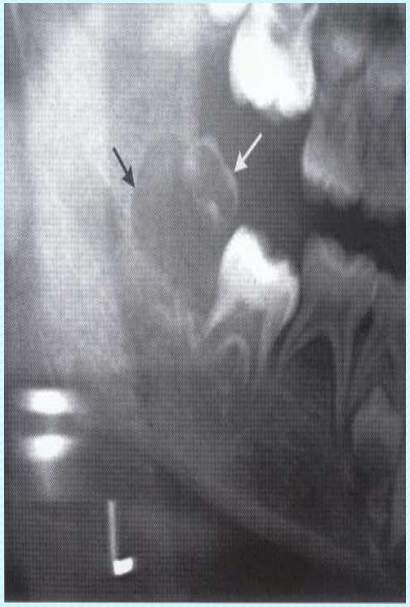

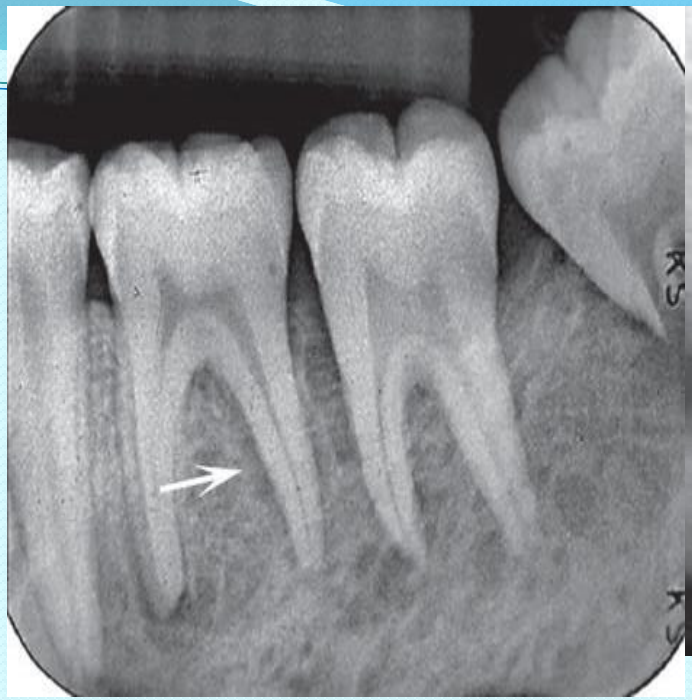

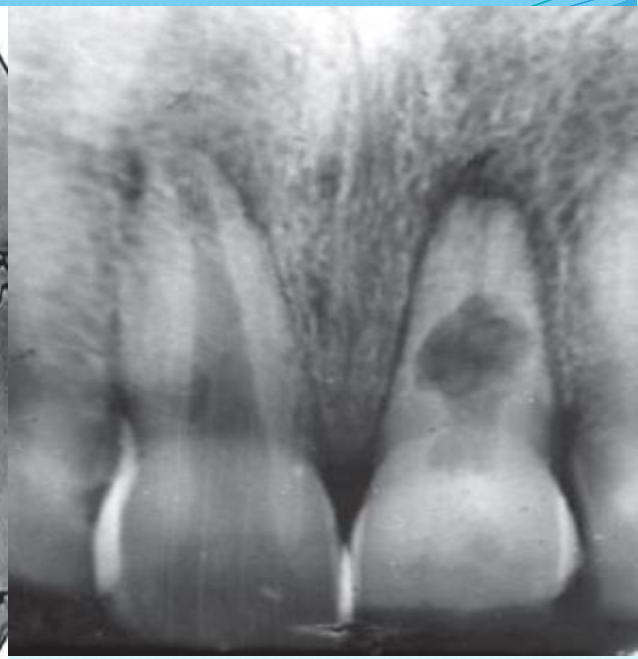

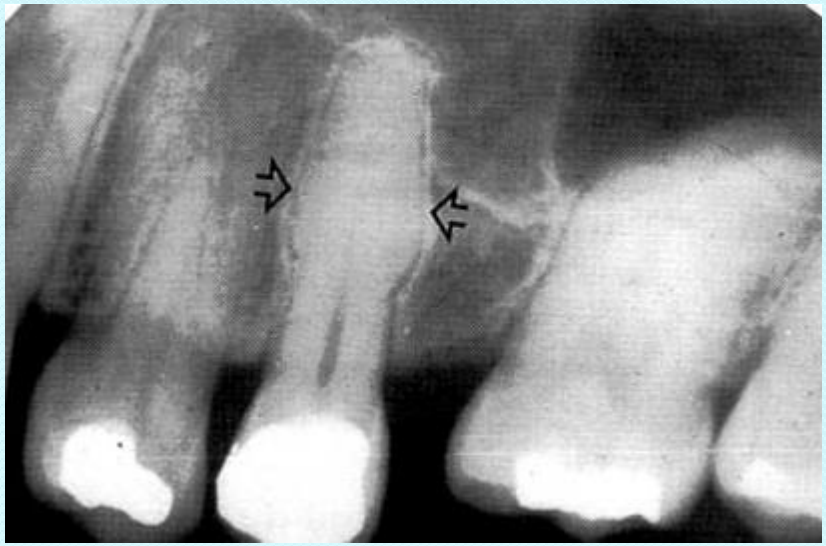

Surrounding bone

- Expansion:
— Buccal
— Lingual
— In other directions
- Displacement or involvement of surrounding
structures, including the:
— Cortex of the inferior dental canal
— Mental foramen
— Lower border cortex of the mandible
— Floor of the antrum
— Floor of the nasal cavity
— Orbits
- Ragged destruction
- Increased density (sclerosis)
- Subperiosteal new bone formation
- An increase in the normal width of the inferior
dental canal
- Irregular bone remodeling, resulting in an
abnormal shape or unusual overall bone
pattern.

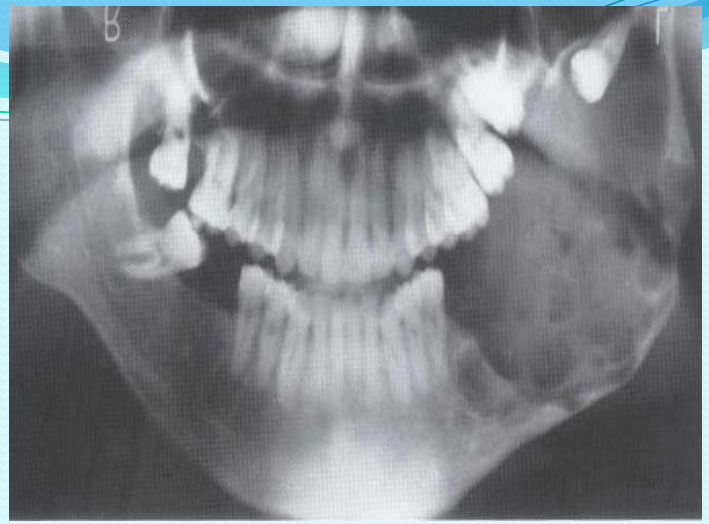

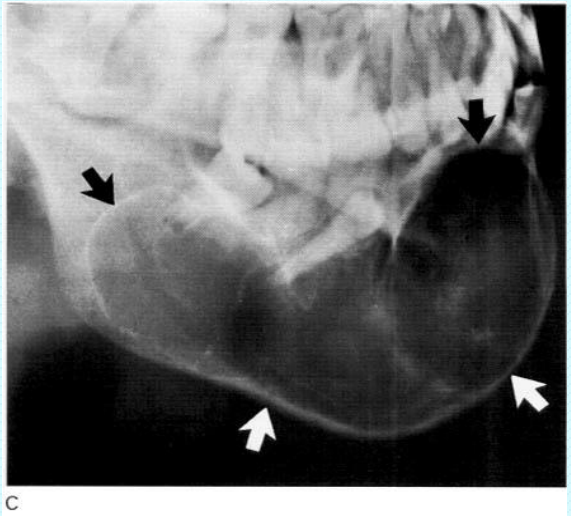

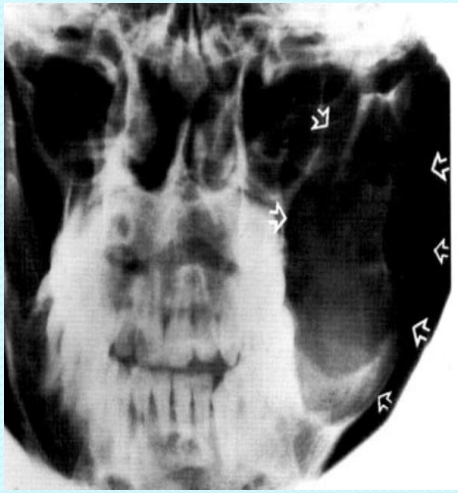

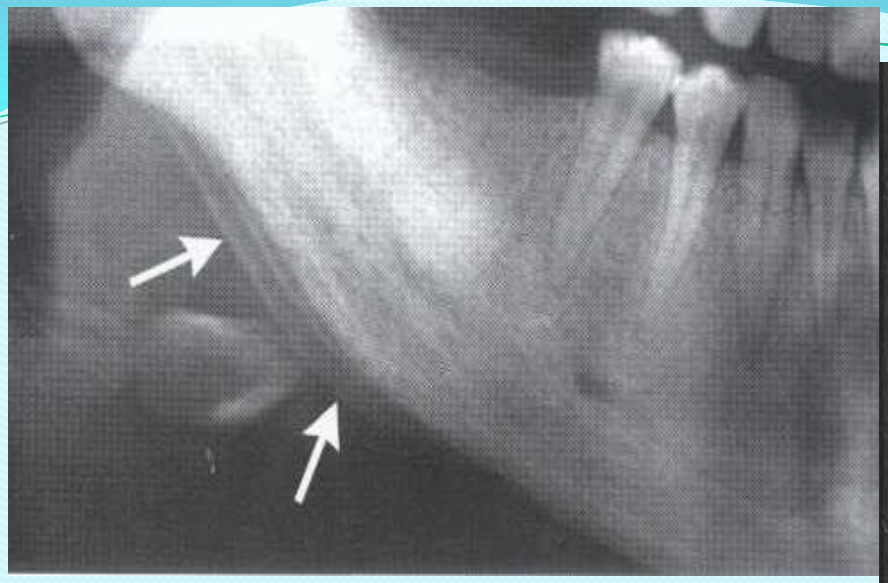

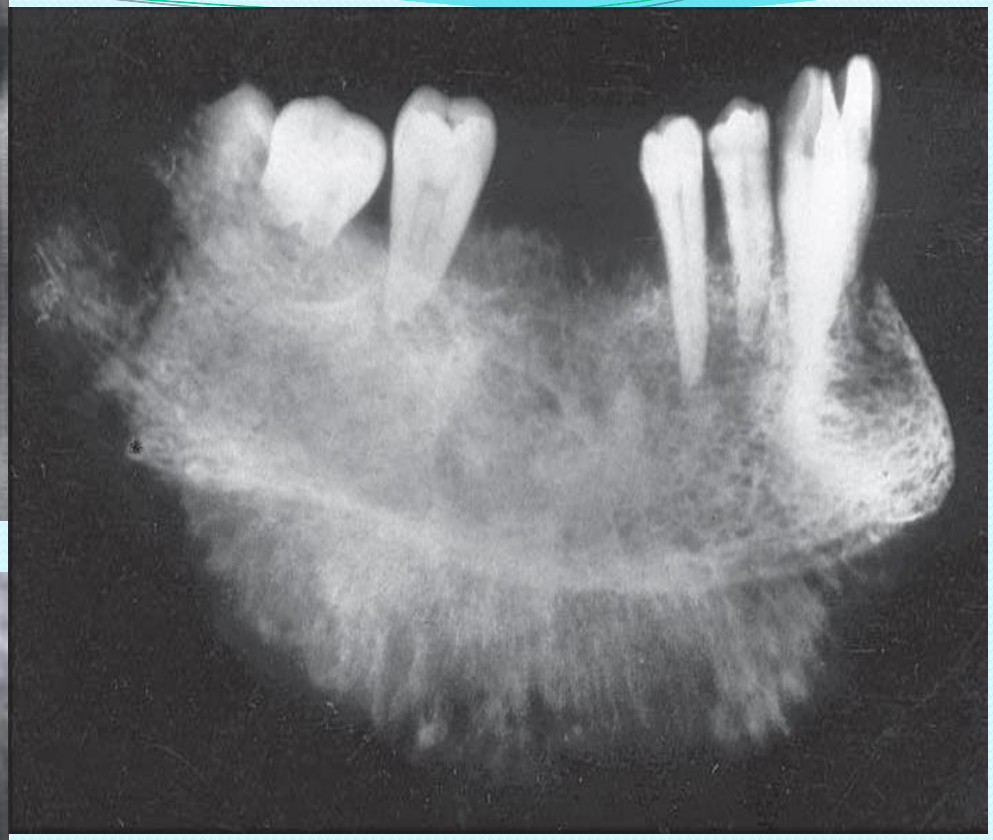

Time present

Unfortunately, this information is not always available. The patient may not be aware of the lesion and there may be no records of when it first became evident.

provide a clue about the nature of the lesion because slow-growing lesions tend to be benign, whilst fast-growing, aggressive lesions are usually malignant

outline

shape

radiodensity

site

This Corticated oval asymptomatic radiolucency , positioned interradicularly between asymptomatic lateral incisor and canine teeth that have vital pulps, is most likely

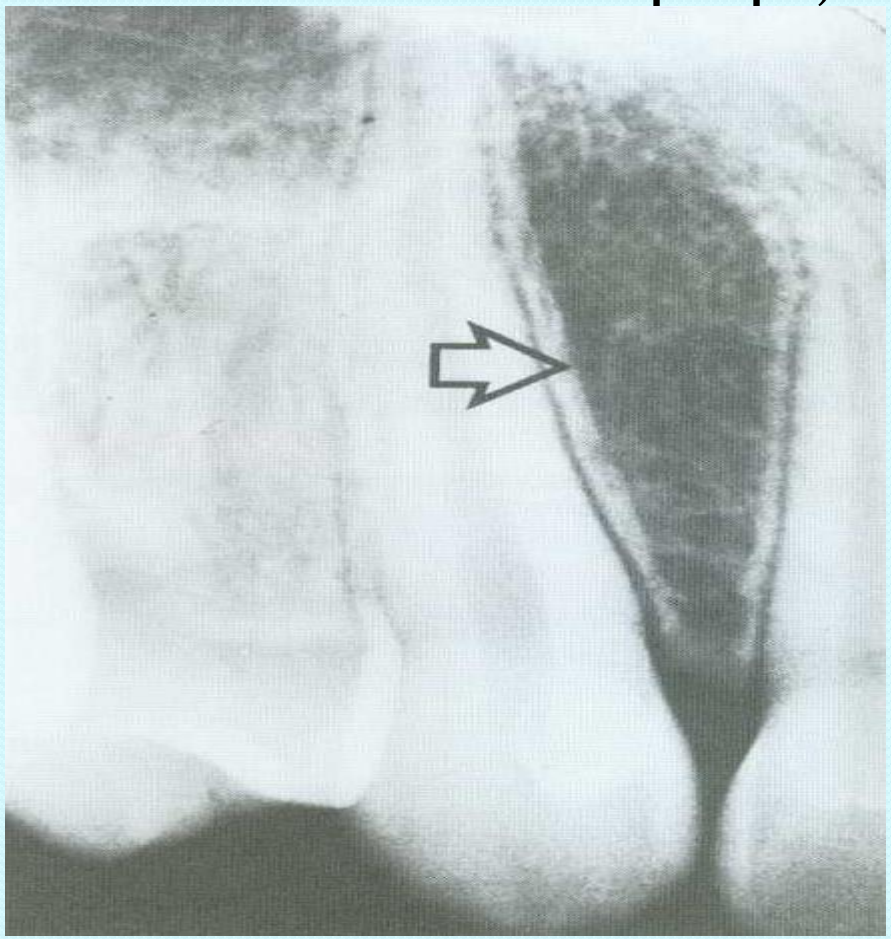

Adenomatoid odontogenic tumour (AOT)
(Fig. 26.10)

- ***Site***: Anterior maxilla — incisor/canine region, occasionally anterior mandible.
- ***Size***: 1–3 cm in diameter.
- ***Shape***: — Monolocular
  — Round or oval
  — Often surrounds an entire unerupted tooth.
- ***Outline***: — Smooth and well defined
  — Well corticated.
- ***Radiodensity***: — Initially radiolucent, but small opacities (*snowflakes*) within the central radiolucency may be seen peripherally as the lesion matures.
- ***Effects***: — Adjacent teeth displaced, rarely resorbed
  — Associated tooth often unerupted
  — Buccal/palatal expansion.

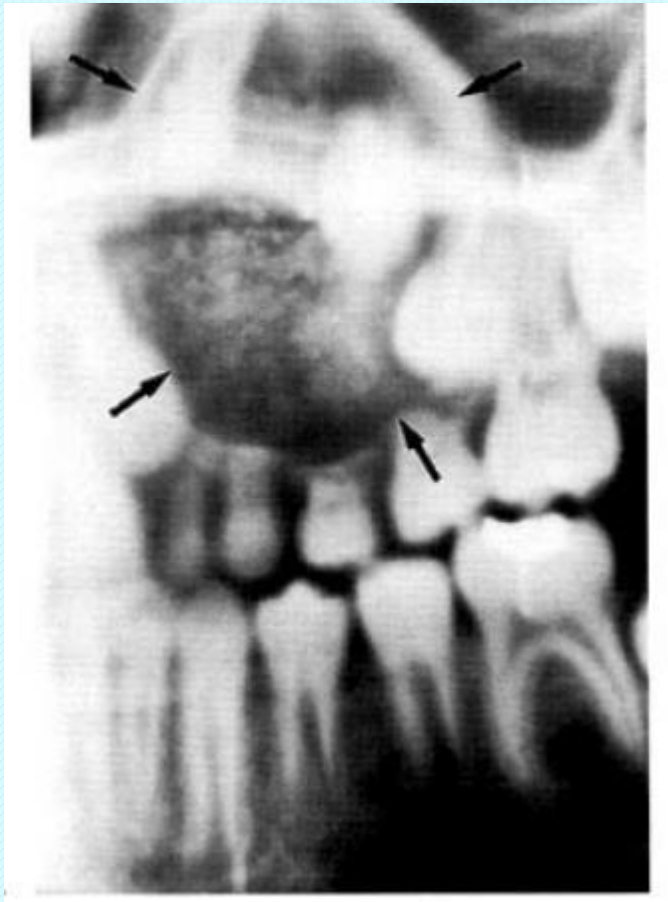

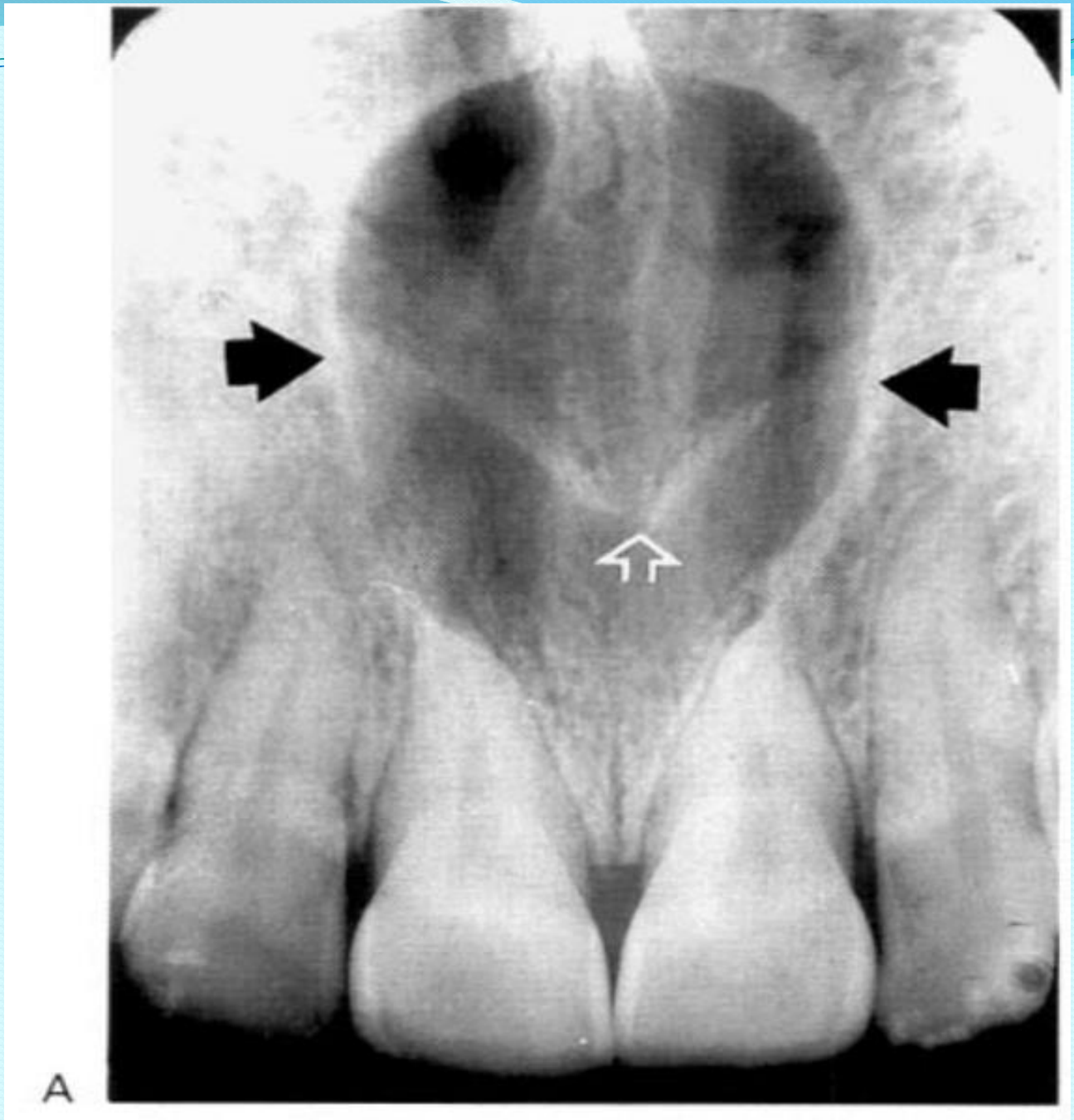
A