

Retinal Detachment

أ.م.د. زينة محمد السبتي

Definitions

A retinal break is a full-thickness defect in the sensory retina.

A retinal detachment (RD) is separation of the sensory retina from the retinal pigment epithelium (RPE) by subretinal fluid (SRF).

Posterior vitreous detachment (PVD) is separation of the cortical vitreous from the internal limiting membrane of the sensory retina posterior to the vitreous base.

Vitreoretinal traction is a force exerted on the retina by structures originating in the vitreous,

A rhegmatogenous RD is one in which SRF derived from synchytic(liquefied) vitreous gains access to the subretinal space through a retinal break.

A tractional RD is one in which the sensory retina is pulled away from the RPE by contracting vitreoretinal membranes, The source of the SRF is unknown. Two important causes of tractional RD are proliferative diabetic retinopathy and penetrating ocular trauma.

An exudative RD is one in which SRF derived from the choroid gains access to the subretinal space through damaged RPE. Important causes are choroidal tumours and inflammation

Pathogenesis of retinal detachment

1-Rhegmatogenous retinal detachment

The retinal breaks responsible for RD are caused by an interplay between vitreoretinal traction and an underlying weakness in the peripheral retina (predisposing degeneration).

ACUTE POSTERIOR VITREOUS DETACHMENT

The pathogenesis of acute posterior vitreous detachment and its potential complications are as follows:

1. Synchysis senilis is an age-related liquefaction of the vitreous gel
2. Some eyes with synchysis senilis develop a hole in the thinned posterior vitreous cortex that overlies the fovea through which synchytic fluid passes into the newly formed retrohyaloid space. This process forcibly detaches the posterior vitreous surface from the retina. . The complications of acute PVD are dependent on the strength and extent of pre-existing vitreoretinal adhesions.

SIGNIFICANCE OF MYOPIA

Although myopic individuals make up 10% of the general population, over 40% of all RDs occur in myopic eyes. The following interrelated factors predispose a myopic eye to RD:

1. **Lattice degeneration** which is more common in myopic eyes of between 6 and 9 D.
2. **Diffuse chorioretinal atrophy** which may give rise to small round holes.
3. **Vitreous degeneration and PVD** which are more common.
4. **Cataract surgery** which increases the risk of RD in myopic eyes, particularly following vitreous loss.

SIGNIFICANCE OF TRAUMA

Trauma is responsible for about 10% of all cases of RD, and is the most common cause in children, particularly boys.

Penetrating posterior segment trauma may cause both rhegmatogenous and tractional RD.

2-Tractional retinal detachment

Diabetic tractional RD

Traumatic tractional RD is the result of vitreous incarceration in the wound and the presence of blood within the vitreous gel which acts as a stimulus to fibroplastic proliferation.

3-Exudative retinal detachment

Exudative RDs are much less common than either rhegmatogenous or tractional RDs. They are caused by subretinal disorders which damage the RPE, thereby allowing the passage of fluid derived from the choroid into the subretinal space.

Causes include choroidal tumours, Harada's disease, posterior scleritis, panretinal photocoagulation, and subretinal neovascularization.

Clinical features of retinal detachment

Rhegmatogenous retinal detachment

SYMPTOMS

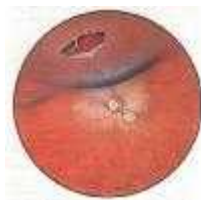The classic premonitory symptoms reported in about 60% of patients with RD are flashing lights and vitreous floaters caused by acute PVD . After a variable period of time, the patient notices a peripheral visual field defect which may progress to involve central vision.

Floaters are moving vitreous opacities which are perceived when they cast a shadow on to the retina.

SIGNS

A fresh RD is characterized by the following signs:

1. A relative afferent pupillary conduction defect is present if the RD is extensive, irrespective of the type.
2. The intraocular pressure is usually lower by about 5 mmHg as compared with the normal fellow eye.
3. A mild anterior uveitis is very common. .
4. Retinal breaks.
5. The detached retina has a convex configuration and a slightly opaque and corrugated appearance



Fresh retinal detachment caused by large retinal tear

Exudative retinal detachment

SYMPTOMS

Photopsia is absent because there is no vitreoretinal traction, although floaters are occasionally present as a result of associated vitritis, The visual field defect may develop suddenly and progress rapidly.

SIGNS

Retinal breaks are absent. The detached retina has a convex configuration, and is smooth and not corrugated as a rhegmatogenous RD.

Retinal detachment surgery

Surgical principles

SCLERAL BUCKLING

Scleral buckling is a surgical procedure for creating an indentation of the sclera ('buckle'). An explant is material sutured directly onto the sclera to create a buckle. The two purposes of scleral buckling are to close retinal breaks by apposing the RPE to the sensory retina and to release vitreoretinal traction.

INTRAVITREAL INJECTIONS

The substances used for injection into the vitreous are: (1) **air**, **saline**, (2) **expanding gases**, (3) **silicone oil** and (4) **perfluorocarbons**.

PARS PLANA VITRECTOMY

Pars plana vitrectomy is an intraocular microsurgical procedure which involves the insertion of instruments, through very small incision in the pars plana, into the vitreous cavity

Diabetic retinopathy

RISK FACTORS FOR DIABETIC RETINOPATHY

1. **The duration of diabetes** is the most important factor.
2. **Good metabolic control** of diabetes will not prevent DR, although it may delay its development by a few years.
3. **Miscellaneous factors** which may have an adverse effect on DR include pregnancy, systemic hypertension, renal disease and anaemia.

PATHOGENESIS OF DIABETIC RETINOPATHY

Diabetic retinopathy is a microangiopathy affecting the retinal precapillary arterioles, capillaries and venules. However, larger vessels may also be involved. Retinopathy has features of both microvascular occlusion and leakage.

Microvascular occlusion

Pathogenesis: factors thought to be responsible for microvascular occlusion include: thickening of the capillary basement membrane, capillary endothelial cell damage and proliferation, changes in red blood cells leading to defective oxygen transport, and increased stickiness and aggregation of platelets .

The consequence of retinal capillary non-perfusion is retinal ischaemia which, in turn, causes retinal hypoxia. Initially, the non-perfused area is located in the midretinal periphery. The two main effects of retinal hypoxia are the following

1. **Arteriovenous shunts** associated with significant capillary occlusion ('drop-out') which run from venules to arterioles.
2. **Neovascularization** is thought to be caused by a 'vasoformative substance' elaborated by hypoxic retinal tissue in an attempt to revascularize hypoxic areas of the retina. This substance promotes neovascularization on the retina and optic nerve head (proliferative DR), and on the iris (rubeosis iridis).

Microvascular leakage

Pathogenesis: the cellular elements of retinal capillaries consist of endothelial cells and pericytes (mural cells). The tight junctions of the endothelial cells constitute the inner blood-retinal barrier. The pericytes are wrapped around the capillaries and are thought to be responsible for the structural integrity of the vessel wall. In normal healthy individuals, there is one pericyte to each endothelial cell, whereas, in diabetic patients, there is a reduction in the number of pericytes. This reduction in pericytes is thought to be responsible for distension of capillary walls and a breakdown of the blood-retinal barrier, leading to leakage of plasma constituents into the retina. Microaneurysms are saccular pouches which may form as a result of local capillary distension.

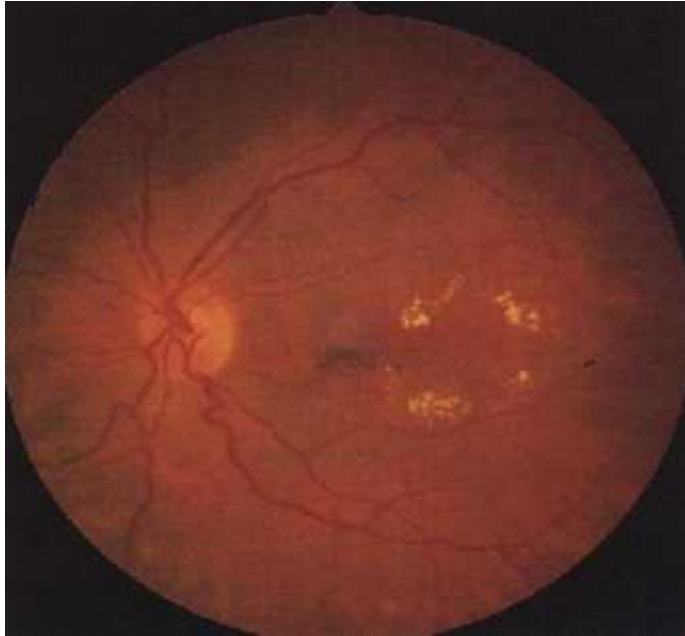
The consequences of increased vascular permeability are haemorrhage and retinal oedema which may be either diffuse or localized.

Simple background diabetic retinopathy

CLINICAL FEATURES

1. **Microaneurysms]**
2. **Haemorrhages.**
3. **Hard exudates** . They vary in size and have a yellow waxy appearance with relatively distinct margins. They are often distributed in a circinate pattern peripheral to areas of chronic focal leakage. The centres of rings of hard exudates usually contain microaneurysms
4. **Retinal oedema**

Eyes with simple background DR not associated with clinically significant macular oedema do not require laser treatment. However, they should be reviewed annually and any factors such as associated hypertension, anaemia or renal failure should, if possible, be corrected.



Preproliferative diabetic retinopathy

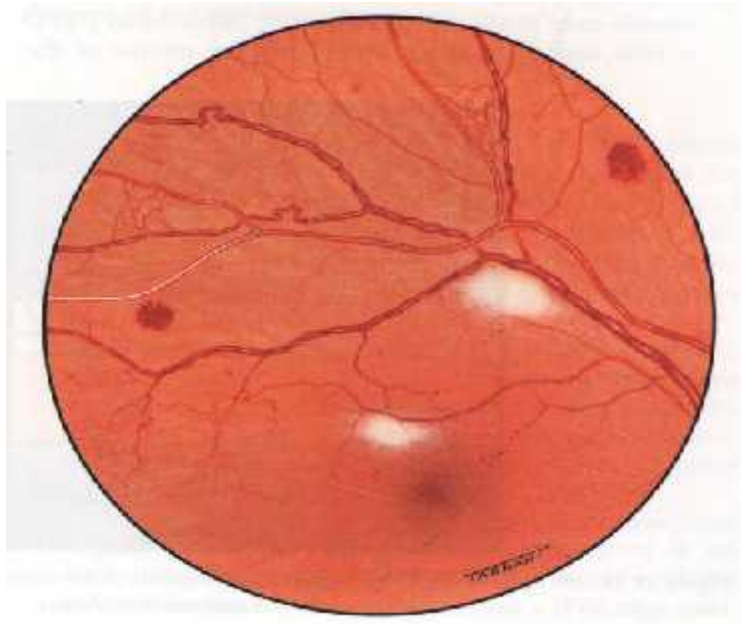
CLINICAL FEATURES

Preproliferative DR develops in some eyes which initially show only simple background DR. All the clinical lesions are caused by retinal ischaemia.

1. **Vascular changes** consist of venous changes in the form of 'beading', 'looping' and 'sausage-like' segmentation, The arterioles may also be narrowed and even obliterated,.
2. **Dark blot haemorrhages** represent haemorrhagic retinal infarcts.
3. **Multiple cotton-wool spots** are caused by capillary occlusion in the retinal nerve fibre layer. .
4. **Intraretinal microvascular abnormalities (IRMA)** are frequently seen adjacent to areas of capillary . closure. Clinically, IRMA may resemble focal areas of flat retinal neovascularization. The main distinguishing features of IRMA are: their intraretinal location, absence of profuse leakage on fluorescein angiography, and failure to cross over major retinal blood vessels.

MANAGEMENT

Patients with preproliferative changes should be watched closely because a significant number develop proliferative DR.



Proliferative diabetic retinopathy

CLINICAL FEATURES

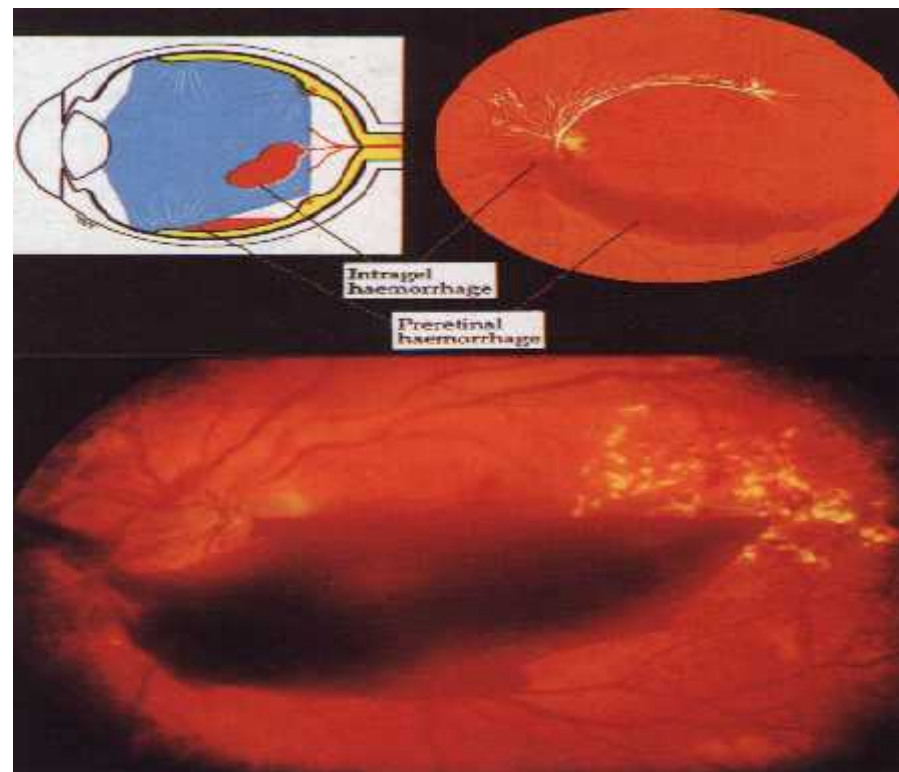
Proliferative diabetic retinopathy (PDR) affects about 5-10% of the diabetic population. Patients with IDD are at increased risk of PDR with an incidence of about 60% after 30 years.

1. **Neovascularization** is the hallmark of PDR. New vessels may proliferate on the optic nerve head (NVD = new vessels at disc), and along the course of the major temporal vascular arcades (NVE = new vessels elsewhere)
2. **Vitreous detachment** (separation) plays an important role in the progression of PDR, ,
3. **Haemorrhage** may occur into the vitreous gel (intragel haemorrhage) or, more frequently, into the retrohyaloid space (preretinal haemorrhage) . Occasionally, a preretinal haemorrhage may penetrate into the vitreous gel. Intragel haemorrhages usually take longer to clear than preretinal haemorrhages.!

MANAGEMENT

Patients should be warned that occasionally vitreous haemorrhage may be precipitated by severe physical exertion or strain, hypoglycaemia and direct ocular trauma. However, not infrequently bleeding occurs while the patient is asleep. Pregnancy may have a worsening effect on PDR, although once the

retinopathy has been successfully treated by photocoagulation, there is no reason to discourage further pregnancies.



PARS PLANA VITRECTOMY

The indications for pars plana vitrectomy are the following:

1. **Severe persistent vitreous haemorrhage**
2. **Tractional retinal detachment** involving the macula..
3. **Combined tractional and rhegmatogenous retinal detachment** should be treated urgently, even if the macula is attached, because subretinal fluid is likely to spread quickly to involve the macula.
4. **Relentlessly progressive fibrovascular proliferation** may occur in a small proportion of patients with IDD, and unless treated by vitrectomy, visual loss may occur rapidly.
5. **Rubeosis iridis associated with vitreous haemorrhage**, which is sufficiently dense to preclude treatment with PRP, must be treated by vitrectomy to prevent progression to neovascular glaucoma.
6. **Dense, persistent, premacular, subhyaloid haemorrhage**