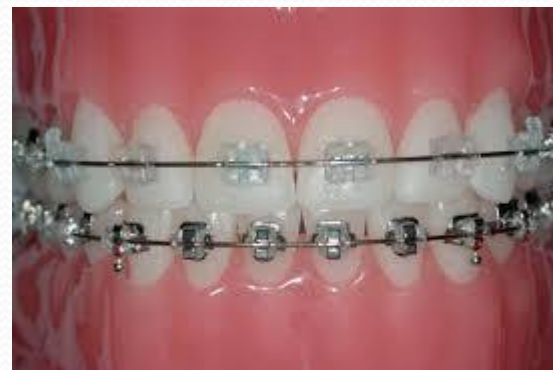
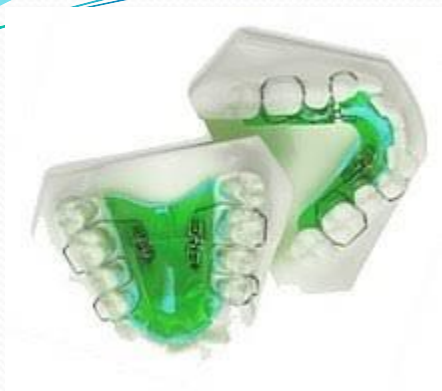
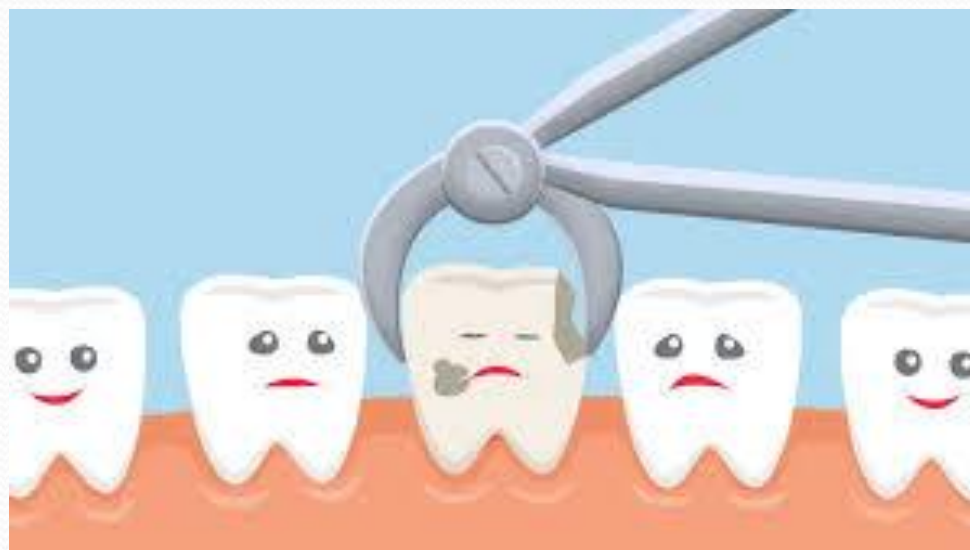

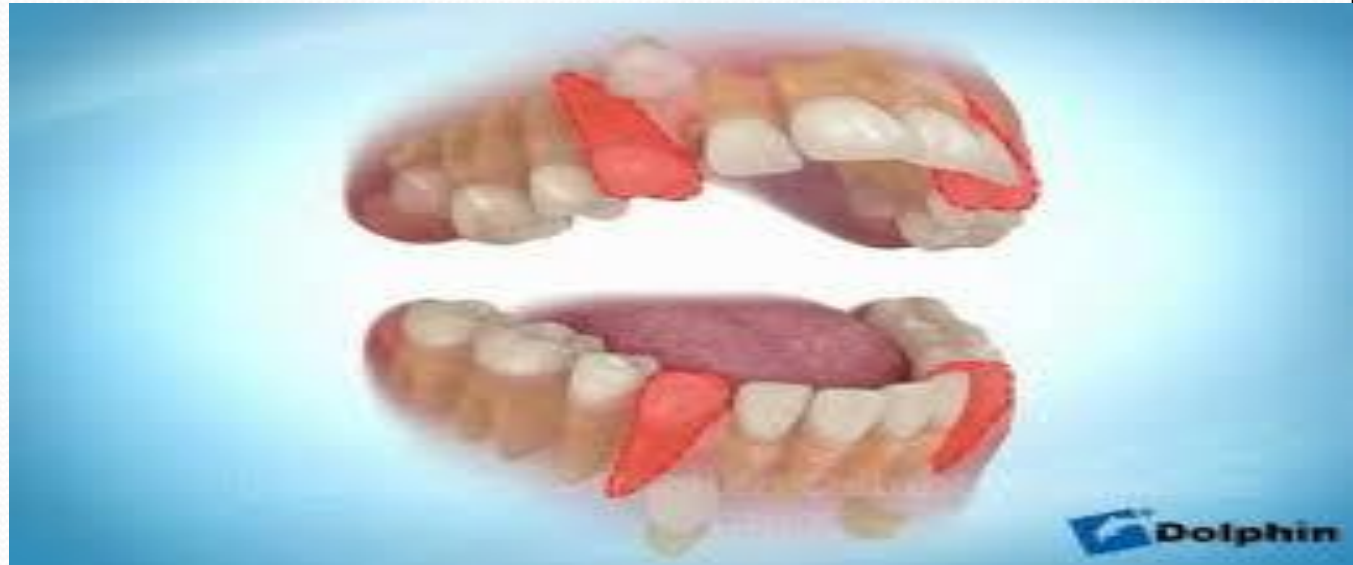Orthodontic treatment plan phases

Ass. Prof. Zena Hekmat

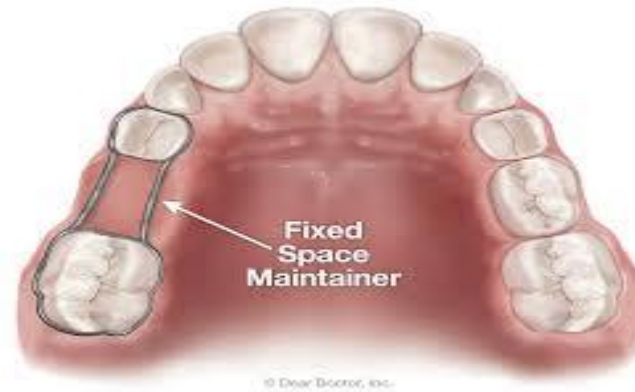
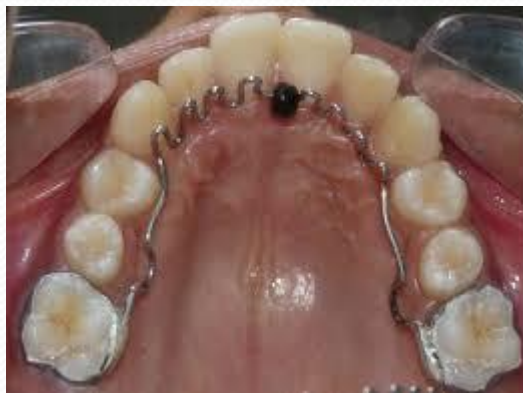
Orthodontic treatment plan phases:

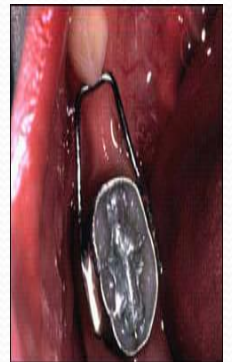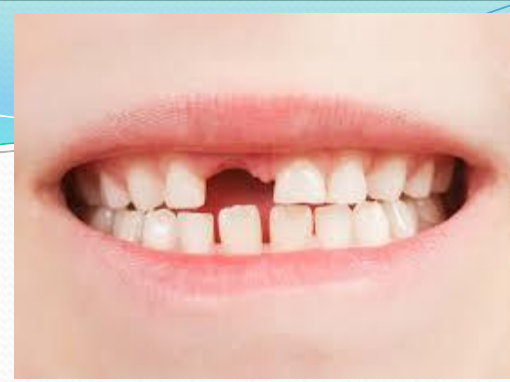- 1-Preventive Orthodontics
- 2- Interceptive Orthodontics
- 3-Corrective Orthodontics



- **Preventive Orthodontics:** Includes all those procedures undertaken to preserve the integrity of normally developing occlusion by protecting current conditions or preventing situations that would interfere with growth by the following measures



- **1-Parent education**
- **3-Maintenance of shedding and eruption timetable**
- **4-Management of premature loss of deciduous teeth:**
- **5- Management of ankylosis of deciduous teeth:**
- **6- Prolonged retention of deciduous teeth**
- **7-Extraction of Supernumerary Teeth**
- **8- Management of Oral Habits**
- **10-Treatment of Occlusal Prematurity:**
- **11-Management of Abnormal Frenum Attachment**
- **12- Space maintainers**



-
- **Interceptive orthodontics:** “that phase of science and art of orthodontics employed to recognize and eliminate potential irregularities and malpositions in the developing dentofacial complex”



- **Interceptive Orthodontics:**

- Interceptive orthodontics is undertaken at a time when malocclusion has already developed or developing. The difference between preventive and
- interceptive orthodontics lies in the timing of the services rendered. Preventive orthodontic procedures are undertaken when the dentition and occlusion are perfectly normal, while the interceptive procedures are carried out when signs and symptoms of a developing malocclusion are evident.
- Interceptive orthodontic procedures may include:

- **1-serial extraction**
- **2-Correction of developing cross-bites**
- **3-Control of abnormal oral habits**
- **4-Proximal stripping of deciduous teeth to facilitate the eruption of adjacent permanent teeth**
- **5-Correction of occlusal interferences**
- **6-Interception of skeletal malrelations**
- **7- Space regaining**
- **9-Muscle exercises**

Corrective early treatment:

Complete or nearly complete correction of an orthodontic problem.

e.g. Expansion appliances, growth modification appliances, alignment of anterior teeth.

II. Goals of Early Treatment

Overall goal of early treatment:

To improve or correct orthodontic problems that would result in:

- Irreversible damage to the dentition and supporting structures.
- Progression into a more severe orthodontic problem that would be more difficult to treatment in Phase II.



SERIAL EXTRACTION

Management

Serial Extraction: A planned sequence of tooth removal during the transition from primary to permanent dentition to promote eruption of teeth through attached gingiva (keratinized tissue) and reduce the severity of crowding.

Eruption sequence of the permanent

dentition: **Maxilla:** 6 1 2 4 5 3 7 8

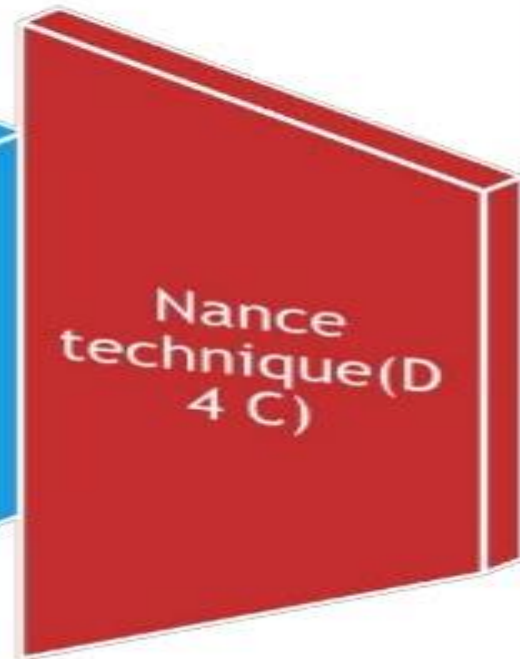
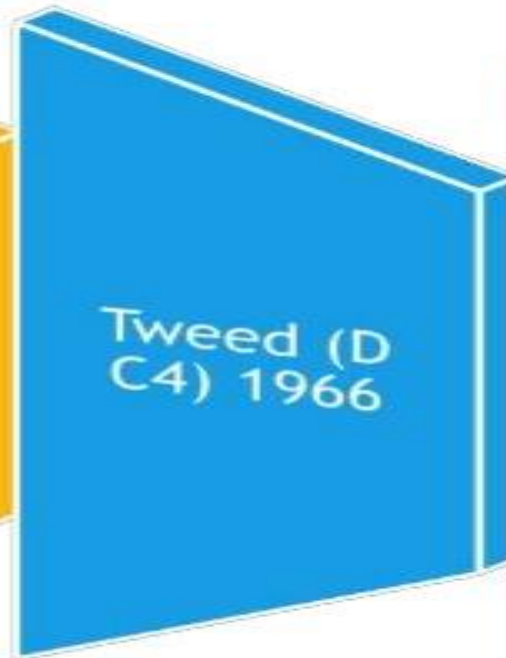
Mandible: 6 1 2 (3 4) 5 7 8

Serial Extraction

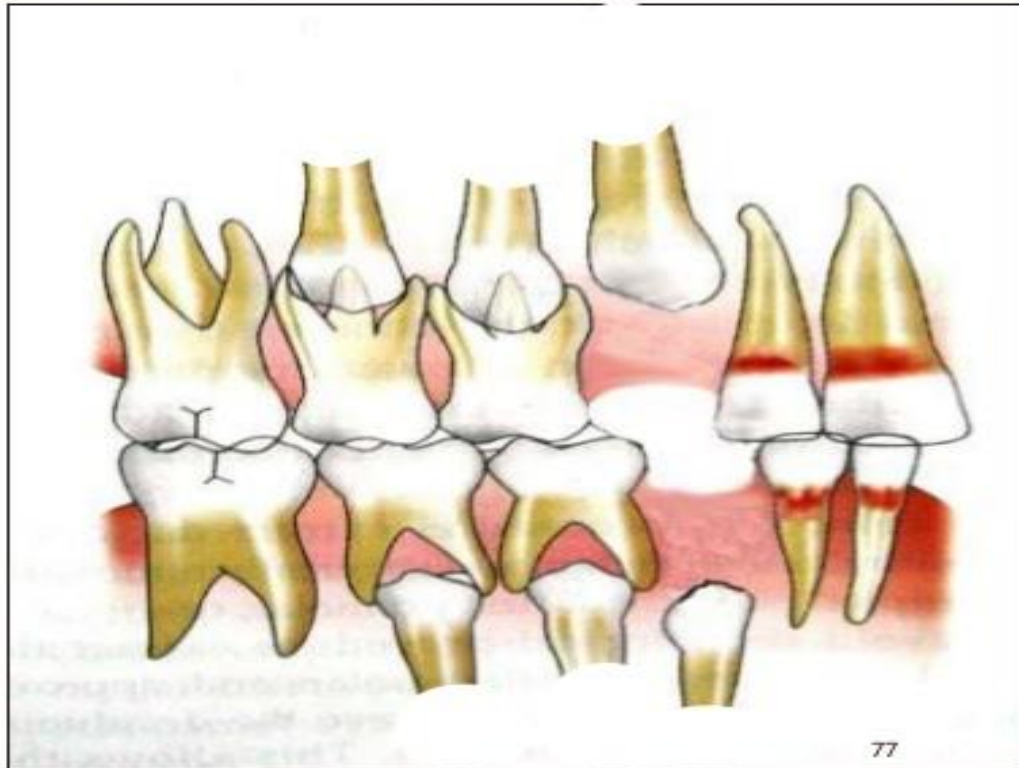
Case selection:

1. No skeletal disproportions
2. Class I molar relationship
3. Non-retrusive lip profile
4. Normal overbite
5. Coincident midlines
6. Severe crowding warranting extractions.

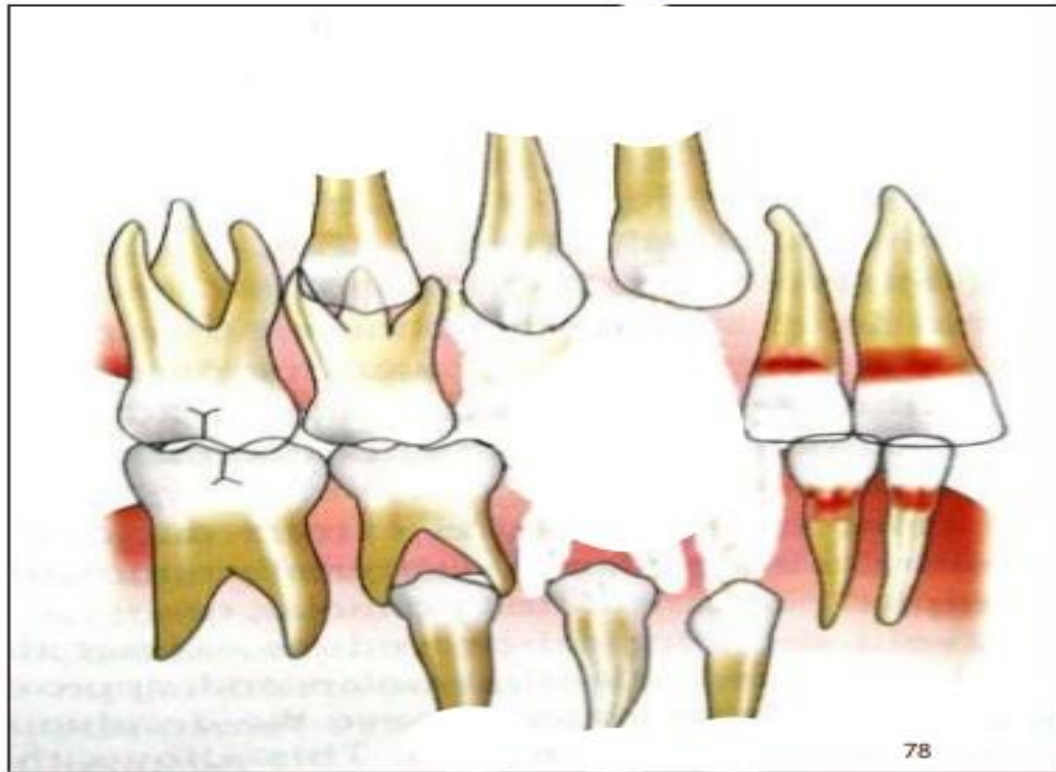
3 DIFFERENT METHODS....



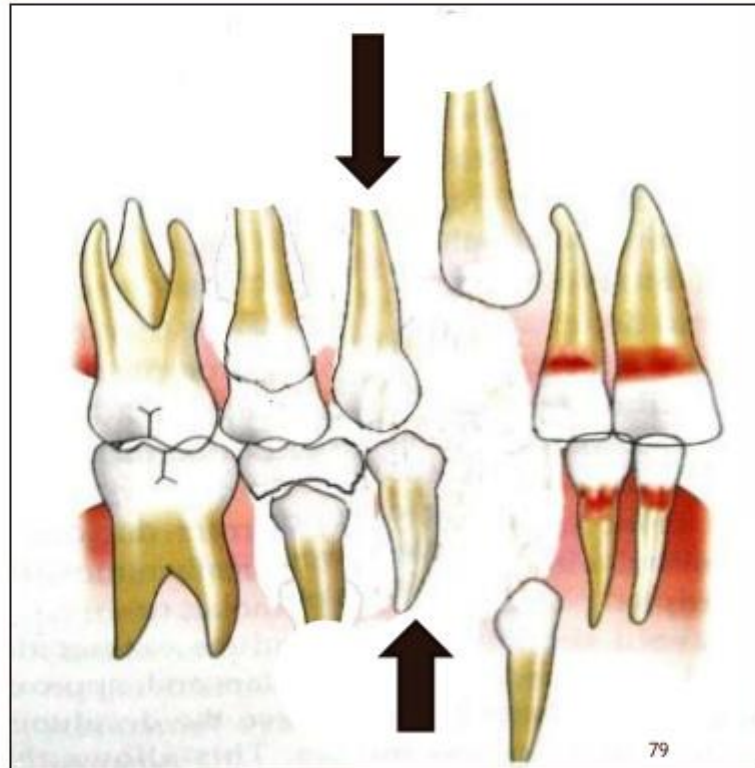
A. EXTRACTION OF DECIDUOUS CANINE (8.5 YEARS)



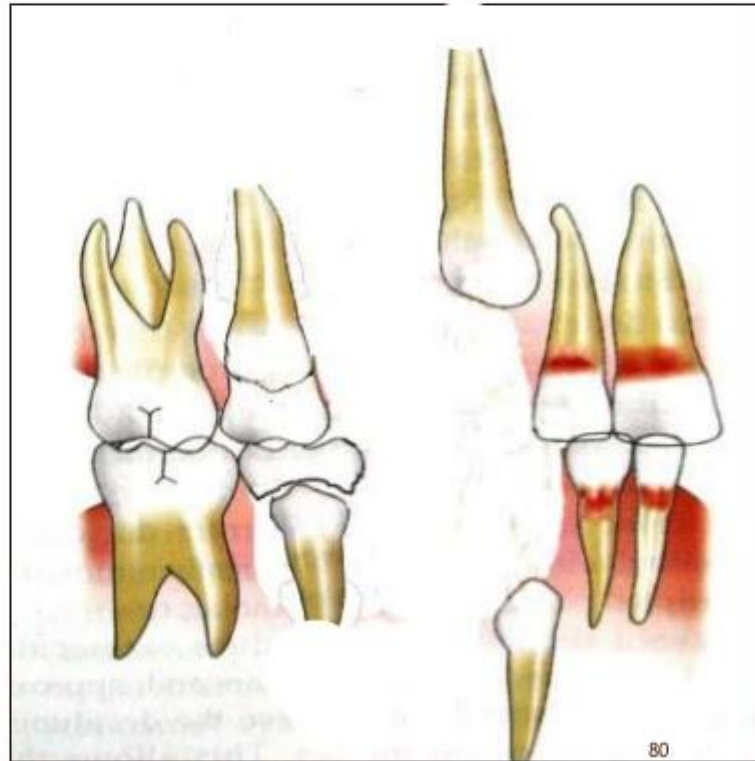
B. EXTRACTION OF FIRST DECIDUOUS MOLAR-



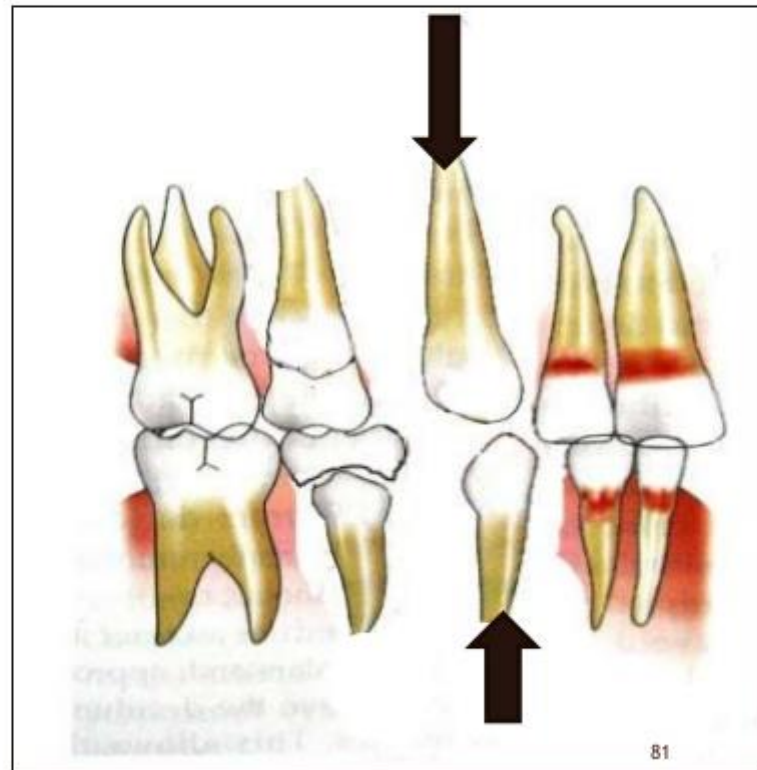
FIRST PREMOLAR ERUPTS



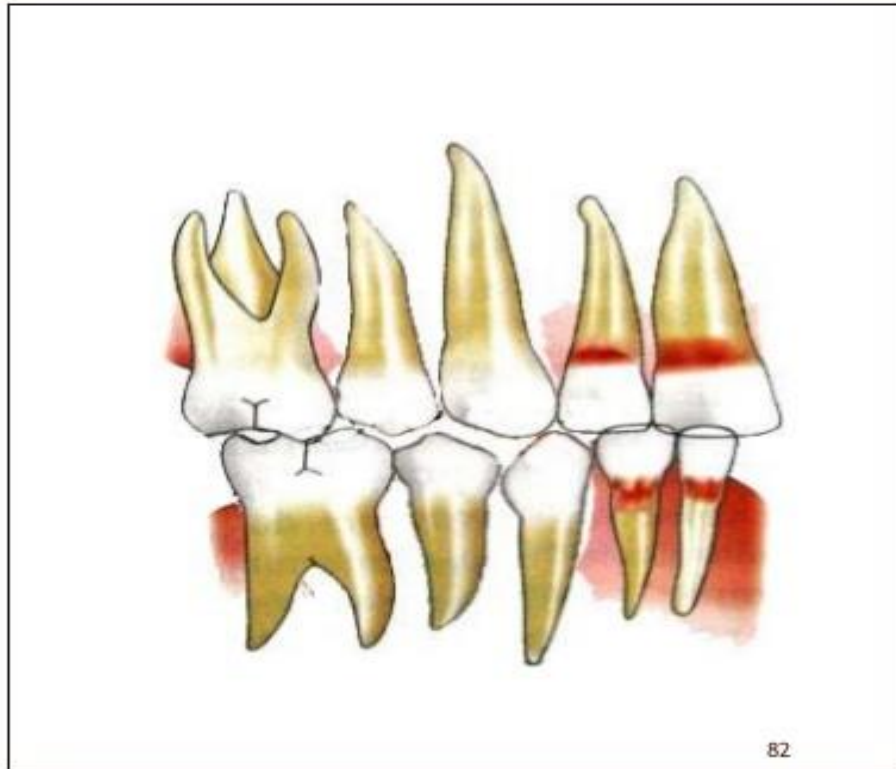FIRST PREMOLAR EXTRACTED

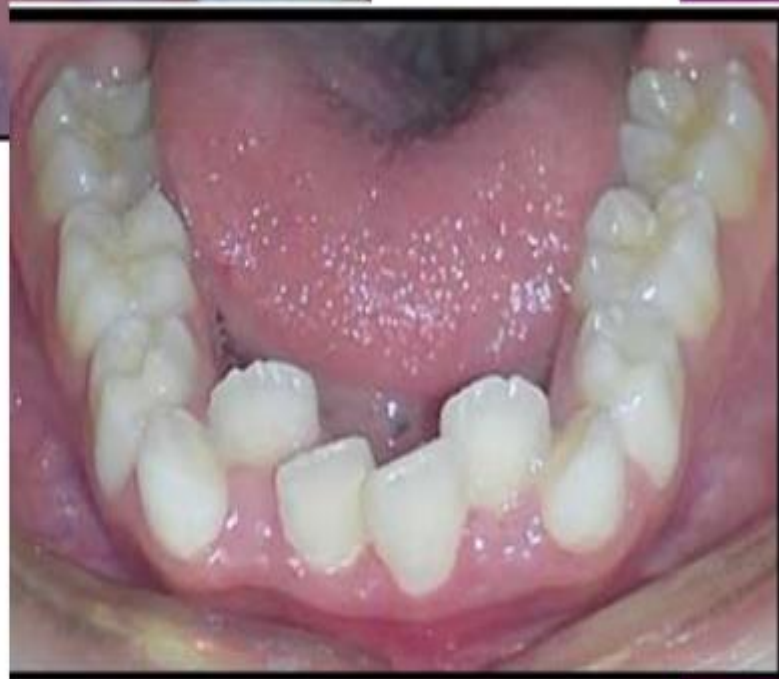
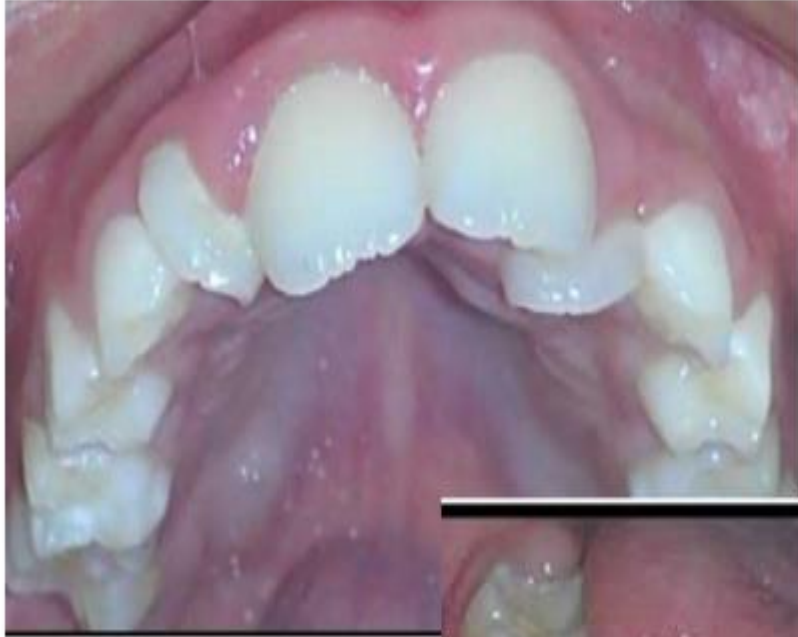
PERMANENT CANINE ERUPT



FINAL POSITION.....





OTHER VARIATIONS.....

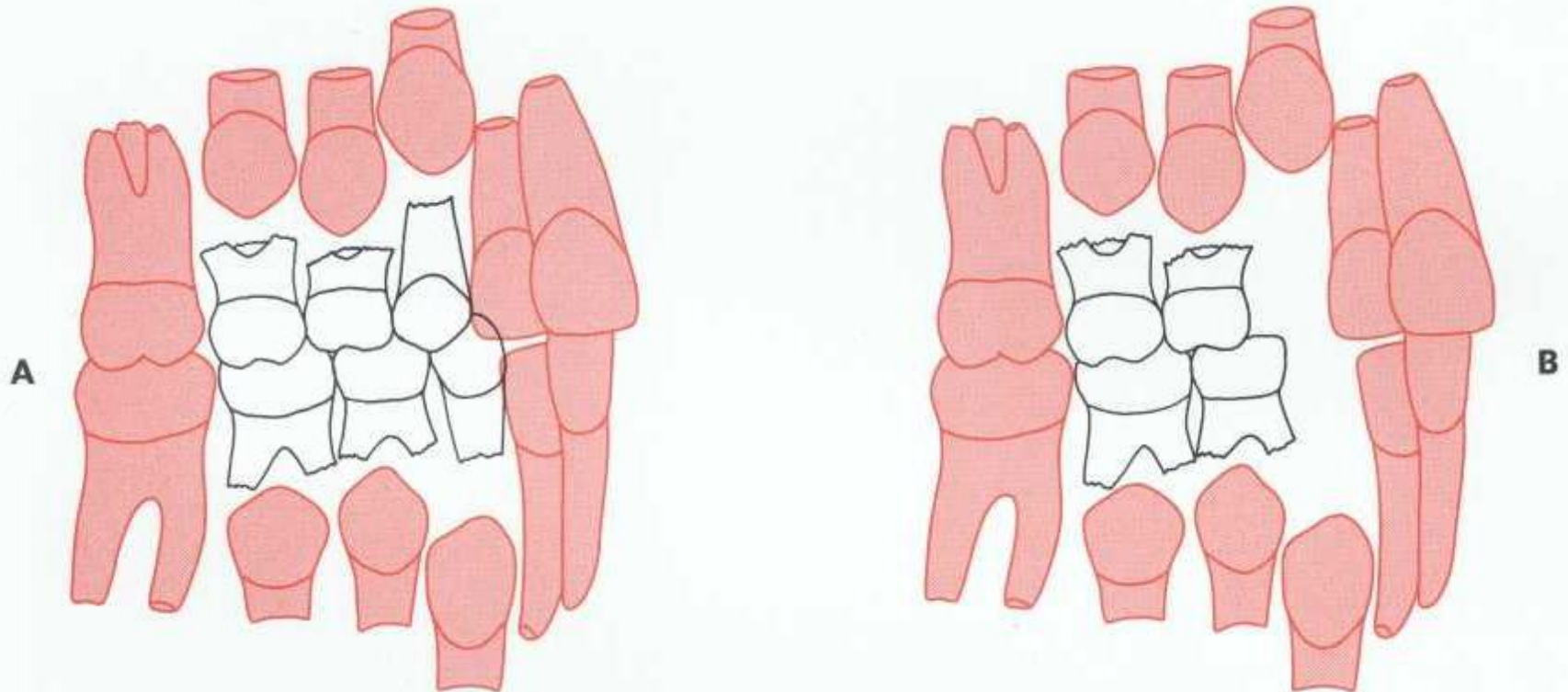
If canine is erupting faster than premolar

then enucleation of first premolar can be done.

Or extraction of 2nd deciduous molar followed by lingual arch space maintainer

procedure:

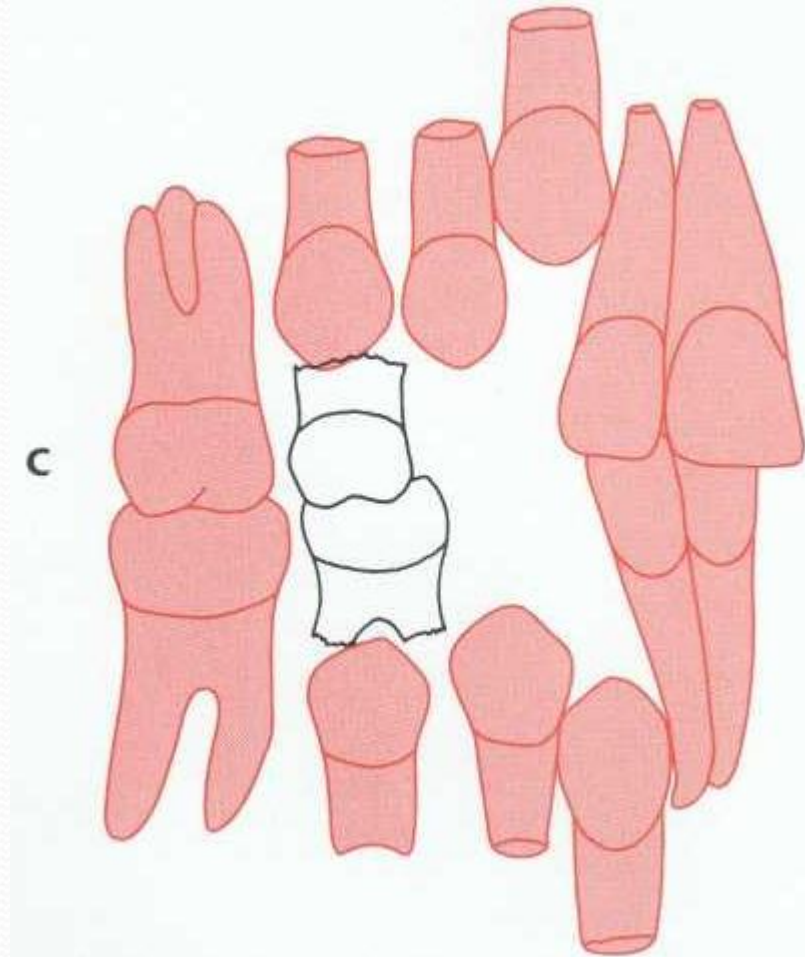
Extraction of Cs as soon as the permanent incisors complete their eruption, such extraction will allow spontaneous relief of crowding.



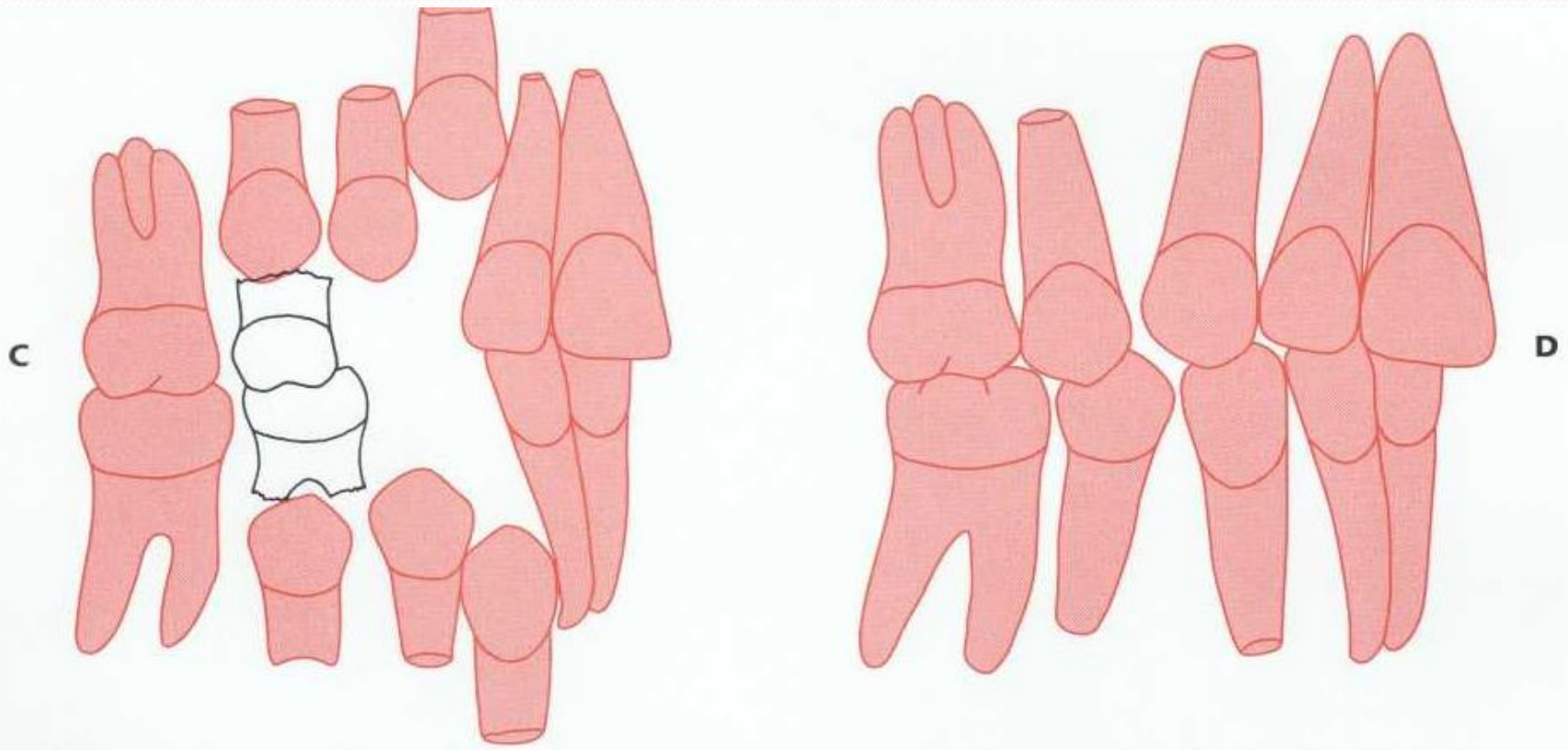
Procedure...

Extraction of Ds, and this is done after an accepted alignment of the incisors.

The aim of these extractions is to accelerate the eruption of the permanent first premolar.



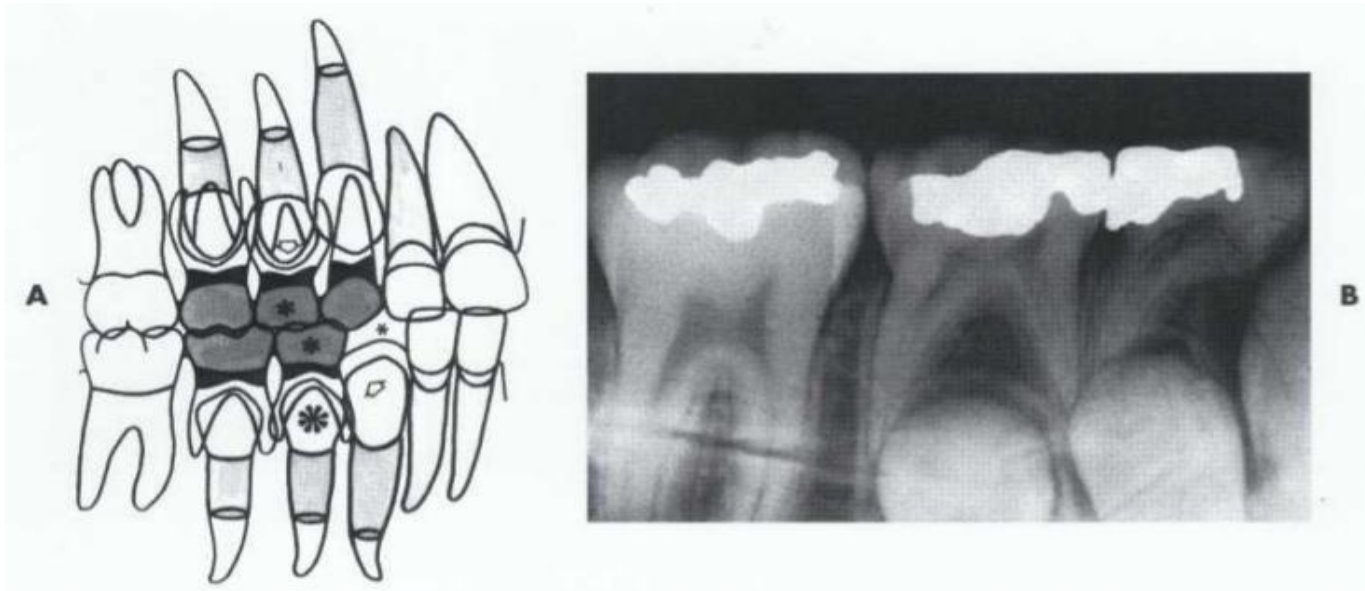
Extraction of permanent first premolar as soon as they emerge from the oral mucosa, thus allowing the space for the canines and 2nd premolars to occupy the space mesial to 6s and distal to 2s.



I. CASES NEED ENUCLEATION IN THE MANDIBLE :

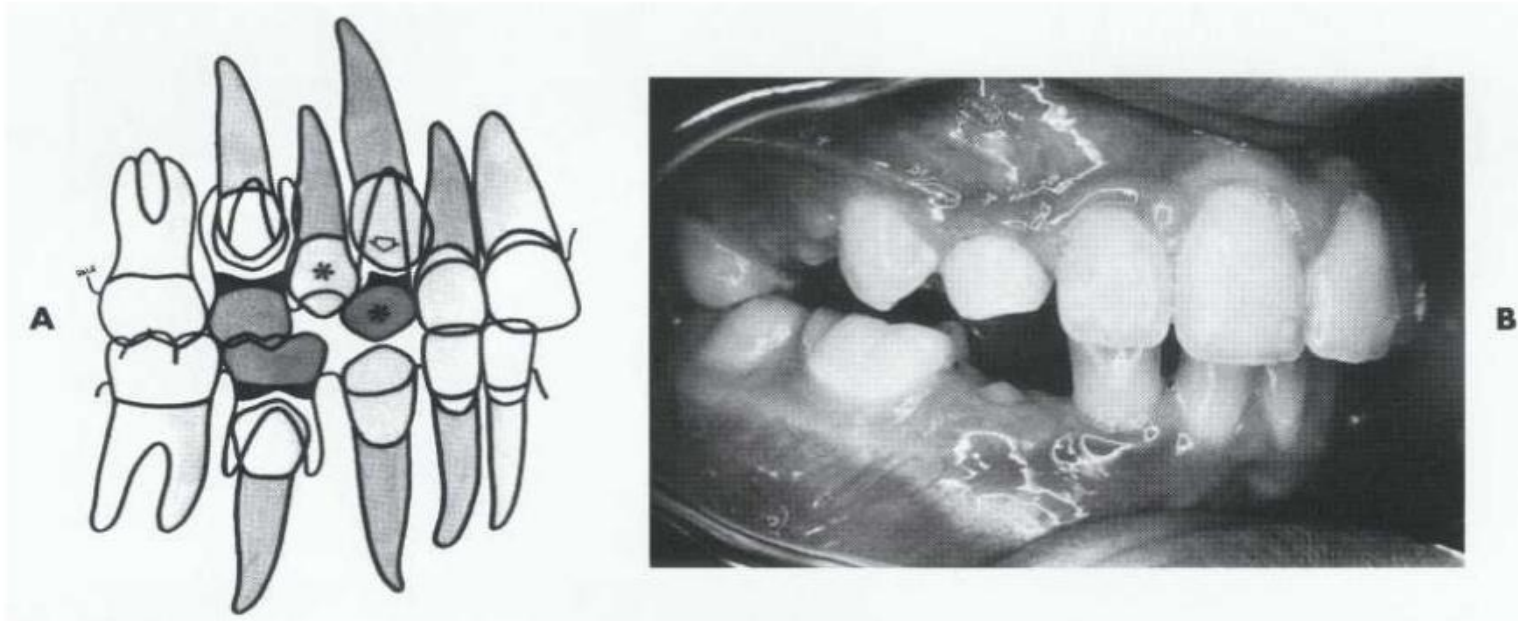
- Treatment Procedure :

I. *Extraction of the primary first molars and enucleation of the mandibular first premolars :*



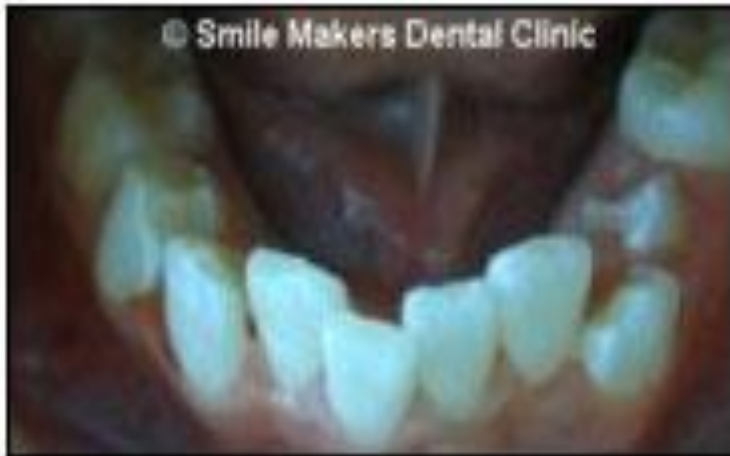2. Extraction of the primary maxillary canines and maxillary first premolars:

In the maxilla the first premolars usually emerge before the canines. Therefore enucleation is less likely to be indicated.

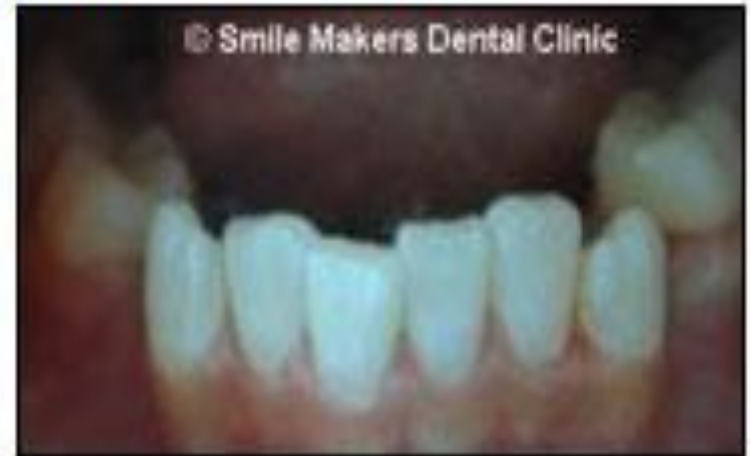

Serial extraction

Crowded Teeth can be Improved with Extractions



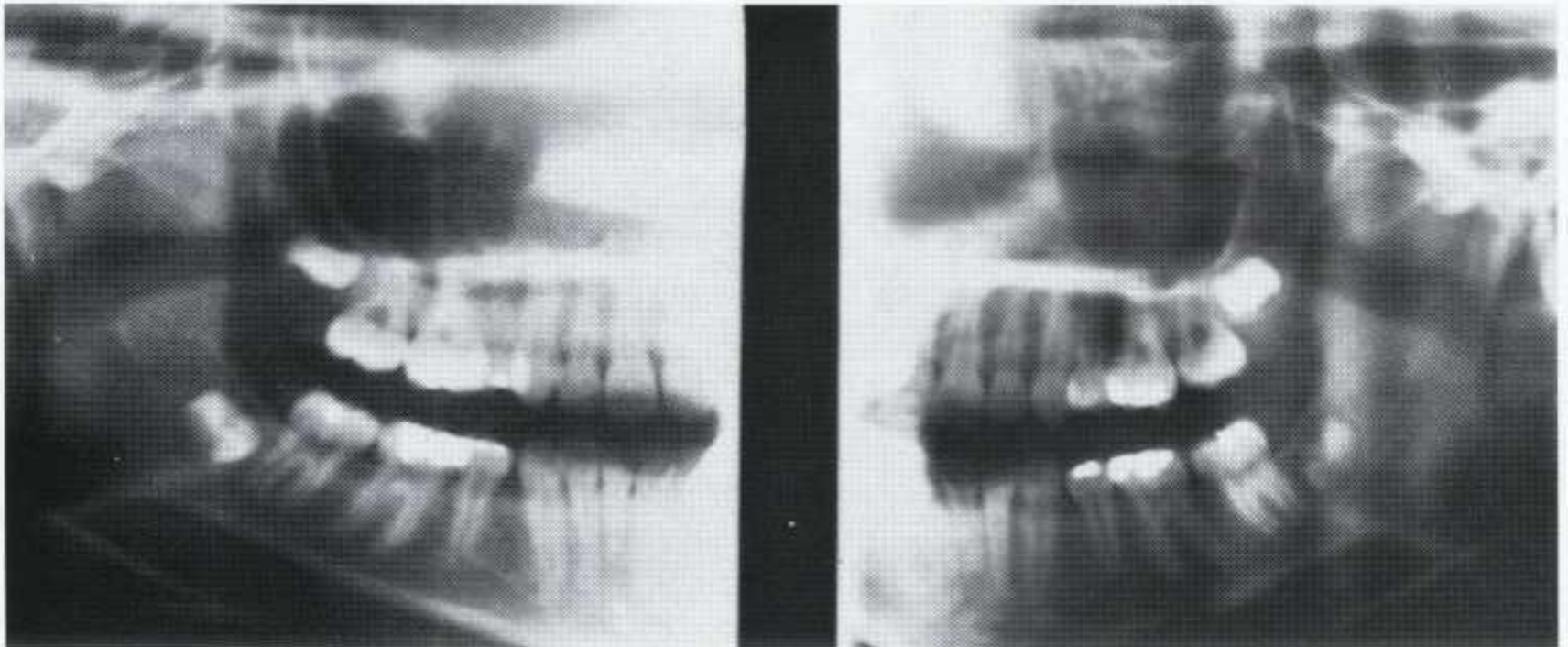
Crowded teeth in 9 year-old girl



One month after extracting premolars, the teeth are already looking straighter.

Serial Extraction

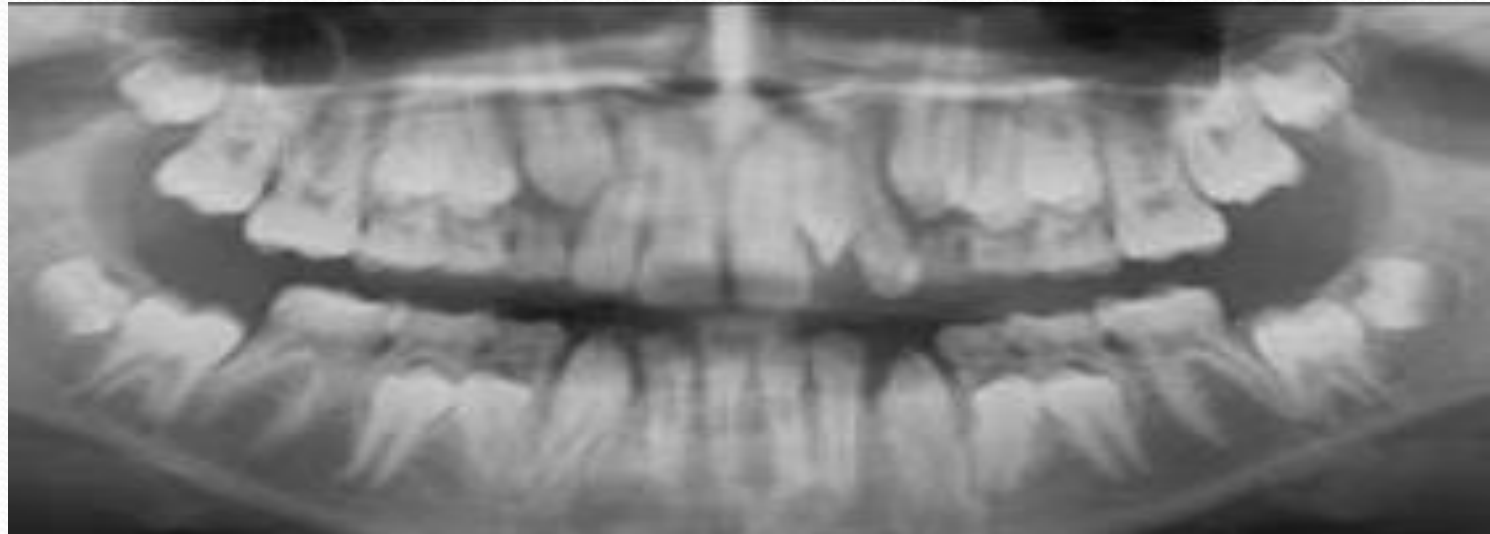
Phase II full braces for alignment, bite and root parallelism.



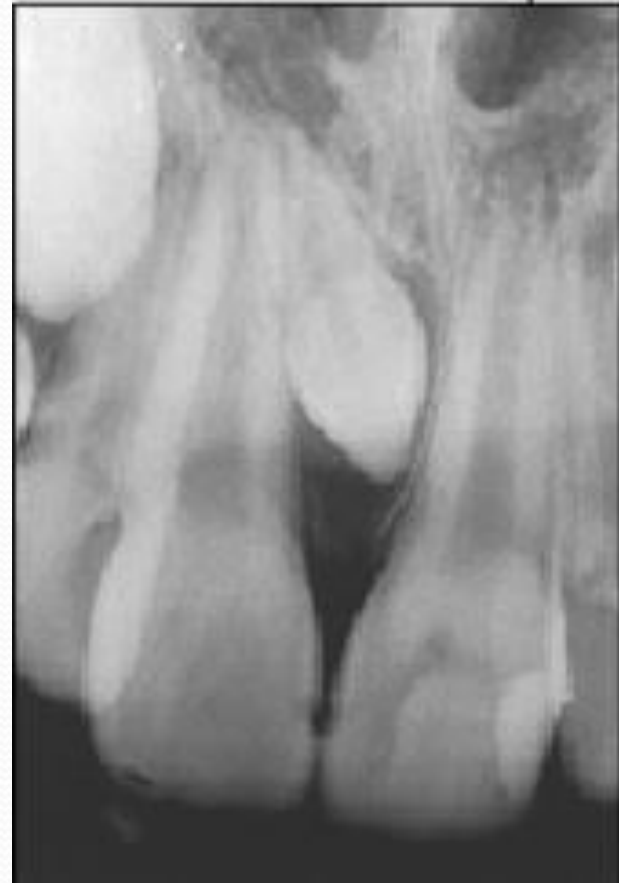Complications:

- I. A complication can occur if the primary first molar is extracted early and the first premolar still does not erupt before the canine. This can lead to impaction of the premolar that requires later surgical removal .
- II. Loss of some arch perimeter.
- III. Concave profile.
- IV. Increase in overbite.
- V. Not enough to solve the problem (alone).

- A complete diagnostic aids should be taken before starting the S.E. procedure and the patient should have at least beside clinical examination an OPG that can demonstrate the existence of the complete dentition at the beginning of the treatment.



- All the local factors that worsen the crowding should be avoided during the treatment such as presence of S.N.T, as early loss of primary Es or bad conservative work for the rest of the remaining teeth.



Advantages:

- Immediate relief of crowding or malocclusion.
- Less time consuming and low cost especially if at the end, the teeth arranged with good alignment.
- Simple procedure
- Less duration of wearing orthodontic appliances.

DISADVANTAGES:

- Requires clinical judgment
- Prolonged treatment time(2-3 years)
- Patient compliance(multiple visits)
- Psychological trauma of extraction.



- Possibility of developing tongue thrust
- Arch length reduction
- Ditching between canine and second premolar
- Axial inclination should be corrected later.

To be considered.....

- In a lot of cases the final outcome of teeth alignment are accepted by the parent, patient and even the dentist. However, an upper and lower fixed appliances are needed to give the final touches....
- The appliances are worn for 6-8 months only rather than 2-2.5 years.



Thank
you

Thank