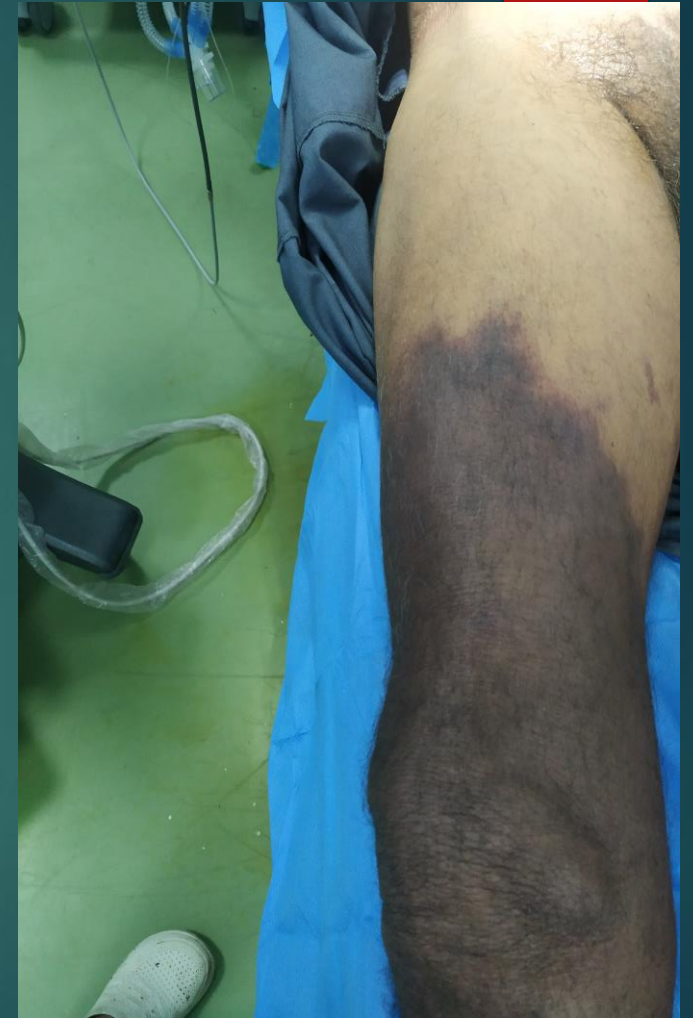



Acute limb ischemia



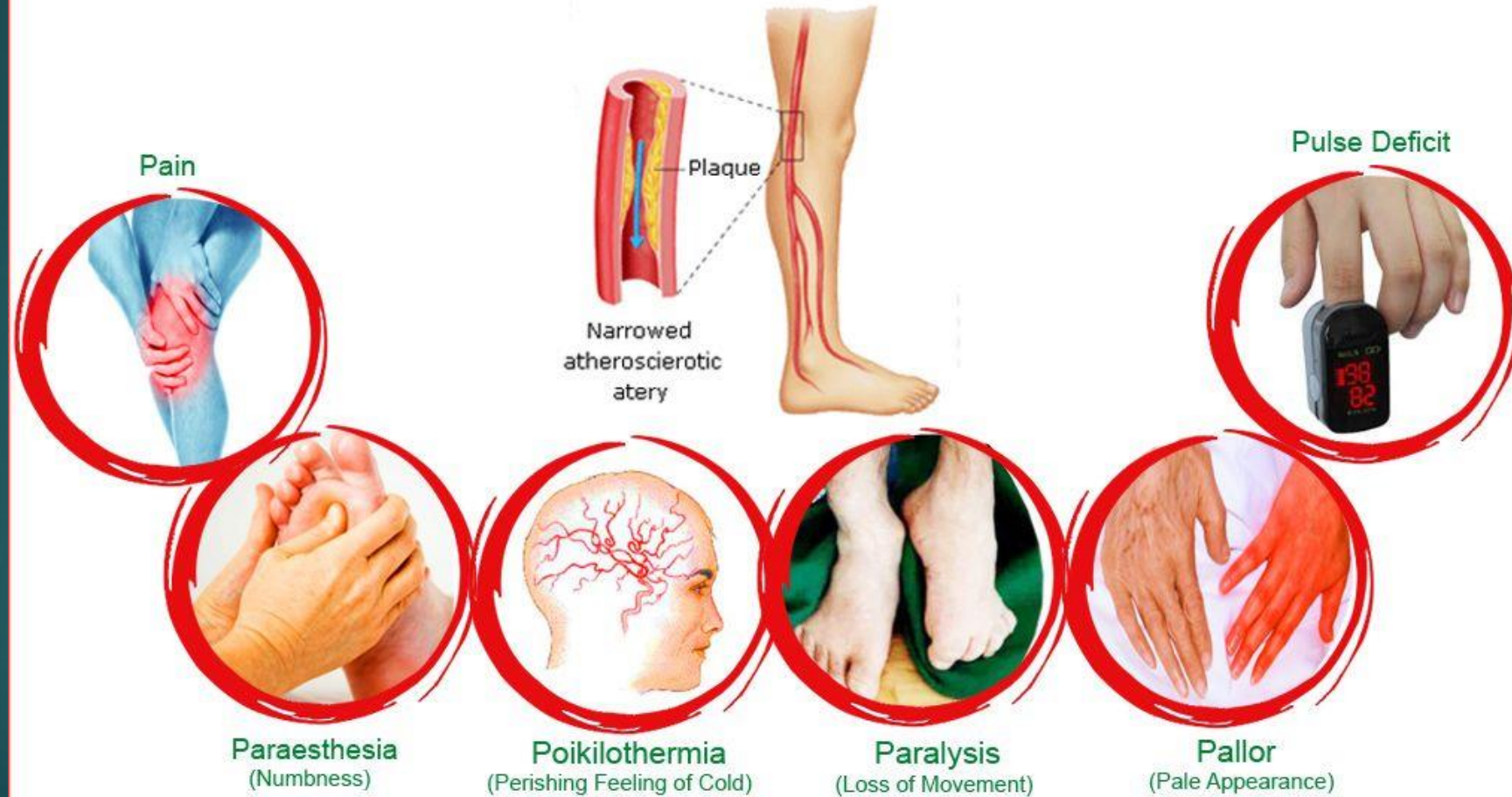
72 years old male
DM
HT
No ICU admission history
No history of trauma
Not smoker



- 
- ▶ Presented with cold limb
 - ▶ Pallor
 - ▶ Severe pain
 - ▶ After 5 days bluish discoloration
 - ▶ Line of demarcation

Six P's Of Critical Limb Ischemia

Peripheral Artery Disease



Approach

- ▶ History
- ▶ Examination
- ▶ Investigations

Acute or chronic

- ▶ Chronic
- ▶ Atherosclerosis
- ▶ Raynauds disease
- ▶ Beurgers disease
- ▶ Vasculitis

Management

- ▶ Medical

Management

