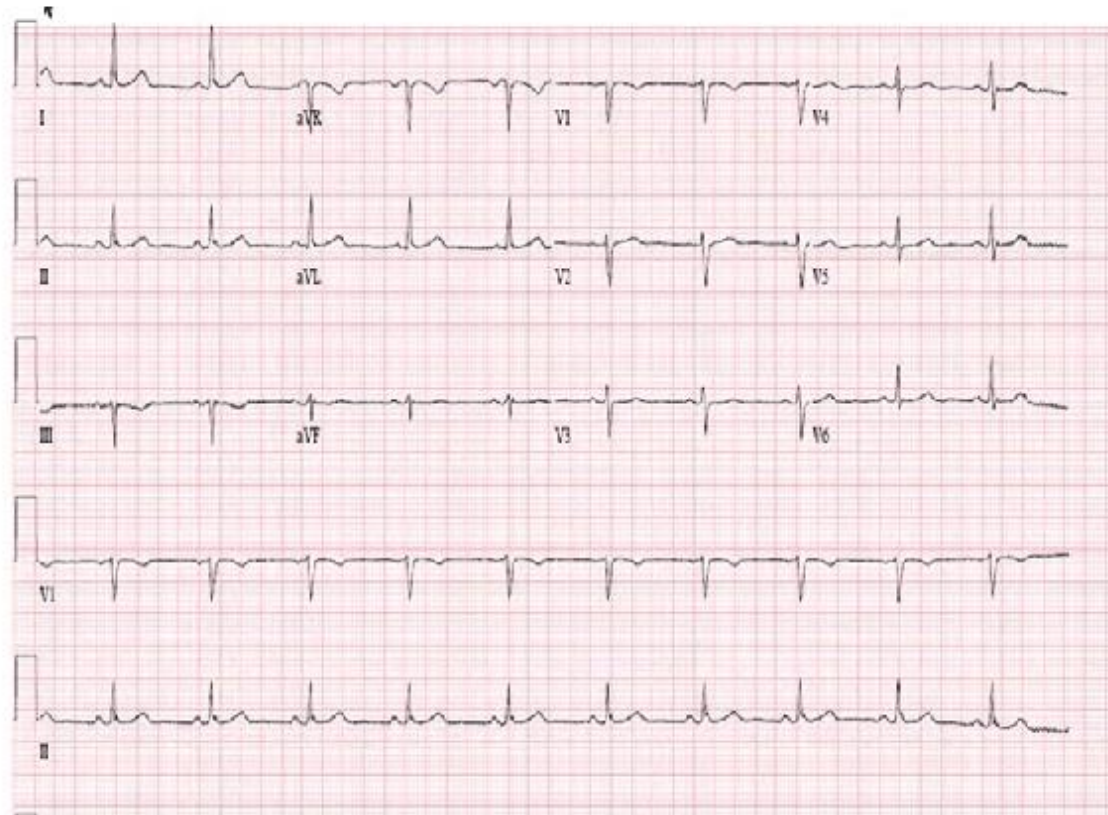
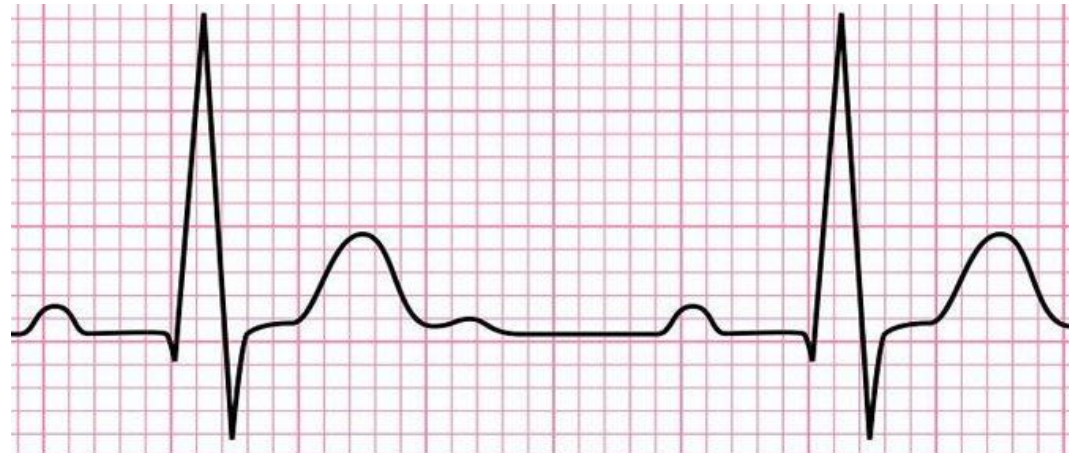


ECG: AN OVERVIEW

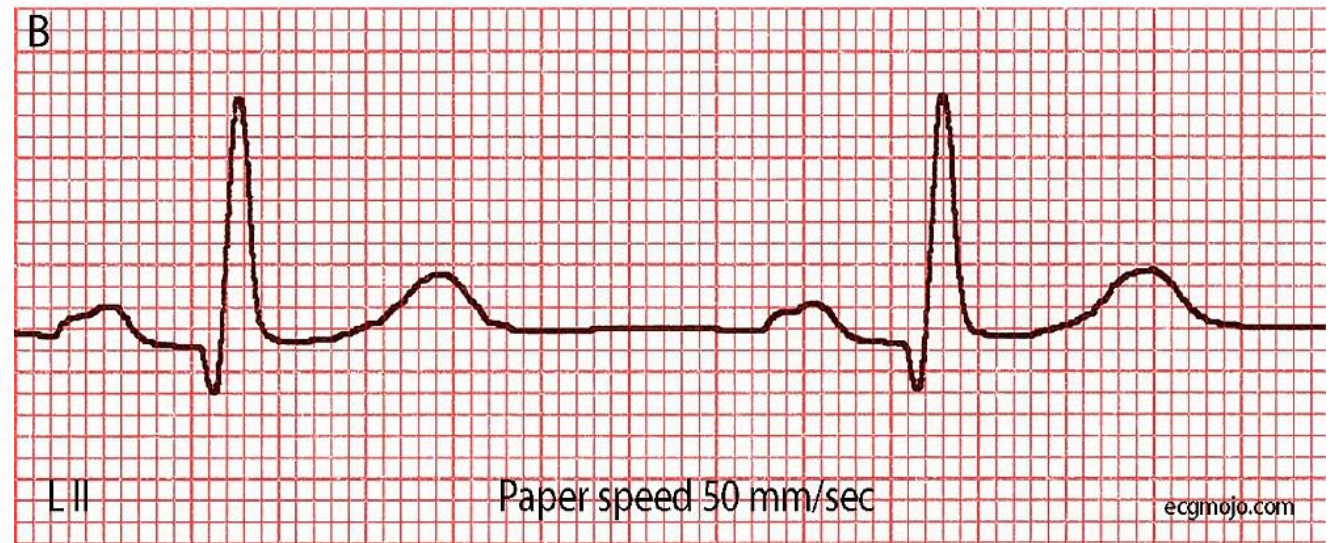
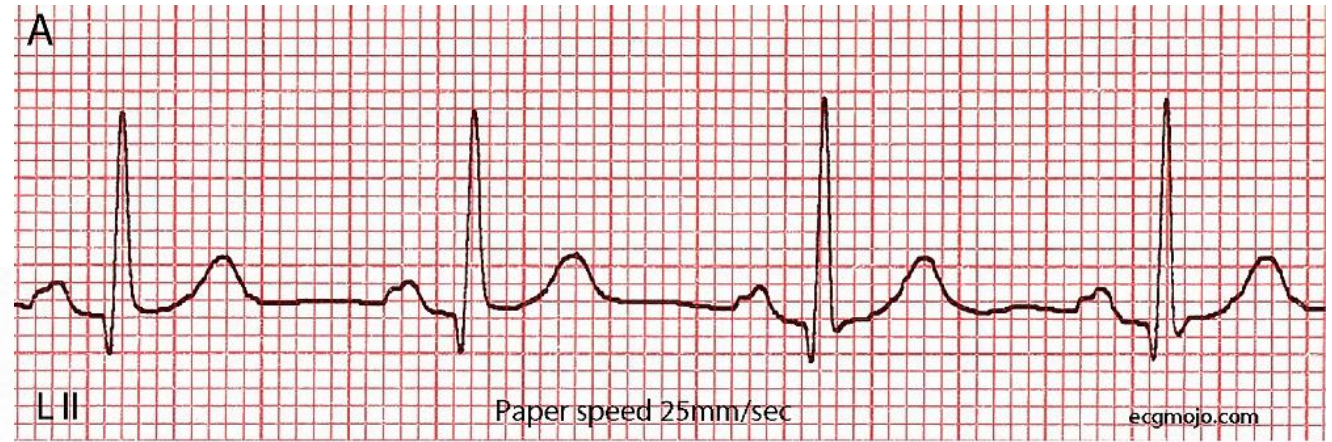
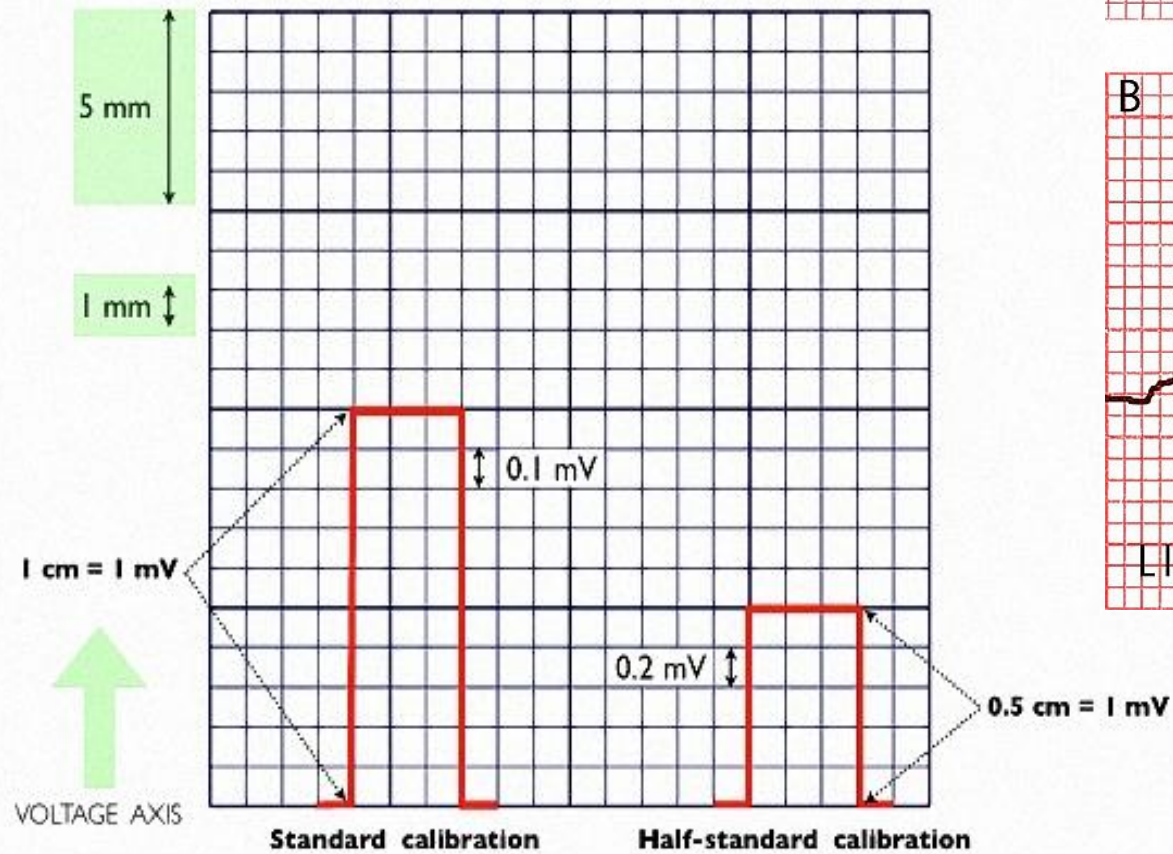
Sami Mukhlif Al-obaigy

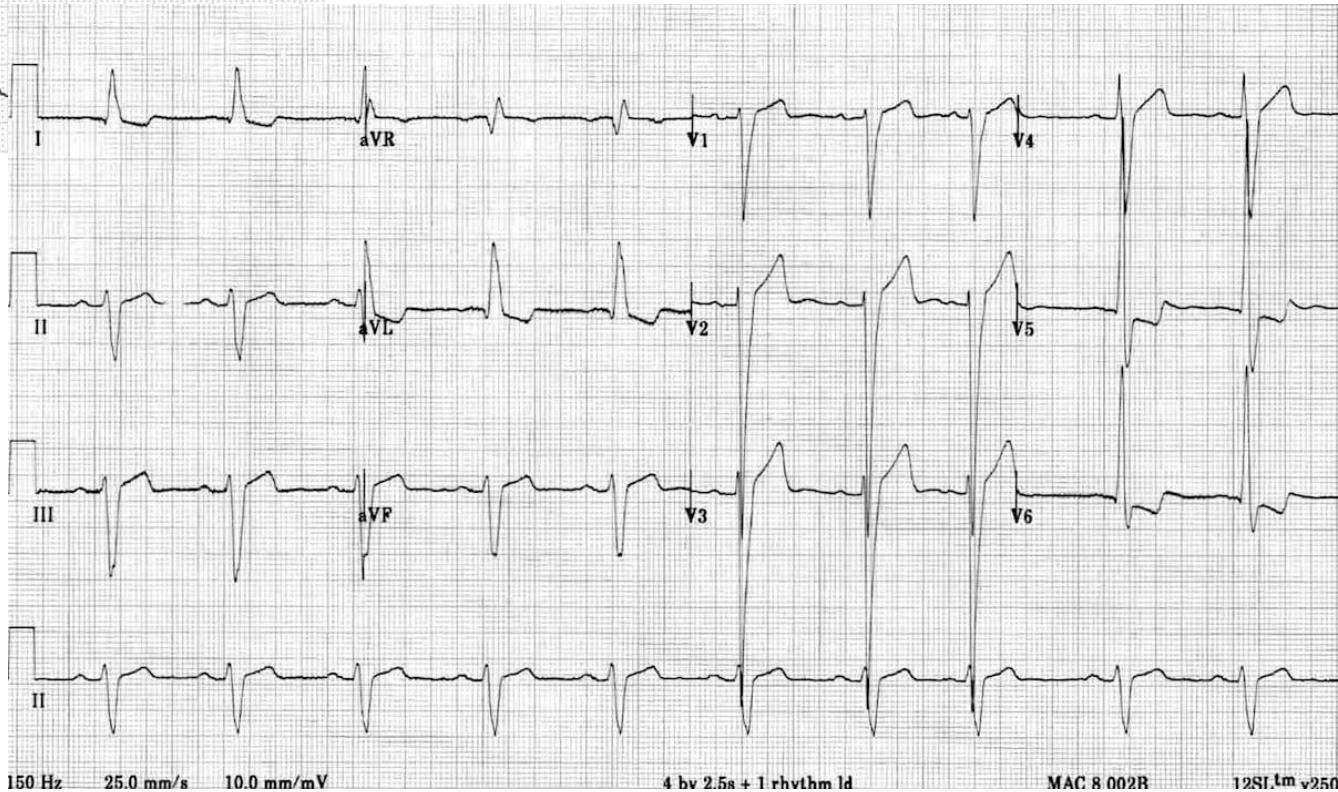
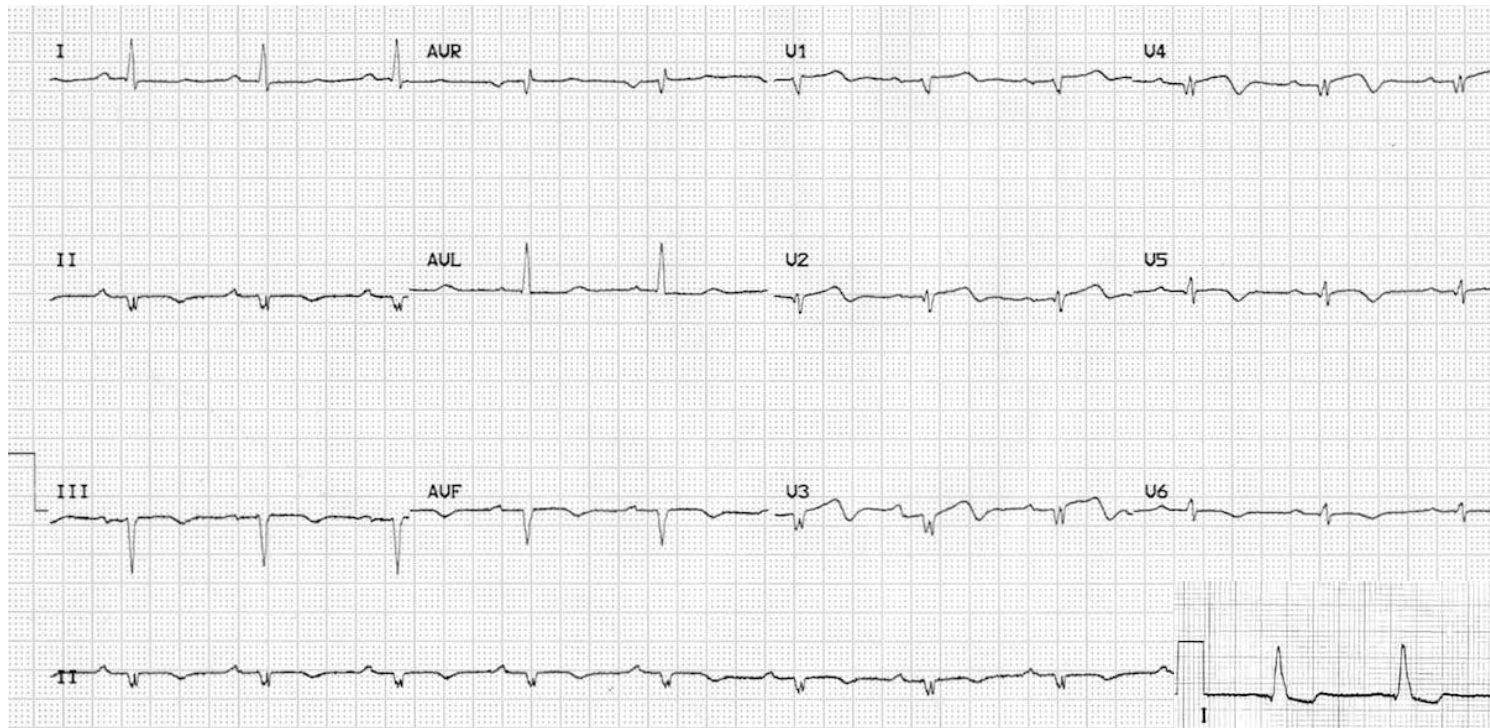
**FIBMS Cardiol, FIBMS (Med.), CABM (Med.), D.M. (Chest Diseases),
D.M.(Med.), MBChB, MESC**

NAME
DATE
CALIBRATION
CONNECTION
RHYTHM
RATE
AXIS
WAVES
P, Q, QRS, T, U
INTERVALS
PR, QT
SEGMENTS
PR, ST

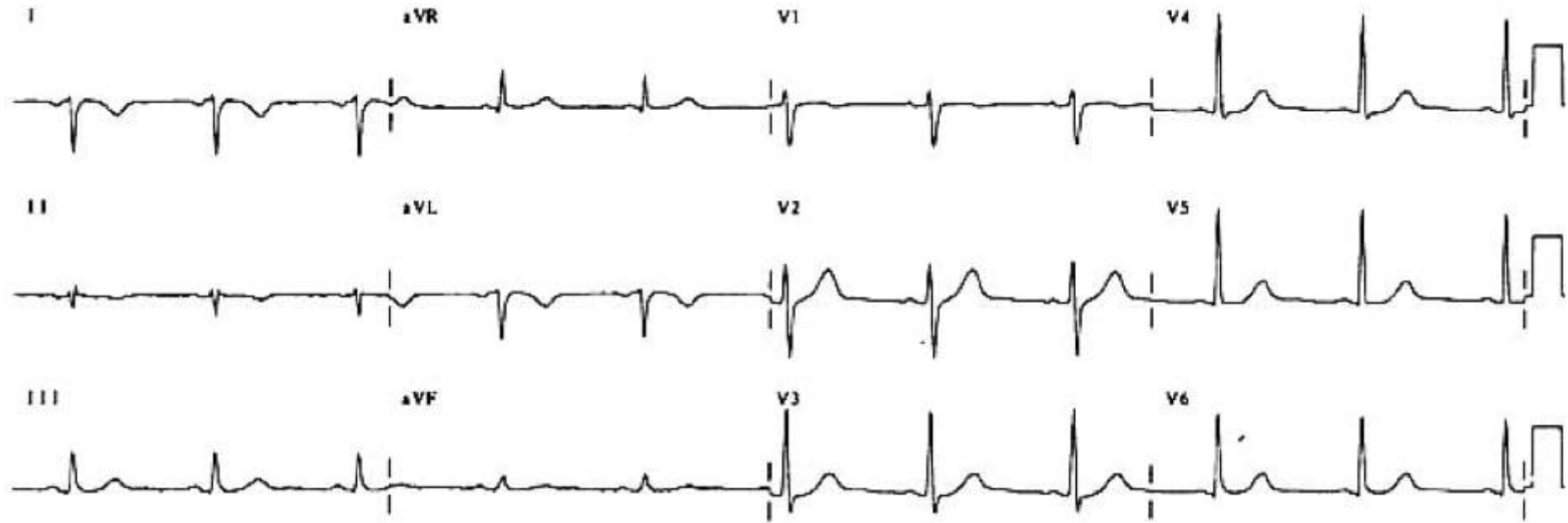


Calibration

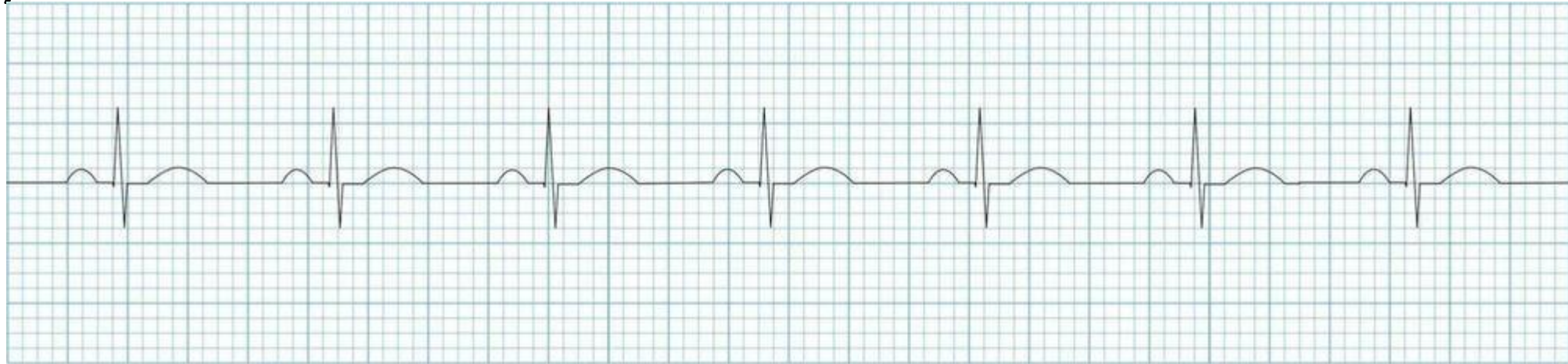




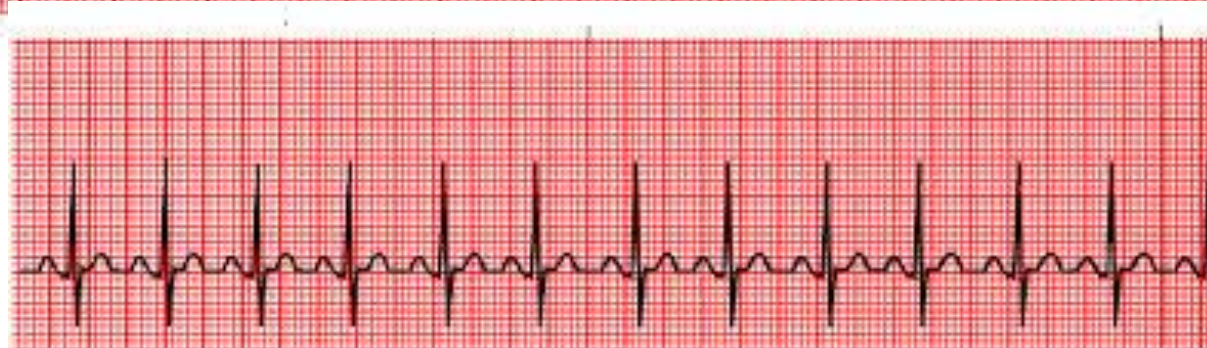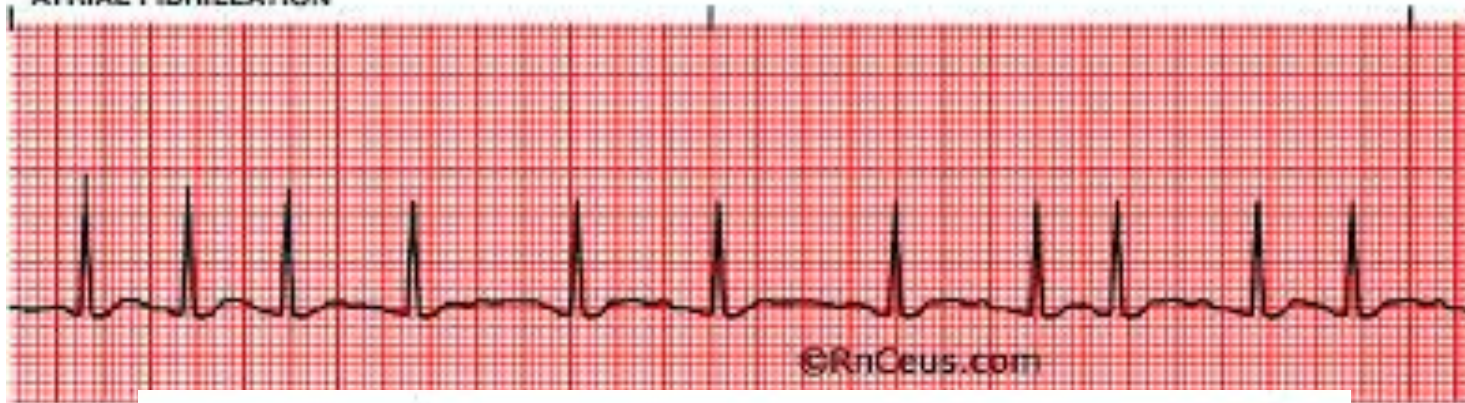
Connection



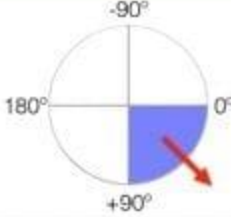
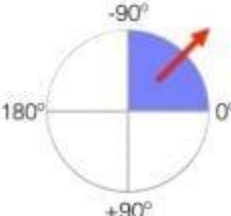
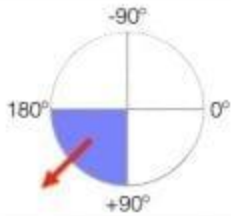

Rhythm and Rate

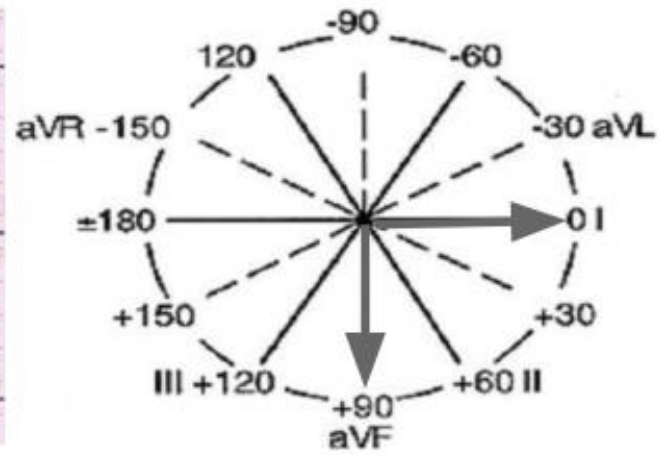
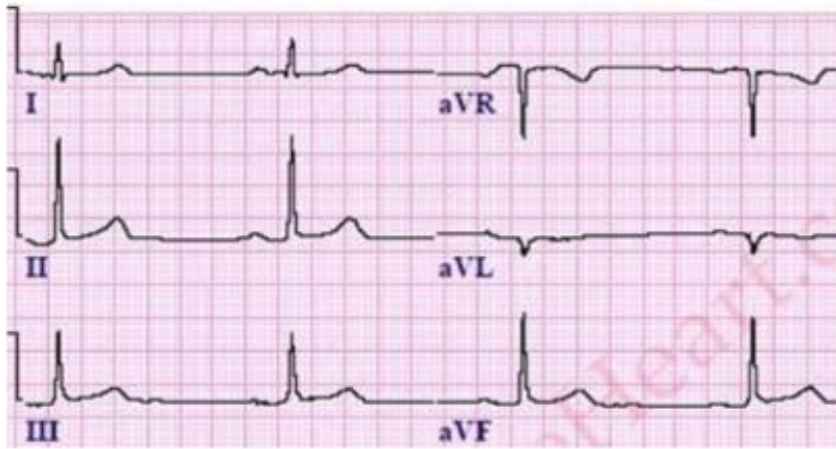


ATRIAL FIBRILLATION

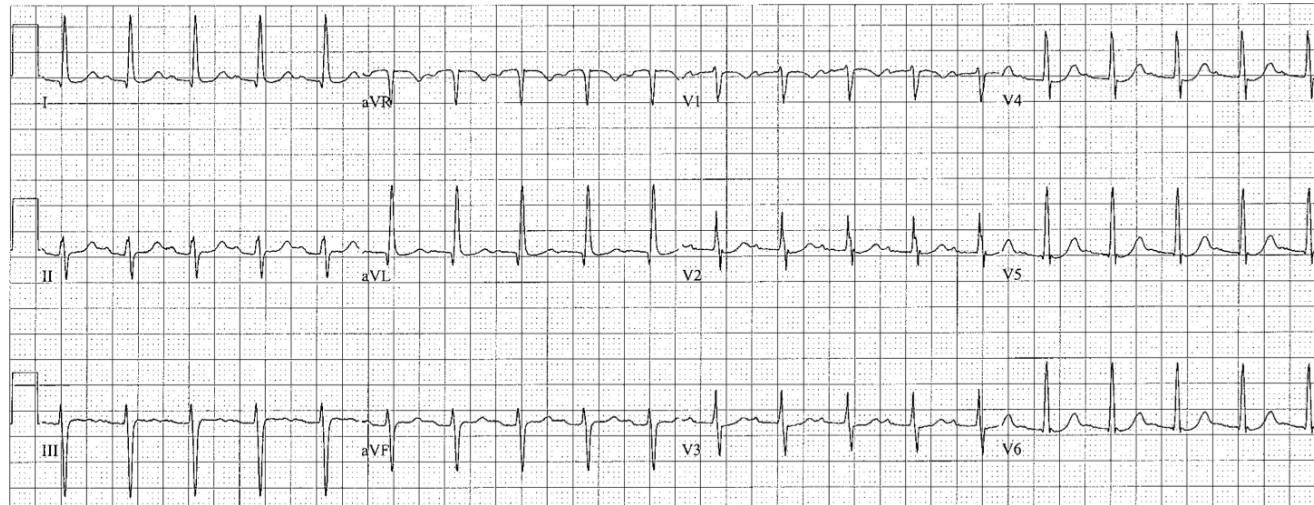


AXIS

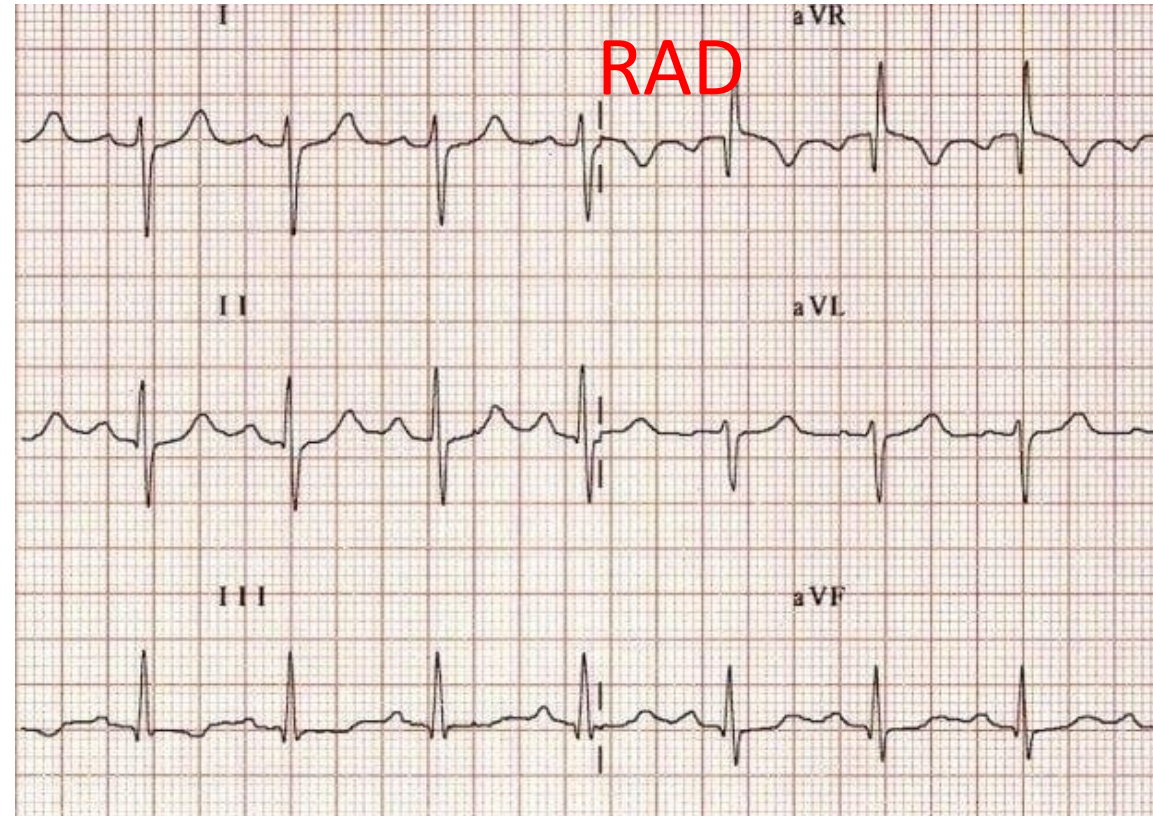
Lead 1	Lead aVF	Quadrant	Axis
POSITIVE	POSITIVE		Normal Axis (0 to +90°)
POSITIVE	NEGATIVE		**Possible LAD (0 to -90°)
NEGATIVE	POSITIVE		RAD (+90° to 180°)
NEGATIVE	NEGATIVE		Extreme Axis (-90° to 180°)

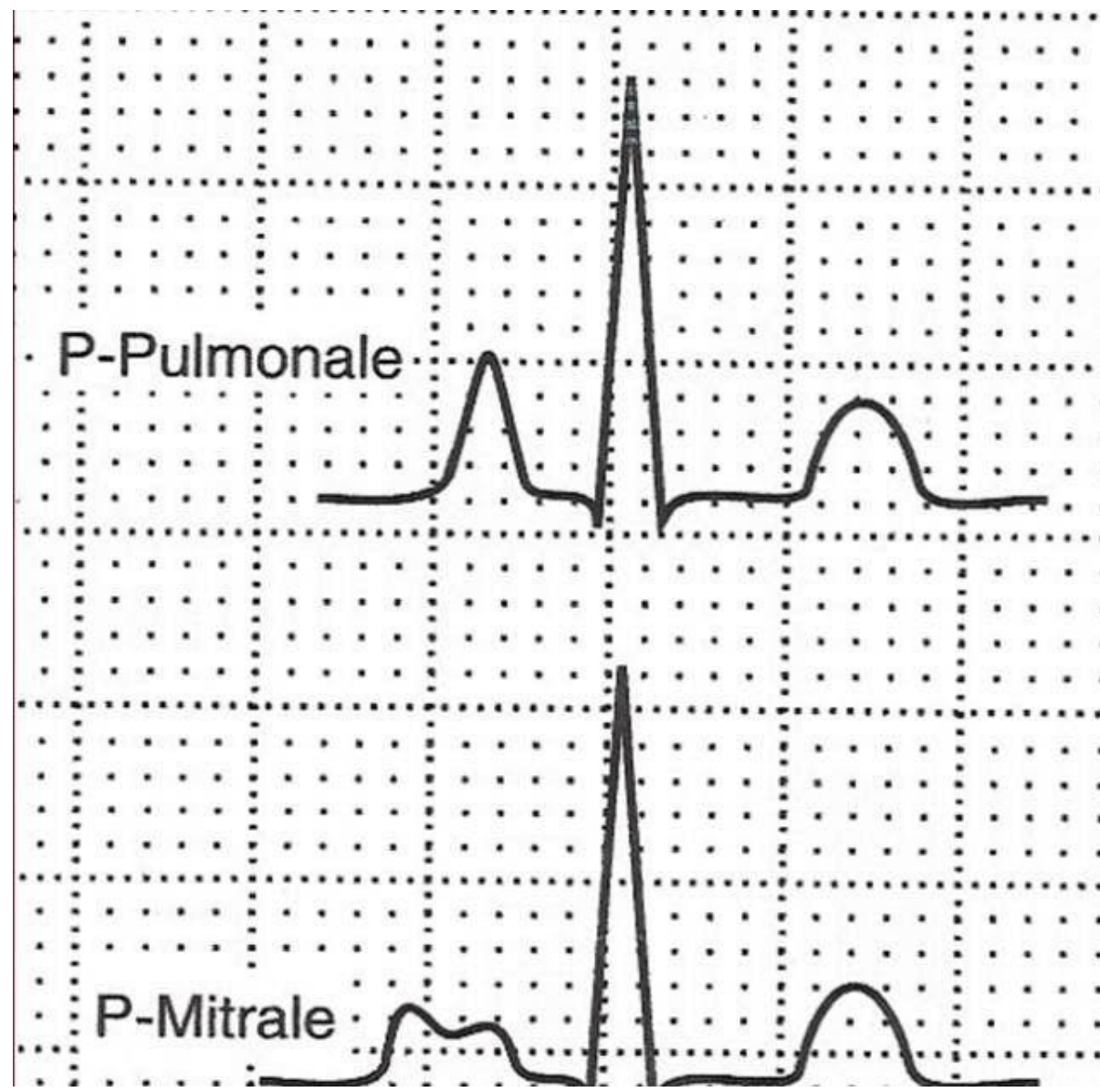


Normal QRS Axis: Positive in Lead I and aVF



LAD

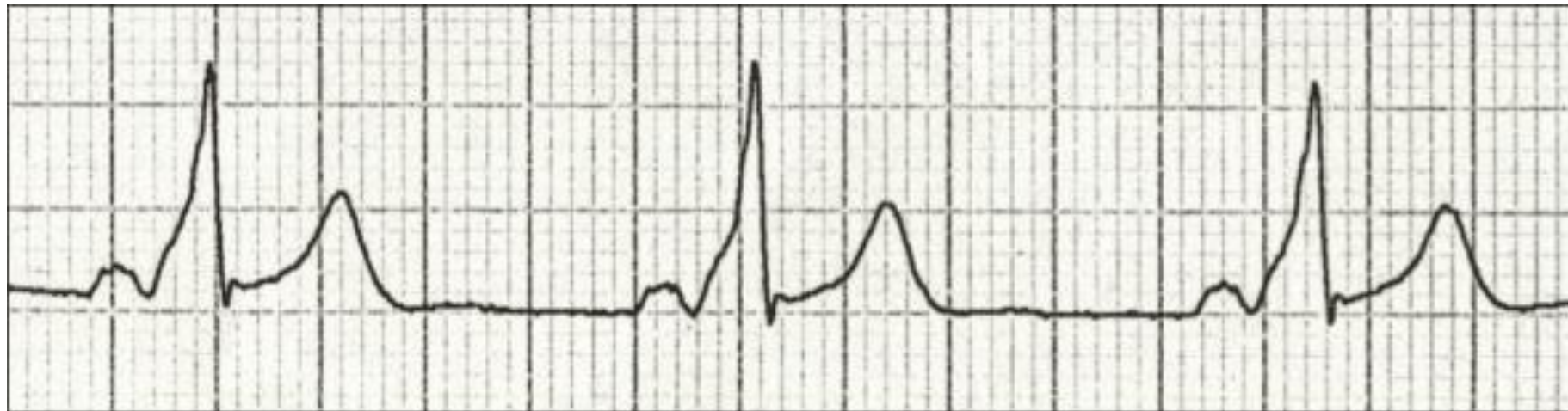
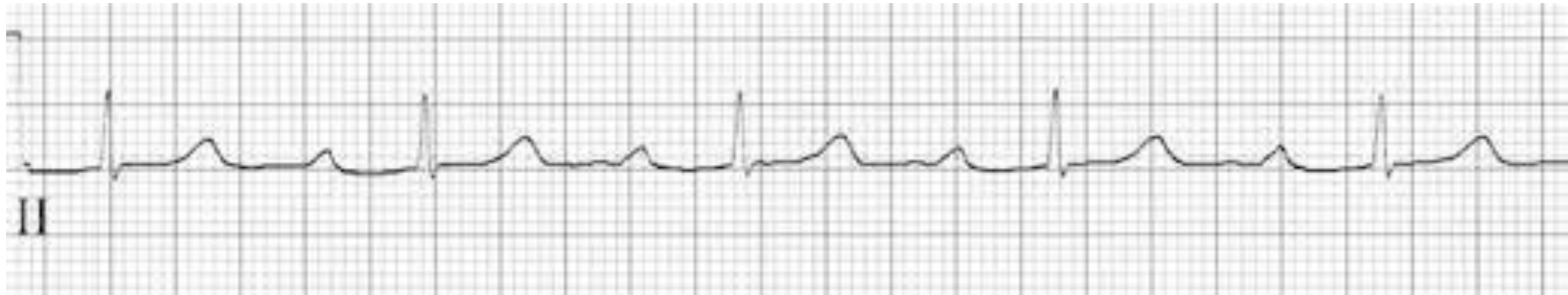



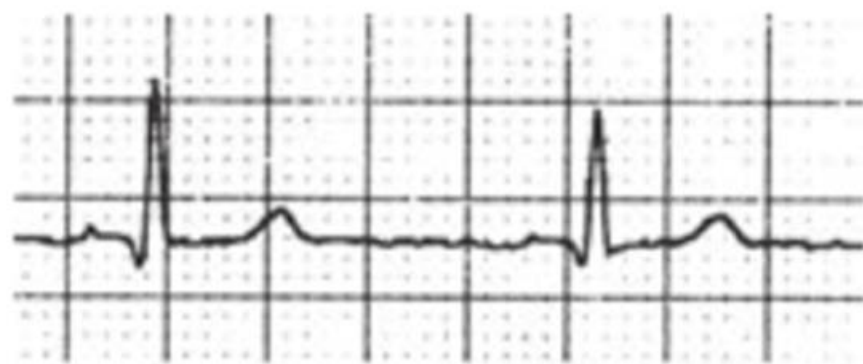P-Pulmonale

P-Mitrale

PR

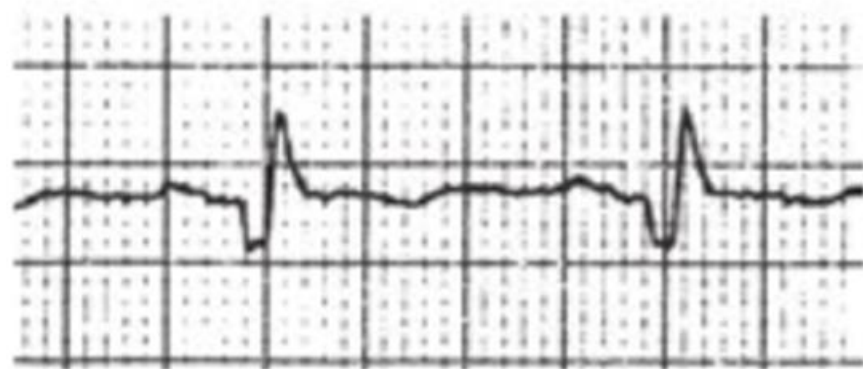

A



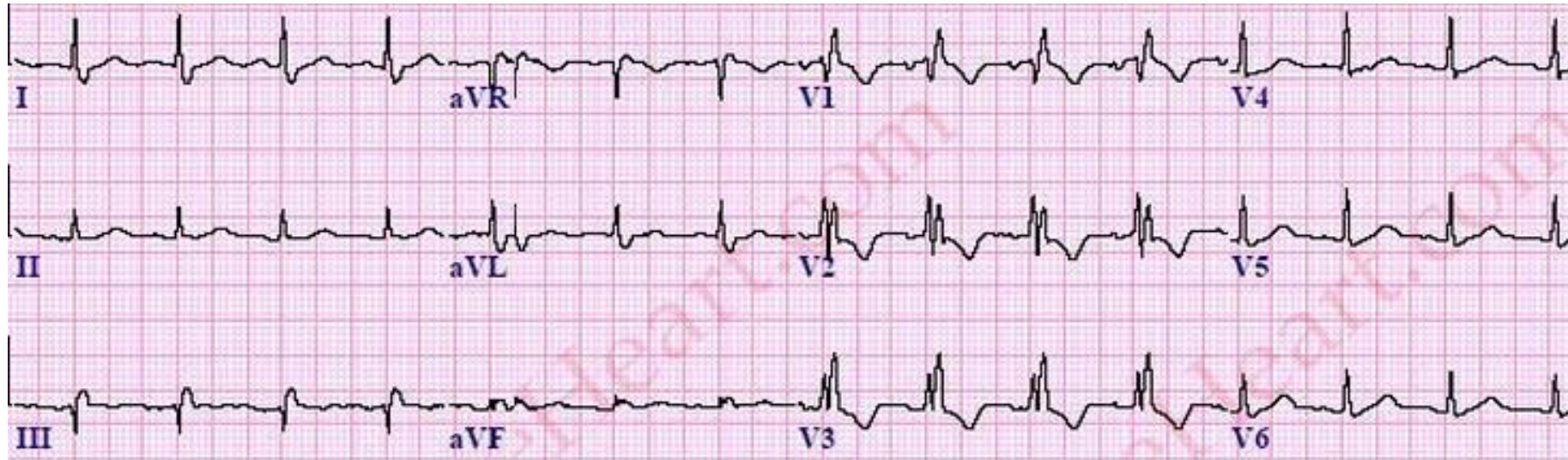
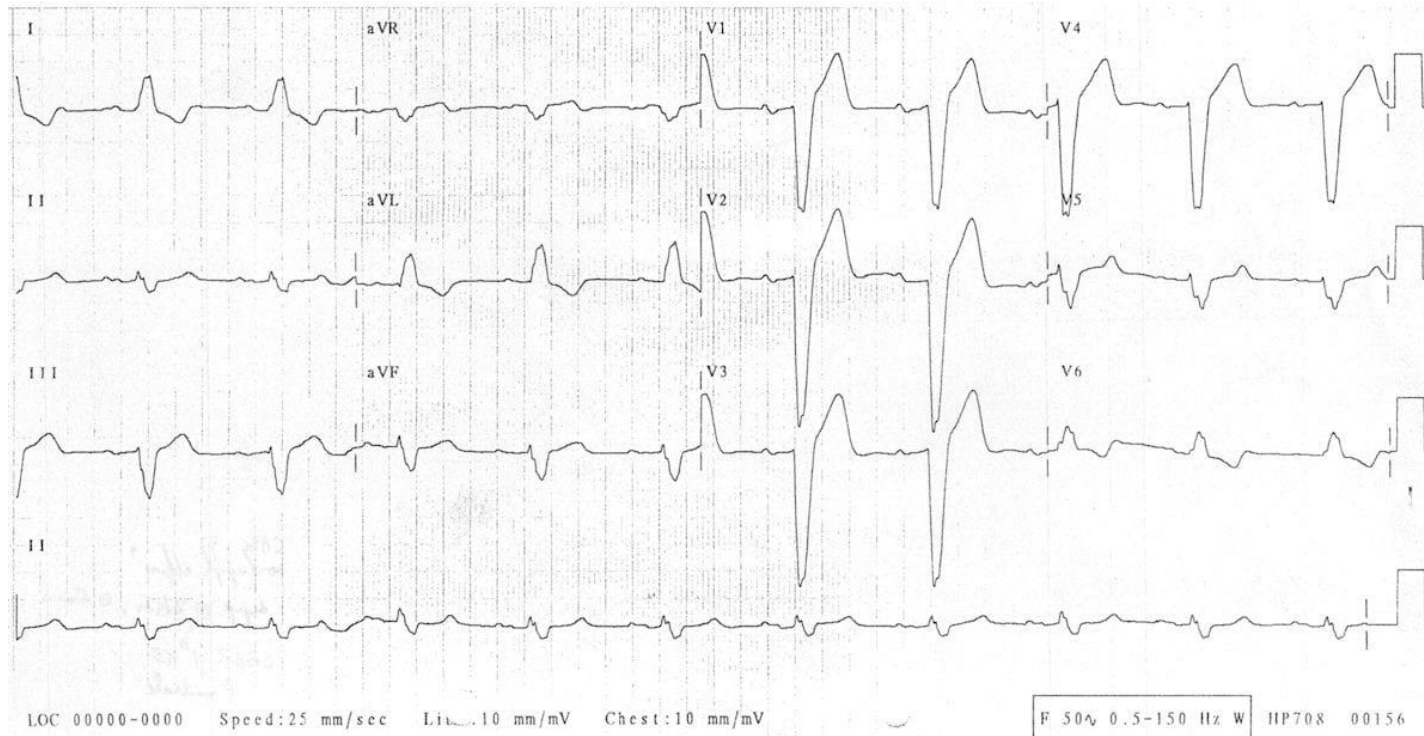
Normal Q Waves

B

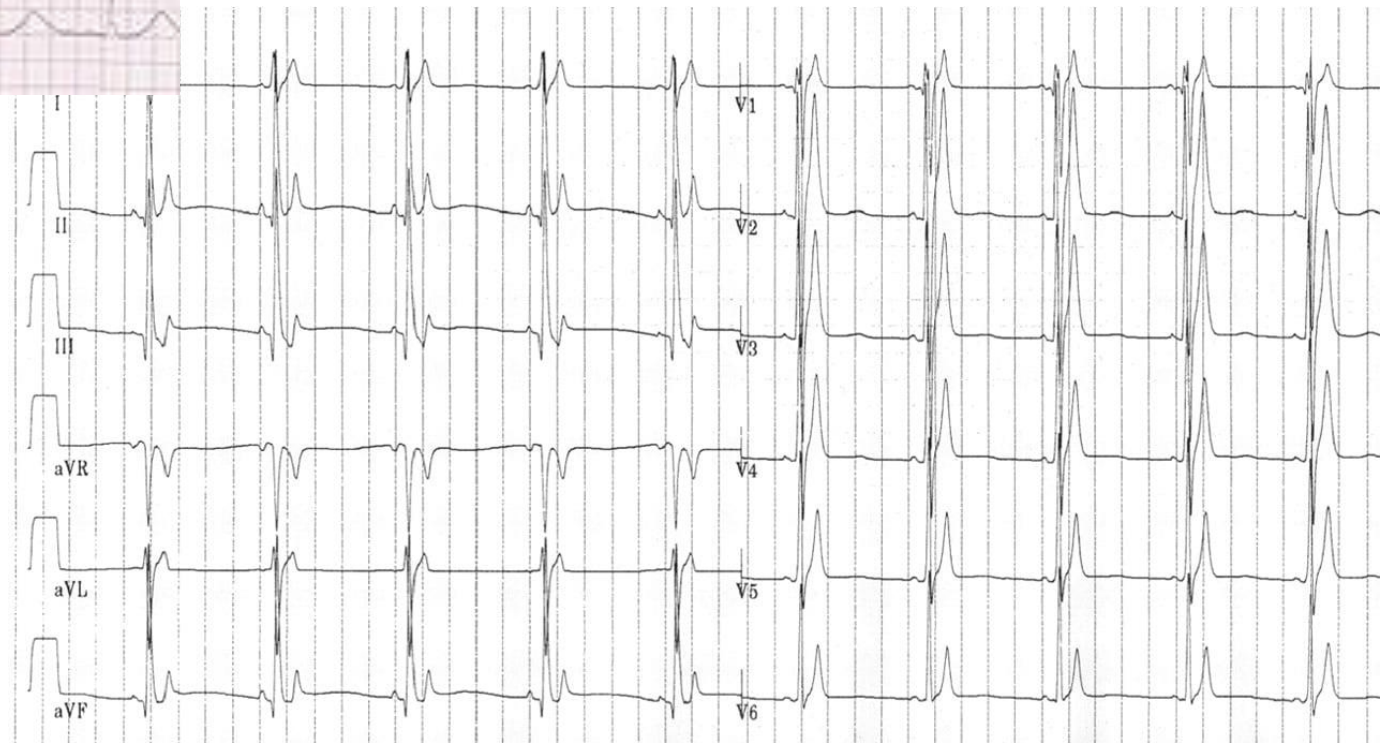
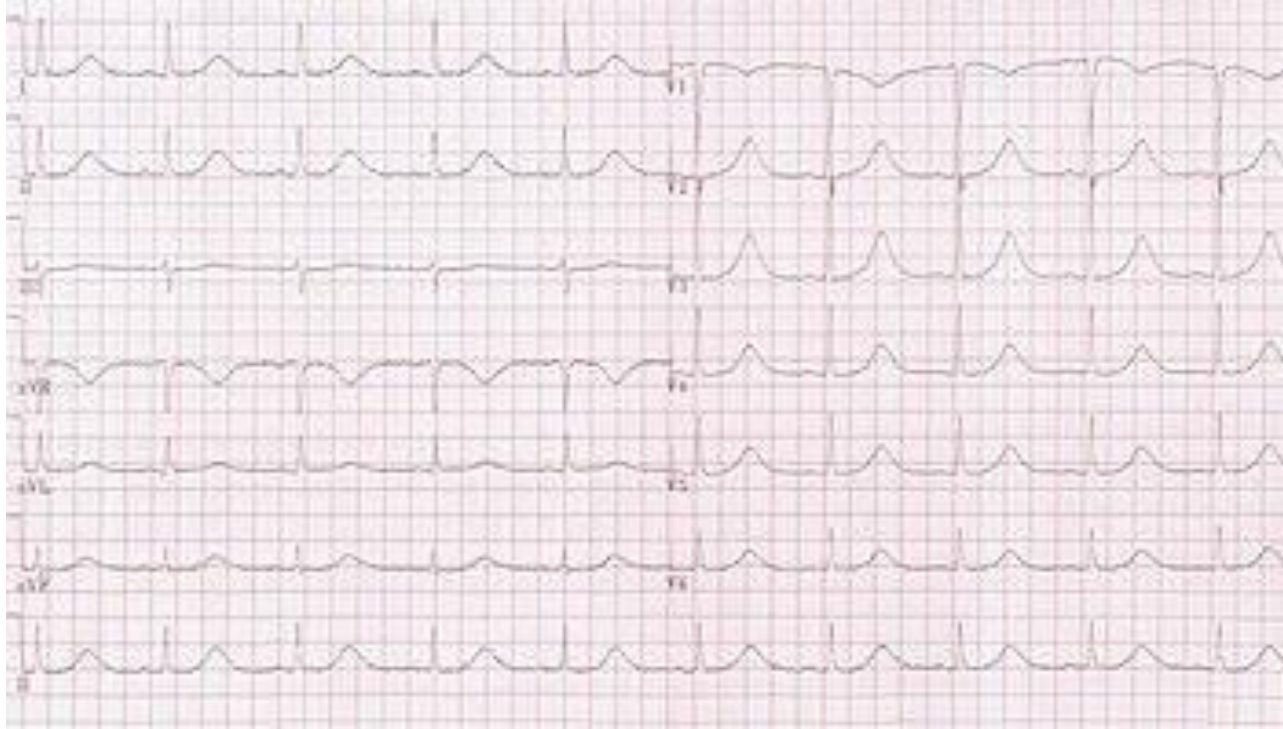

Pathologic Q Waves

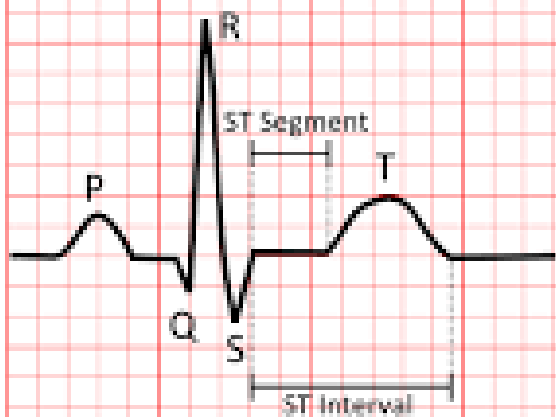
QRS



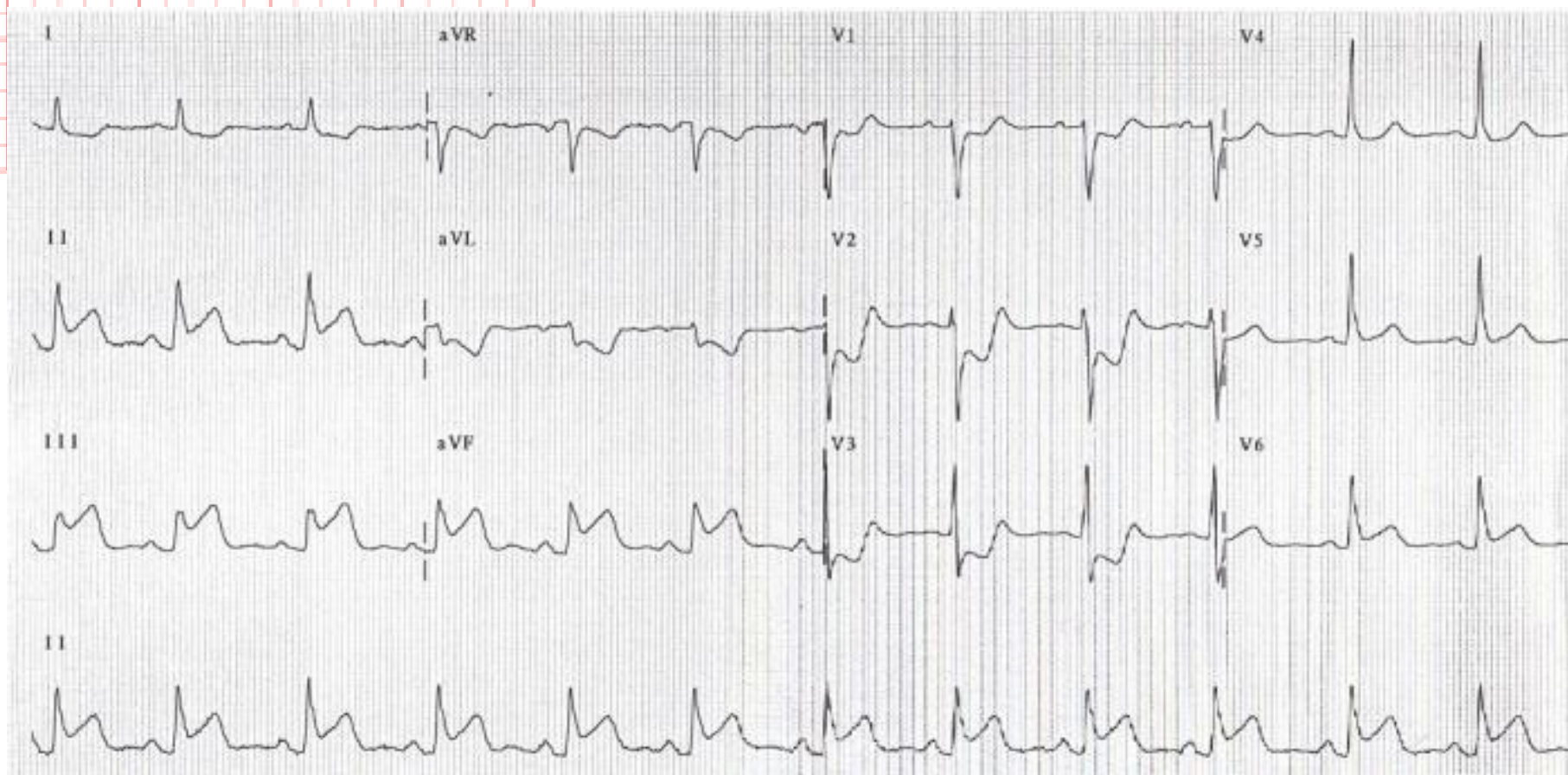
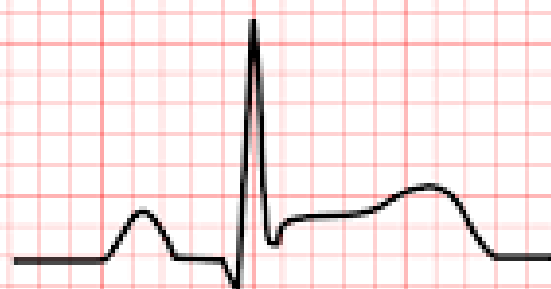QT INTERVAL

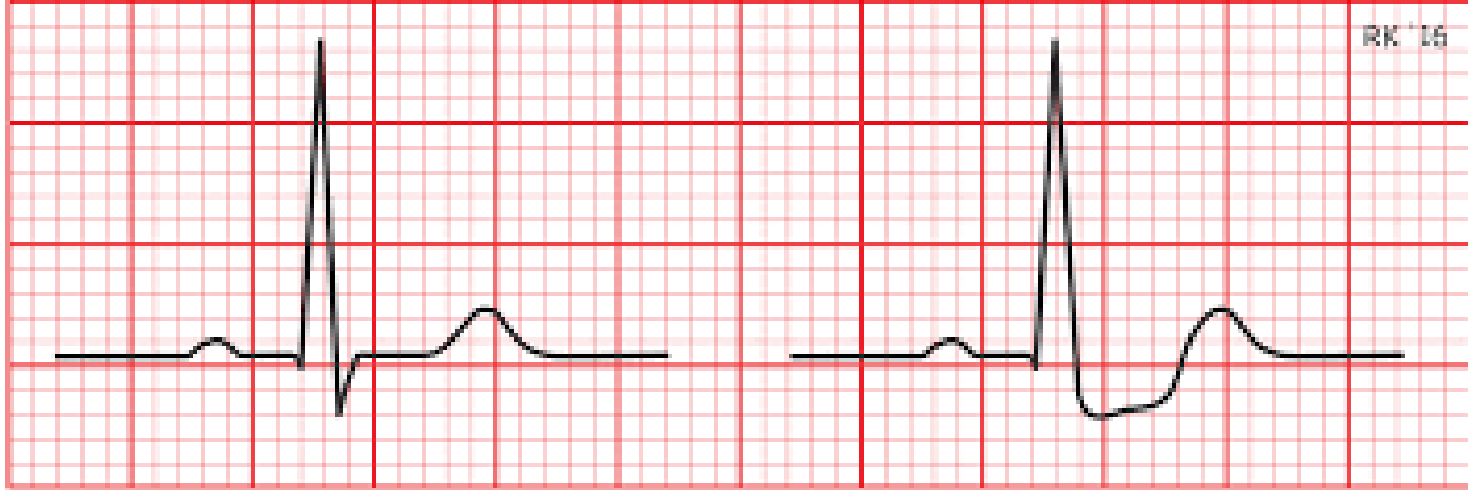


Normal



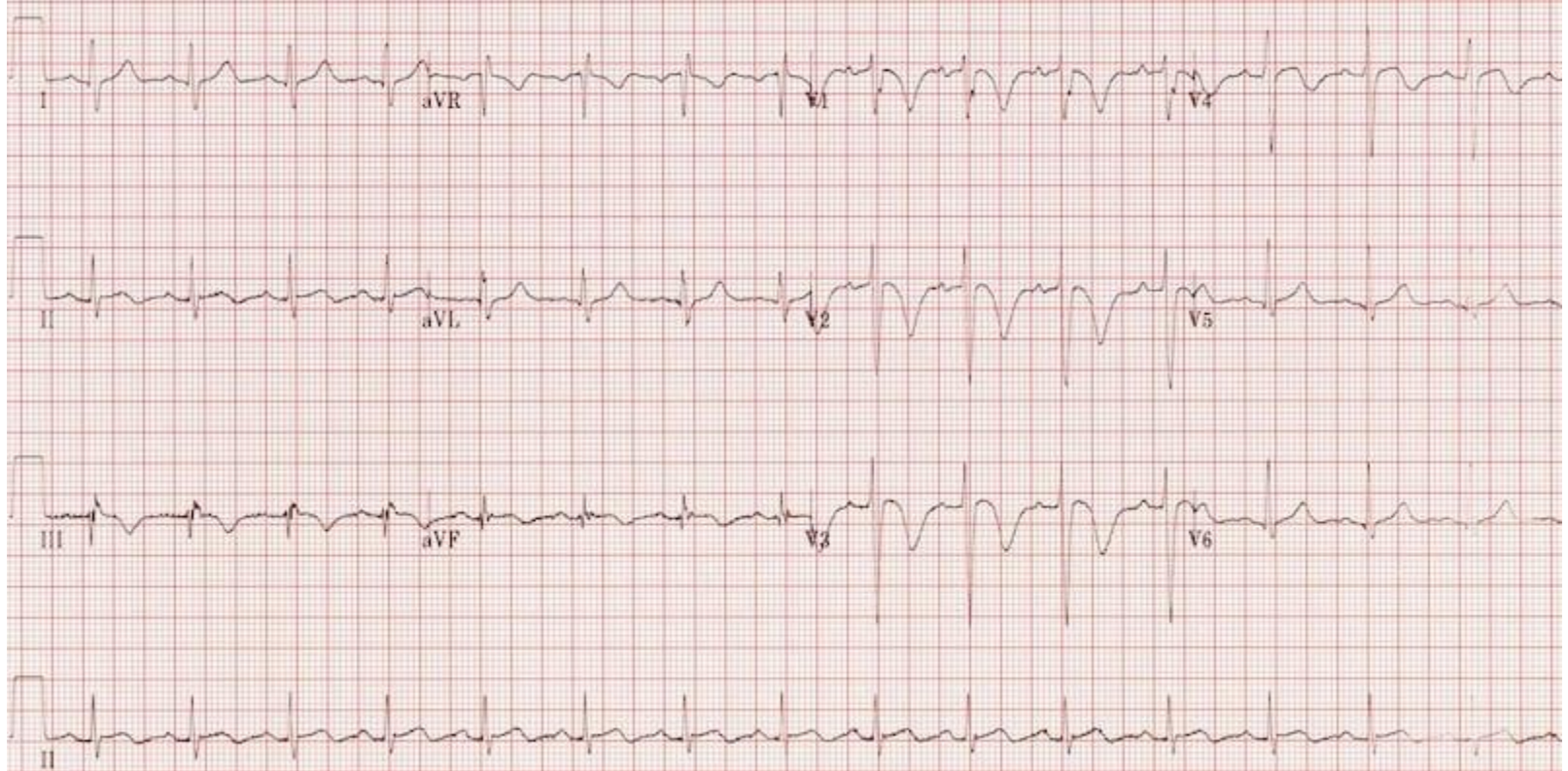
ST elevation

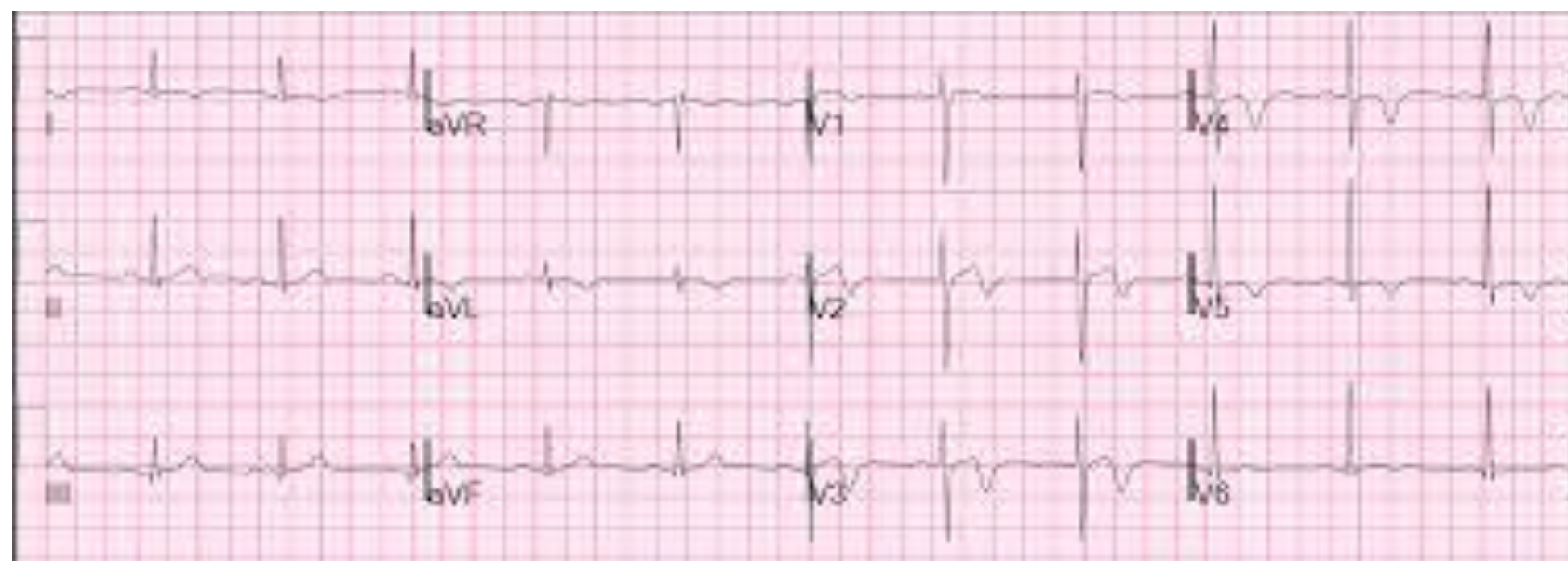



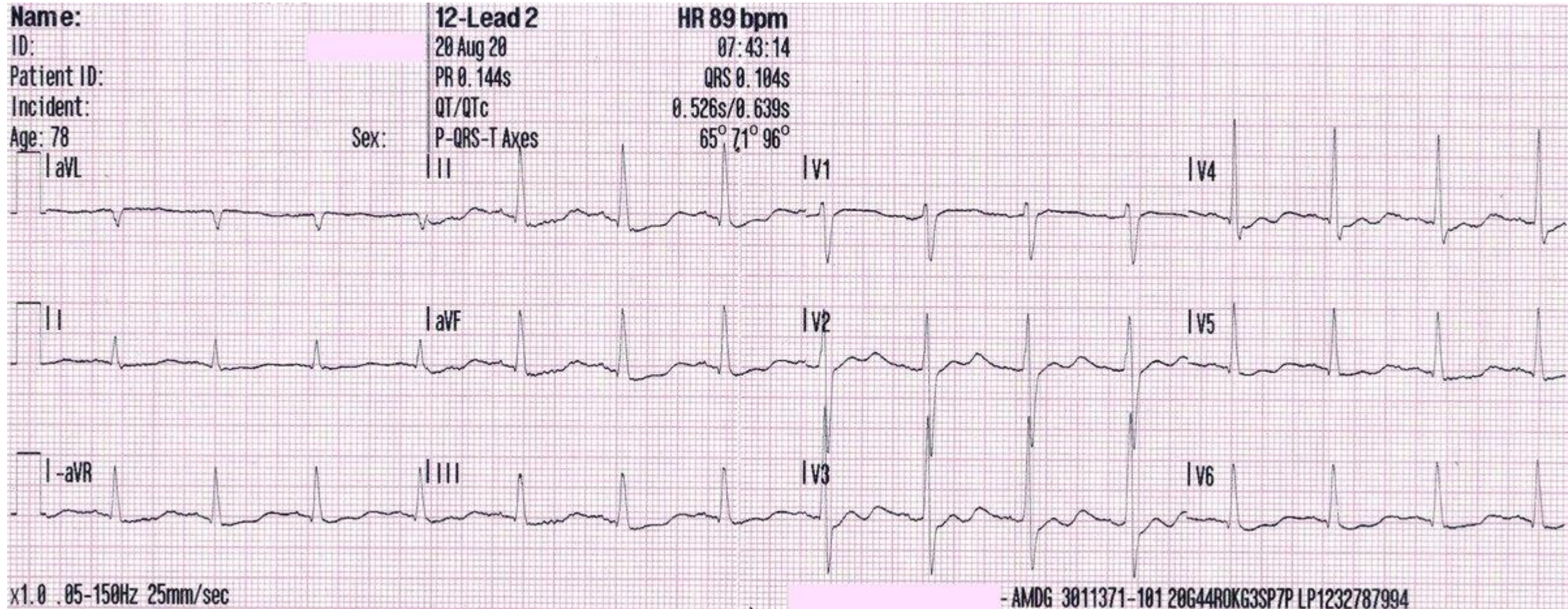
Normal

ST Depression





U wave



Thank you



Thank you