

Endodontic2019-2020

Lec.2

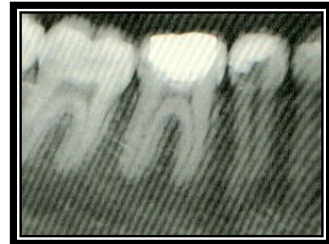د. اياد محمود عبد اللطيف

Endodontic radiography

Radiographs are essential to all phases of endodontic therapy. They inform the diagnosis and the various treatment phases and help evaluate the success or failure of treatment. Because root canal treatment relies on accurate radiographs, it's necessary to master radiographic techniques to achieve films of maximum diagnostic quality.

Requirements:

- 1) Radiograph: - should depict the tooth in the center of the films. Because the center of the films contains the least amount of distortion.
- 2) At least 3mm of bone must be visible beyond the apex of the tooth. Failure to capture this bony area may result in misdiagnosis or incorrect determination of file lengths for canal cleaning and shaping.
- 3) The image on the film must be as anatomically correct as possible, (no elongation or shortening).



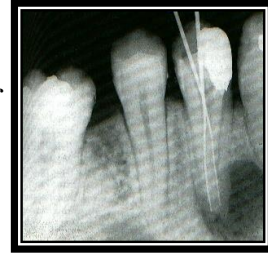
Importance of radiology in endodontics:

- Diagnosis
 - 1) Identifying pathosis
 - 2) Determining root/ pulpal anatomy
 - 3) Signs of additional canals
 - 4) Characterizing normal structures
- Treatment
 - 1) Determining working lengths
 - 2) Identifying/moving superimposed canals
 - 3) Locating canals
 - 4) Evaluating obturation
- Recall
 - 1) Evaluating healing
 - 2) Identifying new pathosis

Application of radiography to endodontics:

- 1) *Pre-endodontic diagnostic radiography:*
 - i) Aid in the diagnosis of hard tissue alterations of the teeth and periradicular structures.
 - ii) Determine the number, location, shape, size, and direction of roots and root canals

- iii) Localize hard-to-find or disclose unsuspected, pulp canals by examining the position of an instrument within the root.
- iv) Aid in locating a pulp that is markedly calcified and/or receded.
- 2) *Estimate and confirm the length of root canals before instrumentation.*
- 3) *Confirm the position and adaptation of primary filling point.*
- 4) *Aid in the evaluation of the final root canal filling.*
- 5) *Evaluate, in follow-up films, the outcome of endodontic treatment.*
- 6) *Endodontic surgery.*



- **SINUS TRACT TRACING:** - All sinus tracts should be traced, i.e. have gutta-percha inserted and radiographed.

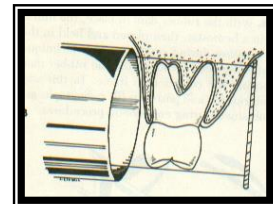
Film placement and cone angulation:

Paralleling technique:

For endodontic purposes, the paralleling technique produces the most accurate periradicular radiograph. Also known as the long cone or right-angle technique.

The film is placed parallel to the long axis of the teeth, and the central beam is directed at right angles to the film and aligned through the root apex. To achieve this parallel orientation, it's often necessary to position the film away from the tooth, toward the middle of the oral cavity, especially when the rubber dam clamp is in position.

The long-cone aiming device is used in the paralleling technique to increase the focal spot-to-object distance. This has the effect of directing only the most central and parallel rays of the beam to the film and teeth, reducing size distortion. This technique permits:




- 1- More accurate reproduction of the tooth's dimensions, thus enhancing a determination of the tooth's length and relationship to surrounding anatomic structure.
- 2- Reduce the possibility of superimposing the zygomatic processes over the apices of maxillary molars, which often occurs with more angulated films, such as those produced by means of the bisecting-angle technique.
- 3- It will provide the clinician with the films with the least distortion, minimal superimposition, and utmost clarity.

Bisecting-angle technique:

The bisecting-angle technique is not preferred for endodontic radiography, however, when a modified paralleling technique can not be used, there may be no choice because of difficult anatomic configurations or patient management problems.

The basis of this technique is to place the film directly against the teeth without deforming the film. The structure of the teeth, however, is such that with the film in this position there is an obvious angle between the plane of the film and the long axis of the teeth. This causes distortion because the tooth is not parallel to the film. If the x-ray beam will be shorter than the actual tooth. If the beam is directed perpendicularly to the long axis of the teeth, the image will be much longer than the tooth. Thus by directing the central beam perpendicular to an imaginary line that bisects the angle between tooth and film, the length of the tooth's image on the film should be the same as the actual length of the tooth.



Although the projected length of the tooth is correct, the image will show distortion because the film and the object are not parallel and the x-ray beam is not directed at right angles to both. This distortion increases along with the image toward its apical extent. The technique produces additional error potential because the clinician must imagine the line bisecting the angle. In addition to producing more frequent superimposition of the zygomatic arch over the apices of maxillary molars, the bisecting angle technique causes greater image distortion than the paralleling technique and makes it difficult for the operator to reproduce radiographs at similar angulations to assess healing after root canal treatment.

Comparison of techniques

<u>Paralleling</u>	<u>Bisecting-Angle</u>
Less comfortable film placement	More comfortable film placement
Less distortion	More distortion
More difficult with rubber dam in place	Easier with rubber dam in place
Easy to reproduce	Difficult to reproduce
Film holder required	Film holder sometimes required
Cone cuts are rare	Cone cuts more likely
Zygomatic arch usually above apices	Arch often superimposed

Film holder and aiming devices:

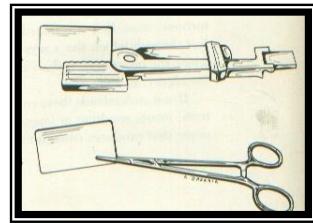
Film holder and aiming devices are required for the parallel technique because:

- 1) They reduce geometric distortion caused by misorientation of the film, central beam, and tooth.

- 2) They also minimize cone cutting.
- 3) Improve diagnostic quality.
- 4) Allow similarly angulated radiographs to be taken during treatment and at recall.
- 5) Eliminating the patient's finger from the x-ray field and thus the potential for displacing the film.
- 6) Help to minimize retakes and make it easier for the patient and clinician to properly position the film.

Types of film holder devices:


- 1- Hemostat: one of the most versatile film-holding devices, the operator positions a hemostat held film, and the handle is used to align the cone vertically and horizontally. The patient then holds the hemostat in the same position and the cone is positioned at a 90-degree angle to the film.



- 2- Green stabe: it's ideal for taking preoperative and postoperative films. It's a disposable film holder.



(2)




(4)




(7)

- 3- Dunvale Snapex system.
- 4- XCP: extension cone paralleling.
- 5- Endo Ray endodontic film holder.
- 6- Uni-Bite film holder.
- 7- Snap-A-Ray film holder.
- 8- Snap Ex system film holder.
- 9- Crawford film holder.



(8)



(9)

Generally, these holders all have an x-ray beam-guiding device (for proper beam to film relationship) and a modified bite block and film holder, for proper positioning over or around the rubber dam clamp.

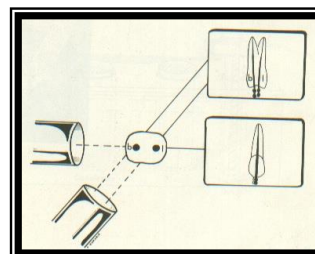
Buccal-object rule (cone shift):

In endodontic therapy, it's imperative that the clinician knows the spatial or buccolingual relation of an object within the tooth or alveolus. The technique used to identify the spatial relation of an object is called the cone or tube shift technique; other names for this procedure are the buccal-object rule, Clark's rule, and the SLOB (Same Lingual, Opposite Buccal) rule.

Proper application of the technique allows the dentist to locate:

- 1- Additional canals or roots.
- 2- Distinguish between objects that have been superimposed.
- 3- Distinguish between various types of resorption.
- 4- Determine the buccal-lingual position of fractures and perforative defects.
- 5- Locate foreign bodies.
- 6- Locate anatomic landmarks in relation to the root apex.

The principle states that the object closest to the buccal surface appears to move in the direction opposite the movement of the cone or tube head when compared with a second film. Are objects closest to the lingual surface appear to? Thus "same lingual, opposite buccal" rule.



Cone alignment for the various teeth in endodontics

Horizontal angulation

Right angle ("straight-on")

Maxillary anteriors

Maxillary molars

Mesial

Maxillary premolars

Mandibular premolars

Mandibular canines

Distal

Mandibular incisors

Mandibular molars

Maxillary molars (to display MB₂ canal, if present)

Vertical angulation

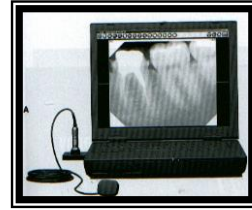
10° downward for mandibular premolars and molars

Digital radiography:

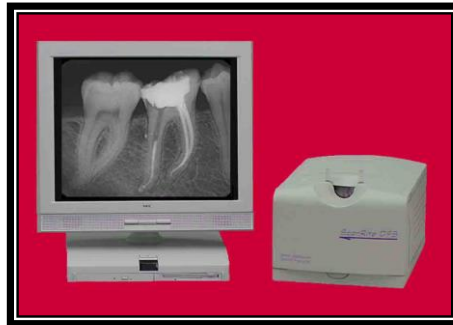As dentistry parallels photography, in the move from silver halide film to digital photography and computer processing, the profession will

undergo continued growth toward digital radiographic systems. Digital radiography used in dentistry is available in three variations:

- 1) Direct digital system: use a solid-state sensor such as a charge-coupled device (CCD), these systems have a cable that connects the sensor to the computer and in turn to screen monitor.



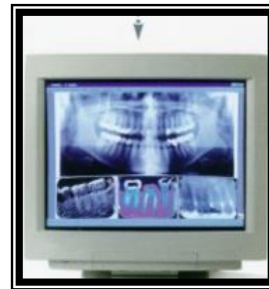- 2) Storage phosphor system: use a photo-stimulable phosphor plate that stores the latent image in the phosphor for subsequent readout by an extra-oral laser scanner.



- 3) Indirect digital system: use a scanning device connected to a computer for digitizing traditional silver halide dental films.

Advantage of digital radiography:

- 1) Image enhancement, contrast stretching and reversing.
- 2) Storage.
- 3) Retrieval.
- 4) Transmission of images to remote sites in a digital format.
- 5) Obtained immediately.
- 6) Radiation exposure is reduced from 50% to 90% compared with conventional film-based radiography.



Disadvantages:

- 1) High initial cost.
- 2) Reduction in image quality when compared with conventional radiography.

Direct digital systems have three components:

- 1) Radio component: consists of a high-resolution sensor with an active area that is similar in size to conventional film. The sensor is protected from x-ray degradation by a fiber-optic shield, and it can be cold sterilized. For infection control, disposable plastic sheaths are used to cover the sensor when it's in use.



- 2) Visio component: consists of a video monitor and display-processing unit. As the image is transmitted to the processing unit, it's digitized and stored by the computer.

- 3) Graphy component: high-resolution video printer that provides a hard copy of the screen image, using the same video signal.

