

ENDODONTICS

Lec.8

Apical third filling

The rationale behind root canal obturation has inclined toward mechanical rather than biological treatment.

It has been recognized for decades that the ideal end results of root canal therapy would be the closure of apical and all lateral foramina with reparative cementum. This permits re-establishment of a complete attachment apparatus and precludes future failure caused by pulpo-periodontal fluid exchange and retro invasion of bacteria.

The apical barrier must be biocompatible with tissues and ideally, should stimulate closure or sealing of the root canal at its most apical extent. The barrier should also have a good sealing ability and must provide a resistant wall against which filling materials can be compacted or condensed. Clinically, the intentionally placed apical barrier is designed to prevent the overextension toxic material into the periradicular tissues and to separate these toxic materials from contact with vital tissue.

Dentin chips apical:

As the quest for more biologically compatible materials continues, the interest in using dentin fillings placed as an interface between the periapical tissue and the endodontic filling material is continued. Dentinal plugs inadvertently formed, even when clinician was trying to avoid forming them, seemed to create an effective apical barrier against which healing could occur. Probably, some of the so-called “miraculous cures” occur periradicularly, to the prepared but unfilled canals, because the apical foramina have actually been obturated by dentin chips from the preparation.

After the canal is totally debrided and shaped, a Gates-Glidden drill or Hedstrom file is used to produce dentin powder in the central position of the canal. These dentin chips may then be pushed apically with the butt end and then the blunted tip of a paper point. They are finally packed into place at the apex using a pre-measured plugger or file one size larger than the last apical enlarging instrument. One to two millimeters of chips should block the apical foramen. Completeness of density is tested by resistance to perforation by a No. 15 or 20 file. Finally, the gutta-percha is then compacted against the plug. Care should be taken during plug production not to perforate or weaken the canal wall.

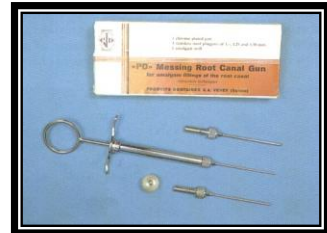Calcium hydroxide:

Calcium hydroxide $\text{Ca}(\text{OH})_2$ was first introduced by Hermann in 1930 as a pulp-capping agent. He demonstrated the ability of the pulp to build a dentinal bridge adjacent to calcium hydroxide as an apparent healing process. Today calcium hydroxide occupied a prominent position as a versatile medicament for use in endodontics.

Calcium hydroxide has been used in endodontics as a root canal filling material or as a sealant in conjunction with the solid core material.

The pure calcium hydroxide powder can be used with normal saline, methylcellulose, intracanal medicament or local anesthetic solutions. The pH of all these mixtures has been found to be similar to a range of 12.3-12.5. The exact mechanism of action of calcium hydroxide is unknown. Several factors have been suggested to be responsible for the action of calcium hydroxide. The hydroxyl group is considered the most important component as it provides an alkaline environment, which is antibacterial and induces superficial necrosis of adjacent tissue. This necrotic tissue seems to be the template upon which a calcified barrier is formed. The alkalinity of calcium hydroxide has also been suggested as promoting hard tissue formation by stimulation of enzymes such as alkaline phosphatase and inhibition of osteoclastic acid phosphatase.

Calcium hydroxide can be placed as an apical plug in either dry or moist state. Dry calcium hydroxide powder may be deposited in the coronal orifice from a sterilized amalgam carrier or endodontic messing gun. The bolus may then be forced apically with a pre-measured plugger and tapped to place with the last size apical file that was used.



Moist Calcium hydroxide can be placed in a number of ways: with amalgam carrier and plugger, with a lentulo spiral, or by injection from one of the commercial syringes loaded with calcium hydroxide like calacept.

Kerr and Madison reported that the placement of calcium hydroxide powder with messing gun had several advantages:

- Greater control in the placement of the powder, thereby minimizing undesirable overfills.
- Greater powder density in the canal thereby minimizing voids.
- Greater ease in preparation
- Greater ease in placement in a short period of time.

MTA: a new endodontic material

Introduction:

Mineral trioxide aggregate (MTA) is a material recently developed by Dr. Mahmoud Torabinejad at Loma Linda University School of Dentistry. MTA (contain trace amounts of SiO₂, CaO, MgO, K₂SO₄, and Na₂SO₄) is FDA approved and is commercially available as ProRoot MTA (Tulsa Dental Products, Tulsa, OK). The material has undergone extensive research for its sealing ability and biocompatibility. MTA can be used for vital pulp therapy, an apical barrier in teeth with open apices, repair of root perforation, root-end filing, coronal barrier prior to internal bleaching, and possibly other applications.

Composition and characteristics:

MTA is a powder composed of several mineral trioxides with bismuth oxide as the main radio-opaque. Hydration of MTA leads to a colloidal gel, which cures in approximately four hours. MTA has an initial pH of 10.2 that rises to 12.5 three hours after mixing. Its compressive strength is similar to that of super EBA(Super EBA is a reinforced zinc oxide cement based on a mixture of 32% eugenol and 68% ethoxy benzoic acid (EBA)) and IRM (IRM is zinc oxide-eugenol cement reinforced by addition of 20% polymethacrylate by weight to the powder) but it is more radio-opaque.

Biological and physical properties:

The ideal root filling and perforation repair material should provide a tight seal to prevent penetration of microorganisms and their byproducts into the periradicular tissue. The same properties are desirable for a pulp capping material to allow pulpal healing. Dyes, bacteria and their byproducts have been used to test the sealing ability of MTA. As a perforation repair material, MTA has been shown to have superior resistance to microleakage compared to IRM and amalgam. When used as a root-end filling material, studies showed that MTA provided a significantly better seal than IRM, amalgam, or super EBA.

Moisture contamination is always a concern when restorative materials are used for repair of root perforations or defects. In 1994, Torabinejad et al. conducted an in-vitro dye study of currently used root-end filling materials. They found that MTA sealed significantly better than Super EBA, IRM, or amalgam with or without blood contamination.

In-vivo and in-vitro tests have shown that MTA is biocompatible. When assessed for cytotoxicity in cell culture tests, MTA was found to be the least toxic in one cell-culture test and slightly more toxic than fresh

amalgam in another cell-culture technique. In vitro tests in guinea pigs, dogs, and monkeys have convincingly demonstrated that dentin forms against MTA in vital pulp applications and cementum forms adjacent to MTA when the material is placed in root perforations and in root-end preparations.

Preparation and mixing:

MTA is mixed with water in a 3:1 powder/water ratio to use. The consistency of the mix can easily be altered by either adding a little extra moisture or by wicking it away. Mixing is accomplished on either wax paper or glass slab using plastic or metal spatulas. During its placement, proper moisture and hemorrhage control is essential. In wet conditions, MTA can become too soft and unmanageable. It is hydrophilic and requires the presence of moisture to set. In cases of perforation or other intra-canal use, a moist cotton pellet, for a minimum of four hours, provides the needed moisture. When used as a root-end filling, interstitial tissue fluid from the periradicular tissues serves the same purpose.

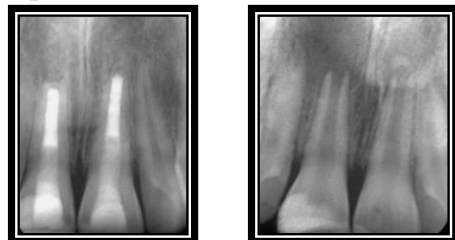
Clinical applications

Vital pulp therapy:

MTA can be used for vital pulp therapy in patients with traumatic crown fractures exposing vital pulp tissue, and in children with carious exposure of pulps in teeth with incompletely formed roots. In traumatic crown fractures, a shallow (partial) pulpotomy is performed in which MTA is placed directly against the pulp wound. In children with carious pulp exposure, usually in molars with incompletely formed roots, the coronal pulp tissue is removed, allowing placement of MTA against the pulp tissue at the floor of the pulp chamber. For the purpose of curing the MTA, moist cotton is placed against the material and covered with a temporary restoration. At a subsequent appointment, a definitive restoration can be placed directly against the cured MTA.

Apical barrier

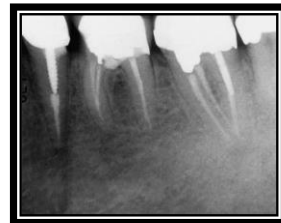
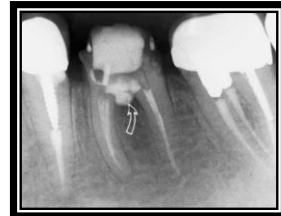
To obturate a root canal properly, an apical barrier is indicated in a tooth with an open apex. The root canal is cleaned, shaped and disinfected prior to MTA placement. A 3-4 mm plug of MTA is placed and packed into the apical root canal, and checked radiographically. If



short, the material can be condensed further apically to a more desirable position. After placement of MTA, the material must not be rinsed, as this will result in a washout. When the MTA is set, the remainder of the root canal can be filled using a sealer and gutta-percha or filled with composite bonded resin to strengthen the root canal walls in teeth with poorly developed roots. Healing of the periradicular tissues should be monitored periodically.

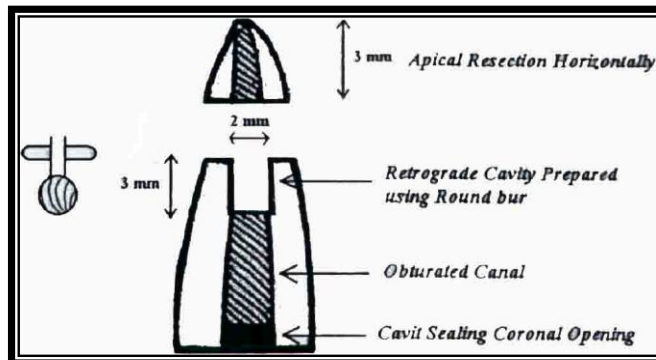
Perforations

For perforation, MTA is placed such that it seals the unwanted opening to the PDL space. For apical perforation, an MTA plug is placed as described in roots with open apices. After the MTA sets, the canal space coronal to the MTA is filled using the sealer and gutta percha. In coronal canal perforations, cleaning and shaping of the apical canal space should be completed first, followed by obturation apical to the perforation site. Subsequently, the perforation site can be repaired with MTA. In cases where the apical portion of the canal cannot be obturated with gutta-percha and sealer, the entire canal can be filled with MTA. Again, the permanent restoration is placed during a subsequent visit when the MTA has fully set.



Root end filling

When used as a root-end filling material, MTA is placed into the root end cavity preparation and the excess is removed with a small piece of moist gauze. Hemorrhage is then induced to fill the bony cavity surrounding the root apex, and the flap closed. A variation to this procedure may be followed: After completion of root-end filling procedures, the surgical wound should not be irrigated because unset MTA can be able washed out of the root-end cavity preparation. To prevent such washout and still be able to irrigate the wound, MTA can be temporarily covered with Zylactin (Zila Pharmaceuticals, Phoenix, AZ) and following



irrigation, the Zylactin can be removed with a cotton pellet saturated with 100% alcohol. The soft tissue is then repositioned and sutured. Periodic monitoring of the outcome is indicated as with all surgical procedures.

Limitations

Because MTA's compressive strength is similar to that of IRM or super EBA, it is not recommended as a permanent restorative material. When used for root end fillings, it is essential to keep the field of operation dry. If the area is too wet, the material becomes very soft and unmanageable.

Set MTA shows no signs of solubility in water; it is, however, readily recorded in an acidic environment. As acids can be generated by foods, beverages, and bacteria, MTA's exposure to the oral environment is contraindicated. Because of its gray color, surrounding dentin may appear dark; therefore, its use should be carefully considered in esthetic areas.

There are several treatment options for a necrotic or infected immature permanent tooth. Traditionally, the apexification procedure has been recommended for treating an immature tooth with an open apex.

Apexification is a procedure that promotes the formation of an apical barrier to prevent the extrusion of filling materials. The most critical drawback is the reduction in root strength due to the use of calcium hydroxide, and this increases the possibility of root fracture. Another drawback is the long time span of the entire treatment.

Regenerative endodontic treatment

Regenerative endodontic treatment is a treatment procedure designed to replace damaged pulp tissue with viable tissue which restores the normal function of the pulp-dentin structure. After regenerative endodontic treatment, continued root development and hard tissue deposition on the dentinal wall can occur under ideal circumstances.

Regenerative endodontic treatment has the advantages of further root development and reinforcement of dentinal walls by deposition of hard tissue, thus strengthening the root against fracture.

Current regimen of regenerative endodontic treatment procedures by American Association of Endodontics (AAE)

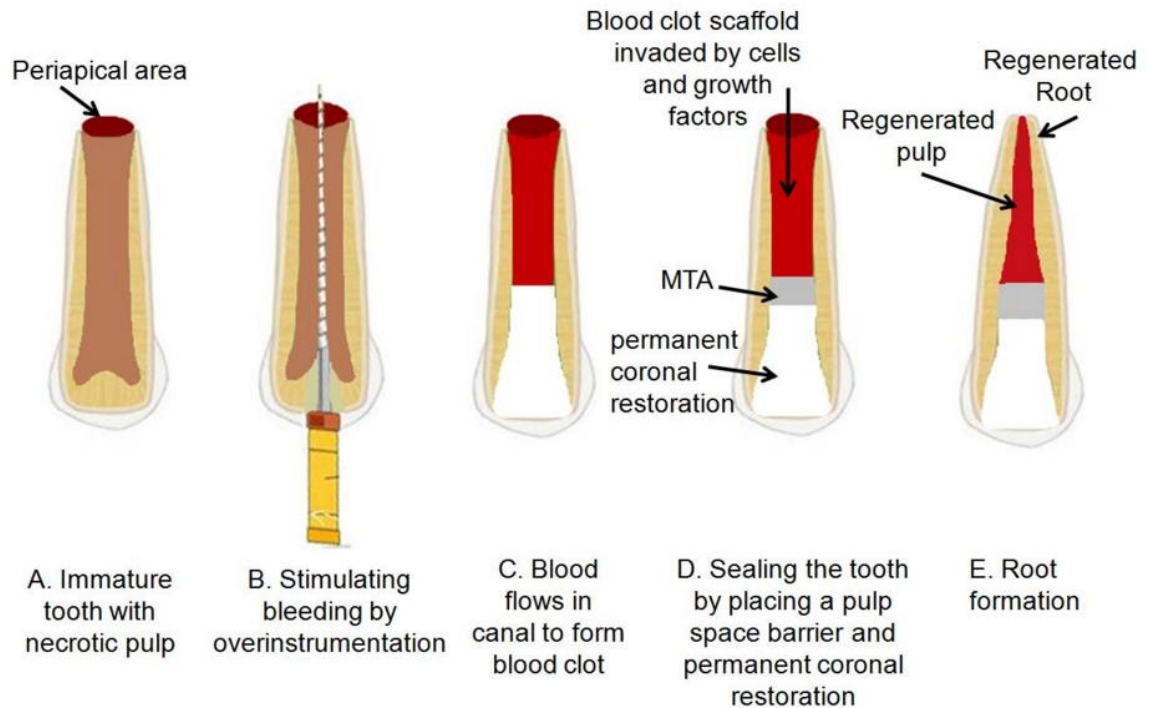
The tooth is anesthetized and isolated with a rubber dam for creating an access opening. Copious, gentle irrigation with 20 mL sodium hypochlorite (NaOCl) using an irrigation system that minimizes the possibility of extrusion of irrigants into the periapical space and lower

concentrations of NaOCl are advised to minimize cytotoxicity to stem cells in the apical tissues.

The root canal is then dried with sterile paper points, and the antimicrobial medicament is applied into the canal space. A triple antibiotic paste is applied to disinfect the canal space. The triple antibiotic paste has the advantage of being a very effective antibiotic combination against intracanal microorganisms. On the other hand, calcium hydroxide has the advantage of being widely available, but it may be cytotoxic to stem cells.

At the second appointment, the patient is evaluated for resolution of signs or symptoms of an acute infection. If there are no symptoms or signs of infection, it is appropriate to proceed with the next step of the regenerative endodontic treatment.

The tooth is irrigated with 20 mL of ethylenediaminetetraacetic acid, followed by normal saline, and the antimicrobial medicament is carefully removed. After drying the canal with a paper point, a file is placed a few millimeters beyond the apical foramen and bleeding is induced up to 3 mm from the cemento-enamel junction (CEJ). To position the mineral trioxide aggregate (MTA),



Colla-Plug, which serves as a resorbable matrix, is placed into the canal. Then about 3 mm of MTA is placed, followed by placement of the final restoration. A 12 to 18-month recall is probably the minimal time to judge radiographic evidence of root development and to conduct the clinical examination.