

Introduction

- Periodontal disease is an infectious disease process that involved by inflammation. It involves the structure of periodontium, causing a breakdown, resulting in loss of tissue attachment and destruction of the alveolar bone

Prevalence of periodontal disease

- Periodontal disease is leading to tooth loss in adults
- In the USA for example 75% of the population has different form of periodontal disease, and most of them are unaware of the disease
- Very high percentage of adults and children have calculus on their teeth
- Early detection and treatment of this disease can save the teeth for long life

Types of periodontal disease

Gingivitis: is a reversible inflammation of the gingival tissue, limited to epithelium and connective but not the alveolar bone. It is characterised by redness, swelling and tendency for bleeding.

- It is painless and often unrecognised until the dental professional emphasises its importance
- Can be improved by daily practice of proper oral hygiene

Gingivitis are also associated with:

Puberty, pregnancy and some medications

Periodontitis: inflammation of teeth supporting tissues, which extends from the gingiva into the connective tissue and the alveolar bone, leading to bone destruction and connective tissue loss.

Signs and symptoms of periodontal disease:

- Redness, swelling, bleeding on probing, brushing and flossing
- Loose and separating teeth
- Pain or pressure on chewing
- Pus discharge from the sulcus
- However, there is no sharp pain

Importance of periodontal disease diagnosis

- To determine the disease presence
- To identify its type
- Extension
- Severity
- Distribution
- Underlying pathological process

First visit

- Overall patient evaluation
- Medical history
- Dental history
- Radiographic survey whether peri-apical or OPG (orthopantomogram)

Overall patient evaluation

-Mental and emotional

Attitude

-Physiological age

Medical history

- Systemic diseases
- Conditions or behavioural factors may affect the periodontal disease
- Oral infection which may affect severity of some systemic disease
- It also includes:
 1. If the patient under medical care
 2. Hospitalisation
 3. Medications
 4. Medical problems
 5. Occupational disease
 6. Abnormal bleeding

Dental history

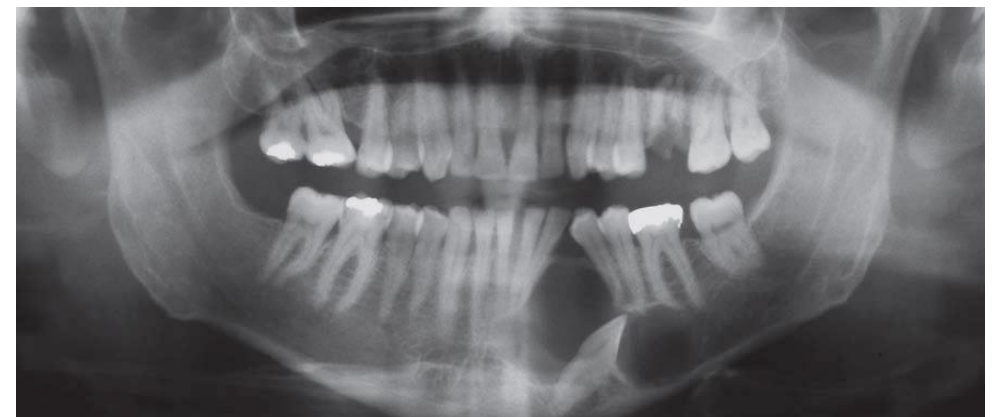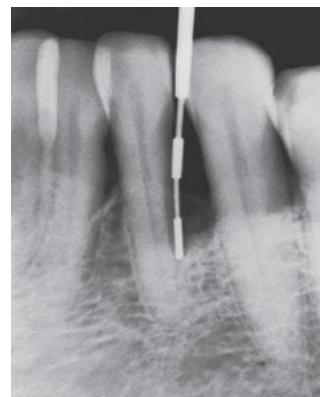
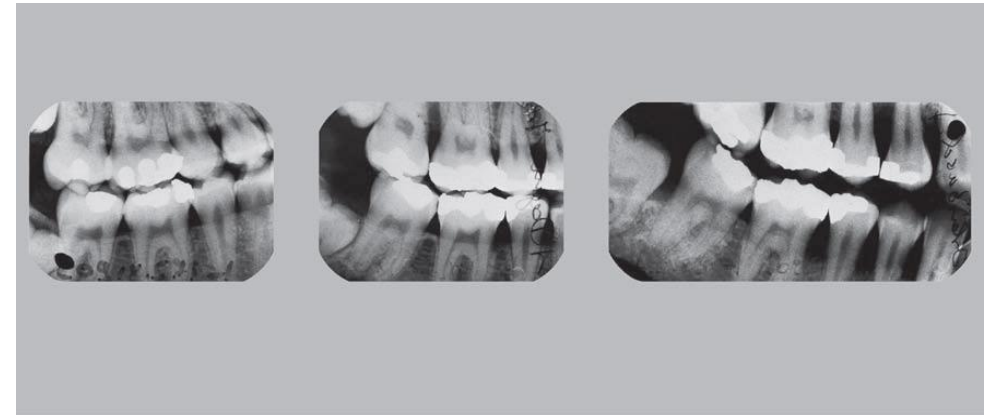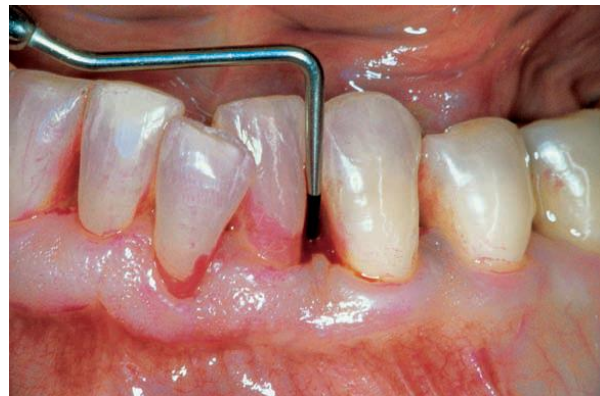- What is the current illness
- Dental history includes:
 - Dental visit
 - Oral hygiene
 - Orthodontic treatment
 - Pain
 - Bleeding gingiva
 - Teeth mobility
 - Dental habits
 - Previous history of periodontal problems

Intra-oral radiographic survey

-Peri-apical and posterior bitewing films

-Panoramic radiograph

Both are helpful in detection of developmental anomalies, pathological lesions of teeth and alveolar bone level.



Oral hygiene

- Plaque index (Silness and Loe)
- Disclosing agent
- Oral malodour: halitosis
- Plaque does not always relate to the severity of the disease as in aggressive periodontitis

Oral cavity Examination

-Examination of lip, floor of the mouth, tongue, palate and oropharyngeal region

Lymph node examination

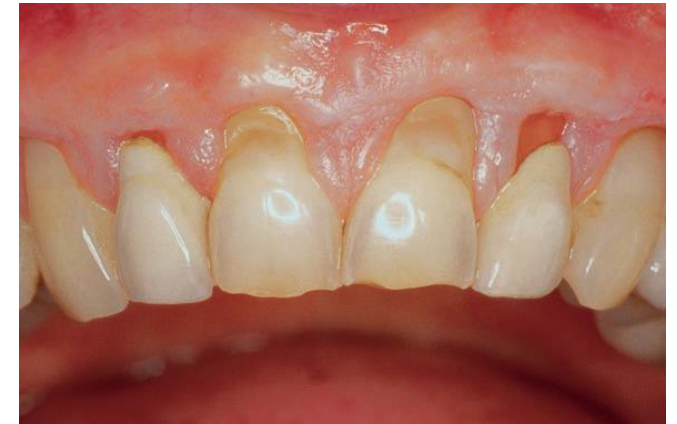-Whether enlarged, palpable, tender or immobile.

-Acute necrotising ulcerative gingivitis (ANUG), primary herpetic gingivostomatitis and acute periodontal abscess

Check for

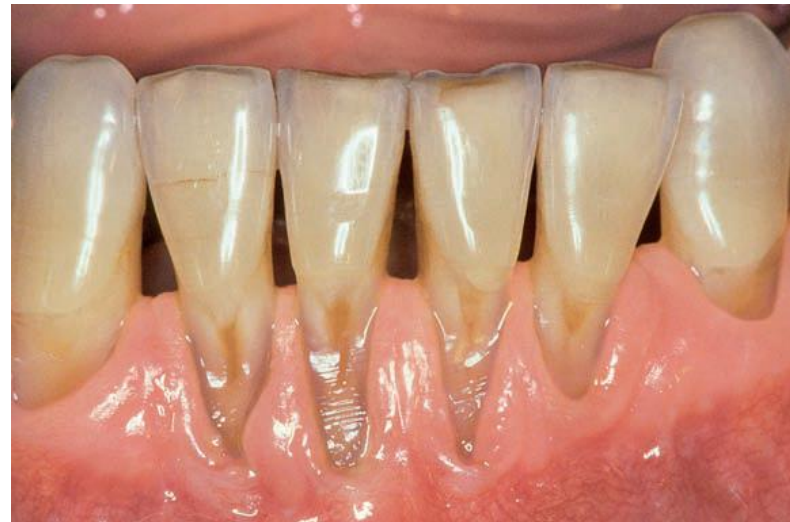Attrition: tooth to tooth functional contact, leading to occlusal wear and short crowns

Abfraction: occlusal loading surfaces causing mechanical microfractures and tooth substances loss at the cervical area



Abrasion: Saucer-Shaped defects due to mechanical effect of tooth brush, pipe smoking...etc

-Erosion: wedge-shaped defect on the cervical part of the enamel, dentine and cementum of teeth



Dental stain

- Pigmented deposits
- sources

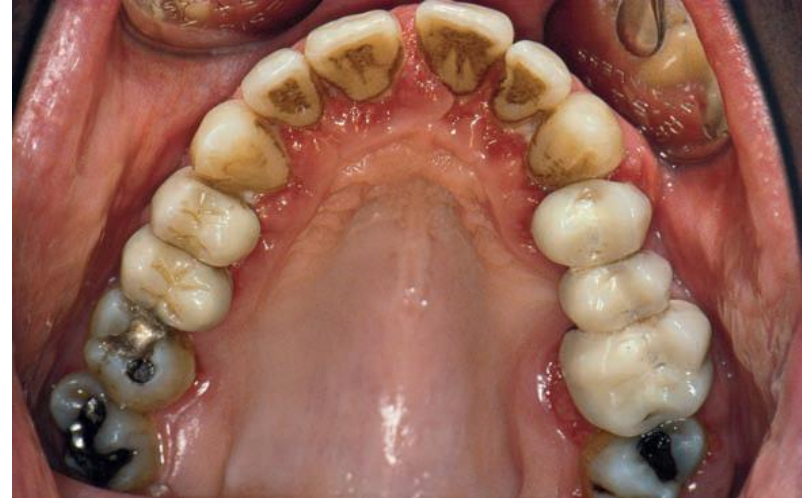Hypersensitivity: exposed root surfaces

Proximal contact relationship

By clinical observation and dental floss

Tooth mobility

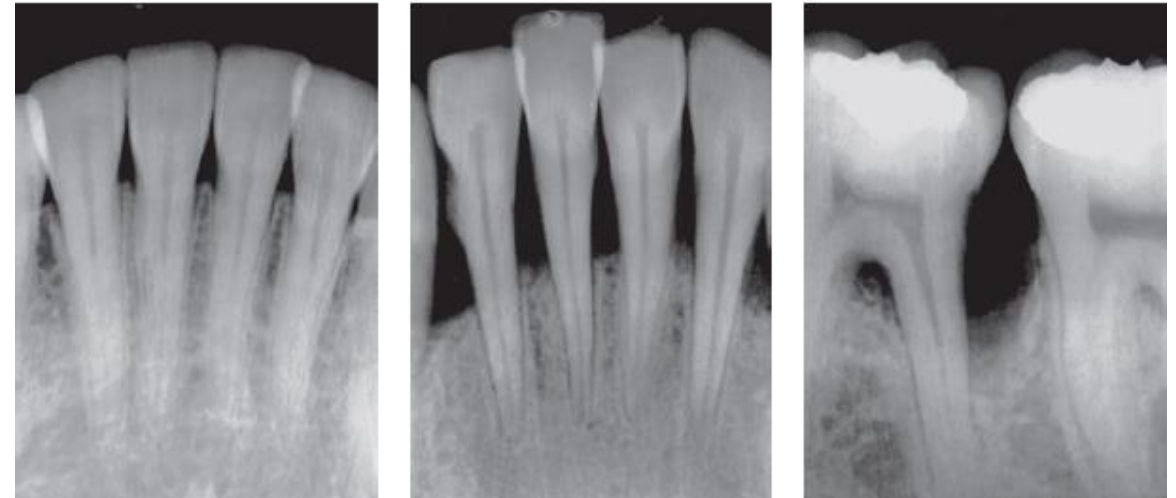
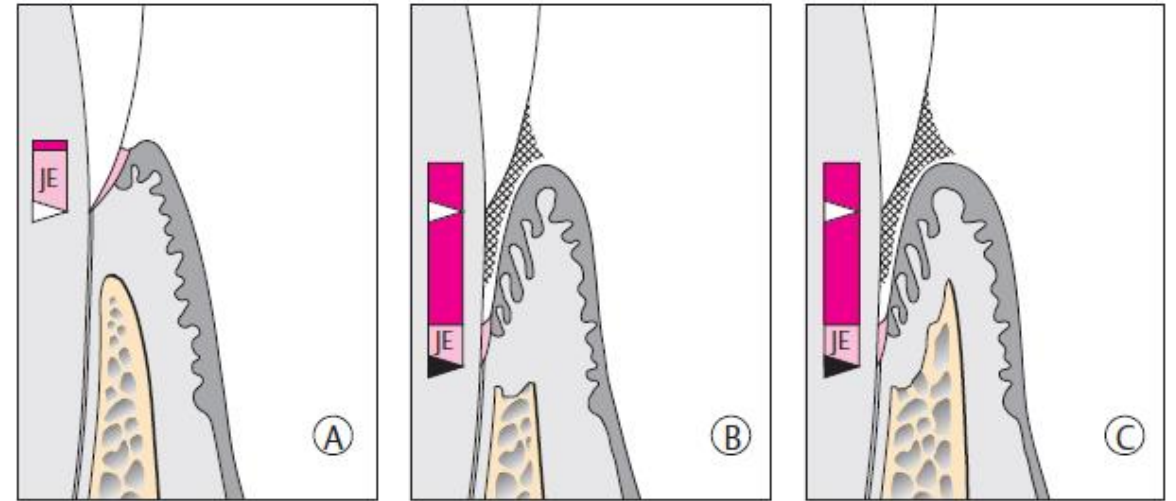
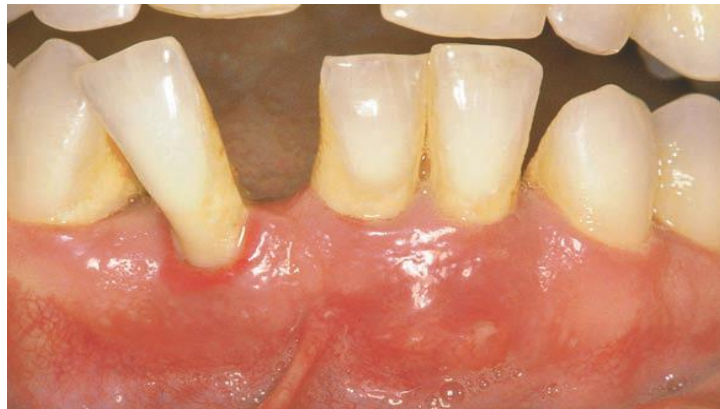- Physiological and pathological mobility
- Normal tooth mobility is less than 1mm
- Pathological tooth mobility when became severe in buccolingual and mesio-distal with vertical displacement



Trauma from occlusion

due to:

- excessive tooth mobility
- Widening of periodontal space
- Vertical or angular bone loss (intra-bony pocket)
- Pathological migration of teeth due to:
 - Tongue thrust
 - Abnormal forces
- Pathological migration of anterior teeth in young adult, which be s sign of localised aggressive periodontitis



Sensitivity or tenderness to percussion

- Acute inflammation of PDL
- Percussion at different angles of the long axis of the tooth

Gingiva





- Colour, size, contour, consistency, surface texture, position, bleeding on probing and pain

Types of gingival inflammation:

- Oedematous: smooth, glossy, soft and red colour
- Fibrotic: opaque, thick and rounded margin

Clinical indices in periodontal practice

Plaque index

Grade 0	No Plaque	
1	Thin plaque layer at the gingival margin, only detectable by scraping with a probe	
2	Moderate layer of plaque along the gingival margin; interdental spaces free, but plaque is visible to the naked eye	
3	Abundant plaque along the gingival margin; interdental spaces filled with plaque	

Abbreviation Grade
PI 0-3

Gingival index

Grade	
0	Normal gingiva; no inflammation; no discoloration (erythema); no bleeding
1	Mild inflammation; slight erythema; minimal superficial alterations. No bleeding
2	Moderate inflammation; erythema; bleeding on probing
3	Severe inflammation; severe erythema and swelling; tendency to spontaneous bleeding; possible ulceration.

Periodontal pocket

- Pocket depth
- Attachment loss level
- Type of pockets whether supra or intrabony

